



Concomitant Mycotic and Verminous Pneumonia in a Blue Jay from Georgia

Authors: Young, Elizabeth A., Cornish, Tood E., and Little, Susan E.

Source: Journal of Wildlife Diseases, 34(3) : 625-628

Published By: Wildlife Disease Association

URL: <https://doi.org/10.7589/0090-3558-34.3.625>

BioOne Complete (complete.BioOne.org) is a full-text database of 200 subscribed and open-access titles in the biological, ecological, and environmental sciences published by nonprofit societies, associations, museums, institutions, and presses.

Your use of this PDF, the BioOne Complete website, and all posted and associated content indicates your acceptance of BioOne's Terms of Use, available at www.bioone.org/terms-of-use.

Usage of BioOne Complete content is strictly limited to personal, educational, and non - commercial use. Commercial inquiries or rights and permissions requests should be directed to the individual publisher as copyright holder.

BioOne sees sustainable scholarly publishing as an inherently collaborative enterprise connecting authors, nonprofit publishers, academic institutions, research libraries, and research funders in the common goal of maximizing access to critical research.

Concomitant Mycotic and Verminous Pneumonia in a Blue Jay from Georgia

Elizabeth A. Young,^{1,2} Todd E. Cornish,¹ and Susan E. Little,^{1,3,4} Southeastern Cooperative Wildlife Disease Study, College of Veterinary Medicine, The University of Georgia, Athens, Georgia 30602, USA; ² University of Wisconsin School of Veterinary Medicine, Madison, Wisconsin 53705, USA; ³ Department of Medical Microbiology and Parasitology, College of Veterinary Medicine, The University of Georgia, Athens, Georgia 30602, USA; and ⁴ Corresponding author (email: slittle@calc.vet.uga.edu).

ABSTRACT: An emaciated, moribund, male blue jay (*Cyanocitta cristata*) was collected in Georgia (USA) and died shortly after capture. Necropsy revealed nine large nematodes identified as *Diplotrinaena tricuspsis* in the thoracic and abdominal air sacs and within the pericardial sac. Multiple mycotic granulomas also were observed in the lungs and air sacs, and fungal culture of these lesions yielded pure growth of *Aspergillus fumigatus*. Histologic examination of the lungs revealed disseminated granulomatous inflammation containing both larvated nematode eggs and abundant fungal hyphae. This is the first description of concomitant *A. fumigatus* and *D. tricuspsis* infection in a bird.

Key words: Aspergillosis, *Aspergillus fumigatus*, blue jay, case report, *Cyanocitta cristata*, *Diplotrinaena tricuspsis*, respiratory nematodiasis.

Pulmonary aspergillosis has been reported in a variety of captive and wild birds, including passerines, and is most commonly caused by *Aspergillus fumigatus* (Zinkl et al., 1977). *Diplotrinaena* spp. are large nematodes, the adults of which inhabit the air sacs of birds of the family corvidae (Anderson and Bain, 1976). When insects containing infective third-stage *Diplotrinaena tricuspsis* larvae are ingested by corvids, the larvae emerge and undergo a complex migratory route during which they molt and mature. The migratory route takes the larvae from the small intestine to the liver, up the posterior vena cava to the heart, out the pulmonary arteries into the lungs, and then to the posterior thoracic and abdominal air sacs where they mature to adults (Cawthorn and Anderson, 1980; Anderson, 1992). We describe herein the lesions associated with a dual infection of *A. fumigatus* and *D. tricuspsis*.

In July 1996, the diagnostic laboratory

of the Southeastern Cooperative Wildlife Disease Study (SCWDS, The University of Georgia, Athens, Georgia, USA) received an adult blue jay (*Cyanocitta cristata*). The bird was found depressed and lethargic near a private residence in Jackson County, Georgia (USA; 33°59'N, 83°29'W). It was held for observation, but died within 1 hr of capture, and was submitted for necropsy the same day.

The bird, a 66 g adult male, was emaciated with marked pectoral muscle atrophy and depletion of body fat stores. A firm, caseous, yellow nodule surrounding a large nematode was present on the right thoracic air sac. The lungs were diffusely consolidated and contained multiple dark, firm, red to tan nodules. A raised, white plaque was present on the left thoracic air sac adjacent to the pericardium. The pericardium was diffusely thickened and yellow. Two large nematodes were found coiled within the pericardial sac. Six additional nematodes were found within the abdominal air sacs.

Aseptically collected swabs of air sac lesions were submitted to the Athens Diagnostic Laboratory (Athens, Georgia, USA) for aerobic bacterial culture and fungal culture using standard techniques (Ikram and Hill, 1991). Briefly, swabs for bacterial culture were streaked onto 5% sheep blood agar plates directly and after overnight enrichment in thioglycolate broth at 37 C. Inoculated plates were incubated at 37 C. Bacterial colonies were identified visually and via testing with an o-nitrophenyl- β -d-galactopyranoside disc (Becton Dickinson & Co., Rutherford, New Jersey, USA). Swabs for fungal culture were streaked onto Sabouraud dextrose agar

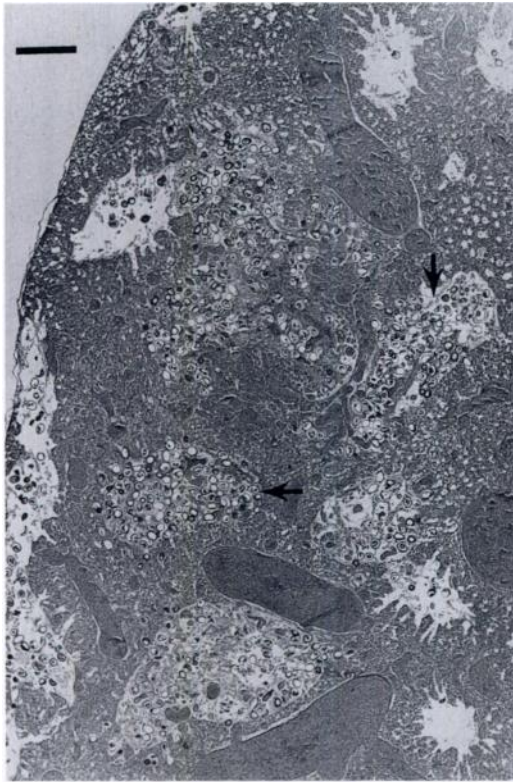


FIGURE 1. Multiple parabronchi filled with larvated *Diplotriaeana tricuspis* eggs (arrows) in the lung of a blue jay. H&E. Bar = 500 μm .

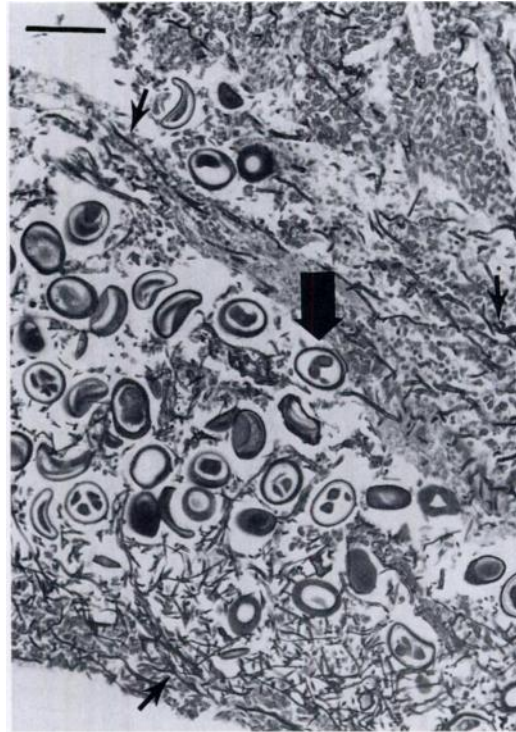

FIGURE 2. Larvated *Diplotriaeana tricuspis* eggs (large arrow) mixed with abundant *Aspergillus fumigatus* hyphae (small arrows) in the lung of a blue jay. Grocott's methenamine silver stain. Bar = 100 μm .

(Difco, Chicago, Illinois, USA) and incubated at 25 C. Fungal colonies were identified visually (Rippon, 1988). Nematodes were collected and placed in 5% neutral buffered formalin for later identification. Sections of brain, kidney, skeletal muscle, liver, proventriculus, ventriculus, heart, testis, lung, and air sac were fixed in 10% neutral buffered formalin, embedded in paraffin, sectioned at 3 μm thickness, and stained with hematoxylin and eosin. Additional sections of lung and air sac were stained with Grocott's methenamine silver (GMS) stain (Luna, 1968).

Cultures of lung and air sac lesions produced pure growth of *A. fumigatus*. Several nematodes were cleared in 60% lacto-phenol solution with fast green and identified as *D. tricuspis* according to the description of Anderson (1959). Representative specimens were deposited in the U.S. National

Parasite Collection (Beltsville, Maryland, USA; Accession number 86860). On microscopic examination, all lung sections contained extensive, multifocal regions of consolidation. In affected regions of lung, both bronchi and parabronchi were filled with dense aggregates of larvated nematode eggs mixed with diffuse mats of fungal hyphae and small numbers of macrophages and heterophils (Fig. 1). The pulmonary parenchyma surrounding these airways contained fewer nematode eggs and fungal hyphae. Fungal hyphae often invaded the walls of blood vessels resulting in vascular necrosis and vasculitis. Nematode eggs were oval, approximately 70 \times 50 μm , thick walled, and contained coiled larvae (Fig. 2). The fungal hyphae admixed with the nematode eggs were thin (5–8 μm) with parallel walls, septa, and branching at acute angles. Air sac membranes were markedly thickened and contained

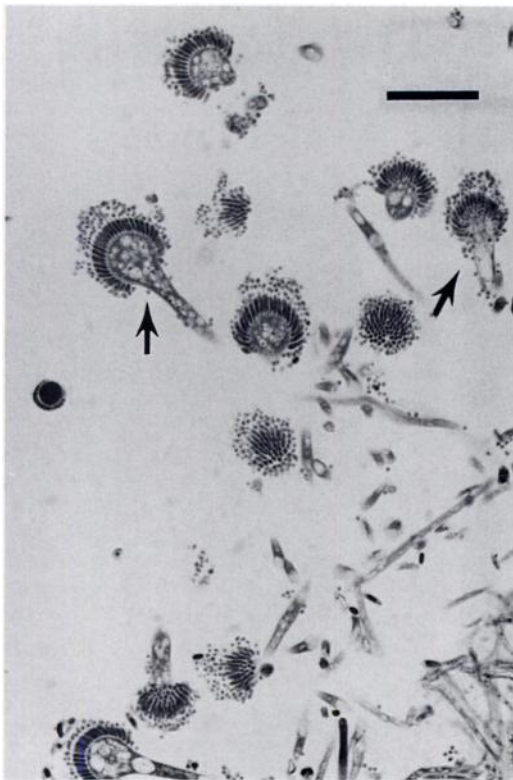


FIGURE 3. Air sac of a blue jay showing fungal conidiophores with fruiting bodies (arrows) characteristic of *Aspergillus fumigatus*. Grocott's methenamine silver stain. Bar = 40 μm .

moderate numbers of nematode eggs mixed with similar fungal organisms. Numerous fungal hyphae lining the surface of the air sac had attached conidiophores and fruiting bodies, and with GMS staining were morphologically consistent with *A. fumigatus*. (Fig. 3).

Aspergillus fumigatus is the most common species isolated from clinical aspergillosis infections in birds (Redig et al., 1980). *Aspergillus fumigatus* spores are widely distributed throughout the world, and free-living birds are in regular contact with this fungal agent (Davis et al., 1971). Healthy adult birds, even those exposed to high numbers of spores, are generally resistant to infection. Thus, infection is believed to occur secondary to immunosuppression (Ritchie et al., 1994). Several factors could cause immunosuppression in

wild birds, including starvation, thermal stress, migratory stress, a primary infectious disease, or toxicosis.

Aspergillosis has been reported in both acute and chronic forms. The acute form occurs when birds are exposed to a large dose of spores from a point source and is characterized by miliary granulomas throughout the lungs and air sacs (Redig et al., 1980). The clinical course is a few days, and birds in good body condition are found dead. The chronic form is usually associated with an immunosuppressive event that allows low levels of these common spores to cause disease (Redig et al., 1980). The birds become emaciated and die over a course of several weeks, with large granulomas observed in the lungs, and free-growing, sporulating mold observed in the air sacs (Redig et al., 1980).

Larval and adult *Diplotrriaena* spp. occur in various passerine birds. Despite the traumatic migration of the developing nematodes, infections with extensive pulmonary lesions have not consistently been associated with clinical disease (Ritchie et al., 1994). Common crows (*Corvus brachyrhynchos*) experimentally infected with *D. tricuspis* developed space-occupying lesions interfering with respiration and subsequent ventilation of air sacs, but only 1 of 44 crows exhibited clinical signs of abnormal respiratory sounds (Cawthorn et al., 1980). Free eggs were present in bronchi of crows and evoked an extensive pneumonia in secondary bronchi and associated parabronchi (Cawthorn et al., 1980). Experimental *D. tricuspis* infections in birds other than corvids suggest *D. tricuspis* is specific to the Corvidae, and in eastern North America the main host may be the blue jay (Cawthorn and Anderson, 1980). In the USA, *Diplotrriaena tricuspis* was found in 31% of 100 adult blue jays from Vermont, New Hampshire, and Massachusetts (Boyd et al., 1956) and in 14% of 50 blue jays from Ohio (Cooper and Crites, 1974).

The concomitant respiratory nematodiasis and chronic aspergillosis found in this

blue jay caused overt clinical disease and extensive morphologic lesions. The presence of two adult *D. tricuspis* in the pericardial sac is considered aberrant as no route exists for larvated eggs to leave the host (Cawthorn et al., 1980). This aberrant migration, coupled with a heavy respiratory *D. tricuspis* burden and poor body condition, may have contributed to the development of chronic aspergillosis in this bird.

The authors thank W. R. Davidson for assistance with identification of the helminths, L. Sileo for assistance with the manuscript, and the late F. Hayes for submitting the clinical case. This work was supported through sponsorship from the fish and wildlife agencies of Alabama, Arkansas, Florida, Georgia, Kansas, Kentucky, Louisiana, Maryland, Mississippi, Missouri, North Carolina, Puerto Rico, South Carolina, Tennessee, Virginia, and West Virginia. Funds were provided by the Federal Aid to Wildlife Restoration Act (50 Stat. 917) and through Grant Agreement 14-45-0009-94-906, National Biological Service, U.S. Department of the Interior.

LITERATURE CITED

- ANDERSON, R. C. 1959. Preliminary revision of the genus *Diplotrriaena* Henry and Ozoux, 1909 (Diplotrriaenidae: Diplotrriaeninae). *Parassitologia* 1: 265–270.
- . 1992. Nematode parasites of vertebrates, their development and transmission. CAB International, Wallingford, UK, 578 pp.
- , AND O. BAIN. 1976. No. 3. Keys to genera of the order Spirurida. Part 3. Diplotrriaenoidea, Aprotoidea, and Filarioidea. *In* CIH keys to the nematode parasites of vertebrates, R. C. Anderson, A. G. Chabaud, and S. Willmott (eds.). CAB International, Wallingford, UK, 116 pp.
- BOYD, E. M., R. L. DIMINNO, AND C. NESSLINGER. 1956. Metazoan parasites of the blue jay, *Cyanocitta cristata*. *The Journal of Parasitology* 42: 332–346.
- CAWTHORN, R. J., AND R. C. ANDERSON. 1980. Development of *Diplotrriaena tricuspis* (Nematoda: Diplotrriaenoidea), a parasite of Corvidae, in intermediate and definitive hosts. *Canadian Journal of Zoology* 58: 94–108.
- , R. C. ANDERSON, AND I. K. BARKER. 1980. Lesions caused by *Diplotrriaena tricuspis* (Nematoda: Diplotrriaenoidea) in the American crow, *Corvus brachyrhynchus* Brehm. *Canadian Journal of Zoology* 58: 1892–1898.
- COOPER, C. L., AND J. L. CRITES. 1974. The helminth parasites of the blue jay, *Cyanocitta cristata bromia*, from South Bass Island Ohio. *Canadian Journal of Zoology* 52: 1421–1423.
- DAVIS, J. W., R. C. ANDERSON, L. KARSTAD, AND D. O. TRAINER. (editors). 1971. Infectious and parasitic diseases of wild birds. Iowa State University Press, Ames, Iowa, 344 pp.
- IKRAM, M., AND E. HILL. 1991. Microbiology for veterinary technicians. American Veterinary Publications, Inc., Goleta, California, 213 pp.
- LUNA, L. G. 1968. Manual of histologic staining methods of the Armed Forces Institute of Pathology, 3rd ed. McGraw-Hill, New York, New York, 258 pp.
- REDIG, P. T., M. R. FULLER, AND D. L. EVANS. 1980. Prevalence of *Aspergillus fumigatus* in free-living goshawks (*Accipiter gentilis atricapillus*). *Journal of Wildlife Diseases* 16: 169–174.
- RIPPON, J. W. 1988. Medical mycology, 3rd ed. W. B. Saunders Company, Philadelphia, Pennsylvania, 797 pp.
- RITCHIE, B. W., G. J. HARRISON, AND L. R. HARRISON. (editors). 1994. Avian medicine: Principles and application. Wingers Publishing, Lake Worth, Florida, 1384 pp.
- ZINKL, J. G., J. M. HYLAND, AND J. J. HURT. 1977. Aspergillosis in common crows in Nebraska, 1974. *Journal of Wildlife Diseases* 13: 191–193.

Received for publication 16 January 1998.