

Multimodal analgesia for treatment of allodynia and hyperalgesia after major trauma in a cat

Authors: Goich, Mariela, Bascuñán, Alejandra, Faúndez, Patricio, and Valdés, Alicia

Source: Journal of Feline Medicine and Surgery Open Reports, 5(1)

Published By: SAGE Publishing

URL: <https://doi.org/10.1177/2055116919855809>

BioOne Complete (complete.BioOne.org) is a full-text database of 200 subscribed and open-access titles in the biological, ecological, and environmental sciences published by nonprofit societies, associations, museums, institutions, and presses.

Your use of this PDF, the BioOne Complete website, and all posted and associated content indicates your acceptance of BioOne's Terms of Use, available at www.bioone.org/terms-of-use.

Usage of BioOne Complete content is strictly limited to personal, educational, and non - commercial use. Commercial inquiries or rights and permissions requests should be directed to the individual publisher as copyright holder.

BioOne sees sustainable scholarly publishing as an inherently collaborative enterprise connecting authors, nonprofit publishers, academic institutions, research libraries, and research funders in the common goal of maximizing access to critical research.



Multimodal analgesia for treatment of allodynia and hyperalgesia after major trauma in a cat

Mariela Goich¹, Alejandra Bascuñán², Patricio Faúndez² and Alicia Valdés²

Journal of Feline Medicine and Surgery Open Reports
1–8

© The Author(s) 2019

Article reuse guidelines:

sagepub.com/journals-permissions

DOI: 10.1177/2055116919855809

journals.sagepub.com/home/jfmsopenreports

This paper was handled and processed by the American Editorial Office (AAFP) for publication in *JFMS Open Reports*



Abstract

Case summary A 2-year-old polytraumatized male cat was admitted to a teaching hospital for correction of a defective inguinal herniorrhaphy. Upon arrival, the cat showed signs of neuropathic pain, including allodynia and hyperalgesia. Analgesic therapy was initiated with methadone and metamizole; however, 24 h later, the signs of pain continued. Reparative surgery was performed, and a multimodal analgesic regimen was administered (methadone, ketamine, wound catheter and epidural anesthesia). Postoperatively, the cat showed signs of severe pain, assessed using the UNESP-Botucatu multidimensional composite pain scale. Rescue analgesia was initiated, which included methadone, bupivacaine (subcutaneous wound-diffusion catheter) and transversus abdominis plane block. Because the response was incomplete, co-adjuvant therapy (pregabalin and electroacupuncture) was then implemented. Fourteen days after admission, the patient was discharged with oral tramadol and pregabalin for at-home treatment.

Relevance and novel information Neuropathic pain is caused by a primary lesion or dysfunction in the nervous system and is a well-described complication following trauma, surgical procedures such as hernia repair, and inadequate analgesia. The aims of this report are to: (1) describe a presentation of neuropathic pain to highlight the recognition of clinical signs such as allodynia and hyperalgesia in cats; and (2) describe treatment of multi-origin, severe, long-standing, 'mixed' pain (acute inflammatory with a neuropathic component). The patient was managed using multiple analgesic strategies (multimodal analgesia), including opioids, non-steroidal anti-inflammatory drugs, locoregional anesthesia, co-adjuvant drugs and non-pharmacological therapy (electroacupuncture).

Keywords: Multimodal analgesia; neuropathic pain; allodynia; hyperalgesia; inguinal herniorrhaphy; electroacupuncture; pregabalin

Accepted: 30 April 2019

Case description

A 2-year-old intact male domestic shorthair polytraumatized cat initially presented to a primary care clinic and underwent surgery for inguinal hernia repair. The owners were not aware of the treatment received, nor were medical records available, and it was discharged without medication the same day as surgery. Seven days later, it was admitted to the Veterinary Hospital of the University of Chile for depression, anorexia and inflammation of the incision. Pain-related behaviors included kyphosis and severe pain with gentle abdominal palpation. The UNESP-Botucatu multidimensional composite pain scale (UNESP-Botucatu MCPS)¹ score

was 18/30. Physiological variables were unremarkable (body weight 3.6 kg; heart rate 180 beats per min [bpm]; systolic blood pressure 130 mmHg; temperature 37.7°C).

¹Escuela de Medicina Veterinaria, Facultad de Ciencias de la vida, Universidad Andres Bello

²University of Chile, Veterinary Hospital

Corresponding author:

Mariela Goich DVM, MSc, PhD, Escuela de Medicina Veterinaria, Facultad de Ciencias de la vida, Universidad Andres Bello, Republica 440, 8370251, Santiago, Chile
Email: mariela.goich@unab.cl



Creative Commons Non Commercial CC BY-NC: This article is distributed under the terms of the Creative Commons

Attribution-NonCommercial 4.0 License (<http://www.creativecommons.org/licenses/by-nc/4.0/>) which permits non-commercial use, reproduction and distribution of the work without further permission provided the original work is attributed as specified on the SAGE and Open Access pages (<https://us.sagepub.com/en-us/nam/open-access-at-sage>).

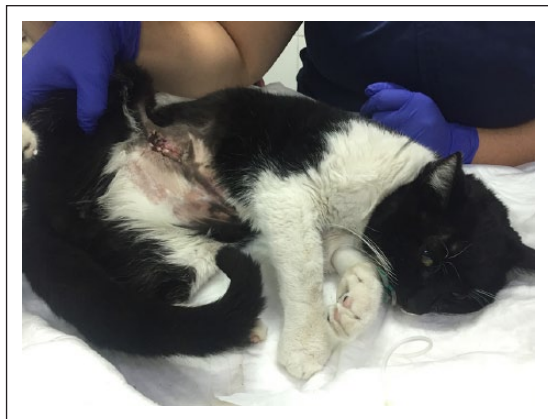

Figure 1 Patient after hospital admission, showing an abnormal posture (back kyphosis, retracted abdomen)

Methadone (0.2 mg/kg IV q6h) and metamizole (25 mg/kg IV q8h) were used for analgesia, avoiding the use of non-steroidal anti-inflammatory drugs (NSAIDs) owing to safety concerns and unknown patient status at admission. Blood test abnormalities indicated neutrophilia (16,575/ μ l; reference interval [RI] 2500–12,500/ μ l), lymphopenia (1365/ μ l [RI 1700–7000/ μ l]), monocytosis (1170/ μ l [RI 0–850/ μ l]) and a slight increase in gamma-glutamyl transferase (17 U/l [RI 0–8 U/l]). When reassessing pain, mechanical allodynia was evidenced by an extreme reaction when the skin was lightly rubbed and stroked with fingers or a gauze, and thermal hyperalgesia was revealed as marked sensitivity when placing an icepack (Figure 1).

The patient was sedated so that we could perform an abdominal ultrasound. A transversus abdominis plane (TAP) block with bupivacaine (1 mg/kg) was incomplete owing to the difficulty in seeing the muscle layers. The ultrasound revealed a loss of continuity of the abdominal muscular wall at the right inguinal area, which likely left the block incomplete. Passage of the jejunum and the presence of a mass of 2.8×2.3 cm was located in the mid-abdomen, suggesting focal adhesions, hematoma or abscess. Exploratory laparotomy was scheduled.

The procedure was performed 24 h after admission and lasted 2 h. Surgery corrected the hernia, resecting 1×2 cm of muscular wall and releasing the intestine (duodenum and jejunum) that was attached to the abdominal wall. The anesthetic protocol consisted of methadone (0.2 mg/kg IV), ketamine (2.5 mg/kg IV)/midazolam (0.25 mg/kg IV), maintenance with isoflurane and an epidural injection (bupivacaine 0.5%: 0.3 ml/kg; morphine: 0.1 mg/kg). Upon skin and muscle incision, the patient showed a sympathetic response (tachycardia, hypertension and tachypnea). Fentanyl (5 μ g/kg/h) and ketamine (0.6 mg/kg/h) constant rate infusion (CRI) was initiated; tachycardia (204 bpm) and

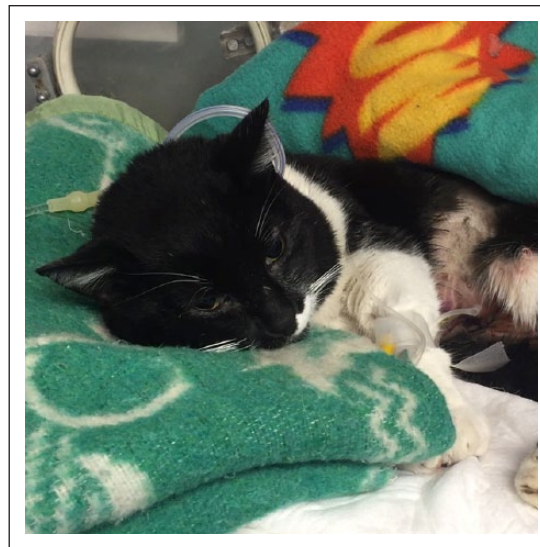

Figure 2 Patient during anesthesia recovery with 15 points on the UNESP-Botucatu multidimensional composite pain scale

tachypnea (40 breaths per minute) persisted, but blood pressure dropped. Postoperatively, dexamethasone was administered (0.5 mg/kg IV). A manually created wound-diffusion catheter was created from a 21 G butterfly catheter, sealed with a heat source and fenestrations were made from a through-and-through puncture with a 21 G hypodermic needle. The wound-diffusion catheter was placed subcutaneously at the closure site for bupivacaine administration.

During anesthesia recovery, the patient was able to walk but appeared hyperreactive to auditory stimuli and ataxic, and the fentanyl and ketamine infusions were suspended 45 mins postoperatively. The patient continued with abdominal pain (UNESP-Botucatu MCPS score 15/30), mechanical allodynia, thermal hyperalgesia and a facial expression characterized by narrowed eyes (Figure 2). Therefore, rescue analgesia was initiated with methadone (0.2 mg/kg IV q4h), and the first dose of bupivacaine was placed through the subcutaneous (SC) wound-diffusion catheter (1 mg/kg q8h).

Despite analgesic rescue, 1 h later the pain score remained high (15/30). The patient was re-sedated, a TAP block (bupivacaine 1 mg/kg) was repeated and co-adjuvant therapy was initiated with pregabalin (3 mg/kg PO q12h). A session of electroacupuncture (EA) was held for 20 mins at mixed frequencies (high and low) at points ST36 (master point of the gastrointestinal tract and abdomen) + SP6 (master point of the caudal abdomen and urogenital system); EA appeared to be well tolerated. Pain score decreased to 12/30 1 h after EA (Figure 3) but remained higher than the score described for rescue analgesia ($>7/30$).¹ Meloxicam was initiated at 0.2 mg/kg SC (continuing at 0.1 mg/kg SC q24h). Two hours later, the pain score had decreased to 8/30.

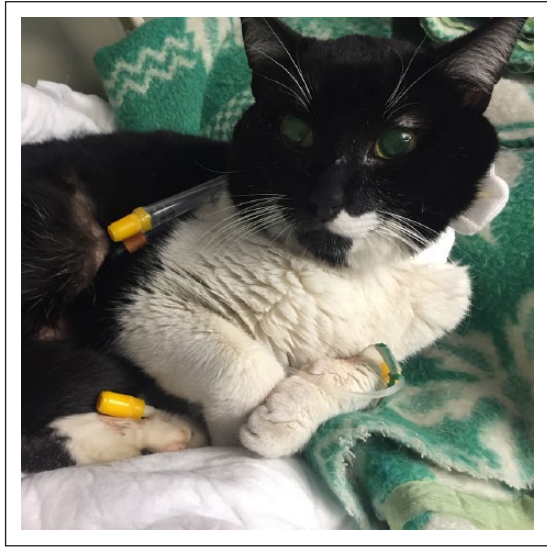

Figure 3 Patient after multimodal analgesia (12 points on UNESP-Botucatu multidimensional composite pain scale)

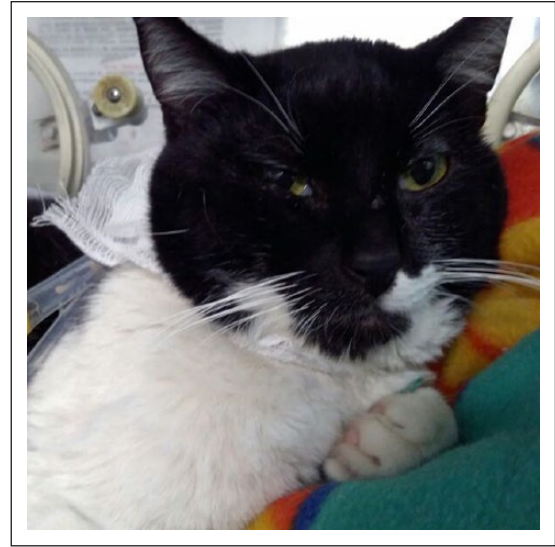

Figure 5 Forty-eight hours postoperatively and after the removal of the wound catheter (12 points on UNESP-Botucatu multidimensional composite pain scale)

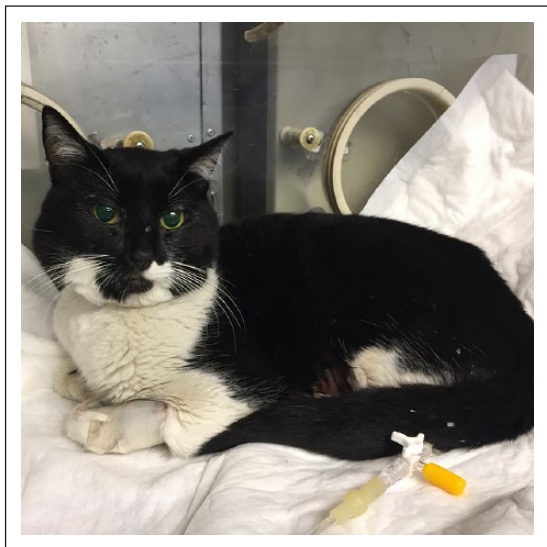

Figure 4 Twenty-four hours postoperatively (6 points on UNESP-botucatu multidimensional composite pain scale)

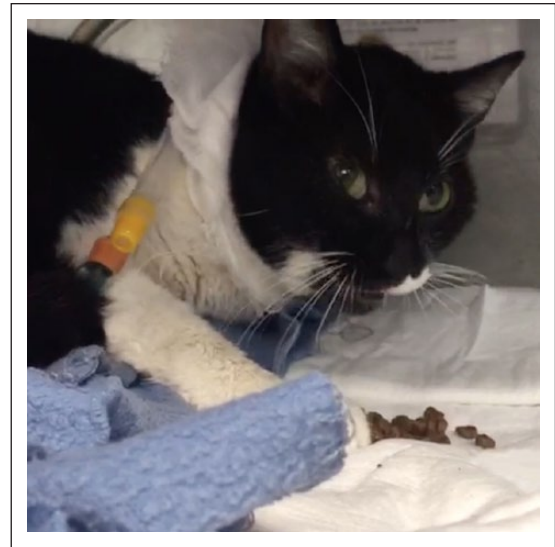


Figure 6 Ninety-six hours postoperatively: the patient was comfortable and had no allodynia

Twenty-four hours postoperatively, the patient accepted food, showed less response to abdominal palpation and the pain score decreased to 6/30 (Figure 4). Methadone (0.2 mg/kg IV q4h), metamizole (25 mg/kg IV q8h), pregabalin (3 mg/kg PO q12h), meloxicam (0.1 mg/kg q24h) and bupivacaine (1 mg/kg SC wound-diffusion catheter q8h) were continued.

Forty-eight hours postoperatively, the wound catheter was removed, and the pain score increased to 12/30 (Figure 5). Ketamine CRI (0.6 mg/kg/h) was initiated, and the methadone dosage and frequency were increased to 0.3 mg/kg intravenously every 4 h.

Forty-eight hours after initiating the ketamine CRI and increasing the dose and frequency of methadone, the

patient no longer demonstrated allodynia and the pain score was 8/30 (Figure 6). An EA session was repeated. Twenty-four hours later (72 h after initiating the ketamine CRI and increased dose and frequency of methadone, 120 h postoperatively), the ketamine and methadone dosages were reduced to 0.3 mg/kg/h and 0.2 mg/kg IV q6h, respectively. Six days after surgery, the ketamine infusion was suspended.

Ten days after surgery, the pain score was 5/30 and methadone was discontinued. Tramadol (3 mg/kg IV q8h) was initiated until discharge.

Ketamine was continued for 6 days; metamizole for 7 days; methadone for 12 days; and meloxicam for 14 days.

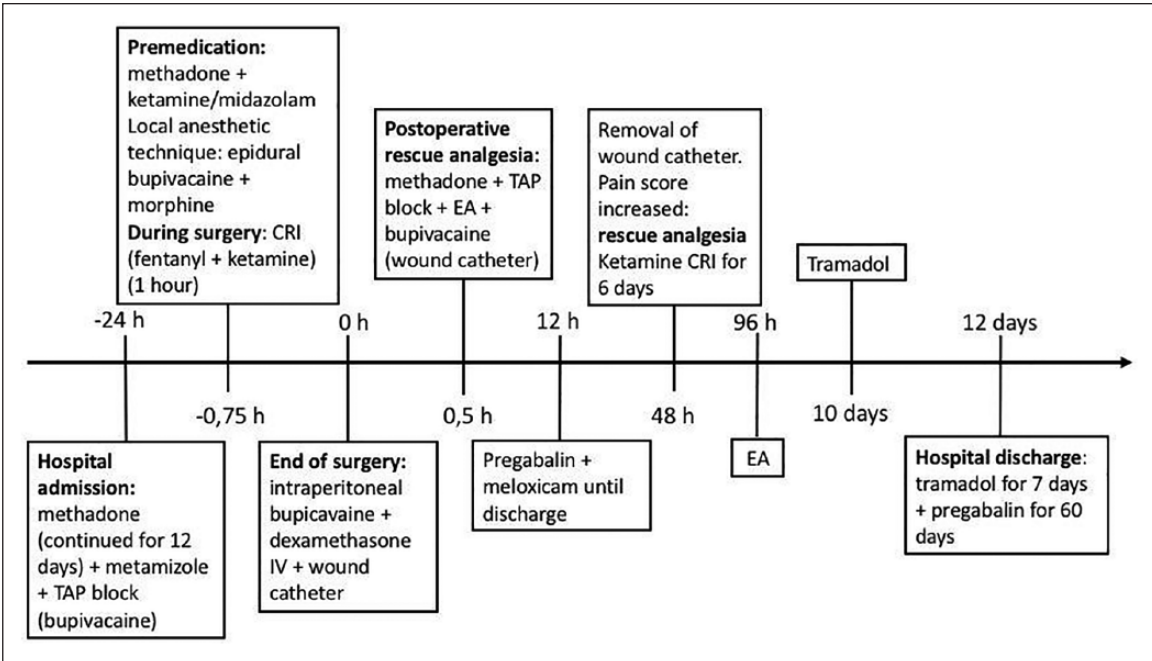


Figure 7 Timeline demonstrating the multimodal treatment administered to the patient with allodynia and hyperalgesia until hospital discharge. TAP = transversus abdominis plane; EA = electroacupuncture; CRI = constant rate infusion; IV = intravenous

Fourteen days post-admission, the patient was discharged with tramadol (3 mg/kg PO q8h for 7 days; oral drops were mixed with food due to the bitter taste) and pregabalin (3 mg/kg PO q12h for 60 days) (Figure 7).

Discussion

This report presents a case of severe pain, suggesting a type of ‘mixed pain’, where nociceptive (inflammatory) and neuropathic pain coexist,² requiring the use of different strategies for relief. Nociceptive pain is normally processed by the somatosensorial system, whereas neuropathic pain is generated by damage or dysfunction in the somatosensorial system.³ Development of neuropathic pain involves central and peripheral sensitization, characterized by ectopic activity of afferent fibers, decreased inhibitory modulation, pathological activation of microglia and phenotypic change in mechanoreceptive A-beta fibers.^{2,4} Possible contributors to the neuropathic component of this patient’s pain included injury of peripheral nerves (eg, iliohypogastric nerve), major

trauma, poor analgesia, surgical procedures and stress (considering that stress exacerbates neuropathic pain via glucocorticoid receptors and microglial activation).⁵

The characteristics and refractoriness to treatment with opioids and NSAIDs suggested persistent postoperative pain (PPP) with a neuropathic component.^{4,6} PPP in humans is defined as clinical discomfort that lasts more than 2 months postoperatively, but remains uncharacterized in animals.

Neuropathic pain has been described in dogs after correction of perineal hernia,⁷ in humans after inguinal herniorrhaphy and in cats post-amputation.^{8,9} Neuropathic pain is manifested by allodynia, hyperalgesia, hyperesthesia, dysesthesias, expanded field and intermittent spontaneous pain and is frequently unresponsive to conventional analgesic drugs.¹⁰ Table 1 shows some simple tests that can be performed to identify allodynia and hyperalgesia in humans. Mathews has suggested an adaptation of these tools to assess allodynia and hyperalgesia in animals.⁴

Table 1 Simple test for the assessment of stimulus-evoked neuropathic pain in humans

Allodynia	Thermal: it can be noticed contacting the lesion with objects at 20°C or 40°C Mechanical: it can be observed stroking the skin with a cotton/gauze
Hyperalgesia	Thermal: it can be observed contacting the skin with acetone or cold metal and with objects at 46°C Mechanical: it can be observed as a painful response when pressing skin with a stick of wood

Adapted from Mathews KA. Neuropathic pain in dogs and cats: if only they could tell us if they hurt. *Vet Clin North Am Small Anim Pract* 2008; 38: 1365–1414⁴

The UNESP-Botucatu MCPS (a trustworthy and sensitive tool for cats and validated in Spanish) was used for postoperative pain assessment.¹ It integrates the observation of patient behavior without and then with interaction features included in the most reliable clinical pain measurement instruments.¹¹

Initially, the patient received methadone and metamizole, eliciting a mild response. Metamizole is a non-opioid analgesic drug, sometimes incorrectly classified as an NSAID. The mechanism responsible for the analgesic effect is probably the inhibition of a central cyclooxygenase (COX) 3 and activation of the opioidergic system and cannabinoid system.¹² Its pharmacokinetics profile has been described in cats.¹³

Methadone is an opioid agonist and a weak NMDA receptor antagonist.¹⁴ Opioid receptors, found in the brain, spinal cord and peripheral tissues, reduce the release of excitatory neurotransmitters and cause hyperpolarization of neurons.^{15,16} In cats, methadone provides effective analgesia for procedures such as orchietomy and ovari-hysterectomy.^{17,18} The patient was subsequently placed on fentanyl CRI; in cats, fentanyl has elicited an increase in thermal and mechanical nociceptive thresholds.¹⁹ Ideally, opioids should be used before a painful stimulus, thus preventing sensitization of the central nervous system;¹⁴ however, in this case, they were administered 7 days post-trauma. Complications of opioid therapy include vomiting, inappetence, reduced intestinal motility, urinary retention, opioid-induced hyperalgesia and tolerance (reported in humans).^{14,20} Nevertheless, none of these effects were observed.

For the abdominal herniorrhaphy, an epidural regional block was performed; however, the blockade appeared to fail and rescue analgesia was necessary. Failure rates of epidurals are 23% in humans, 7% in dogs and 9% in cats.^{21,22}

The ketamine and fentanyl CRIs were suspended after surgery when hyperreactivity and ataxia were observed. Both behaviors have been described as adverse effects of opioids²³ and ketamine during anesthesia recovery.^{16,24} As alternatives, the rate of either or both drug infusions could have been decreased, or only one infusion discontinued. Ketamine is a phencyclidine dissociative anesthetic at higher doses. When administered subanesthetically by CRI, it still shows activity in the spinal cord dorsal horn, blocking the NMDA receptor and reducing wind-up and central sensitization.^{25,26} Subanesthetic doses are described in humans and dogs.^{25,27} In cats not experiencing pain, with a lack of central sensitization, subanesthetic ketamine CRI minimally affects thermal and mechanical antinociception.²⁸ In this patient, with central sensitization presumed present, the treatment appeared to generate a positive response.

A TAP block was performed twice in this patient. TAP block is an alternative to neuraxial techniques and blocks

the neural afferent of the abdominal wall through the introduction of local anesthetic in the interfascial plane between the transversus abdominis and internal oblique muscles.^{29–31} The first blockade was deemed only partially effective, owing to the loss of muscle generated by the trauma. Analgesia was complemented with EA. The proposed mechanism of analgesic action for EA involves activation of chemically bioactive substances (including opioids, serotonin and norepinephrine) through peripheral, spinal and adrenal mechanisms; desensitization of peripheral nociceptors; and reduction of the release of proinflammatory cytokines at a peripheral level and in the spinal cord. EA at low and high frequencies inhibits pain through the mu, delta and kappa opioid receptors.^{32,33} EA at acupoints ST36 and SP6 reduced postoperative analgesic requirements in cats undergoing ovariohysterectomy.³⁴

Although pain scores decreased with these interventions, scores remained above the limit for rescue analgesia ($>7/30$). Meloxicam was added 12 h postoperatively, which may have been too close in time to the administration of dexamethasone, considering its prolonged biological activity.^{35,36} Dexamethasone might be a useful adjunct to a multimodal analgesia, due to anti-inflammatory effects, as well as interactions with opioid receptors,³⁷ eliciting benefits such as a reduction in pain and in opioid consumption in humans;³⁸ however, the benefits must be weighed against the adverse effects, especially gastrointestinal damage when given in close proximity to NSAIDs.

The pain score decreased after meloxicam administration, presumably through its peripheral and central anti-inflammatory and analgesic effects. NSAIDs act by inhibiting the production of prostaglandins generated by the COX-1 and COX-2 enzymes. Meloxicam is metabolized in the liver by oxidative pathways, in contradistinction to other NSAIDs that require glucuronidation, in which cats are deficient.³⁹ In this case, meloxicam was administered for a longer period than recommended by the manufacturer (single dose) owing to ongoing inflammation and pain. Adverse effects associated with NSAID administration, such as acute kidney injury, gastrointestinal ulcers and gastroenteritis,³⁵ were not observed. The safety of long-term low-dosage meloxicam has been described for chronic pain treatment in clinically stable cats.^{40–42}

Wound-diffusion catheters are described as tools for postoperative pain management in humans, dogs, cats and goats.^{43,44} The catheter was in place for 2 days, based on a previous study in cats.⁴⁴ The pain score increased after removal, presumably due to the loss of local anesthetic blocking somatic sensation.

Gabapentinoids are used for treatment and prevention of maladaptive pain and have been approved by the Food and Drug Administration for use in humans in diabetic

neuropathy, post-herpetic neuralgia and fibromyalgia.⁴⁵ They enhanced the effect of other analgesics in patients with hyperalgesia and allodynia.^{46,47} Gabapentin has been described as an analgesic in multiple surgical settings in dogs and cats, with variable outcomes.^{48–52} Pregabalin was chosen over gabapentin because it is less expensive in this country. Pregabalin is a structural analog of gamma-aminobutyric acid (GABA). Its mechanism of action is not related to GABA and is not completely elucidated; however, the compound binds to the $\alpha 2$ -delta voltage-gated calcium channel subunit, inhibiting calcium influx at the spinal and supraspinal levels and decreasing the release of neurotransmitters, including glutamate and substance P.⁵³ Pregabalin is used as an anticonvulsant and analgesic in humans, but little information exists for animals, with only one published pharmacokinetic report for cats.^{53,54} The analgesic response to pregabalin was uncertain in this patient as subanesthetic ketamine CRI was initiated at the same time, and pharmacokinetics in cats indicate that the steady-state concentration is not reached for 2 days.⁵⁴

Tramadol acts in opioidergic, serotonergic and adrenergic pathways in cats and has elicited thermal antinociception and shown efficacy for treating acute pain in this species.^{55–57} The mu-agonist active metabolite O-desmethyl-tramadol remains high for longer in cats, in comparison with dogs, with a half-life of 261 ± 28 mins (IV administration) and contributes to analgesia.⁵⁸

It was difficult to know which treatments most contributed to pain relief, but adding meloxicam to the therapy did significantly lower pain scores. Three different locoregional anesthetic techniques (epidural, TAP block, wound-diffusion catheter) were used. Two were not completely successful, likely because of anatomical difficulties (TAP block) or failure of the technique (epidural). However, bupivacaine every 8 h through the wound-diffusion catheter appeared effective, as patient pain scores increased when the catheter was removed.

Conclusions

Multimodal pharmacologic and non-pharmacologic interventions were used to reduce pain and allodynia, and complementary analgesic therapies, such as EA and anticonvulsants, were needed to reduce pain, allodynia and hyperalgesia in a cat with neuropathic pain after major trauma and post-herniorrhaphy. A validated clinical pain-scoring instrument (UNESP-Botucatu MCPS) was successfully used to monitor patient status and guide the patient's analgesic therapy.

Acknowledgements The authors are grateful to the team at the Veterinary Hospital of University of Chile for their collaboration and financial support.

Conflict of interest The authors declared no potential conflicts of interest with respect to the research, authorship, and/or publication of this article.

Funding The authors received no financial support for the research, authorship, and/or publication of this article.

References

- 1 Brondani JT, Luna SPL, Crosignani N, et al. **Validade y confiabilidad de la versión en español de la escala multidimensional de la UNESP-Botucatu para evaluar el dolor postoperatorio en gatos.** *Arch Med Vet* 2014; 46: 477–486.
- 2 Moore SA. **Managing neuropathic pain in dogs.** *Front Vet Sci* 2016; 3: 12.
- 3 Merskey H and Bogduk N. **Pain terms, a current list with definitions and notes on usage, classification of chronic pain.** 2nd ed. Seattle, WA: IASP Press, 1994.
- 4 Mathews KA. **Neuropathic pain in dogs and cats: if only they could tell us if they hurt.** *Vet Clin North Am Small Anim Pract* 2008; 38: 1365–1414.
- 5 Alexander JK, De Vries AC, Kigerl KA, et al. **Stress exacerbates neuropathic pain via glucocorticoid and NMDA receptor activation.** *Brain Behav Immun* 2009; 23: 851–860.
- 6 Richebé P, Capdevila X and Rivat C. **Persistent postsurgical pain: pathophysiology and preventative pharmacologic considerations.** *Anesthesiology* 2018; 129: 590–607.
- 7 Forterre F, Tomek A, Rytz U, et al. **Iatrogenic sciatic nerve injury in eighteen dogs and nine cats (1997–2006).** *Vet Surg* 2007; 36: 464–471.
- 8 Niccolai P, Ouchchane L, Libier M, et al. **Persistent neuropathic pain after inguinal herniorrhaphy depending on the procedure (open mesh v. laparoscopy): a propensity-matched analysis.** *Can J Surg* 2015; 58: 114–120.
- 9 O'Hagan BJ. **Neuropathic pain in a cat post-amputation.** *Aust Vet J* 2006; 84: 83–86.
- 10 Woolf CJ and Mannion RJ. **Neuropathic pain: aetiology, symptoms, mechanisms, and management.** *Lancet* 1999; 353: 1959–1964.
- 11 Robertson SA. **Managing pain in feline patients.** *Vet Clin North Am Small Anim Pract* 2008; 38: 1267–1290.
- 12 Jasińska A, Maslanka T and Jaroszewski JJ. **Pharmacological characteristics of metamizole.** *Pol J Vet Sci* 2014; 17: 207–214.
- 13 Lebkowska-Wieruszewska B, Kim TW, Chea B, et al. **Pharmacokinetic profiles of the two active metabolites of metamizole (dipyrone) in cats following three different routes of administration.** *J Vet Pharmacol Ther* 2018; 41: 334–339.
- 14 Bortolami E and Love EJ. **Practical use of opioids in cats: a state-of-the-art, evidence-based review.** *J Feline Med Surg* 2015; 17: 283–311.
- 15 Hammond R, Macdonald C and Nicholson A. **Opioid analgesics.** In: Maddison JE, Page SW and Church DB (eds). *Small animal clinical pharmacology.* 2nd ed. Edinburgh: WB Saunders, 2008, pp 309–329.
- 16 Berry SH. **Analgesia in the perioperative period.** *Vet Clin North Am Small Anim Pract* 2015; 45: 1013–1027.
- 17 Bortolami E, Murrell JC and Slingsby LS. **Methadone in combination with acepromazine as premedication prior to neutering in the cat.** *Vet Anaesth Analg* 2013; 40: 181–193.

- 18 Slingsby LS, Bortolami E and Murrell JC. **Methadone in combination with medetomidine as premedication prior to ovariohysterectomy and castration in the cat.** *J Feline Med Surg* 2015; 17: 864–872.
- 19 Ambros B, Alcorn J, Duke-Novakovski T, et al. **Pharmacokinetics and pharmacodynamics of a constant rate infusion of fentanyl (5 µg/kg/h) in awake cats.** *Am J Vet Res* 2014; 75: 716–721.
- 20 Epstein ME. **Opioids.** In: Gaynor JS and Muir W (eds). *Handbook of veterinary pain management*. 3rd ed. St Louis, MO: Elsevier Mosby, 2015, pp 161–195.
- 21 Thangamuthu A, Russell IF and Purva M. **Epidural failure rate using a standardized definition.** *Int J Obstet Anesth* 2013; 22: 310–315.
- 22 Troncy E, Junot S, Keroack S, et al. **Results of preemptive epidural administration of morphine with or without bupivacaine in dogs and cats undergoing surgery: 265 cases (1997–1999).** *J Am Vet Med Assoc* 2002; 221: 666–672.
- 23 Kamata M, Nagahama S, Kakishima K, et al. **Comparison of behavioral effects of morphine and fentanyl in dogs and cats.** *J Vet Med Sci* 2012; 74: 231–234.
- 24 Berry. **Injectable anesthetics.** In: Grimm K, Lamont L, Tranquilli W, et al (eds). *Veterinary anesthesia and analgesia: the fifth edition of Lumb and Jones*. Hoboken: John Wiley & Sons, 2015, pp 277–296.
- 25 Schmid RL, Sandler AN and Katz J. **Use and efficacy of low-dose ketamine in the management of acute postoperative pain: a review of current techniques and outcomes.** *Pain* 1999; 82: 111–125.
- 26 Gaynor JS and Muir W. **Alternative drugs and novel therapies used to treat pain.** In: Gaynor JS and Muir W (eds). *Handbook of veterinary pain management*. 3rd ed. St Louis, MO: Elsevier Mosby, 2015, pp 280–301.
- 27 Wagner AE, Walton JA, Hellyer PW, et al. **Use of low doses of ketamine administered by constant rate infusion as an adjunct for postoperative analgesia in dogs.** *J Am Vet Med Assoc* 2002; 221: 72–75.
- 28 Ambros B and Duke T. **Effect of low dose rate ketamine infusions on thermal and mechanical thresholds in conscious cats.** *Vet Anaesth Analg* 2013; 40: e76–82.
- 29 Bermudez E. **Bloqueos de la pared abdominal.** *Revista Chilena de Anestesia* 2011; 40: 230–237.
- 30 Kanazi GE, Aouad MT, Abdallah FW, et al. **The analgesic efficacy of subarachnoid morphine in comparison with ultrasound-guided transversus abdominis plane block after cesarean delivery.** *Anesth Analg* 2010; 111: 475–481.
- 31 Portela DA, Fuensalida SE and Otero PE. **Bloqueo de los nervios de la pared abdominal en el plano del músculo transverso abdominal.** In: Otero PE and Portela DA (eds). *Manual de anestesia regional en animales de compañía: anatomía para bloqueos guiados por ecografía y neuroestimulación*. Buenos Aires: Editorial Intermedica, 2017, pp 248–254.
- 32 Zhang R, Lao L, Ren K, et al. **Mechanisms of acupuncture–electroacupuncture on persistent pain.** *Anesthesiology* 2014; 120: 482–503.
- 33 Taffarel MO and Freitas PMC. **Acupuntura e analgesia: aplicações clínicas e principais acupontos.** *Cienc Rural* 2009; 39: 2665–2672.
- 34 Marques VI, Cassu RN, Nascimento FF, et al. **Laser acupuncture for postoperative pain management in cats.** *Evid Based Complement Alternat Med* 2015: 653270.
- 35 Lascelles BD, Court MH, Hardie EM, et al. **Nonsteroidal anti-inflammatory drugs in cats: a review.** *Vet Anaesth Analg* 2007; 34: 228–250.
- 36 Lowe AD, Campbell KL and Graves T. **Glucocorticoids in the cat.** *Vet Dermatol* 2008; 19: 340–347.
- 37 De Oliveira GS, Jr, Almeida MD, Benzon HT, et al. **Perioperative single dose systemic dexamethasone for postoperative pain: a meta-analysis of randomized controlled trials.** *Anesthesiology* 2011; 115: 575–588.
- 38 Hartmann J, Khanna V, Habib A, et al. **Perioperative systemic glucocorticoids in total hip and knee arthroplasty: a systematic review of outcomes.** *J Orthop* 2017; 14: 294–301.
- 39 Sparkes AH, Heiene R, Lascelles BD, et al. **ISFM and AAEP consensus guidelines: long-term use of NSAIDs in cats.** *J Feline Med Surg* 2010; 12: 521–538.
- 40 Gowan RA, Baral RM, Lingard AE, et al. **A retrospective analysis of the effects of meloxicam on the longevity of aged cats with and without overt chronic kidney disease.** *J Feline Med Surg* 2012; 14: 876–881.
- 41 Gunew MN, Menrath VH and Marshall RD. **Long-term safety, efficacy and palatability of oral meloxicam at 0.01–0.03 mg/kg for treatment of osteoarthritic pain in cats.** *J Feline Med Surg* 2008; 10: 235–241.
- 42 Gowan RA, Lingard AE, Johnston L, et al. **Retrospective case-control study of the effects of long-term dosing with meloxicam on renal function in aged cats with degenerative joint disease.** *J Feline Med Surg* 2011; 13: 752–761.
- 43 Oakley MJ, Smith JS, Anderson JR, et al. **Randomized placebo-controlled trial of local anaesthetic infusion in day-case inguinal hernia repair.** *Br J Surg* 1998; 85: 797–799.
- 44 Abelson AL, McCobb EC, Shaw S, et al. **Use of wound soaker catheters for the administration of local anesthetic for post-operative analgesia: 56 cases.** *Vet Anaesth Analg* 2009; 36: 597–602.
- 45 Grubb T. **What do we really know about the drugs we use to treat chronic pain?** *Top Companion Anim Med* 2010; 25: 10–19.
- 46 Lamont LA. **Adjunctive analgesic therapy in veterinary medicine.** *Vet Clin North Am Small Anim Pract* 2008; 38: 1187–1203.
- 47 Steagall PV and Monteiro-Steagall BP. **Multimodal analgesia for perioperative pain in three cats.** *J Feline Med Surg* 2013; 15: 737–743.
- 48 Wagner AE, Mich PM, Uhrig ST, et al. **Clinical evaluation of perioperative administration of gabapentin as an adjunct for postoperative analgesia in dogs undergoing amputation of a forelimb.** *J Am Vet Med Assoc* 2010; 236: 751–756.
- 49 Aghighi SA, Tipold A, Piechotta M, et al. **Assessment of the effects of adjunctive gabapentin on postoperative pain after intervertebral disc surgery in dogs.** *Vet Anaesth Analg* 2012; 39: 636–646.
- 50 Crociolli GC, Cassu RN, Barbero RC, et al. **Gabapentin as an adjuvant for postoperative pain management in dogs undergoing mastectomy.** *J Vet Med Sci* 2015; 77: 1011–1015.

- 51 Steagall PV, Benito J, Monteiro BP, et al. **Analgesic effects of gabapentin and buprenorphine in cats undergoing ovariohysterectomy using two pain-scoring systems: a randomized clinical trial.** *J Feline Med Surg* 2018; 20: 741–748.
- 52 Lorenz ND, Comerford EJ and Iff I. **Long-term use of gabapentin for musculoskeletal disease and trauma in three cats.** *J Feline Med Surg* 2013; 15: 507–512.
- 53 KuKanich B. **Outpatient oral analgesics in dogs and cats beyond nonsteroidal antiinflammatory drugs.** *Vet Clin North Am Small Anim Pract* 2013; 43: 1109–1125.
- 54 Esteban MA, Dewey CW, Schwark WS, et al. **Pharmacokinetics of single-dose oral pregabalin administration in normal cats.** *Front Vet Sci* 2018; 5: 136. DOI: 10.3389/fvets.2018.00136.
- 55 Pypendop BH, Siao KT and Ilkiw JE. **Effect of tramadol hydrochloride on the thermal threshold in cats.** *Am J Vet Res* 2009; 70: 1465–1470.
- 56 Evangelista MC, Silva RA, Cardozo LB, et al. **Comparison of preoperative tramadol and pethidine on postoperative pain in cats undergoing ovariohysterectomy.** *BMC Vet Res* 2014; 10: 252. DOI: 10.1186/s12917-014-0252-1.
- 57 Cagnardi P, Villa R, Zonca A, et al. **Pharmacokinetics, intraoperative effect and postoperative analgesia of tramadol in cats.** *Res Vet Sci* 2011; 90: 503–509.
- 58 Pypendop BH and Ilkiw JE. **Pharmacokinetics of tramadol, and its metabolites O-desmethyl-tramadol, in cats.** *J Vet Pharmacol Ther* 2008; 31: 52–59.