

An evaluation of methods for distinguishing between juvenile and adult mountain hares *Lepus timidus*

Authors: Kauhala, Kaarina, and Soveri, Timo

Source: Wildlife Biology, 7(4) : 295-300

Published By: Nordic Board for Wildlife Research

URL: <https://doi.org/10.2981/wlb.2001.028>

The BioOne Digital Library (<https://bioone.org/>) provides worldwide distribution for more than 580 journals and eBooks from BioOne's community of over 150 nonprofit societies, research institutions, and university presses in the biological, ecological, and environmental sciences. The BioOne Digital Library encompasses the flagship aggregation BioOne Complete (<https://bioone.org/subscribe>), the BioOne Complete Archive (<https://bioone.org/archive>), and the BioOne eBooks program offerings ESA eBook Collection (<https://bioone.org/esa-ebooks>) and CSIRO Publishing BioSelect Collection (<https://bioone.org/csiro-ebooks>).

Your use of this PDF, the BioOne Digital Library, and all posted and associated content indicates your acceptance of BioOne's Terms of Use, available at www.bioone.org/terms-of-use.

Usage of BioOne Digital Library content is strictly limited to personal, educational, and non-commercial use. Commercial inquiries or rights and permissions requests should be directed to the individual publisher as copyright holder.

BioOne is an innovative nonprofit that sees sustainable scholarly publishing as an inherently collaborative enterprise connecting authors, nonprofit publishers, academic institutions, research libraries, and research funders in the common goal of maximizing access to critical research.

An evaluation of methods for distinguishing between juvenile and adult mountain hares *Lepus timidus*

Kaarina Kauhala & Timo Soveri

Kauhala, K. & Soveri, T. 2001: An evaluation of methods for distinguishing between juvenile and adult mountain hares *Lepus timidus*. - Wildl. Biol. 7: 295-300.

Different age determination methods were compared to find a practical method for distinguishing between young and adult mountain hares *Lepus timidus*. The age of the hares was determined using: 1) the ossification stage of the radius and ulna, and 2) the dry weight of the eye lens. The ossification stage of the bones was examined with the unaided eye and palpation, and by using radiography. The proportion of young was higher when the bones were examined using radiography rather than the unaided eye, except in early autumn when the two methods led to the same results. Age determination based on bone examination using the unaided eye gave more reliable results than age determination based on radiography; this became evident when the results were compared with the reproductive status of females or with the dry weight of the eye lens. Using an eye lens weight of 0.25 g as a discriminating value between young and adult hares, gave an age determination similar to that derived from bone examinations using the unaided eye in 90% of the cases. Age determination based on examination of the radius and ulna using the unaided eye and palpation, together with the eye lens weight thus forms a reliable and practical method for distinguishing between young and adult mountain hares, and radiography is only necessary when examining live animals.

Key words: age determination, eye lens, *Lepus timidus*, mountain hare, radius, ulna

Kaarina Kauhala, Finnish Game and Fisheries Research Institute, P.O. Box 6, FIN-00721 Helsinki, Finland - e-mail: kaarina.kauhala@rktl.fi
Timo Soveri, Section of Veterinary Physiology, Department of Basic Veterinary Sciences, Faculty of Veterinary Medicine, P.O. Box 57, FIN-00014 Helsinki University, Finland

Received 23 March 2000, accepted 15 January 2001

Associate Editor: Paolo Cavallini

Although the mountain hare *Lepus timidus* is an important game species in Finland, little is known of its population dynamics and factors affecting hare numbers. Age determination, especially distinguishing between 'young'

(<1 year old) and 'adult' (≥1 year old) individuals, is essential for population ecology studies. Large samples of hares are needed to calculate the age structure of the population, and hence, a rapid method for age determi-

nation is required. The proportion of young individuals in the autumn population can also be used as an indicator of the reproductive success of a hare population during the previous summer.

Broekhuizen (1971) and Soveri, Aarnio & Kärkkäinen (1986) used the ossification stage of the radius and ulna for identifying young and adult hares and radiographed the bones for age determination. Walhovd (1965) used the ossification stage of humeri for age determination in mountain hares. Kauhala & Helle (1990) also used the ossification stage of the radius and ulna for determining the age of raccoon dogs *Nyctereutes procyonoides*, but they examined boiled and cleaned bones with the unaided eye. This proved to be a rapid and reliable method for distinguishing between young and adult raccoon dogs, especially in autumn.

The dry weight of the eye lens has also been used for age determination in mammals, because the mass of the lens steadily increases during the lifetime of an animal (Lord 1959, Broekhuizen & Maaskamp 1979, Morris 1972). Walhovd (1965) and Flux (1970) used eye lens weight to identify young and adult mountain hares, and Andersen & Jensen (1972) used it to separate young European hares *L. europaeus* from adult individuals.

The aim of the present study was to compare three different methods, i.e. 1) radiography of the radius and ulna, 2) examination of the radius and ulna using the unaided eye and palpation, and 3) weighing the eye lens, which can be used to distinguish young from adult mountain hares, and to find a rapid and reliable method, or combination of methods, for practical use in age determination.

Material and methods

Hare samples were collected from hunters throughout southern and central Finland (20–30°E, 60–65°N) during September 1998 – February 1999 and during September–December 1999. Most samples came from the provinces of Oulu (northern parts of central Finland), Häme and Satakunta (southern Finland) and Keski-Suomi (central Finland). Most hares were caught with hounds.

The age of the hares was determined from the ossification stage of the distal epiphyseal cartilage of the radius and ulna and was compared with the dry weight of the eye lens and also with the presence of placental scars in females. The presence of placental scars was taken as proof that the animal was ≥ 1 year of age, because mountain hares are not known to give birth until their second year (Iason 1990).

Growth occurs in the cartilaginous region near the end of the long bones (Weinmann & Sicher 1955). In very young hares (< 6 months) the terminal part of the bone (the epiphysis) is only loosely fused to the rest of the bone, but when growth ceases the epiphyseal cartilage ossifies and the terminal part becomes solidly fused to the rest of the bone. An epiphyseal line is frequently seen at the site of the recently ossified epiphyseal cartilage (Soveri et al. 1986). The ossification stage of the epiphyseal cartilage can thus be used to separate young from adult individuals, especially in autumn (Stroh 1931, Morris 1972, Broekhuizen & Maaskamp 1979, Soveri et al. 1986).

The forelegs of hares were detached and frozen, and the radius and ulna were subsequently boiled for three hours to separate the flesh from the bones. The bones of 176 hares were examined using both 1) the unaided eye and palpation and 2) radiography (Table 1). When the bones were examined with the unaided eye, they were classified into two groups: young (<1 year old) and adult (≥ 1 year old). The hares were classified as young if the terminal part of the bone was loosely fused to the rest of the bone or if an epiphyseal line was clearly seen and could be felt when the bone was palpated (the bone felt rough). The animal was classified as adult when the epiphyseal line could not be seen or was weak (the bone felt smooth).

When the bones were radiographed, they were classified into five groups: Group 1 = young with an epiphyseal cartilage, Group 2 = young with a recently ossified epiphyseal cartilage, but an epiphyseal line clearly visible, Group 3 = uncertain young (epiphyseal line could be seen), Group 4 = uncertain adult (epiphyseal line weak) and Group 5 = adult (epiphyseal line had disappeared or was very weak). A veterinarian (T. Soveri) did the age determination based on radiography without knowing the results of age determination obtained using the unaided eye and palpation done by a zoologist (K. Kauhala).

The eyes of 103 hares were detached less than two hours after death and preserved in 10% formalin for two weeks. The eye lens was then removed, cleaned and air-

Table 1. The number of hares used when different methods of age determination were compared: 1) age determined using bones examined with the unaided eye where compared with age determination using bones examined with radiography and 2) with age determined using the dry weight of the eye lens, and 3) age determined using bones examined with radiography where compared with age determined using the dry weight of the eye lens.

	X-ray	Eye lens
Unaided eye	176 ¹	256 ²
X-ray		101 ³

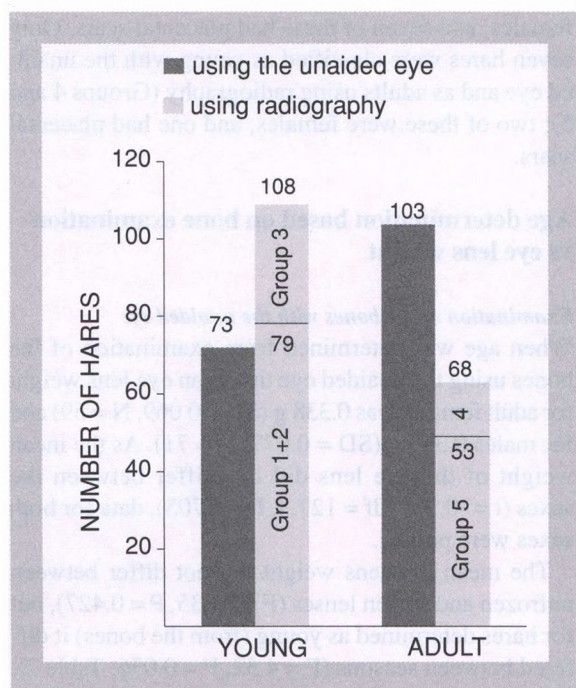


Figure 1. Number of young and adult mountain hares identified using the ossification stage of the radius and ulna. Age determination was performed using both the unaided eye and palpation, and radiography. See text for definition of age group classifications of radiographed hares.

dried for one hour at room temperature and then dried for 1.5 hours in the oven (70°C), according to the method described by Friend (1968) and Morris (1972). The heads of 163 hares were initially frozen, because not all hunters could remove the eyes in the field. The eyes were removed after 1–6 weeks in the freezer and then treated as described above. The lenses were weighed to the nearest 0.0001 g, and the lens weight was compared with the age determination obtained through bone examination (256 hares examined using the unaided eye and 101 examined using radiography).

Table 2. Eye lens dry weights (g) for mountain hares according to age group using the ossification stage of the radius and ulna, examined with either the unaided eye and palpation or radiography. The number given for hares determined as young but carrying placental scars indicates errors in age determination.

Group	Mean	SD	N	Weight		With placental scars
				Min	Max	
Unaided eye						
Young, all	0.147	0.069	126	0.010	0.380	1
Killed in:						
September-October	0.140	0.078	76	0.010	0.380	1
November-December	0.142	0.045	34	0.060	0.230	
January-February	0.194	0.045	16	0.140	0.280	
Adult	0.341	0.073	130	0.150	0.490	

Radiographs						
Group 1	0.129	0.054	33	0.030	0.230	0
Group 2	0.262	0.108	17	0.060	0.470	8
Group 3	0.332	0.080	16	0.180	0.430	7
Group 4	0.323	0.081	6	0.220	0.390	
Group 5	0.332	0.074	29	0.160	0.480	

The eye lens weights were compared using Student's t-test and ANOVA with Bonferroni as a *post hoc* test. The Pearson χ^2 -test was used to compare the age structures obtained using the different methods.

Results

Age determination based on bone examination using the unaided eye vs radiography

A total of 73 out of 176 hares (41.5%) were determined as young with the unaided eye, while 79 (44.9%) were determined as young (Groups 1+2) using radiography ($t = 0.64$, NS). Additionally, 29 hares were classified as 'uncertain young' (Group 3) using radiography (Fig. 1). If these were included in the category 'young', the proportion of young would be 61.4%, and the difference between the results obtained using the two methods would be significant ($t = 3.76$, $P < 0.001$). In early autumn (September–October) the proportion of young was 47.5% (19/40) when age was determined using the unaided eye, and 50.0% (20/40) when using radiography, including the uncertain cases ($t = 0.24$, NS). In late autumn and winter (November–February) the corresponding figures were 40.2% and 64.4% ($t = 3.94$, $P < 0.001$).

The proportion of young was 50.3% for females ($N = 169$) and 48.0% for males ($N = 204$) when the bones were examined with the unaided eye ($\chi^2 = 0.188$, $df = 1$, $P = 0.664$). The corresponding figures were 67.1% and 56.0% when radiography was used ($\chi^2 = 8.066$, $df = 4$, $P = 0.089$).

A total of 66 individual hares were classified as young and 61 as adult by both methods (both categories included the 'uncertain' categories determined using radiography). Both methods thus led to the same classification in 72.2% (127/176) of the cases. If the uncertain

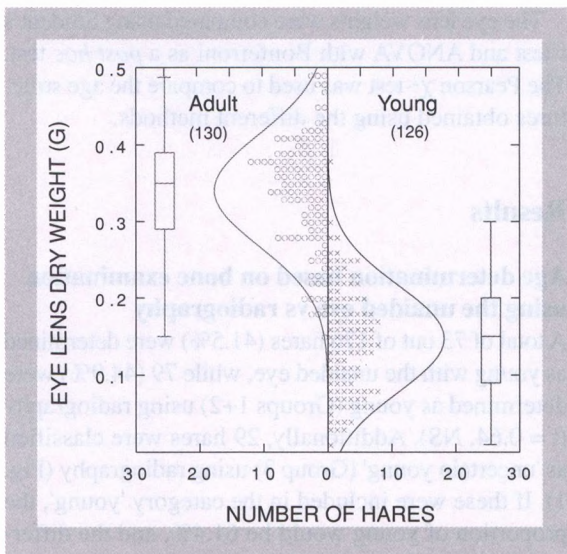


Figure 2. Eye lense dry weight of mountain hares determined as either young or adults using the ossification stage of the radius and ulna, and examined with the unaided eye and palpation. Mean, SD, range and sample size are also given.

cases were excluded from the data, 85.4% (111/130) were classified similarly with the two methods.

In 16 cases the hare was determined as an adult with the unaided eye and as young (Group 2) using radiography. Of the 16 hares, nine were females and eight of these had placental scars, indicating that they were ≥ 1 year of age. Furthermore, 26 hares were classified as adults with the unaided eye, but as uncertain young (Group 3) using radiography. Of the 26 hares, 10 were

females, and seven of these had placental scars. Only seven hares were classified as young with the unaided eye and as adults using radiography (Groups 4 and 5); two of these were females, and one had placental scars.

Age determination based on bone examination vs eye lens weight

Examination of the bones with the unaided eye

When age was determined from examination of the bones using the unaided eye the mean eye lens weight for adult females was 0.338 g (SD = 0.069, N = 59) and for males 0.343 g (SD = 0.077, N = 71). As the mean weight of the eye lens did not differ between the sexes ($t = -0.379$, $df = 127.3$, $P = 0.705$), data for both sexes were pooled.

The mean eye lens weight did not differ between unfrozen and frozen lenses ($F = 0.635$, $P = 0.427$), but for hares determined as young (from the bones) it differed between seasons ($F = 4.52$, $P = 0.036$; Table 2). The mean eye lens weight in early autumn (September-October) did not differ from that in late autumn (November-December; Bonferroni *post hoc* test: $P = 1.00$), but the mean weight in winter (January-February) was higher than in early or late autumn (early autumn-winter: $P = 0.039$, late autumn-winter: $P = 0.012$).

The mean weight of the eye lens was 0.147 g for hares determined as young from bones, and 0.341 g for hares determined as adults ($t = 21.746$, $df = 253.8$, $P < 0.001$; Fig. 2, see Table 2). Only one of the hares determined

Table 3. Eye lens dry weight for mountain hares grouped according to age determination based on the ossification stage of the radius and ulna, using either the unaided eye or radiography. * indicates that placental scars were present.

Lens weight (g)	Age from bones				
	Young	Adult			
Unaided eye (all hares)					
< 0.20	94	5			
0.20-0.22	13	7			
0.23-0.25	13	7			
0.26-0.28	4	11			
0.29-0.30	1	7			
> 0.30	1*	93			
Unaided eye (excluding hares killed in January-February)					
< 0.20	86	4			
0.20-0.22	9	6			
0.23-0.25	11	6			
0.26-0.28	2	9			
0.29-0.30	1	5			
> 0.30	1*	71			

Radiographs	Group				
	1	2	3	4	5
< 0.20	29	4	1	0	2
0.20-0.22	2	2	2	2	1
0.23-0.25	2	1	1	0	1
0.26-0.28	0	3	0	0	4
0.29-0.30	0	2	0	0	1
> 0.30	0	5	12	4	20

as young from bones had placental scars and a heavy eye lens (0.38 g; Tables 2-3), indicating incorrect age determination.

Of hares determined as adults from bones using the unaided eye five had an eye lens weight of less than 0.20 g (see Fig. 2 and Table 3), whereas only one which had an eye lens weight of more than 0.30 g was determined as young (but had placental scars). In total 14.6% (19/130) of hares determined as adults from the bones, had an eye lens weight of ≤ 0.25 g, and 4.8% (6/126) of hares determined as young from the bones, had an eye lens weight of >0.25 g. If 0.25 g was used as a discriminating value between young and adult hares, 90.2% (231/256) of all cases would be similarly classified as young or adult with both methods. Both methods also gave a similar picture of the proportion of young in different months (Fig. 3).

Examination of the bones using radiography

When age was determined using radiography, the eye lens weight differed among the five groups ($F = 34.82$, $df = 4,96$, $P < 0.001$; see Table 2). Group 1 differed from all others ($P < 0.001$ for all), and Group 2 also differed from Group 5 (Bonferroni *post hoc* test: $P = 0.036$). Groups 3-5 did not differ from each other.

Of hares determined as adult using radiography two had an eye lens weight of less than 0.20 g (see Table 3). A total of 17 hares with an eye lens weight of more than 0.30 g were determined as 'young' or 'uncertain young' using radiography.

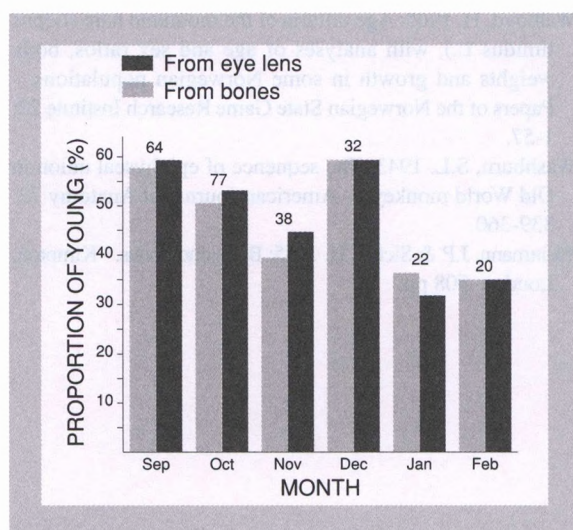


Figure 3. Proportion of young hares (in %) determined using the ossification stage of the radius and ulna, and examined with the unaided eye and palpation, and from the eye lens dry weight (0.25 g as a discriminating value between young and adult) in different months. The sample size for each month is given above the columns.

Discussion

Age determination based on examination of the cleaned bones using the unaided eye and palpation proved to be the most favourable method for distinguishing between juvenile and adult mountain hares, as this method is both rapid and reliable. When the results obtained using this method were compared with the reproductive status of the females (presence of placental scars), we found only one evident mistake. Although it is difficult to separate young from adults when examining the bones using the unaided eye only, the difference can be felt with the fingers; the distal end of the bone is smooth if growth has entirely ceased (adult), but rough if the hare is still growing or its growth has recently ceased (young).

When the results of this method were compared to the results obtained using the dry weight of the eye lens, both methods gave similar result in 90% of the cases, when using an eye lens weight of 0.25 g as a discriminating value between young and adult. Walhovd (1965), who studied mountain hares in Norway, also concluded that hares with an eye lens weight of less than about 0.25 g were <1 year of age. Flux (1970) reported that the eye lens weight of young mountain hares in Scotland was <0.235 g. Walhovd (1965) found no overlap in the eye lens weight between the two age groups in mountain hares and neither did Andersen & Jensen (1972) in European hare, whereas some overlap was found in our study. One reason for this may be that the age determination based on bone examination was incorrect in some cases, especially in January and February.

Although radiography appeared to be a better method for age determination than palpation of the radius and ulna of untreated mountain hare forelimbs (Soveri et al. 1986), examining the cleaned bones with the unaided eye and palpation was even better. If the ossification line can still be seen in some adults, it is very difficult to separate the young from adult individuals using radiography. Kauhala & Helle (1990) also found that in raccoon dogs age determination based on examination of the radius and ulna using the unaided eye and palpation produced more favourable results than radiography; the epiphyseal line was sometimes also visible in adults, which was confusing and resulted in overestimation of the proportion of young.

Age determination based on radiography also differed to some extent from age determination based on the eye lens weight; 17 hares with an eye lens weight of more than 0.30 g were determined as young using radiography. This also points to the conclusion that determining the age using radiography results in overestimation of the proportion of young individuals; e.g. Morris

(1972) concluded that radiography is the most favourable method, but he did not use examination and palpation of cleaned bones.

Hares belonging to Groups 2 and 3, as judged from radiographs, were most problematic; many of these had placental scars, indicating that they actually were adults, because no female mountain hare has been recorded to breed in the summer of her birth (Flux 1970, Iason 1990). The sensitivity of radiography appears to be favourable but specificity becomes poor quite soon after ossification. The hares killed in early autumn posed no problem, but age determination became more difficult towards winter when growth of the young ceased. According to this and to results of eye lens weights, it would be reasonable to divide the animals under radiographical examination into three groups: 1 and 2 as described (young) and 3 (including Groups 3, 4 and 5; adults) as was done in Soveri et al. (1986).

The mean weight of the eye lenses was not affected by the treatment (freezing or unfreezing) and hence eye lens weight can be used to distinguish between young and adult hares even when it is not possible to remove the eyes immediately after the death of the animal in the field. The heads can be frozen and the eyes removed later in the laboratory. The heads should, however, be frozen as soon as possible after the death of the animal. Selecting an eye lens weight of 0.25 g as a discriminating value gave the best fit with the age determination based on bone examination using the unaided eye (see Table 3).

In conclusion, age determination based on the ossification stage of the distal radius and ulna using the unaided eye and palpation is a reliable and rapid method for distinguishing between young and adult mountain hares. The proximal humerus might be even better because it ossifies later than the distal radius and ulna (Washburn 1943). Combining age determination based on bone examination and eye lens weight gives even more reliable results. Although radiography is a quite reliable method in early autumn, it is unnecessary and does not provide a more accurate age determination. The only advantages of radiography are that it can be used to examine live animals, and that it can be used when a rapid and easy method for examining untreated forelimbs is required in autumn.

Acknowledgements - we are grateful to the hunters who sent us hare samples. M. Hiltunen and R. Koivunen treated and weighed the eye lenses. H. Lindén read the manuscript and gave valuable comments on it. The Academy of Finland gave financial support.

References

- Andersen, J. & Jensen, B. 1972: The weight of the eye lens in the European hares of known age. - *Acta Theriologica* 17: 87-92.
- Broekhuizen, S. 1971: Age determination and age composition of hare populations. - *Transactions of the International Congress of Game Biologists* 10: 477-489.
- Broekhuizen, S. & Maaskamp, F. 1979: Age determination in the European hare (*Lepus europaeus* Pallas) in the Netherlands. - *Zeitschrift für Säugetierkunde* 44: 162-175.
- Flux, J.E.C. 1970: Life history of the mountain hare (*Lepus timidus scoticus*) in north-east Scotland. - *Journal of Zoology* (London) 161: 75-123.
- Friend, M. 1968: The lens technique. - *Transactions of the 33rd North American Wildlife and Natural Resources Conference* 33: 279-298.
- Iason, G.R. 1990: The effects of size, age and a cost of early breeding on reproduction in female mountain hares. - *Holarctic Ecology* 13: 81-89.
- Kauhala, K. & Helle, E. 1990: Age determination of the raccoon dog in Finland. - *Acta Theriologica* 35: 321-329.
- Lord, R.D. 1959: The lens as an indicator of age in cottontail rabbits. - *Journal of Wildlife Management* 23: 358-360.
- Morris, P. 1972: A review of mammalian age determination methods. - *Mammal Review* 2: 69-103.
- Soveri, T., Aarnio, M. & Kärkkäinen, M. 1986: Kynär- ja värtinälüun kasvurusto jänisten iänmäärittämisessä. (In Finnish with English summary: The epiphyseal cartilage of the radius and ulna as an age indicator for hares). - *Suomen Riista* 33: 26-30.
- Stroh, G. 1931: Zwei sichere Altersmerkmale beim Hasen. - *Berliner Tierärztliche Wochenschrift* 47: 180-181. (In German).
- Walhovd, H. 1965: Age criteria of the mountain hare (*Lepus timidus* L.), with analyses of age and sex ratios, body weights and growth in some Norwegian populations. - *Papers of the Norwegian State Game Research Institute* 22: 1-57.
- Washburn, S.L. 1943: The sequence of epiphyseal union in Old World monkeys. - *American Journal of Anatomy* 72: 339-360.
- Weinmann, J.P. & Sicher, H. 1955: Bone and bones. - Kimpton, London, 508 pp.