

Frenkelia sp.-like Infection in the Small Intestine of a Red-tailed Hawk

Authors: Lindsay, David S., Ambrus, Sandra I., and Blagburn, Byron L.

Source: Journal of Wildlife Diseases, 23(4) : 677-679

Published By: Wildlife Disease Association

URL: <https://doi.org/10.7589/0090-3558-23.4.677>

BioOne Complete (complete.BioOne.org) is a full-text database of 200 subscribed and open-access titles in the biological, ecological, and environmental sciences published by nonprofit societies, associations, museums, institutions, and presses.

Your use of this PDF, the BioOne Complete website, and all posted and associated content indicates your acceptance of BioOne's Terms of Use, available at www.bioone.org/terms-of-use.

Usage of BioOne Complete content is strictly limited to personal, educational, and non - commercial use. Commercial inquiries or rights and permissions requests should be directed to the individual publisher as copyright holder.

BioOne sees sustainable scholarly publishing as an inherently collaborative enterprise connecting authors, nonprofit publishers, academic institutions, research libraries, and research funders in the common goal of maximizing access to critical research.

***Frenkelia* sp.-like Infection in the Small Intestine of a Red-tailed Hawk**

David S. Lindsay, Sandra I. Ambrus, and Byron L. Blagburn, Department of Pathology and Parasitology, College of Veterinary Medicine, Auburn University, Alabama 36849, USA

ABSTRACT: Developmental stages of a *Frenkelia* sp.-like coccidium were observed in tissue sections of the duodenum, jejunum, and ileum of a naturally infected red-tailed hawk (*Buteo jamaicensis borealis*) that died and was examined at necropsy. Developmental stages were located in the lamina propria of these tissues. Thirty sporulated sporocysts measured $11.1 \times 8.1 \mu\text{m}$ in tissue sections. Four sporozoites were present in each sporulated sporocyst. The coccidial infection was not a contributing factor in the death of this red-tailed hawk.

Key words: *Frenkelia* sp., *Sarcocystis* sp., *Isospora buteonis*, red-tailed hawk, *Buteo jamaicensis borealis*.

Henry (1932) described *Isospora buteonis* from two red-tailed hawks (*Buteo borealis*), a Swainson's hawk (*Buteo swainsoni*), a Cooper's hawk (*Accipiter cooperi*), and a short-eared owl (*Asio flammeus*) from California. The oocysts of this species sporulate endogenously to form two sporocysts each containing four sporozoites. Therefore, it is either a species of *Sarcocystis* or *Frenkelia*.

Rommel and Krampitz (1975) demonstrated that *I. buteonis*-like sporocysts from buzzards (*Buteo buteo*) were actually those of *Frenkelia glareoli* (= *F. clethrionomyobuteonis*). They demonstrated also that *F. glareoli* was apparently host specific for the definitive host (*B. buteo*) because the brains of experimentally infected bank voles (*Clethrionomys glareolus*) were not infectious for three European kestrels (*Falco tinnunculus*), a goshawk (*Accipiter gentilis*), four long-eared owls (*Asio otus*), a barn owl (*Tyto alba*), and four tawny owls (*Strix aluco*). Dubey (1977) believed that *I. buteonis* should be combined with *F. glareoli* to form *F. buteonis*. However, perhaps this is premature because there are no experimental transmission data

available that indicate that *I. buteonis*-like sporocysts isolated from *B. borealis*, *B. swainsoni*, *Accipiter cooperi* or *Asio flammeus* are actually a species of *Frenkelia*. These birds are not reported to serve as definitive hosts for a *Sarcocystis* species (Levine and Tadros, 1980; Cawthorn et al., 1984; Levine, 1986).

The present study reports intestinal infection of a red-tailed hawk (*Buteo jamaicensis borealis*) with a coccidium that sporulates endogenously to form oocysts containing two sporocysts each with four sporozoites. Because there is no way to differentiate *Sarcocystis* spp. from *Frenkelia* spp. in the definitive host, we will refer to the coccidium observed in the present study as a *Frenkelia* sp.-like coccidium.

In October 1986, an immature red-tailed hawk was submitted to the Auburn University Raptor Rehabilitation Center (College of Veterinary Medicine, Auburn University, Alabama 36849, USA). The hawk died approximately 3 hr after submission; the 550 g carcass was emaciated. Portions of brain, pectoralis muscle, trachea, lung, gizzard, kidney, liver, duodenum, jejunum, ileum, and colon were obtained at necropsy, fixed in 10% neutral-buffered formalin, and processed for routine light microscopic examination.

Examination of all small intestinal tissues revealed numerous sporulated sporocysts of a *Frenkelia* sp.-like coccidium in the lamina propria (Fig. 1). The oocyst wall surrounding the sporocysts was very thin and membrane-like. A few macrogamonts and unsporulated and sporulating oocysts were observed also. Microgamonts and asexual stages were not observed. Sporocysts were concentrated in the lamina propria within the distal three-fourths of

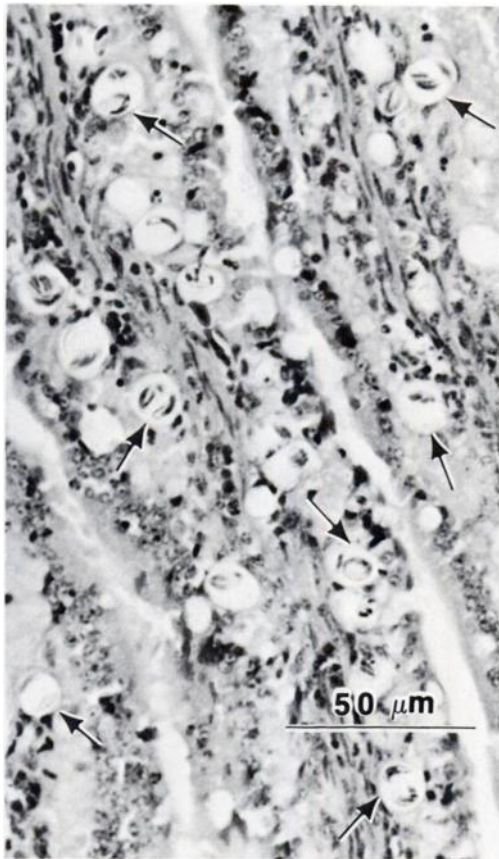


FIGURE 1. Histological section of the small intestine from a red-tailed hawk infected with a *Frenkelia* sp.-like coccidium. The lamina propria of the villi contain numerous cells infected with sporulated sporocysts (several are labeled with arrows), H&E stain.

the villi; they were observed rarely in the tunica propria of the crypts. Developmental stages were not observed in enterocytes. All the villi that were examined had parasites. Thirty sporocysts that were not collapsed by fixation or embedding measured $10.0\text{--}12.0 \times 7.0\text{--}9.0 \mu\text{m}$ ($\bar{x} = 11.1 \pm 0.12 \times 8.1 \pm 0.07 \mu\text{m}$, mean length/width ratio = 1.4). Sporocysts each contained four sporozoites and neither a Stieda body nor a sporocyst residuum were observed. An inflammatory response was not associated with the presence of this *Frenkelia* sp.-like coccidium in the lamina propria.

Parasites were not observed in the colon or in the extraintestinal tissues examined.

Acute, necrotizing myositis and marked diffuse atrophy of myofibers were observed in sections of the pectoralis muscle. Injury to the breast muscles with resultant starvation was considered to be the cause of death. Our interpretation was that infection with the *Frenkelia* sp.-like coccidium was not a contributing factor in the death of this hawk. However, intestinal infection by some *Sarcocystis* spp. may cause clinical disease in avian hosts (Cawthorn et al., 1984).

The measurements of *I. buteonis* sporocysts ($9.6\text{--}13.0 \times 8.0\text{--}10.4 \mu\text{m}$) given by Henry (1932) are similar to those observed in the present study. Henry (1932) observed a prominent sporocyst residuum in the sporocysts of *I. buteonis* she examined, but this was not observed in the *Frenkelia* sp.-like coccidium in the present study. She also believed that the infection was limited to the duodenum, whereas in the present study the infection was found throughout the small intestine.

Further studies are needed to determine the taxonomic status of the *Frenkelia* sp.-like coccidium infecting red-tailed hawks. Present knowledge of coccidian life cycles indicates that *B. borealis*, *B. swainsoni*, and *Accipiter cooperi* might be the definitive hosts for the same species of coccidium. However, it is unlikely that *Asio flammeus* would be a definitive host for this species.

This paper is College of Veterinary Medicine publication number 1888.

LITERATURE CITED

- CAWTHORN, R. J., A. A. GAJADHAR, AND R. J. BROOKS. 1984. Description of *Sarcocystis rauschorum* sp. n. (Protozoa: Sarcocystidae) with experimental cyclic transmission between varying lemmings (*Dicrostonyx richardsoni*) and snowy owls (*Nyctea scandiaca*). *Canadian Journal of Zoology* 62: 217–225.
- DUBEY, J. P. 1977. *Toxoplasma*, *Hammondia*, *Besnoitia*, *Sarcocystis* and other tissue cyst-forming coccidia of man and animals. In *Parasitic protozoa*, Vol. III, J. P. Kreier (ed.). Academic Press, New York, New York, pp. 101–237.
- HENRY, D. P. 1932. *Isopora buteonis* sp. nov. from

- the hawk and owl, and notes on *Isospora lacazii* (Labbé) in birds. University of California Publications in Zoology 37: 291–299.
- LEVINE, N. D. 1986. The taxonomy of *Sarcocystis* (Protozoa, Apicomplexa) species. The Journal of Parasitology 72: 372–382.
- , AND W. TADROS. 1980. Named species and hosts of *Sarcocystis* (Protozoa: Apicomplexa: Sarcocystidae). Systematic Parasitology 2: 41–59.
- ROMMEL, M., AND H. E. KRAMPITZ. 1975. Beiträge zum Lebenszyklus der Frenkelien. I. Die Identität von *Isospora buteonis* aus dem Mäusebusard mit einer Frenkelienart (*F. clethrionomyobuteonis* spec. n.) aus der Rötelmaus. Berliner und Münchener Tierärztliche Wochenschrift 88: 338–340.

Received for publication 12 December 1986.