

## **Knemidokoptes mutans (Acari: Knemidocoptidae) in a Great-horned Owl (Bubo virginianus)**

Authors: Schulz, Terry A., Stewart, James S., and Fowler, Murray E.

Source: Journal of Wildlife Diseases, 25(3) : 430-432

Published By: Wildlife Disease Association

URL: <https://doi.org/10.7589/0090-3558-25.3.430>

---

BioOne Complete ([complete.BioOne.org](https://complete.BioOne.org)) is a full-text database of 200 subscribed and open-access titles in the biological, ecological, and environmental sciences published by nonprofit societies, associations, museums, institutions, and presses.

Your use of this PDF, the BioOne Complete website, and all posted and associated content indicates your acceptance of BioOne's Terms of Use, available at [www.bioone.org/terms-of-use](https://www.bioone.org/terms-of-use).

Usage of BioOne Complete content is strictly limited to personal, educational, and non - commercial use. Commercial inquiries or rights and permissions requests should be directed to the individual publisher as copyright holder.

---

BioOne sees sustainable scholarly publishing as an inherently collaborative enterprise connecting authors, nonprofit publishers, academic institutions, research libraries, and research funders in the common goal of maximizing access to critical research.

## ***Knemidokoptes mutans* (Acari: Knemidocoptidae) in a Great-horned Owl (*Bubo virginianus*)**

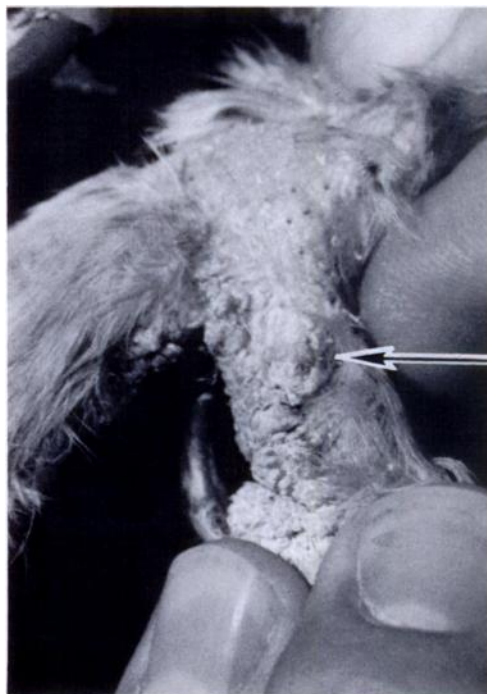
**Terry A. Schulz,<sup>1</sup> James S. Stewart,<sup>2</sup> and Murray E. Fowler,<sup>2</sup>** <sup>1</sup>University of California, Davis Raptor Center; <sup>2</sup>Zoological Medicine Service, Veterinary Medical Teaching Hospital, School of Veterinary Medicine, University of California, Davis, California 95616, USA

**ABSTRACT:** A routine examination of a captive juvenile great-horned owl (*Bubo virginianus*) revealed bilateral proliferative papillary hyperkeratosis on the feet. Microscopic examination of skin scrapings produced numerous mites identified as *Knemidokoptes mutans*. This is the first record of this parasite in a great-horned owl. A single dose of ivermectin (200 µg/kg) was effective in treatment of this infection.

**Key words:** Great-horned owl, *Bubo virginianus*, *Knemidokoptes mutans*, ivermectin, proliferative papillary hyperkeratosis, case report.

A juvenile great-horned owl (*Bubo virginianus*) was found in a weakened condition in Greenfield, Monterey County, California, USA (36°21'N, 121°15'W) on 21 April 1986 and brought to the Monterey Society for the Prevention of Cruelty to Animals (SPCA, P.O. Box 3058, Monterey, California 93940, USA). The owl was transferred to the School of Veterinary Medicine (University of California, Davis, California 95616, USA) approximately 6 mo later for ophthalmologic examination of bilateral eye lesions. Diagnosis of bilateral congenital cataracts (Buyukmihci et al., 1988) was confirmed by the Department of Ophthalmology. The owl was held at the University of California (Davis Raptor Center, Davis, California 95616, USA) beginning 10 November 1986 in order to obtain information on cataract resorption and evaluate its visual capabilities. On 8 May 1987 after nearly 1 yr in captivity a routine physical examination revealed bilateral foot lesions which were characterized by flakey, proliferative papillary hyperkeratosis on the plantar, lateral, and dorsal surfaces of the phalanges (Figs. 1, 2). Moderate tissue swelling, inflammation and feather loss also were apparent. The gross lesions were similar to those described by Arnall (1958) in psittacine birds

except there were no signs of lesions on the cere. Histologic examination was not performed. Initial treatment with oral antibiotics to counteract possible infection was administered on 9 May 1987. A skin scraping was taken on 11 May 1987 in order to assess the presence of astigmatid mites. The skin samples were macerated in 1 drop of 10% potassium hydroxide solution. Microscopic examination revealed numerous mites later identified as *Knemidokoptes mutans* (B. M. O'Connor, pers. comm.). The identification was based on the morphology of the dorsal shield and scapular setae (Lavoipierre and Griffiths, 1951; Fain and Elsen, 1967). Several females were ob-



**FIGURE 1.** Gross flakey skin lesions caused by *Knemidokoptes mutans* on lateral aspect of the foot of a great-horned owl.



FIGURE 2. Gross skin lesions on the plantar surface of the foot of a great-horned owl showing proliferative papillary hyperkeratosis.

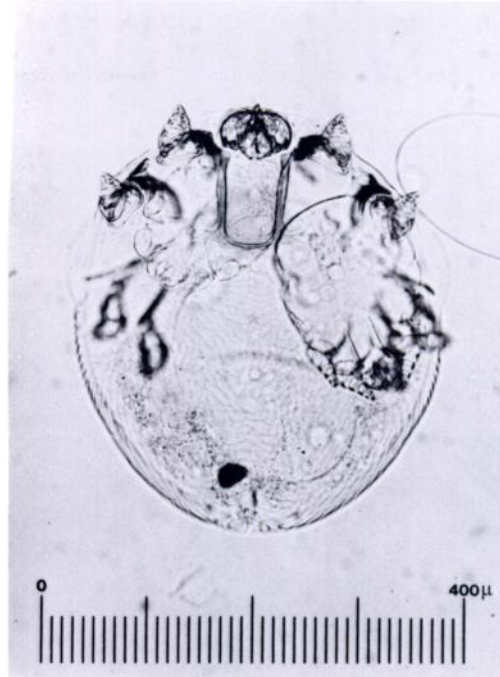


FIGURE 3. Photomicrograph of female *Knemidokoptes mutans* from a great-horned owl.

served to have embryonated larvae (Fig. 3). The owl was treated with a single dose of ivermectin (Merck and Co., Inc., P.O. Box 2000, Rahway, New Jersey 07065, USA) intramuscularly at a dosage of 200  $\mu\text{g}/\text{kg}$ . Swelling had subsided 5 days post-treatment; however, hyperkeratosis was unresolved. At 2 wk posttreatment examination of microscopic skin scrapings taken from the periphery of the lesions at three different sites revealed no mites. The hyperkeratosis was notably resolving at this time. All lesions were completely healed 6 wk posttreatment.

Although knemidokoptid mites are relatively common on pet birds (Harrison and Harrison, 1986), there are only two records from birds of prey. *Knemidokoptes* sp. were found on the legs of a snowy owl (*Nyctea scandiaca*) and on accipiters in Great Britain (Cooper, 1985). This report represents the first known documentation of *Knemidokoptes* sp. parasitizing a great-horned owl. All previous verified records

of *K. mutans* are from galliform birds (Fain and Elsen, 1967). Because many species of birds are handled and caged at the Monterey Society for Prevention of Cruelty to Animals and University of California Veterinary Medical Teaching Hospital, including galliform and psittacine birds, the possibility of cross contamination during housing or handling procedures cannot be dismissed. However, cross contamination is probably unlikely since earlier attempts to experimentally infect the budgerigar *Melopsittacus undulatus* with *Knemidokoptes pilae* by direct contact were unsuccessful (Blackmore, 1963; Yunker, 1973).

The authors thank Barry M. O'Connor, Museum of Zoology, University of Michigan, for confirming the identification of *Knemidokoptes mutans*. Representative specimens of *K. mutans* are deposited in The U.S. National Parasite Collection (Animal Parasitology Institute, USDA, Building 1180 BARC-East, Beltsville, Maryland 20795, USA; accession number 80557).

## LITERATURE CITED

- ARNALL, L. 1958. Experiences with cage-birds. *Veterinary Record* 70: 120-128.
- BLACKMORE, D. K. 1963. Some observations on *Cnemidocoptes pilae*, together with its effect on the budgerigar (*Melopsittacus undulatus*). *Veterinary Record* 75: 592-595.
- BUYUKMIHCI, N., C. J. MURPHY, AND T. SCHULZ. 1988. Developmental ocular disease of raptors. *Journal of Wildlife Diseases* 24: 207-213.
- COOPER, J. E. 1985. *Veterinary aspects of captive birds of prey*. The Standfast Press, Saul, Gloucestershire, England, 256 pp.
- FAIN, A., AND P. ELSEN. 1967. Les Acariens de la famille Knemidokoptidae producteurs de gale chez les oiseaux (Sarcoptiformes). *Acta Zoologica et Pathologica Antverpiensia* 45: 3-142.
- HARRISON, G. J., AND L. K. HARRISON. 1986. *Clinical avian medicine and surgery*. W. B. Saunders Co., Philadelphia, Pennsylvania, 717 pp.
- LAVOPIERRE, M., AND R. B. GRIFFITHS. 1951. A preliminary note on a new species of *Cnemidocoptes* (Acarina) causing scaly leg in a budgerigar (*Melopsittacus undulatus*) in Great Britain. *Annals of Tropical Medicine and Parasitology* 45: 253-254.
- YUNKER, C. E. 1973. Mites. In *Parasites of laboratory animals*, R. J. Flynn (ed.). Iowa State University Press, Ames, Iowa, pp. 425-492.

*Received for publication 29 September 1988.*