

## **EFFICACY OF TRICLABENDAZOLE AGAINST NATURAL INFECTIONS OF FASCIOLOIDES MAGNA IN WAPITI**

Authors: Pybus, M. J., Onderka, D. K., and Cool, N.

Source: Journal of Wildlife Diseases, 27(4) : 599-605

Published By: Wildlife Disease Association

URL: <https://doi.org/10.7589/0090-3558-27.4.599>

---

BioOne Complete ([complete.BioOne.org](https://complete.BioOne.org)) is a full-text database of 200 subscribed and open-access titles in the biological, ecological, and environmental sciences published by nonprofit societies, associations, museums, institutions, and presses.

Your use of this PDF, the BioOne Complete website, and all posted and associated content indicates your acceptance of BioOne's Terms of Use, available at [www.bioone.org/terms-of-use](https://www.bioone.org/terms-of-use).

Usage of BioOne Complete content is strictly limited to personal, educational, and non - commercial use. Commercial inquiries or rights and permissions requests should be directed to the individual publisher as copyright holder.

---

BioOne sees sustainable scholarly publishing as an inherently collaborative enterprise connecting authors, nonprofit publishers, academic institutions, research libraries, and research funders in the common goal of maximizing access to critical research.

## EFFICACY OF TRICLABENDAZOLE AGAINST NATURAL INFECTIONS OF *FASCIOLOIDES MAGNA* IN WAPITI

M. J. Pybus,<sup>1</sup> D. K. Onderka,<sup>2</sup> and N. Cool<sup>3</sup>

<sup>1</sup> Alberta Fish and Wildlife Division, 6909-116 Street, Edmonton, Alberta, Canada T6H 4P2

<sup>2</sup> Alberta Agriculture, 6909-116 Street, Edmonton, Alberta, Canada T6H 4P2

<sup>3</sup> Canadian Parks Service, Elk Island National Park,  
R.R. 1, Fort Saskatchewan, Alberta, Canada T8L 2N7

**ABSTRACT:** Fourteen free-ranging adult wapiti (*Cervus elaphus nelsoni*) were captured in Banff National Park, Alberta (Canada) and held in captivity near Edmonton. A 24% suspension of triclabendazole at doses of 30 to 100 mg/kg body weight was drenched into the rumen of eight females and four males. Two male wapiti were used as untreated controls. Animals were killed and examined at 4 ( $n = 3$ ), 6 ( $n = 4$ ), or 8 ( $n = 4$ ) wk after treatment. Efficacy was 90% against immature *Fascioloides magna* collected 4 wk after treatment and 98% against adult flukes collected 4, 6 or 8 wk after treatment. All 32 flukes recovered from control wapiti were active and apparently healthy. Treatment at 50 to 60 mg/kg is recommended against *F. magna* in wapiti. A protocol for treating infected wapiti is outlined.

**Key words:** Triclabendazole, wapiti, *Fascioloides magna*, *Cervus elaphus nelsoni*, anthelmintic, treatment, drug trial, translocation.

### INTRODUCTION

*Fascioloides magna*, the giant liver fluke, occurs in North America as a relatively benign parasite in the liver of white-tailed deer (*Odocoileus virginianus*), caribou (*Rangifer tarandus*), and wapiti (*Cervus elaphus*). However, it can cause extensive hepatic damage in wapiti, moose (*Alces alces*), black-tailed deer (*O. hemionus columbianus*) and cattle but usually is not lethal in these hosts (Erhardova-Kotrla, 1971; Foreyt, 1981). In domestic sheep and goats, infection with *F. magna* often is lethal (Foreyt and Todd, 1976; Foreyt and Leathers, 1980).

Translocation of wapiti is used increasingly by wildlife managers to supplement or reestablish free-ranging populations. In addition, large numbers of wapiti are moved as part of the growing game farm industry. Unfortunately, *F. magna* also is translocated easily with infected wapiti into areas suitable for completion of its life cycle (Bassi, 1875; Kingscote, 1950; Flook and Stenton, 1969; Pybus, 1990).

Triclabendazole, a benzimidazole anthelmintic, has proven effective against natural and experimental infections of *Fasciola hepatica* in sheep (Boray et al.,

1983; Smeal and Hall, 1983; Wolff et al., 1983; Guralp and Tinai, 1984; Turner et al., 1984), goats (Wolff et al., 1983) and cattle (Boray, 1982; Craig and Huey, 1984); *F. gigantica* in buffalo (Gupta et al., 1988); and *F. magna* in cattle (Craig and Huey, 1984), sheep (Foreyt, 1989) and white-tailed deer (Qureshi et al., 1989). In these studies, efficacy against mature and immature flukes was achieved without toxicity in the hosts. A dose of 200 mg/kg is toxic in sheep (Boray et al., 1983) and cattle (Boray, 1982) and there is a clearance period of 28 days in cattle (Ciba-Geigy, unpubl. data).

We report the efficacy of triclabendazole against *F. magna* in naturally-infected wapiti and present a treatment protocol to minimize the risk of translocating giant liver flukes. Results also are applicable to management of captive wapiti in areas where *F. magna* is enzootic.

### MATERIALS AND METHODS

Fourteen free-ranging adult wapiti (10 females, four males) were captured near Banff, Alberta (51°10'N, 115°35'W) in Banff National Park 13 to 16 October 1989. They were immobilized with 28 to 36 mg succinylcholine chloride (Burroughs Wellcome Inc., Kirkland,

TABLE 1. Efficacy of triclabendazole against natural infections of *Fascioloides magna* in wapiti.

Dose <sup>a</sup>	Number of wapiti	Adult trematodes		Immature trematodes	
		Number	% Dead or damaged	Number	% Dead or damaged <sup>b</sup>
30–40	3	10	100	27	48
45–60	4	4	100	6	67
65–75	3	25	100	12	100
80–100	2	5	80	8	50
Total	12	44	98	53	64
Control	2	22	0	10	0

<sup>a</sup> mg/kg of body weight at necropsy.<sup>b</sup> Does not include degenerated remnants in deposits of black amorphous material.

Quebec, Canada H9H 4J4) by remote darting (Pneu-Dart Inc., Williamsport, Pennsylvania, 17703 USA). Antlers were removed and wapiti were eartagged (All-flex®, United Farmers of Alberta, Edmonton, Alberta, Canada T7X 2P1) prior to release into a temporary holding pen. Water and hay were provided.

On October 15 and 16, the wapiti were transported in stock trailers to the Agriculture Canada quarantine facility near Edmonton, Alberta (Nisku, Alberta, Canada, T0C 2G0). Initially they were allowed to move freely throughout a series of nine darkened indoor holding pens in the facility. Subsequently females were penned in groups of two to four, while males were housed singly. All pens had a cement floor, ventilation and light-control. Water and alfalfa hay were provided.

To facilitate drenching, each wapiti was immobilized with 350 to 400 mg xylazine hydrochloride (Rompun®, Haver-Lockhart Laboratories, Shawnee, Kansas 66201, USA) administered intramuscularly via a spring-powered jabstick (Westergaard Enterprises, Edmonton, Alberta, Canada T5W 1N7). Weights of the wapiti were estimated. The animals remained in excellent body condition throughout the trial. Dosages of triclabendazole were calculated based on weight at necropsy.

Twelve wapiti were drenched with 30 to 100 mg/kg of a 24% suspension of triclabendazole (Fasinex® 24%, Ciba-Geigy Corporation, Greensboro, North Carolina 27419, USA) via stomach tube into the rumen (Table 1). The tube was flushed with 100 ml water and 50 cc air. Five mg idazoxan (RX821002, Reckitt and Colman, Pharmaceutical Division, Kingston-Upon-Hull, England) was used to reverse the effects of xylazine in males; 24 mg yohimbine (Sigma Chemical Co., St. Louis, Missouri, 63178, USA) was used in females.

Treated wapiti were killed 4, 6 and 8 wk after treatment. Control animals were killed at 4 and 8 wk. Each animal was immobilized with 28 mg succinylcholine chloride and killed with 27 gm sodium pentobarbital (Euthanyl®, M.T.C. Pharmaceuticals, Mississauga, Ontario, Canada L4W 2S3) administered intravenously.

All adult wapiti and three fetuses from treated females were examined at necropsy. Body condition was assessed by amount of mesenteric, perirenal and bone marrow fat. Samples of kidney, pancreas, spleen, salivary gland, testis, mesenteric lymph node, hepatic lymph node, and liver (three samples) from each animal were collected and prepared routinely for histologic examination. Each liver was sliced (2 to 4 mm) and all *F. magna* and associated lesions were recorded. Many flukes, tissue capsules, and lesions were collected and examined histologically. The number of dead flukes, live flukes, and the stage of development (immature or mature) was recorded. Determination of viability was based on color, shape, movement, integrity of cuticle and internal organs, and evidence of cellular damage such as necrosis and inflammatory cell reactions within the fluke.

## RESULTS

Natural infections of *F. magna* were found in 13 (93%) of the wapiti; mean intensity was  $10 \pm 11$  flukes. Gross lesions included black streaks in hepatic parenchyma, fibrous adhesions between the liver and diaphragm, and large pale irregular-shaped nodules on the surface of the liver. Fibrous capsules and hemorrhagic tracts throughout hepatic parenchyma were associated with adult and immature *F. magna*, respectively. In heavily infected wapiti, fibrous adhesions were noted between pleural surfaces of the diaphragm, ribs and lungs.

Forty-four adult *F. magna* were collected from treated wapiti (Table 1). All but one (98%) were dead or damaged. Dead flukes were pale and flaccid, often with no recognizable inner morphology. In many dead flukes the posterior region was disintegrating. Damaged flukes were pink and apparently healthy in the anterior region but black and immobile in the posterior region (Fig. 1). Dead adult flukes were seen by 4 wk after treatment (Table 2).

Fifty-three immature *F. magna* were

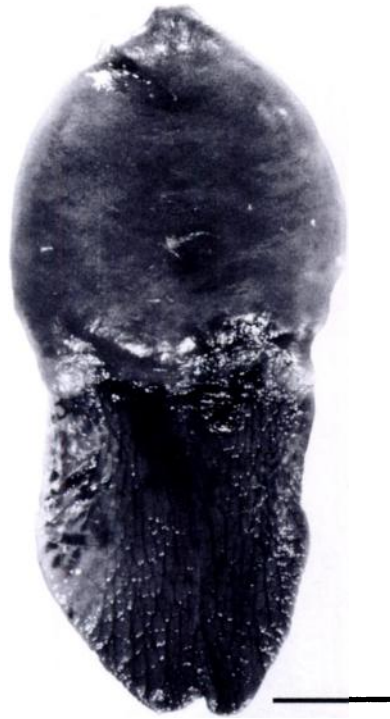

FIGURE 1. Adult *Fascioloides magna* from wapiti treated with triclabendazole. Note severe degeneration of posterior half. Bar = 1 cm.

collected from treated wapiti (Table 1). Thirty-four (64%) were dead or damaged. The greatest efficacy against immature flukes was seen at 65 to 75 mg/kg (Table 1) and at 4 wk after treatment (Table 2). However, tracks and capsules containing firm black caseous material were seen in most of the wapiti examined 6 or 8 wk after treatment. On histologic examination, many of these lesions contained remnants of *F. magna*.

There were no clinical signs or gross or histologic evidence of toxicity due to triclabendazole in any wapiti, including the fetuses. Damage was evident only in affected flukes.

Twenty-two adult and 10 immature *F. magna* were collected from the two control wapiti (Table 1). All flukes were pink and fully mobile with recognizable inner structures throughout.

Microscopic lesions associated with mi-

TABLE 2. Efficacy of triclabendazole against *Fascioloides magna* after different time periods.

Time after treatment (wk)	Number of wapiti	Adult trematodes		Immature trematodes	
		Number	% Dead or damaged	Number	% Dead or damaged*
4	3	5	100	10	90
6	4	27	96	16	69
8	4	12	100	27	52

\* Does not include degenerated remnants in deposits of black amorphous material.

gration or encapsulation of flukes in liver of treated and control wapiti were similar to those described by Erhardova-Kotrla (1971). However, in treated animals, *F. magna* showed differing degrees of degeneration. Earliest changes always occurred at the posterior end as indicated by necrotic cuticle, often with scant infiltration of host neutrophils and degeneration of internal structures (Fig. 2). Sometimes the entire posterior half of adult flukes was severely degenerated while the anterior half appeared normal (Fig. 3). In advanced stages of degeneration, the cuticle was dissolved and the body cavity shrunk. Coagulation of protein occurred giving it a dense appearance with numerous host inflammatory cells invading the dead parasite. Within fibrous capsules the inflammatory reaction to dead flukes was extensive and large caseous masses intermingled with typical black fluke pigment (Fig. 4).

## DISCUSSION

Triclabendazole was effective against *F. magna* in wapiti regardless of dose or time. Adult flukes recovered 4 wk after treatment appeared to have been dead for quite some time and most dead or damaged immature flukes apparently sustained damage soon after treatment. Estimates of efficacy against immature flukes recovered 6 and 8 wk after treatment are considered conservative since dead immature flukes disintegrated and could not be distinguished from necrotic debris. Thus we consider the 90% efficacy observed 4 wk

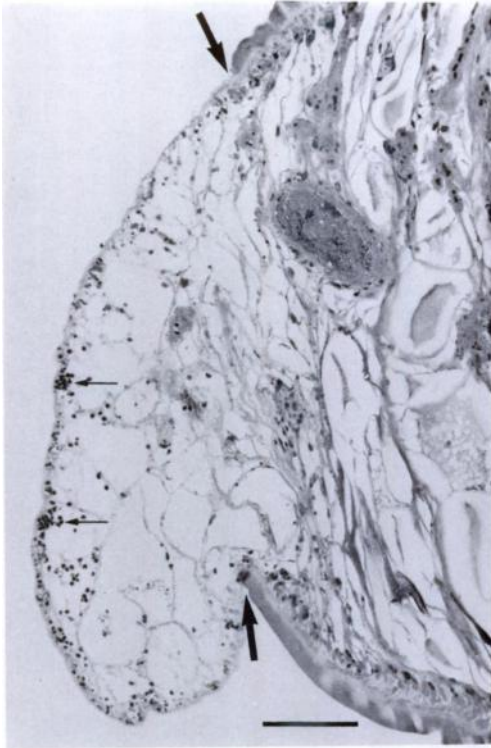


FIGURE 2. Early degenerative change in the posterior pole of *Fascioloides magna* 4 wk after treatment. The cuticle is disrupted (thick arrows) and the subcuticular membrane is infiltrated with mixed host inflammatory cells (thin arrows). Bar = 200  $\mu$ m.

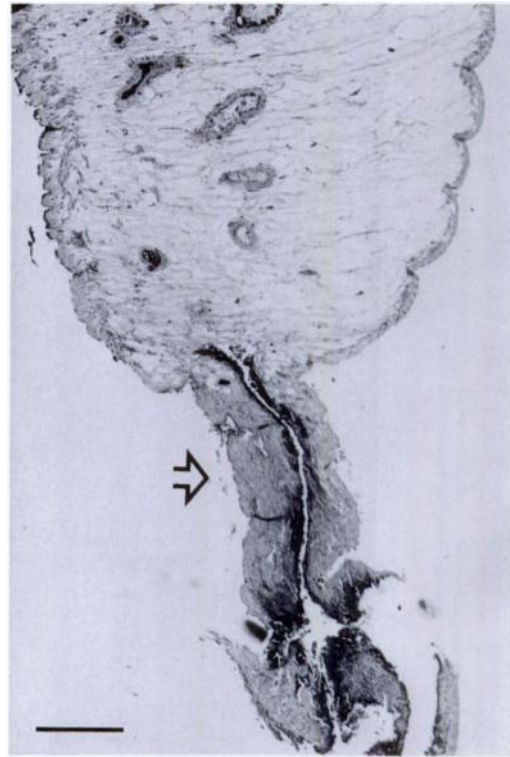


FIGURE 3. Severe posterior degeneration of treated adult *Fascioloides magna* (arrow) with normal cuticle and internal structures of the anterior half. Bar = 500  $\mu$ m.

after treatment to be the best indication of the actual effects of triclabendazole on immature flukes.

The progressive degeneration of damaged flukes may reflect physiologic and/or metabolic peculiarities of trematodes. The excretory pore of many digenetic trematodes, including *F. magna*, is located on the posterior margin of the fluke (Schell, 1970). Concentration or accumulation of triclabendazole in this region could result in earlier and more severe tissue damage. A similar ascending necrosis was noted in *F. hepatica* from sheep treated with triclabendazole (Smeal and Hall, 1983).

Dosage levels used in this study are considerably higher than those recommended to treat *F. magna* in other species: 6–12 mg/kg in cattle (Craig and Huey, 1984), 10–20 mg/kg in sheep (Foreyt, 1989), 10

mg/kg in white-tailed deer (Qureshi et al., 1989). A pilot study with 5 naturally-infected wapiti suggested that triclabendazole at 20 mg/kg was not effective (M. J. Pybus, unpubl. data) and the difficulty in assessing efficacy against immature flukes observed later in this study (when some of the low dose animals were killed) leads us to recommend a minimum dosage level of 50 mg/kg. There was no evidence of toxicity in wapiti, even at 100 mg/kg and our recommended dose is considered well within the safety limits of triclabendazole.

Results of this study have direct implications for the translocation of wapiti in Alberta. Elk Island National Park, in central Alberta (53°30'N, 112°30'W), has been used as a source of animals for translocation to other areas (Bryant and Maser, 1982). In 1987, *F. magna* was detected within the park (M. J. Pybus, unpubl. data)



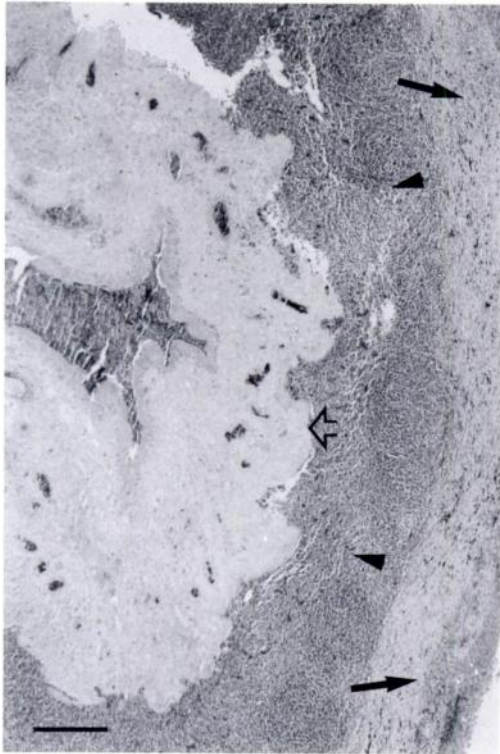


FIGURE 4. Necrotic fluke (open arrow) surrounded by granulomatous reaction and debris (arrowheads) embedded in a thick fibrous capsule with scattered black pigment (arrows). Bar = 500  $\mu$ m.

and in 1989 programs for restocking wapiti in Alberta were postponed due to the risk of introducing giant liver flukes into range used by moose. Triclabendazole is now being used to reduce the risk by treating all wapiti prior to translocation.

Similar treatment could be used in other captive and field management situations where wapiti are handled individually. Drenching can be combined easily with most marking or blood sampling procedures and we have successfully drenched wapiti with and without chemical immobilization. In the latter situation, the animals were physically restrained. In field situations, a drenching syringe is used instead of a stomach tube.

Very few giant liver flukes mature unless they are paired with another fluke in the liver (Foreyt et al., 1977; Addison et al., 1988). The marked reduction in num-

ber of viable flukes suggests that treated wapiti are unlikely to carry enough live *F. magna* to establish a viable population of liver flukes in an area where the parasite does not exist. If wapiti are released into areas where *F. magna* is enzootic, treatment would minimize the chances of adding to existing fluke populations.

Transmission of giant liver flukes, like that of many parasites, is affected by density-dependent factors (Anderson, 1976). It often is facilitated by increased density of hosts and repeated access to infective stages of the parasite. Thus, the prevalence and intensity of liver fluke infections is likely to increase in captive wapiti held on game farms or in other situations with conditions suitable for transmission. Triclabendazole could be used to limit such infections and their detrimental effects in captive wapiti. In addition, this would be important when infected wapiti are sympatric with moose or domestic sheep or goats.

After drenching, wapiti should be held for 30 days without access to vegetation contaminated with larvae of *F. magna*. This should allow for cessation of egg production and disappearance of eggs from the feces of treated wapiti (Smeal and Hall, 1983; Qureshi et al., 1989). In addition, the waiting period may allow for clearance of the drug from body tissues, a concern if treated animals are to be hunted or slaughtered. Holding animals for 30 days after treatment will present significant logistical problems unless the wapiti are in a semi-captive situation or can be relocated temporarily to suitable holding facilities. These problems must be weighed against the concerns of introducing or adding to a population of liver flukes (Pybus, 1990).

#### RECOMMENDED TREATMENT PROTOCOL

We recommend that wapiti be drenched with triclabendazole at 50 to 60 mg/kg and then held for at least 30 days without opportunity for reinfection. This protocol should result in death of most, if not all,

adult *F. magna* and a large portion of the immature flukes. A second drenching after 7 days probably would improve the efficacy.

#### ACKNOWLEDGMENTS

The authors gratefully acknowledge the assistance of staff of the Canadian Parks Service in Elk Island National Park and Banff National Park, particularly P. Deering and R. Kunelius, respectively. Agriculture Canada provided secure and exceptional housing facilities for the wapiti and H. Crough looked after the wapiti and provided solutions to many of the logistical problems throughout this program. Ciba-Geigy freely provided Fasinox® and background information. D. Welch and W. Foreyt provided helpful review comments. Financial support was provided by Environment Canada, Canadian Parks Service.

#### LITERATURE CITED

- ADDISON, E. M., J. HOEVE, D. G. JOACHIM, AND D. J. MCLACHLIN. 1988. *Fascioloides magna* (Trematoda) and *Taenia hydatigena* (Cestoda) from white-tailed deer. Canadian Journal of Zoology 66: 1359-1364.
- ANDERSON, R. M. 1976. Dynamic aspects of parasite population ecology. In Ecological aspects of parasitology, C. R. Kennedy (ed.). North-Holland Publishing Company, Amsterdam, Netherlands, pp. 431-462.
- BASSI, R. 1875. Jaundiced verminous cachexy of pus of the stags caused by *Distoma magnum*. Medico Veterinario 4: 497-515. As reprinted in the Southeastern Veterinarian 14: 103-112.
- BORAY, J. C. 1982. Chemotherapy of fasciolosis. New South Wales Veterinary Proceedings 1982: 42-47.
- , P. D. CROWFOOT, M. B. STRONG, J. R. ALLISON, M. SCHELLENBAUM, M. VON ORELLI, AND G. SARASIN. 1983. Treatment of immature and mature *Fasciola hepatica* infections in sheep with triclabendazole. The Veterinary Record 113: 315-317.
- BRYANT, L. D., AND C. MASER. 1982. Classification and distribution. In Elk of North America, ecology and management, J. W. Thomas and D. E. Towell (eds.). Stackpole Books, Harrisburg, Pennsylvania, pp. 1-59.
- CRAIG, T. M., AND R. L. HUEY. 1984. Efficacy of triclabendazole against *Fasciola hepatica* and *Fascioloides magna* in naturally infected calves. American Journal of Veterinary Research 45: 1644-1645.
- ERHARDOVA-KOTRLA, B. 1971. The occurrence of *Fascioloides magna* (Bassi, 1875) in Czechoslovakia. Czechoslovak Academy of Sciences, Prague, Czechoslovakia, 155 p.
- FLOOK, D. R., AND J. E. STENTON. 1969. Incidence and abundance of certain parasites in wapiti in the national parks of the Canadian Rockies. Canadian Journal of Zoology 47: 795-803.
- FOREYT, W. J. 1981. Trematodes and cestodes. In Diseases and parasites of white-tailed deer, W. R. Davidson, F. A. Hayes, V. F. Nettles, and F. E. Kellogg (eds.). Miscellaneous Research Publication No. 7, Tall Timbers Research Station, Tallahassee, Florida, pp. 237-265.
- . 1989. Efficacy of triclabendazole against experimentally induced *Fascioloides magna* infections in sheep. American Journal of Veterinary Research 50: 431-432.
- , AND C. W. LEATHERS. 1980. Experimental infection of domestic goats with *Fascioloides magna*. American Journal of Veterinary Research 41: 883-884.
- , W. M. SAMUEL, AND A. C. TODD. 1977. *Fascioloides magna* in white-tailed deer (*Odocoileus virginianus*): Observations on the pairing tendency. The Journal of Parasitology 63: 1050-1052.
- , AND A. C. TODD. 1976. Development of the large American liver fluke, *Fascioloides magna*, in white-tailed deer, cattle, and sheep. The Journal of Parasitology 63: 26-32.
- GUPTA, S., S. CHAUDHRI, AND J. C. PAUL. 1988. Comparative efficacy of triclabendazole, oxclozanide and albendazole against field infections of chronic *Fasciola gigantica* infections in buffaloes. Indian Veterinary Journal 65: 875-879.
- GURALP, N., AND R. TINAI. 1984. Trematodiasis in Turkey: Comparative efficacy of triclabendazole and niclofolan against natural infections of *Fasciola hepatica* and *F. gigantica* in sheep. Journal of Helminthology 58: 113-116.
- KINGSCOTE, A. A. 1950. Liver rot (Fascioloidiasis) in ruminants. Canadian Journal of Comparative Medicine 14: 203-208.
- PYBUS, M. J. 1990. Survey of hepatic and pulmonary parasites of wild cervids in Alberta, Canada. Journal of Wildlife Diseases 26: 453-459.
- QURESHI, T., T. M. CRAIG, D. L. DRAWE, AND D. S. DAVIS. 1989. Efficacy of triclabendazole against fascioloidiasis (*Fascioloides magna*) in naturally infected white-tailed deer (*Odocoileus virginianus*). Journal of Wildlife Diseases 25: 378-383.
- SCHELL, S. C. 1970. How to know the trematodes, William C. Brown Company, Dubuque, Iowa, 355 pp.
- SMEAL, M. G., AND C. A. HALL. 1983. The activity of triclabendazole against immature and adult *Fasciola hepatica* infections in sheep. Australian Veterinary Journal 60: 329-331.
- TURNER, K., J. ARMOUR, AND R. J. RICHARDS. 1984. Anthelmintic efficacy of triclabendazole against

- Fasciola hepatica* in sheep. The Veterinary Record 114: 41–42.
- WOLFF, K., J. ECKERT, G. SCHNEITER, AND H. LUTZ. 1983. Efficacy of triclabendazole against *Fasciola hepatica* in sheep and goats. Veterinary Parasitology 13: 145–150.
- Received for publication 4 September 1990.