



## Apparent Fatal Snakebite in Three Hawks

Authors: Heckel, Jens-Ove, Sisson, D. Clay, and Quist, Charlotte F.

Source: Journal of Wildlife Diseases, 30(4) : 616-619

Published By: Wildlife Disease Association

URL: <https://doi.org/10.7589/0090-3558-30.4.616>

---

BioOne Complete ([complete.BioOne.org](https://complete.BioOne.org)) is a full-text database of 200 subscribed and open-access titles in the biological, ecological, and environmental sciences published by nonprofit societies, associations, museums, institutions, and presses.

Your use of this PDF, the BioOne Complete website, and all posted and associated content indicates your acceptance of BioOne's Terms of Use, available at [www.bioone.org/terms-of-use](https://www.bioone.org/terms-of-use).

Usage of BioOne Complete content is strictly limited to personal, educational, and non - commercial use. Commercial inquiries or rights and permissions requests should be directed to the individual publisher as copyright holder.

---

BioOne sees sustainable scholarly publishing as an inherently collaborative enterprise connecting authors, nonprofit publishers, academic institutions, research libraries, and research funders in the common goal of maximizing access to critical research.

## Apparent Fatal Snakebite in Three Hawks

Jens-Ove Heckel,<sup>1,3</sup> D. Clay Sisson,<sup>2</sup> and Charlotte F. Quist,<sup>1</sup> <sup>1</sup> Southeastern Cooperative Wildlife Disease Study, College of Veterinary Medicine, The University of Georgia, Athens, Georgia 30602, USA; <sup>2</sup> Tall Timbers Research, Inc., Route 1, Box 678, Tallahassee, Florida 32312, USA; <sup>3</sup> Present address: Tierärztliche Hochschule Hannover, Bischofsholer Damm 15, 3000 Hannover 1, Federal Republic of Germany

**ABSTRACT:** Based on histories and gross and histologic findings, snakebite was diagnosed in three dead raptors submitted for post-mortem examination from northern Florida and southern Georgia (USA). Two immature red-tailed hawks (*Buteo jamaicensis*) were found next to dead and partially eaten venomous snakes. An adult Cooper's hawk (*Accipiter cooperii*) was found adjacent to a den containing a cottonmouth (*Agkistrodon piscivorus*) and an eastern diamondback rattlesnake (*Crotalus adamanteus*). Gross findings in all birds consisted of hemorrhage and gangrenous necrosis of one limb. Severe muscular degeneration was seen histologically.

**Key words:** Snakebite, raptor, red-tailed hawk, *Buteo jamaicensis*, Cooper's hawk, *Accipiter cooperii*, cottonmouth, *Agkistrodon piscivorus*, eastern diamondback rattlesnake, *Crotalus adamanteus*.

Snakes are well documented as a dietary component of various hawk species (Bent, 1937; Knight and Erickson, 1976). However, few snakebite deaths have been reported in avian species. In Africa, snakebite has been reported in a hen (*Gallus domesticus*) (Onoviran et al., 1976) and in a wild tufted guinea fowl (*Numida meleagris galatea*) (Okaeme, 1985). An adult red-tailed hawk (*Buteo jamaicensis*) died from flaccid paralysis induced by the bite from an eastern coral snake (*Micrurus fulvius*) in Florida (USA) (Brugger, 1989).

Between March 1989 and February 1993, three cases of apparent fatal snakebite in hawks were diagnosed at post-mortem examination. All three birds, two immature red-tailed hawks and one adult Cooper's hawk (*Accipiter cooperii*), were killed in adjoining counties located in north Florida and south Georgia (USA) (approximately 30°39'N, 84°13'W). The two red-tailed hawks were submitted from the Pebble Hill Plantation in Grady County, Georgia and the Cooper's hawk was sub-

mitted from the Tall Timbers Research Station, Leon County, Florida. Necropsies were performed on all birds by the methods of Franson (1987).

In January 1989, a dead, thin, immature female red-tailed hawk was found close to a dead 120 cm long eastern diamondback rattlesnake (*Crotalus adamanteus*) on the day after a controlled burn of the area. The snake was near a burned-out stump. Parts of the snake's head and neck had been eaten. There was a large area of hemorrhage and edema on the left leg of the hawk, with blood staining the breast feathers. No discernable puncture wounds were found. Musculature and skin surrounding the left tibiotarsometatarsal joint were darkly discolored and necrotic, with a distinct line of demarcation between normal and necrotic muscle. The hawk's crop contained snakeskin, mandibles, fangs, and muscle.

In February 1992, an adult Cooper's hawk was found dead close to a stump hole that was surrounded by feathers of a northern bobwhite (*Colinus virginianus*). Two days prior to finding the hawk, a live radio-collared bobwhite had been located in the hole. During recovery of the bobwhite it was observed that the hole also was inhabited by both a large cottonmouth and an eastern diamondback rattlesnake. There were two puncture sites on the hawk, 15 mm apart, and subcutaneous discoloration on the lower right leg. Necrosis of underlying musculature extended proximally into the medial thigh muscles.

A third case involving another thin, immature, female red-tailed hawk was submitted in January 1993. This bird was found dead on a recently burned area. Dried blood covered feathers on the ventral abdomen and medial aspect of the right

thigh. On palpation of the right leg, there was laxity of musculature and skeletal attachments when compared to the left leg. Two puncture wounds, approximately 2 mm in diameter and 3 cm apart, were present on the cranio-lateral aspect of the distal thigh. Skin surrounding these lesions was necrotic with mild subcutaneous emphysema and marked edema extending proximally to mid-femur. Affected musculature was hemorrhagic and was sharply demarcated from normal muscle (Fig. 1). The stomach contained partially digested food consisting of numerous pieces of snakeskin ranging from 1 to 12 cm in diameter, several vertebrae and ribs, and moderate amounts of muscle. The snakeskin and bones were identified as those of a cottonmouth (*Agkistrodon piscivorus*). Because only ventral and lateral pieces of snake skin were available, subspecies could not be determined, but based on size of bones and ventral scales, it appeared to be a large adult.

Samples of skeletal muscle were fixed in 10% formalin, embedded in paraffin, sectioned at 4  $\mu$ m, and stained with hematoxylin and eosin. Based on histologic examination of tissues from affected musculature of both red-tailed hawks, there was severe muscular degeneration with increased eosinophilia of muscle fibers, hyalinization, loss of striations, and occasional fragmentation (Fig. 2). No inflammation or evidence of regeneration was present. Congestion of affected and adjacent nonaffected muscle tissue was marked. Although presence of venom in tissues of these birds was not confirmed, all three birds had similar presentations with lesions compatible with death due to snakebite (Parrish et al., 1957).

While common throughout the entire United States, red-tailed hawks are noticeably more numerous in the southern states in winter. Small mammals are their main prey, but birds, reptiles, amphibians, and insects also are consumed (May, 1935). Of all hawk species, the red-tailed hawk is particularly known to prey on snakes (Knight and Erickson, 1976). Snakes killed

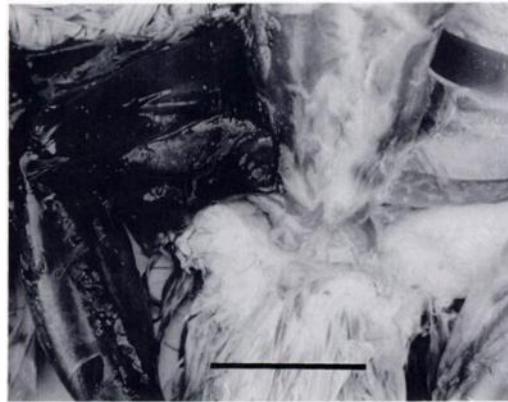


FIGURE 1. Severe hemorrhage and necrosis of the right leg of a red-tailed hawk found in January 1993 in Georgia probably caused by the bite of a cottonmouth snake. Bar = 5 cm.

by hawks are grasped close to the head and often decapitated (Klauber, 1972). Though mentioned (Bent, 1937), snake predation by Cooper's hawks apparently is not a frequent occurrence. To our knowledge, no mention of resistance of hawks or other snake-eating birds to snake venom has been reported.

The active components of venom from either snake include hyaluronidase, arginine ester hydrolase, and phospholipase A; thus, the venom is both necrotizing and hemolytic (Beasley et al., 1990; Tan and Ponnudurai, 1990). The wide variability and complexity of venom components even between snakes within the same genus probably accounts for the wide variety of pathological changes associated with bites (Ownby, 1982). Initially, local effects predominate including edema, severe hemorrhage, and myonecrosis. Various venom enzymes and proteases trigger endogenous release of bradykinin, prostaglandins, serotonin and histamine, causing vasodilation and increased vascular permeability (Hawgood, 1982). Based on Hawgood (1982) and Ownby (1982) systemic effects, such as decreased arterial blood pressure and hypotension, follow these local events. Phospholipase A induces hypotension by promoting prostaglandin E synthesis via release of arachidonic acid. Cardiac ar-

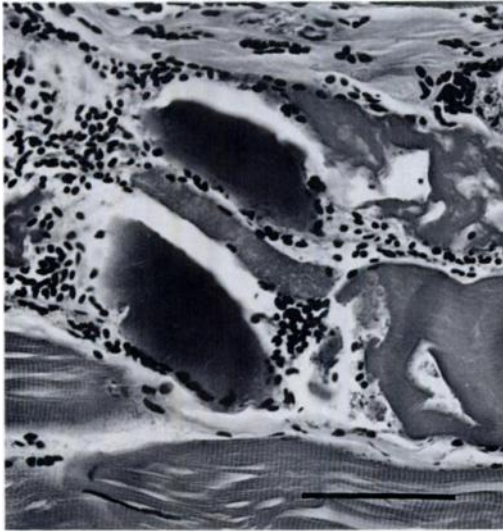


FIGURE 2. Affected skeletal muscle with hyalinization, loss of striations, and fragmentation of muscle fibers with associated hemorrhage. H&E. Bar = 60  $\mu$ m.

rhythmias can occur contributing to myocardial weakness and failure. A vicious cycle of circulatory collapse and irreversible shock can ensue. In some snakes, neurotoxins block neuromuscular transmission resulting in flaccid paralysis and respiratory failure; target species vary in susceptibility to this toxin. Central nervous system alterations have been noted. Hemostatic alterations can lead to disseminated intravascular coagulation. Sublethal bites can cause serious secondary bacterial infections, such as tetanus or gas gangrene (Jones and Hunt, 1983). Thus, the cause of death in target species can be a result of one primary event or failure of many systems (Ownby, 1982).

Similar circumstances were associated with the deaths of both juvenile red-tailed hawks. Both snake species hibernate; however, eastern diamondback rattlesnakes in Florida may stay active all winter (Ernst, 1992) or may emerge from hibernation and become active when disturbed. In these cases, fire may have created such a disturbance. Based on these observations, we propose that snakebite should be considered as a differential diagnosis in raptor mortality, particularly in young birds with

locally extensive hemorrhagic myopathy. Snakebite probably represents an occasional, though scarcely reported, cause of death in inexperienced or immature hawks.

We thank Dr. V. F. Nettles, Dr. W. R. Davidson, D. J. R. Fischer, and Mr. G. L. Doster of the Southeastern Cooperative Wildlife Disease Study, for their assistance, manuscript review, and photography, and acknowledge Dr. E. E. Provost, School of Forest Resources, University of Georgia, Athens, Georgia for identification of the cottonmouth. Field information was provided by M. D. Bentley and C. P. Martin of Tall Timbers Research, Inc., and Dr. D. W. Speake of the Alabama Cooperative Fish and Wildlife Research Unit. This study was supported in part through sponsorship from the fish and wildlife agencies from the following states: Alabama, Arkansas, Florida, Georgia, Kentucky, Louisiana, Maryland, Tennessee, Virginia, and West Virginia. Funds were provided by the Federal Aid to Wildlife Restoration Act (50 Stat. 917) and through Grant Agreement No. 14-16-0004-89-912), Fish and Wildlife Service, U.S. Department of the Interior.

#### LITERATURE CITED

- BEASLEY, V. R., D. C. DORMAN, AND J. D. FIKES. 1990. A systems affected approach to veterinary toxicology. Vol. 1. Illinois Animal Poison Information Center, Champaign, Illinois, pp. 447-450.
- BENT, A. C. 1937. Life histories of North American birds of prey. Part 1. Dover Publications, Inc., New York, New York, pp. 117-118, 156-158.
- BRUGGER, K. E. 1989. Red-tailed hawk dies with coral snake in talons. *Copeia* 2: 508-510.
- ERNST, C. H. 1992. Venomous reptiles of North America. Smithsonian Institution Press, Washington, D.C., pp. 63-71.
- FRANSON, J. C. 1987. Specimen collection and preservation. In *Field guide to wildlife diseases*, M. Friend (ed.). Resource Publication 167, U.S. Fish and Wildlife Service, Washington, D.C., pp. 7-20.
- HAWGOOD, B. J. 1982. Physiological and pharmacological effects of rattlesnake venoms. In *Rattlesnake venoms*, A. T. Tu (ed.). Marcel Dekker, Inc., New York, New York, pp. 121-162.
- JONES, T. C., AND R. D. HUNT. 1983. *Veterinary pathology*, 5th ed. Lea and Febiger, Inc., Philadelphia, Pennsylvania, pp. 904-905.

- KLAUBER, L. M. 1972. Rattlesnakes: Their habits, life histories, and influence on mankind, Vol. 1. University of California Press, Berkeley, California, pp. 448-450, 621, 1081-1085.
- KNIGHT, R. L., AND A. W. ERICKSON. 1976. High incidence of snakes in the diet of red-tailed hawks. *Raptor Research* 10: 108-110.
- MAY, J. B. 1935. The hawks of North America. The National Association of Audubon Societies, New York, New York, pp. 35-36.
- OKAEME, A. N. 1985. Venom toxicity and haemorrhagia crisis in a guinea fowl. *African Journal of Ecology* 23: 203-204.
- ONOVIRAN, O., B. E. OLUFEMI, AND O. ONUNKWO. 1976. Snake bite in a hen. *The Veterinary Record* 99: 86-87.
- OWNBY, C. L. 1982. Pathology of rattlesnake envenomation. In *Rattlesnake venoms*, A. T. Tu (ed.). Marcel Dekker, Inc., New York, New York, pp. 163-209.
- PARRISH, H. M., J. E. SCATTERDAY, AND C. B. POLLARD. 1957. The clinical management of snake venom poisoning in domestic animals. *Journal of the American Veterinary Medical Association* 130: 548-551.
- TAN, N-H., AND G. PONNUDURAI. 1990. A comparative study of the biological activities of venoms from snakes of the genus *Agkistrodon* (moccasins and copperheads). *Comparative Biochemistry and Physiology* 95: 577-582.

*Received for publication 25 June 1993.*