

## **HISTOPATHOLOGIC FEATURES OF NATURALLY OCCURRING HEPATOOZONOSIS IN WILD MARTENS (MARTES MELAMPUS) IN JAPAN**

Authors: Yanai, Tokuma, Tomita, Atsushi, Masegi, Toshiaki, Ishikawa, Katsuaki, Iwasaki, Toshirou, et al.

Source: Journal of Wildlife Diseases, 31(2) : 233-237

Published By: Wildlife Disease Association

URL: <https://doi.org/10.7589/0090-3558-31.2.233>

---

BioOne Complete ([complete.BioOne.org](https://complete.BioOne.org)) is a full-text database of 200 subscribed and open-access titles in the biological, ecological, and environmental sciences published by nonprofit societies, associations, museums, institutions, and presses.

Your use of this PDF, the BioOne Complete website, and all posted and associated content indicates your acceptance of BioOne's Terms of Use, available at [www.bioone.org/terms-of-use](https://www.bioone.org/terms-of-use).

Usage of BioOne Complete content is strictly limited to personal, educational, and non - commercial use. Commercial inquiries or rights and permissions requests should be directed to the individual publisher as copyright holder.

---

BioOne sees sustainable scholarly publishing as an inherently collaborative enterprise connecting authors, nonprofit publishers, academic institutions, research libraries, and research funders in the common goal of maximizing access to critical research.

## HISTOPATHOLOGIC FEATURES OF NATURALLY OCCURRING HEPATOZOONOSIS IN WILD MARTENS (*MARTES MELAMPUS*) IN JAPAN

Tokuma Yanai,<sup>1,3</sup> Atsushi Tomita,<sup>1</sup> Toshiaki Masegi,<sup>1</sup> Katsuaki Ishikawa,<sup>1</sup>  
Toshirou Iwasaki,<sup>2</sup> Kazuaki Yamazoe,<sup>2</sup> and Katsumoto Ueda<sup>1</sup>

<sup>1</sup> Department of Veterinary Pathology, Gifu University, Yanagido 1-1, Gifu 501-11, Japan

<sup>2</sup> Veterinary Hospital, Gifu University, Yanagido 1-1, Gifu 501-11, Japan

<sup>3</sup> Author for reprint requests

**ABSTRACT:** Nodular lesions containing *Hepatozoon* sp. schizonts or merozoite-gametocytes were found in the tissues of 67 (96%) of 70 wild-caught martens (*Martes melampus*) examined in Gifu, Japan, 1991 and 1992. The heart was the most commonly parasitized organ (96%), followed by the perirenal adipose tissue (36%); the diaphragm, mesentery, tongue, omentum and perisplenic adipose tissue generally had a prevalence of 10 to 15%. In the heart, two types of nodular lesions were differentiated based on developmental stages: nodules containing schizonts and nodules consisting of an accumulation of phagocytes containing merozoites or gamonts. Under electron microscopy, mature schizonts contained membrane-bound merozoites with a single nucleus and small scattered electron-dense cytoplasmic granules in the schizont nodules; the merozoites and gamonts were engulfed in a phagosome-like vacuole of phagocytes with the nucleus compressed to one side due to the parasite in the merozoite-gamont nodule.

**Key words:** *Hepatozoon* sp., marten, *Martes melampus*, Japan.

### INTRODUCTION

Hepatozoonosis has been described in several families of carnivores, with or without apparent disease (Keymer, 1971). *Hepatozoon* sp. infection in the martens (*Martes melampus*) living in Japan has not been reported in the literature and very little is known about the biology of the parasite or the light microscopic features of the life-cycle stages. In the course of a survey on wildlife diseases in Gifu, in the mountainous areas of central Japan, *Hepatozoon* sp. infections frequently were observed in wild-caught martens. Our objective was to describe the histologic features of *Hepatozoon* sp. infection in martens.

### MATERIALS AND METHODS

Formalin-fixed visceral organs of seventy young adult or adult Japanese martens (14 males, 10 females, 46 sex unknown) were obtained from hunters. Seventeen martens were collected in July and August 1991, and another 53 were collected from December 1991 to February 1992. The animals were captured by trappers in the mountainous areas of Gifu (36°30'N, 136°45'E), and did not have signs of disease when found in the traps. A necropsy was performed on each animal immediately after death. Organs and

tissues, including the liver, spleen, kidneys, adrenals, heart, lungs, pancreas, duodenum, ileum, mesenteric lymph nodes, omentum, diaphragm and tongue were collected and fixed in 10% formalin. The peripheral adipose tissue of some organs such as the spleen or kidneys was included whenever possible. The animals were trapped for their fur; thus the skin and subcutis, skeletal muscles, brain and eyes were not sampled. The heart was sectioned horizontally in three regions: atrial, and upper and lower ventricular. Paraffin sections from each organ and tissue, cut at 5  $\mu$ m, were stained with hematoxylin and eosin (H&E).

Cases negative for *Hepatozoon* sp. infection under routine histological section were additionally examined using serial tissue sections. Selected sections from hearts including lesions were stained using the periodic acid-Schiff (PAS), phosphotungstic acid hematoxylin (PTAH), Masson trichrome, and Warthin-Starry methods (Vacca, 1985). Deparaffinized sections of the heart were subjected to immunohistochemistry using labeled streptavidin-biotin (LSAB), according to the manufacturer's instructions (Dako Corporation, Santa Barbara, California, USA). The peroxidase reaction was initiated using 0.06% diaminonenzidine (Daiichi Chemicals, Kumamoto, Japan) and 0.01% H<sub>2</sub>O<sub>2</sub> (Nakai Chemicals, Kyoto, Japan). The sections were counterstained with Mayer's hematoxylin. The antibodies used were anti-myoglobin, anti-lysozyme, and anti-vimentin (Dako Corporation). Samples of formalin-fixed heart were washed in

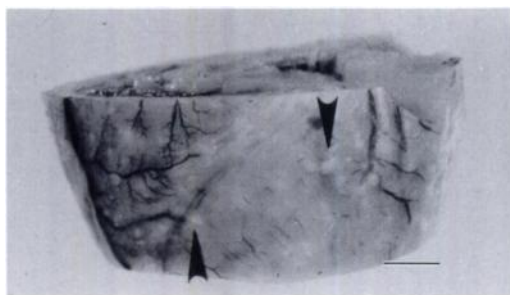


FIGURE 1. Gross appearance of a formalin-fixed heart. Small grayish-white foci (arrow heads) are scattered out on the surface and deep in the heart muscle. Bar = 4 mm.

phosphate buffer, fixed with 2% phosphate buffered glutaraldehyde and 1% osmium tetroxide (Polyscience Incorporation, Warrington, Pennsylvania, USA), and dehydrated in a series of graded ethanols, and embedded in Epon 812 (Polyscience Incorporation). Ultrathin sections were cut and double-stained with uranyl acetate and lead citrate (Reynolds, 1963), and examined with a H-800 electron microscope (Hitachi Limited, Tokyo, Japan).

### RESULTS

Macroscopically, grayish-white small foci were scattered on the surface or in the parenchyma of the heart in six of the 70 martens (Fig. 1).

Histopathologically, 67 (96%) of the 70 martens were infected with *Hepatozoon* sp. Schizonts or merozoite-gametocytes within infected cells were located focally, and formed nodular lesions in the heart or other organs. These stages of *Hepatozoon* sp. were noted in affected tissue sections. We observed *Hepatozoon* sp. in 67 (96%) of 70 heart samples, 25 (36%) of 70 perirenal adipose tissue samples, nine (16%) of 58 diaphragm, 10 (14%) of 68 samples of mesentery, one of seven tongue samples, eight (14%) of 57 omentum samples, and seven (10%) of 70 perisplenic adipose tissue samples. Lower prevalences of infection were seen in the liver (1.4%;  $n = 70$ ) and lung (5.7%;  $n = 70$ ). Each myocardial region had a high prevalence (60 to 77%), and when examined with serial sections, the incidence increased to 96%. In the seven most severely affected hearts, incidence

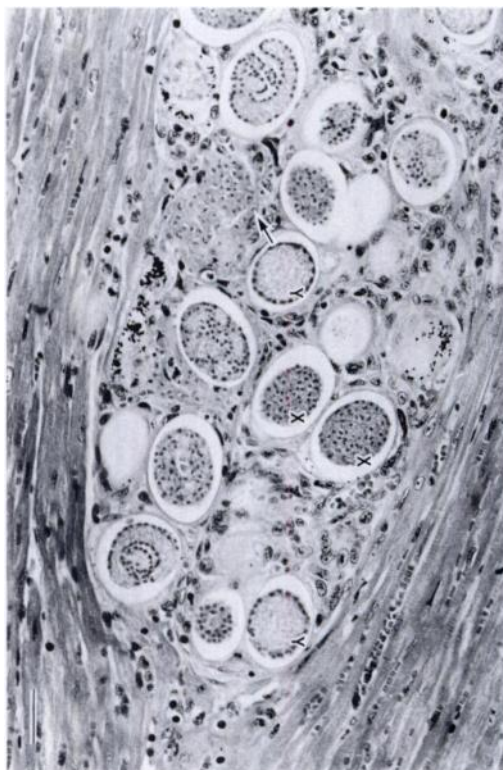


FIGURE 2. X (X) and Y schizont (Y) in a schizont-stage nodule. A schizont (arrow) is ruptured and is releasing merozoites. A mild infiltration surrounds the schizonts. H&E. Bar = 26  $\mu$ m.

of parasitic nodules detected exceeded 10, and often 100, per histologic section; the heart of the remaining 60 martens had at least 10 nodules per section. Other organs or tissues usually possessed one to several parasitic nodules per section.

Young schizonts, and X- and Y-like schizonts were observed (Fig. 2). Sub-spherical schizonts resembling Y schizonts had peripherally arranged nuclei in the schizocyst, while larger spherical schizonts resembling X schizonts were fully packed with nuclei, some of which had matured to merozoites in the schizocyst. Schizonts were surrounded by a clear parasitophorous vacuolar space. The X schizonts were dominant, and accumulations of several schizonts in the same or varying developing stages were observed within one nodule. The size of nodules containing schizonts

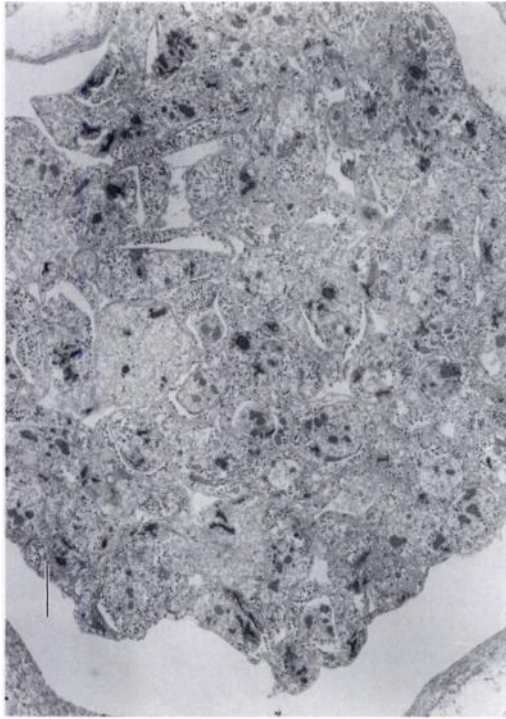


FIGURE 3. Electron micrograph of a schizont in a cardiac muscle cell. Membrane-bound merozoites with a single nucleus and small cytoplasmic granules are packed in a mature schizont. Bar = 2.2  $\mu\text{m}$ .

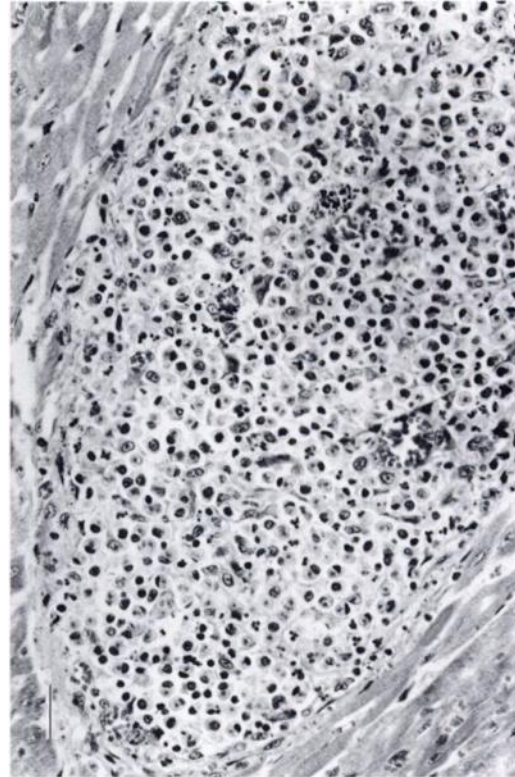


FIGURE 4. A focal microgranuloma in a cardiac muscle cell. Merozoites or gamont are engulfed by phagocytes. H&E. Bar = 26  $\mu\text{m}$ .

ranged from 50 to 400  $\mu\text{m}$  in diameter. Most hepatozoon nodules were accompanied by varying degrees of encapsulating fibrous reaction, but the fibrous reaction was missing in a few instances. Infected host cells appeared to be hypertrophic cardiac muscle cells based on PTAH stain and immunohistochemical stains. The infected cells were stained positively with PTAH stain, and had a positive reaction for myoglobin.

Some nodules contained newly-ruptured schizocysts from which many merozoites were being released. These nodules were accompanied by a severe focal inflammatory infiltration of neutrophils, macrophages and proteinous fluid exudation. The most characteristic feature was the presence of many phagocytes containing merozoites, and the nuclei of infiltrative cells were karyorrhectic or pyknotic. Parasite-laden phagocytes also were found

in vascular canals in and around the nodules. After immunostaining against lysozyme, we observed many positive cells in the nodules. Ultrastructurally, mature schizonts were packed by focal accumulations of merozoites (Fig. 3). Merozoites with thick cell membranes were round in shape and measured approximately  $4.7 \times 3.0 \mu\text{m}$  in size, and possessed a single nucleus measuring  $2.0 \mu\text{m}$  in diameter, as well as small electron-dense granules, measuring approximately 100 nm in diameter, in the cytoplasm.

Merozoite-gamont nodules consisted of an accumulation of phagocytes containing merozoites or gamonts; merozoites and gamonts were difficult to differentiate in H&E-stained tissue sections (Fig. 4). Nodule size varied considerably but usually ranged from 100 to 300  $\mu\text{m}$  in diameter. Nodules were encapsulated in well-devel-



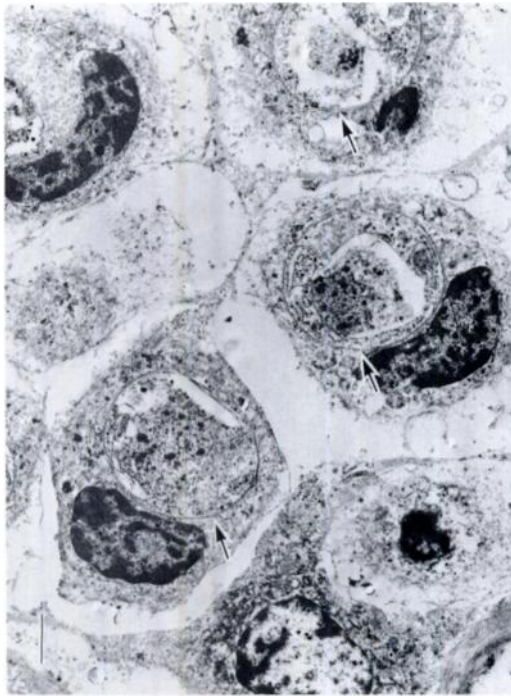


FIGURE 5. Electron micrograph of a merozoite-gamont nodule. Phagocytic cells possess a nucleus with condensed chromatin and concave contour pressed to the one-side due to the presence of a parasite. A gamont was in a phagosome-like vacuole (arrows). Bar = 1.1  $\mu$ m.

oped fibrous tissue. Among the infected cells there were varying numbers of fibrous tissue components with newly formed capillaries. We also observed infiltration of small numbers of neutrophils, eosinophils, and lymphocytic cells. Lymphocytic and plasmacytic infiltration were seen at the periphery of some nodules, while degenerated protozoa-laden phagocytes also were seen in some nodules. Although not frequent, parasite-laden phagocytes were seen in the blood vessels in the parasitic nodules. The phagocytes and protozoa stained poorly with H&E, but staining with PTAH, Warthin-Starry and Masson trichrome produced more discernible results. Unlike phagocytes in the schizont nodules which released merozoites, phagocytes in these nodules were mostly negative for lysozyme by immunostaining. Under the electron microscope, phagocy-

TABLE 1. Frequency and developmental stages of *Hepatozoon* sp. nodules in organs and tissues of martens in Japan, 1991 and 1992.

Number of each parasitic nodule found	Tissues:		
	Heart (n = 67)	Tongue (n = 1) and diaphragm (n = 9)	Adipose tissues (n = 50)
Young	62	7	3
Y-type	26	0	6
X-type	13	1	4
Merozoite-releasing	17	1	3
Merozoite-gamont	244	20	85
Total	362	29	101

tized cells had nuclei with condensed chromatin and concave contours pressed to the periphery of the cell due to the presence of a parasite. A single parasite, merozoite or gamont, was contained in a phagosome-like vacuole (Fig. 5). Parasitized phagocytes in occasional nodules contained several rectangular or polygonal electron-dense granules about  $0.7 \times 0.7 \mu$ m in their cytoplasm.

Nodules of all tissue sections were classified into these described types. In the tongue and diaphragm, parasitic nodules occurred in striated muscle fibers, with young schizonts and merozoite-gamonts being dominant. In adipose tissues and perisplenic connective tissues, various developmental stages were observed, but the merozoite-gamont stage was predominant (Table 1).

#### DISCUSSION

Infections of *Hepatozoon* sp. have been reported in a wide variety of vertebrates. In the Family Mustellidae, several species are known to be susceptible to the infection (Presidente and Karstad, 1971; Novilla et al., 1980). The high prevalence in martens in the present study is evidence that the virulence of this parasite might be low and that exposure is frequent in the wild, as occurs among raccoons (*Procyon lotor*) in Texas (USA) (Clark et al., 1973).

The predilection site of *Hepatozoon* sp. infection in the present study was the heart.

Parasitism of *Hepatozoon* sp. in the heart has been described in several carnivores (Schneider, 1968; Brocklesby, 1971; Davis et al., 1978); however, tissue tropism was thought to be different depending on the animal species (Clark et al., 1973; Davis et al., 1978). In our study, schizonts appeared to occur in the cardiac muscle cell, based on histological and immunohistological findings. Schizonts also were observed in the myofiber of other striated muscles such as the tongue and diaphragm; however, the type of host cells in adipose and other tissues remained unclear in our study.

Many schizont nodules were accompanied by varying degrees of a less intense fibrous reaction and by a mild foreign body tissue reaction containing small amounts of macrophages. In comparison, a marked inflammatory tissue reaction with neutrophils and macrophages was induced in the merozoite-releasing schizont nodules. Exudation of proteins and infiltration of phagocytes in and around the nodule seemed to be a host response to the contents from ruptured schizocysts. At the same time, a fibrous reaction with angioblastic proliferation also was seen in the nodules. These stages may be important to the course of the infection because released merozoites were able to spread easily to the outside of the nodules, then into the general circulation. In the histopathological examination of raccoon tissues, Clark et al. (1973) reported that schizonts occurred in myofibers without any apparent inflammation reaction, and the maturing schizonts then became chemotactic with infiltration of mononuclear inflammatory cells.

The most frequently encountered lesion was the merozoite-gamont nodule. Tissue reaction of this lesion was characterized by well-developed granulation tissues with numerous parasitized phagocytes and rather thick encapsulation; these findings

are evidence for chronicity. Increased amounts of collagen fibers and the presence of seemingly deteriorated parasite-laden phagocytes in some nodules may be interpreted as the healing process of the nodules. However, the confirmed presence of parasite-laden phagocytes, although seen rarely, in intra-nodular capillaries is evidence that this type of nodule still is able to release parasite-laden phagocytes into the circulation. The parasite-laden phagocytes may consist of either granulocytic or monocytic series cell populations.

#### LITERATURE CITED

- BROCKLESBY, D. W. 1971. Illustrations of a *Hepatozoon* species in the heart of a lion. *Journal of Zoology* 164: 525–528.
- CLARK, K. A., R. M. ROBINSON, L. L. WEISHUHN, T. J. GALVIN, AND K. HORVATH. 1973. *Hepatozoon procyonis* infections in Texas. *Journal of Wildlife Diseases* 9: 182–193.
- DAVIS, D. S., R. M. ROBINSON, AND T. M. CRAIG. 1978. Naturally occurring hepatozoonosis in a coyote. *Journal of Wildlife Diseases* 14: 244–246.
- KEYMER, I. F. 1971. Blood protozoa of wild carnivores in central Africa. *Journal of Zoology* 164: 513–524.
- NOVILLA, M. N., J. W. CARPENTER, AND R. P. KWA-PIEN. 1980. Dual infection of Siberian polecats with *Encephalitozoon cuniculi* and *Hepatozoon mustelae* n. sp. In *The comparative pathology of zoo animals*, R. J. Montail and J. Migaki (eds.). Smithsonian Institution Press, Washington, D.C., p. 353.
- PRESIDENTE, P. J. A., AND L. H. KARSTAD. 1971. *Hepatozoon* sp. infection in mink from southwestern Ontario. *Journal of Wildlife Diseases* 11: 479–481.
- REYNOLDS, E. S. 1963. The use of lead citrate at high pH as an electron-opaque stain in electron microscopy. *Journal of Cell Biology* 17: 208–212.
- SCHNEIDER, C. R. 1968. *Hepatozoon procyonis* Richard, 1961, in a Panamanian raccoon, *Procyon carnivoros panamensis* (Goldman). *Revista de Biología Tropical* 15: 123–135.
- VACCA, L. L. 1985. Silver. In *Laboratory manual of histochemistry*. Raven Press, New York, New York, pp. 355–392.

Received for publication 3 June 1994.