



## **Notoedric Mange in the Florida Panther (*Felis concolor coryi*)**

Authors: Maehr, David S., Greiner, Ellis C., Lanier, John E., and Murphy, David

Source: Journal of Wildlife Diseases, 31(2) : 251-254

Published By: Wildlife Disease Association

URL: <https://doi.org/10.7589/0090-3558-31.2.251>

---

BioOne Complete ([complete.BioOne.org](https://complete.BioOne.org)) is a full-text database of 200 subscribed and open-access titles in the biological, ecological, and environmental sciences published by nonprofit societies, associations, museums, institutions, and presses.

Your use of this PDF, the BioOne Complete website, and all posted and associated content indicates your acceptance of BioOne's Terms of Use, available at [www.bioone.org/terms-of-use](https://www.bioone.org/terms-of-use).

Usage of BioOne Complete content is strictly limited to personal, educational, and non - commercial use. Commercial inquiries or rights and permissions requests should be directed to the individual publisher as copyright holder.

---

BioOne sees sustainable scholarly publishing as an inherently collaborative enterprise connecting authors, nonprofit publishers, academic institutions, research libraries, and research funders in the common goal of maximizing access to critical research.

## Notoedric Mange in the Florida Panther (*Felis concolor coryi*)

David S. Maehr,<sup>1,5</sup> Ellis C. Greiner,<sup>2</sup> John E. Lanier,<sup>3</sup> and David Murphy,<sup>4</sup> <sup>1</sup> Game and Fresh Water Fish Commission, 566 Commercial Boulevard, Naples, Florida 33942, USA; <sup>2</sup> Box 110880, Department of Infectious Diseases, College of Veterinary Medicine, University of Florida, Gainesville, Florida 32611, USA; <sup>3</sup> Golden Gate Animal Clinic, 1550 40th Terrace S.W., Naples, Florida 33999, USA; <sup>4</sup> Lowery Park Zoo, 7530 North Boulevard, Tampa, Florida 33604, USA; <sup>5</sup> Present address: Wilkison and Associates, Inc., 3506 Exchange Ave., Naples, Florida 33942, USA

**ABSTRACT:** Notoedric mange (*Notoedres cati*) was found in a neonate Florida panther (*Felis concolor coryi*) and presumably its mother on 22 June 1992 and 8 February 1993, respectively, in Collier County, Florida (USA). Both infestations were treated successfully with 0.2 mg/kg ivermectin. This is the first known case of notoedric mange in the endangered Florida panther.

**Key words:** Florida panther, *Felis concolor*, *Notoedres cati*, mange.

Among North American felids, notoedric mange (*Notoedres cati*) has been reported in domestic cats (*Felis catus*) (Greiner and Werner, 1984) and bobcats (*Felis rufus*) (Pence et al., 1982). Because this mite has a potential to become epizootic, it deserves the attention of managers of wild populations and animals in captivity. We report the first known case of *Notoedres cati* in the Florida panther (*Felis concolor coryi*), an endangered subspecies of the mountain lion.

Female panther number 208, a 10-day-old kitten, was taken from its natal den on the Florida Panther National Wildlife Refuge, Collier County, Florida, USA (26°12'N, 81°25'W), on 6 June 1992 to form a part of a captive breeding population. This kitten was the sole offspring of female number 32 and male number 12, both long-standing, free-ranging, resident adults living in the core of panther range in southwest Florida (Maehr et al., 1991). The den site was characteristically located in a thicket of saw palmetto (*Serenoa repens*), with dense horizontal and vertical cover (Maehr et al., 1990a). Compared to 11 other panther kittens handled at this age, panther number 208 was listless and lethargic when handled. After arrival at the Lowery Park Zoo, Tampa, Florida, it was screened

for feline immunodeficiency virus, feline leukemia virus (Roelke et al., 1993), *Cytauxzoon felis* (Glenn et al., 1982), and treated for mild dehydration. On 16 June female number 208 was dewormed with 20 mg/kg of pyrantel pamoate (Pfizer Animal Health, New York, New York, USA). On 22 June, a mite infestation and perineal dermatitis were discovered and treated subcutaneously with 0.2 mg/kg of ivermectin (MSD Agvet, Rahway, New Jersey, USA) and 18 mg/kg of amoxicillin and clavulanate (Clavamox; SmithKline Beecham, Pittsburg, Pennsylvania, USA), respectively. These treatments were successful in eliminating the mite and dermatitis. Following treatment, panther number 208 developed normally in captivity. Specimens of the mite were identified at the University of Florida College of Veterinary Medicine following descriptions in Kettle (1984) and deposited in the H. W. Manter Laboratory, University of Nebraska State Museum, Lincoln, Nebraska (USA) (accession number HWML 37462).

On 8 February 1993 during a routine recapture (McCown et al., 1990; Maehr et al., 1991) to replace an aging radio-transmitter, female number 32 was anesthetized with 10 mg/kg of ketamine hydrochloride (Ketaset; Fort Dodge Laboratories, Inc., Fort Dodge, Iowa, USA) administered intramuscularly, and was found with signs of a mite infestation. Alopecia was most extreme on the dorsal surface of the head with hair loss estimated at 80% over the rest of her body (Fig. 1). The panther was not emaciated nor did it appear malnourished. However, exposed skin from sternum to abdomen appeared red




FIGURE 1. Florida panther number 32 with suspected notoedric mange.

and irritated. Epidermal biopsies were taken from the affected areas and the panther was treated subcutaneously with 0.2 mg/kg of ivermectin before she recovered from anesthesia. She was retreated on 18 February, 25 March, and 6 May 1993 with 0.2 mg/kg of ivermectin administered intramuscularly with a Telinject remote injection system (Telinject USA, Inc., Saugus, California, USA). Each treatment was made while the cat was alert and after it was chased up a tree so that anesthesia could be avoided. Hair regrowth, especially on face, flanks and back was evident through field glasses on 6 May 1993.

Adult mites from number 208 had the characteristics of *N. cati*. Female mites had terminal suckers on long, unsegmented pedicels on leg pairs 1 and 2 (Fig. 2) and the anus was located on the dorsal surface of the mite, surrounded by scalloped scales (Fig. 3). The males had similar suckers located on leg pairs 1, 2, and 4 (Fig. 4). These mites were indistinguishable from *N. cati* occurring on domestic cats found in Florida (Greiner and Werner, 1984).

On microscopic examinations of skin biopsies taken from female number 32 on 8 February, we found no mites. However, because she was the mother of kitten number 208, and her alopecia was advanced, panther number 32 probably was infected with *N. cati* prior to the birth of kitten

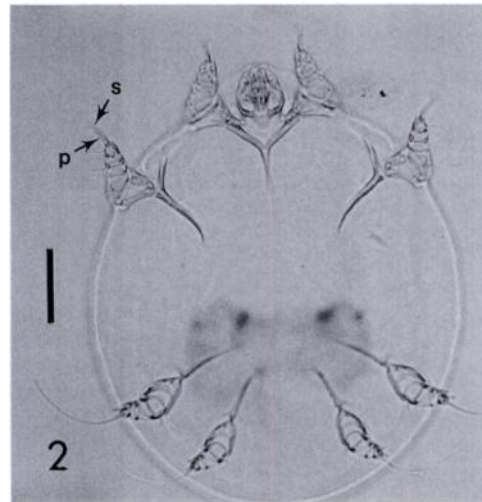


FIGURE 2. Female *Notoedres cati* isolated from Florida panther 208, focusing on the legs; s = sucker, p = long, unsegmented pedicel. Bar = 50  $\mu$ m.

number 208. The kitten, because of her undeveloped state and lack of mobility, almost certainly acquired the mite infection from number 32. The source of the mite infestation in panther number 32 is unknown. However, because direct contact can readily transmit the mite, infested conspecifics or prey such as rabbits (*Sylvilagus* spp.) (Fraser et al., 1991), domestic cats, or bobcats carrying *N. cati* may serve as infective reservoirs. In southwest Florida, panthers consume cottontail rabbits (*Sylvilagus floridanus*) (Maehr et al., 1990b). Florida panthers in Everglades National Park consumed bobcats (O. L. Bass, Jr., pers. comm.) and an experimental western cougar killed and ate a domestic cat in north Florida (Florida Game and Fresh Water Fish Commission files).

Panther number 32 did not have abnormal movement patterns at any time before or after her treatments (D. Maehr, unpubl.), and we believe that she was not physically compromised from the infestation. Differential hematology was conducted by Diagnostic Services, Inc., Naples, Florida on blood samples taken 8 February 1993. Wright-stained eosinophils were immersed in oil and hand-counted at 50 $\times$  and 100 $\times$  under a light

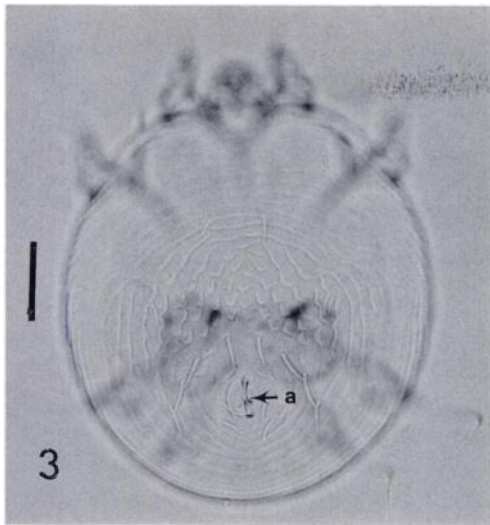


FIGURE 3. Female *Notoedres cati* isolated from Florida panther number 208, focusing on the anus (=a) and dorsal scales. Bar = 50  $\mu$ m.

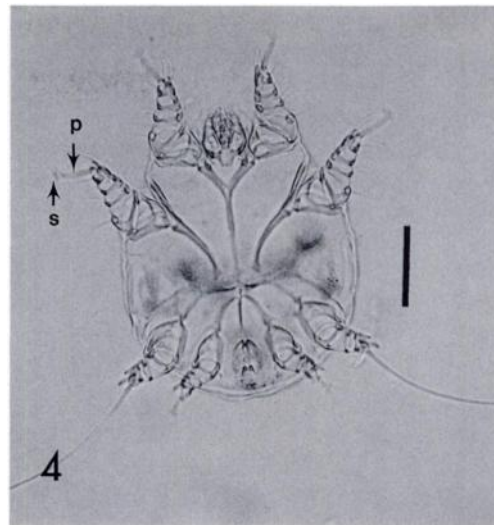


FIGURE 4. Male *Notoedres cati* isolated from Florida panther number 208, focusing on the legs; s = sucker, p = pedicel. Bar = 50  $\mu$ m.

microscope. Elevated levels (2290 eosinophils/ $\mu$ l, 15%) of eosinophils were observed; these elevated levels may have been in response to the mite. Further, *Notoedres cati* can be fatal (Pence et al., 1982), and, given its virulence in Florida bobcats (Wassmer et al., 1988), panther kitten number 208 may not have survived the infection if left untreated.

Given the solitary nature of the Florida panther (Maehr et al., 1991), the potential for the spread of this disease is low and its effect should be local and among few individuals. Nonetheless, managers of this endangered population should be prepared to administer prophylaxis in the field because individual panthers can have significant impacts on the overall productivity of the population. Adult female panthers suffering chronic *N. cati* infestations may be unable to produce offspring to the age of independence and eventual recruitment or may, themselves, be physiologically compromised.

P. Nol, R. McBride, J. Roof, W. McCown, and D. Land provided assistance in the field. M. Dunbar provided biomedical data and J. Gaskin made helpful comments on an earlier draft. Funding for this study

was provided through Federal Endangered Species Project E-1 and the Florida Nongame Wildlife Trust fund. This paper is published as Florida Agricultural Experiment Stations Journal Series Number R-03877.

#### LITERATURE CITED

- FRASER, C. M., J. A. BERGERON, A. MAYS, AND S. E. AIELLO. 1991. The Merck veterinary manual, 7th ed. Merck and Co., Inc., Rahway, New Jersey, 1832 pp.
- GLENN, G. L., R. E. ROLLEY, AND A. A. KOCAN. 1982. *Cytauxoon*-like piroplasms in erythrocytes of wild-trapped bobcats in Oklahoma. *Journal of the American Veterinary Medical Association* 181: 1251-1253.
- GREINER, E. C., AND M. B. WERNER. 1984. Notoedric mange in domestic cats in Florida. *Florida Veterinary Journal* 13: 28-29.
- KETTLE, D. S. 1984. Medical and veterinary entomology. Croom Helm Ltd., London, England, 658 pp.
- MAEHR, D. S., E. D. LAND, J. C. ROOF, AND J. W. MCCOWN. 1990a. Day beds, natal dens, and activity of Florida panthers. *Proceedings of the Annual Conference of the Southeastern Association of Fish and Wildlife Agencies* 44: 310-318.
- , R. C. BELDEN, E. D. LAND, AND L. WILKINS. 1990b. Food habits of panthers in southwest Florida. *The Journal of Wildlife Management* 54: 420-423.
- , E. D. LAND, AND J. C. ROOF. 1991. Social

- ecology of Florida panthers. *National Geographic Research and Exploration* 7: 414-431.
- MCCOWN, J. W., D. S. MAEHR, AND J. ROBOSKI. 1990. A portable cushion as a wildlife capture aid. *Wildlife Society Bulletin* 18: 34-36.
- PENCE, D. B., F. D. MATTHEWS, III, AND L. A. WINDBERG. 1982. Notoedric mange in the bobcat, *Felis rufus*, from south Texas. *Journal of Wildlife Diseases* 18: 47-50.
- ROELKE, M. E., D. J. FORRESTER, E. R. JACOBSON, G. V. KOLLIAS, F. W. SCOTT, M. C. BARR, J. F. EVERMANN, AND E. C. PIRTLE. 1993. Seroprevalence of infectious disease agents in free-ranging Florida panthers (*Felis concolor coryi*). *Journal of Wildlife Diseases* 29: 36-49.
- WASSMER, D. A., D. D. GUENTHER, AND J. N. LAYNE. 1988. Ecology of the bobcat in south-central Florida. *Bulletin of the Florida State Museum: Biological Sciences* 33: 159-228.

*Received for publication 14 June 1994.*