

## **Isolation of *Mycoplasma felis* from a Serval (*Felis serval*) with Severe Respiratory Disease**

Authors: Johnsrude, J. D., Christopher, M. M., Lung, N. P., and Brown, M. B.

Source: Journal of Wildlife Diseases, 32(4) : 691-694

Published By: Wildlife Disease Association

URL: <https://doi.org/10.7589/0090-3558-32.4.691>

---

BioOne Complete ([complete.BioOne.org](https://complete.BioOne.org)) is a full-text database of 200 subscribed and open-access titles in the biological, ecological, and environmental sciences published by nonprofit societies, associations, museums, institutions, and presses.

Your use of this PDF, the BioOne Complete website, and all posted and associated content indicates your acceptance of BioOne's Terms of Use, available at [www.bioone.org/terms-of-use](https://www.bioone.org/terms-of-use).

Usage of BioOne Complete content is strictly limited to personal, educational, and non - commercial use. Commercial inquiries or rights and permissions requests should be directed to the individual publisher as copyright holder.

---

BioOne sees sustainable scholarly publishing as an inherently collaborative enterprise connecting authors, nonprofit publishers, academic institutions, research libraries, and research funders in the common goal of maximizing access to critical research.

## Isolation of *Mycoplasma felis* from a Serval (*Felis serval*) with Severe Respiratory Disease

J. D. Johnsrude,<sup>1</sup> M. M. Christopher,<sup>2</sup> N. P. Lung,<sup>3</sup> and M. B. Brown,<sup>4\*</sup> Department of Physiological Sciences, Box 100144, College of Veterinary Medicine, University of Florida, Gainesville, Florida, 32610, USA; Department of Pathology, Microbiology and Immunology, School of Veterinary Medicine, University of California, Davis, California, 95616, USA; <sup>3</sup> Department of Small Animal Clinical Sciences, College of Veterinary Medicine, University of Florida, Gainesville, Florida, 32610, USA; and <sup>4</sup> Department of Pathobiology, Box 110926, College of Veterinary Medicine, University of Florida, Gainesville, Florida, 32610, USA

**ABSTRACT:** We report cytologic observations and isolation of *Mycoplasma felis* in September 1992 from the lower respiratory tract of a 3-week-old captive serval (*Felis serval*) cub with pneumonia, in Florida (USA). Septic, neutrophilic inflammation with a large, monomorphic population of unique, pleomorphic, intracellular and extracellular rods was diagnosed from a transtracheal wash. *Mycoplasma felis* was the only bacterium isolated in significant numbers from the transtracheal wash.

**Key words:** *Felis serval*, serval, transtracheal wash, *Mycoplasma felis*, mycoplasmosis, pneumonia.

For many years, controversy has existed over the pathogenicity of *Mycoplasma* spp. in various hosts. Because mycoplasmas are isolated from the conjunctiva, upper respiratory tract and urogenital tracts of asymptomatic animals, the actual role of mycoplasma in producing disease has been ambiguous in some species (Rosendal, 1990; Bemis, 1992). Culture of mycoplasma involves an increased amount of time relative to routine bacterial cultures and special techniques generally are necessary for identification and speciation; therefore, knowledge of the prevalence of mycoplasma species among various animals remains incomplete. This is especially true in exotic or wild animal species. We describe the cytologic detection of a monomorphic population of microorganisms in a transtracheal wash from a 3-wk-old serval (*Felis serval*) which subsequently was euthanized due to severe respiratory disease. The only microorganism isolated in significant numbers was identified as *Mycoplasma felis*.

A 3-wk-old serval was admitted to the University of Florida Veterinary Medical Teaching Hospital, Gainesville, Florida (USA), with a 1-day history of pneumonia.

The serval's litter and dam were being raised by a private individual, and had been housed in close association with domestic cats. The cub apparently received no colostrum and had been bottle fed a mixture of kitten milk replacement, goat milk, and a small amount of rice cereal since birth. An unspecified dose of amoxicillin (Amoxidrops<sup>®</sup>, Smith Kline Beecham, Inc., Pennsylvania, USA) had been administered prophylactically on a daily basis since birth. There was no history of aspiration, and the two littermates appeared healthy.

On physical examination, the cub was recumbent, depressed, slightly dehydrated and weighed 396 g. The cub had a dull, dry hair coat, was thin and the abdomen was doughy on palpation. Crackles and wheezes were ausculted bilaterally. Initial treatment included placement in an oxygen cage with 40% oxygen as well as administration of 10 ml of subcutaneous lactated Ringer's solution, 6.3 ml of intravenous lactated Ringer's solution, and a single dose of 15 mg intravenous cephalexin (Keflin<sup>®</sup>, Eli Lilly and Co., Indianapolis, Indiana, USA). The cub was anesthetized by face mask with 2% isoflurane (Aerane<sup>®</sup>, Anaquest, Madison, Wisconsin, USA), to obtain blood samples, radiographs, and a transtracheal wash.

A complete blood count was done using a Coulter S+IV (Coulter Diagnostics, Hialeah, Florida) automated cell counting instrument. Differential leukocyte counts were done on Wright-Giemsa-stained (Wright's stain, Biochemical Sciences, Inc., Bridgeport, New Jersey, USA; Giemsa Modified Azure Blend Type, Harleco,

Gibbstown, New Jersey) blood smears. Abnormal hematologic findings included leukopenia with 63 nucleated red blood cells (nRBC) per 100 leukocytes. The packed cell volume was 33%. The corrected white blood count was 2,500 cells/ $\mu$ l with a differential white blood cell count (WBC) of 200 segmented neutrophils/ $\mu$ l, 150 band neutrophils/ $\mu$ l, 130 metamyelocytes/ $\mu$ l, 1,230 lymphocytes/ $\mu$ l, 650 monocytes/ $\mu$ l, 50 eosinophils/ $\mu$ l and 100 basophils/ $\mu$ l. Neutrophils were markedly toxic in appearance, with foamy, basophilic cytoplasm and Dohle bodies. Erythrocytes had mild polychromasia and anisocytosis. Plasma proteins were 5.0 g/dl; hyperfibrinogenemia (400 mg/dl) was present. On thoracic and abdominal radiographs, there was a marked atelectasis of cranial and right caudal lung lobes and poor abdominal detail, respectively; aeration was present only in the left caudal lung lobe.

A transtracheal wash was done via an endotracheal tube, and direct smears were stained with Wright-Giemsa for cytologic evaluation. The background contained abundant particulate debris and cellularity was low, with scattered epithelial cells and neutrophils that were markedly degenerate in appearance. A large, monomorphic population of small rods approximately 1  $\mu$ m in length was observed both intracellularly and extracellularly (Fig. 1). The microorganisms often appeared comma-shaped, and were characterized by polar staining and a small tail. Large clusters of the bacteria were observed, sometimes covering the surface of epithelial cell clumps. Occasional larger bacterial rods also were noted. The morphologic findings of the bacterium on cytology prompted the microbiologists to consider the specialized conditions for culture of *Mycoplasma* spp. Columbia CNA culture media (Remel<sup>®</sup> Columbia CNA agar with 5% sheep blood, Lenexa, Kansas, USA) and MacConkey agar (Remel<sup>®</sup>, Lenexa, Kansas, USA) were used to isolate the Gram positive and Gram negative bacteria, respectively. Speciation of the *Escherichia coli* was

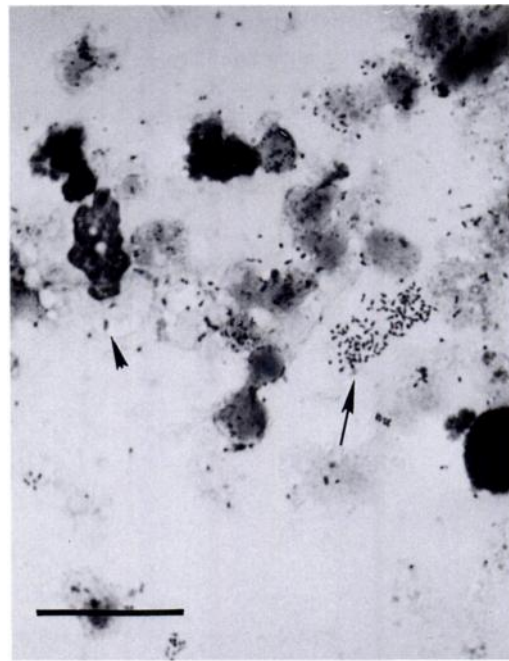


FIGURE 1. Direct smear of a transtracheal wash specimen from a serval (*Felis serval*) with mycoplasmal pneumonia. A cluster of organisms consistent with *Mycoplasma* sp. are present in the background (arrow) as well as within a degenerating neutrophil (arrowhead). Wright-Giemsa stain. Bar = 17  $\mu$ m.

achieved by using the API 20E biochemical strip (bioMérieux Vitek, Inc., Hazelwood, Montana, USA). The other microorganisms were further identified by use of colony morphology and biochemical characteristics as described by Carter and Chengappa, (1991). Culture of the transtracheal aspirate on Columbia agar with 5% sheep blood (Remel, Lenexa, Kansas, USA) at 37 C for 72 hr yielded 100% mycoplasma organisms, with <1% of several other isolates that included *Escherichia coli*, *Streptococcus* spp., *Corynebacterium* sp., *Staphylococcus* spp., *Proteus* sp. and *Pseudomonas* sp.. The mycoplasma was subcultured into SP4 broth as previously described by Brown et al., (1990). Broth cultures were incubated at 37 C in ambient air. When a color change occurred, indicating mycoplasma growth, the broth was subcultured to SP4 agar and incubated at 37 C in 5% carbon dioxide (Tully et

al., 1975). Identification as *Mycoplasma felis* was made using an immunobinding assay (Brown et al., 1990). The cub was euthanized with a combination of pentobarbital and phenytoin (Beuthanasia-D®, Schering-Plough Animal Health Corporation, Kenilworth, New Jersey, USA) due to the poor prognosis and was unavailable for necropsy.

A controversial aspect on the pathogenicity of mycoplasmas is that they have been isolated from both diseased and asymptomatic animals (Tan and Miles, 1974; Haesebrouck et al., 1991). Mycoplasmas can be isolated from the upper respiratory tract (Schneck, 1973) and the lower genital tracts of asymptomatic dogs and cats (Rosendal, 1990). *Mycoplasma felis* is one of the species that inhabits these tissues in cats (Blackmore et al., 1973). In rats, *Mycoplasma pulmonis* may be transmitted in utero (Steiner et al., 1993). The source of infection for the cub in this report is unknown as the littermates, dam, and domestic cats in contact with the cub were not cultured. Because *M. felis* has been isolated from healthy animals, we hypothesized that one of the animals in contact with the cub was a carrier.

Mycoplasmas more often are associated with diseased than healthy lungs (Ogilvie et al., 1983; Bemis, 1992). *Mycoplasma* spp. infections of the lower respiratory tract of cats are relatively rare and thought to occur as opportunistic infections in immunocompromised hosts (Bemis, 1992). In one cat, a pulmonary abscess that occurred as an extension from an external wound was determined to be secondary to mycoplasma (Crisp et al., 1987). *Mycoplasma felis* also was isolated as the causative agent of polyarthritis in an immunocompromised cat, as determined by history and clinical signs. The histologic observation of lymphocyte depletion in lymph nodes and spleen (Hooper et al., 1985) was supportive of the immunocompromised state. Although the cub in the present report was not documented to be immunocompromised, the history of it

having received no colostrum at birth is evidence that it may not have received adequate maternal antibodies.

Because mycoplasmas lack a cell wall, the amoxicillin treatments given to the cub would have been ineffective. Indeed, *M. felis* was more likely to be isolated from cats given penicillin than from cats that did not receive the antibiotic (Schneck, 1973). This was postulated to be due to loss of competition from other bacteria, which allowed *M. felis* to colonize more readily.

Isolation of mycoplasmas is best achieved by the use of special, enriched media; however, some species may be isolated after 72 hr growth on blood agar (Freundt, 1983). Because agar plates are not routinely observed for an extended period of time, the incidence of mycoplasmal infections in cats and other species may be higher than currently reported. Mycoplasma infection was not originally considered in the serval; however, because of the cytologic observation of a population of pleomorphic microorganisms morphologically consistent with *Mycoplasma* spp., prolonged incubation of the blood agar plates was done, and allowed isolation of *M. felis*. The unique appearance of the characteristic, small, pleomorphic bacterial rods is evidence that microscopic recognition of the microorganism may be useful in the evaluation of cytologic specimens. Awareness of these specialized conditions for culture and identification of mycoplasmas is necessary for definitive diagnosis.

In this case, the pleomorphic rods characteristic of mycoplasma were seen in a cytologic preparation and prompted the microbiologists to pursue a culture for *Mycoplasma* sp.. While we hypothesized that *M. felis* infection played an important role in the clinical pneumonia that was present, necropsy and histopathology were not permitted by the owner of the animal. Likewise, serologic tests and follow-up cultures were not performed to rule out concurrent viral or chlamydial infections in the affected cub or its littermates and dam.

The hematologic abnormalities seen in

the cub may be explained by severe bacterial infection. Toxic neutrophilic changes can occur secondary to septicemia, severe bacterial infections, acute inflammation and extensive burns (Jain, 1986). The septic inflammation and the culture of *Mycoplasma felis* from the tracheal wash supports a bacterial infection as the cause of the toxic changes. It is unknown if the cub was septicemic, as no blood cultures were performed. Release of nRBCs, as noted in this cub, was considered inappropriate in the absence of an erythroid regenerative response (reticulocytosis). Inappropriate release of nRBCs can occur due to infection and septicemia (Jain, 1986). Characterizing the cause of hypoproteinemia requires biochemical analysis and serum protein electrophoresis, which were not done in this cub. Possible causes of hypoproteinemia in young animals include decreased intake of colostrum or increased loss through the gastrointestinal tract or kidneys. The hyperfibrinogenemia may be secondary to an acute phase response which can occur with bacterial sepsis.

The isolation of *M. felis* in such significant amounts from an animal with severe respiratory disease is evidence for its potential pathogenicity in this species. *Mycoplasma felis* should be considered as a differential diagnosis in wild felids, especially in possibly immunocompromised hosts and in cases of pneumonia that are resistant to penicillins. Cytologic identification of the organism with its characteristic morphology should prompt a request for the special culture conditions required for the definitive identification of mycoplasmas.

The authors acknowledge An Nguyen and the Clinical Microbiology Laboratory at the College of Veterinary Medicine, University of Florida, Gainesville, Florida, for consultation on this case.

#### LITERATURE CITED

- BEMIS, D. A. 1992. *Bordetella* and *Mycoplasma* respiratory infections in dogs and cats. *Veterinary Clinics of North America* 22: 1173–1186.
- BLACKMORE, D. K., A. HILL, AND O. F. JACKSON. 1971. The incidence of mycoplasma in pet and colony maintained cats. *Journal of Small Animal Practice* 12: 207–217.
- BROWN, M. B., P. GIONET, AND D. F. SENIOR. 1990. Identification of *Mycoplasma felis* and *Mycoplasma gateae* by an immunobinding assay. *Journal of Clinical Microbiology* 28: 1870–1873.
- CARTER, G. R., AND M. M. CHENGAPPA. 1991. In *Essentials of veterinary bacteriology and mycology*, 4th ed. Lea and Febiger, Philadelphia, Pennsylvania, pp. 109, 115, 157, 165–166.
- CRISP, M. S., S. J. BIRCHARD, A. E. LAWRENCE, AND J. FINGEROTH. 1987. Pulmonary abscess caused by a *Mycoplasma* sp. in a cat. *Journal of the American Veterinary Medical Association* 191: 340–342.
- FREUNDT, E. A. 1983. Culture media for classic mycoplasmas. In *Methods in mycoplasmaology*, Vol. I. Academic Press, Inc., New York, New York, pp. 127–135.
- HAESEBROUCK, F., L. A. DEVRIESE, B. VAN RIJSEN, AND E. COX. 1991. Incidence and significance of *Mycoplasma felis* from conjunctival swabs of cats. *Veterinary Microbiology* 26: 95–101.
- HOOPER, P. T., L. A. IRELAND, AND A. CARTER. 1985. Mycoplasma polyarthrititis in a cat with probable severe immune deficiency. *Australian Veterinary Journal* 62: 352–355.
- JAIN, N. C. 1986. *Schalm's veterinary hematology*, 4th ed., Lea and Febiger, Philadelphia, Pennsylvania, pp. 499, 715.
- OGILVIE, T. H., S. ROSENDAL, T. E. BLACKWELL, C. M. ROSTKOWSKI, R. J. JULIAN, AND L. RUHNKE. 1983. *Mycoplasma felis* as a cause of pleuritis in horses. *Journal of the American Veterinary Medical Association* 182: 1374–1376.
- ROSENDAL, S. 1990. Mycoplasmal infections. In *Infectious diseases of the dog and cat*, L. E. Mills (ed.), W. B. Saunders, Philadelphia, Pennsylvania, pp. 446–449.
- SCHNECK, G. 1973. Mycoplasma in a cat colony. *Veterinary Medicine/Small Animal Clinician* 68: 381–382.
- STEINER, D. A., E. W. UHL, AND M. G. BROWN. 1993. *In utero* transmission of *Mycoplasma pulmonis* in experimentally-infected Sprague Dawley rats. *Infection and Immunity* 61: 2985–2999.
- TAN, R. S. J., AND J. A. R. MILES. 1974. Incidence and significance of mycoplasmas in sick cats. *Research in Veterinary Science* 16: 27–34.
- TULLY, J. G., R. F. WHITCOMB, H. F. CLARK, AND D. L. WILLIAMSON. 1975. Pathogenic mycoplasmas: Cultivation and vertebrate pathogenicity of a new spiroplasma. *Science* 195: 829–894.

*Received for publication 14 January 1994.*