

Mycoplasmal Conjunctivitis in a European Starling

Authors: Frasca, S., Hinckley, Lynn, Forsyth, Mark H., Gorton, Timothy S., Geary, Steven J., et al.

Source: Journal of Wildlife Diseases, 33(2) : 336-339

Published By: Wildlife Disease Association

URL: <https://doi.org/10.7589/0090-3558-33.2.336>

BioOne Complete (complete.BioOne.org) is a full-text database of 200 subscribed and open-access titles in the biological, ecological, and environmental sciences published by nonprofit societies, associations, museums, institutions, and presses.

Your use of this PDF, the BioOne Complete website, and all posted and associated content indicates your acceptance of BioOne's Terms of Use, available at www.bioone.org/terms-of-use.

Usage of BioOne Complete content is strictly limited to personal, educational, and non - commercial use. Commercial inquiries or rights and permissions requests should be directed to the individual publisher as copyright holder.

BioOne sees sustainable scholarly publishing as an inherently collaborative enterprise connecting authors, nonprofit publishers, academic institutions, research libraries, and research funders in the common goal of maximizing access to critical research.

Mycoplasmal Conjunctivitis in a European Starling

S. Frasca Jr.,^{1,2} Lynn Hinckley,² Mark H. Forsyth,³ Timothy S. Gorton,² Steven J. Geary,² and Herbert J. Van Kruiningen,^{1,2} ¹ Northeastern Research Center for Wildlife Diseases and ² Department of Pathobiology, University of Connecticut, 61 North Eagleville Road, U-89, Storrs, Connecticut 06269-3089, USA; ³ Department of Medicine, Division of Infectious Diseases, Vanderbilt University, Nashville, Tennessee 37232-2605, USA

ABSTRACT: Bilateral conjunctivitis and episcleritis were identified in an adult European starling (*Sturnus vulgaris*). A novel mycoplasma species, *Mycoplasma sturni*, was isolated in pure culture from the conjunctiva of both eyes. The clinical presentation was similar to that of conjunctivitis in house finches (*Carpodacus mexicanus*) caused by *Mycoplasma gallisepticum*. However, the histologic lesions were distinct, by the presence of ulceration and epithelial hyperplasia and lacking a lymphoplasmacytic infiltration. *Mycoplasma sturni* ferments glucose, does not hemadsorb or hemagglutinate chicken erythrocytes, and grows rapidly at 37 C in comparison to other *Mycoplasma* spp. The role of *M. sturni* in conjunctivitis in other passerine species is presently unknown.

Key words: Conjunctivitis, European starling, eye, *Mycoplasma sturni*, *Sturnus vulgaris*.

A live adult male European starling (*Sturnus vulgaris*) from southwestern Connecticut (USA) was presented for study to the Northeastern Research Center for Wildlife Diseases (University of Connecticut, Storrs, Connecticut, USA) on 23 December 1994. The bird was emaciated, lethargic, and apparently blind. Severe bilateral conjunctivitis with moderate bilateral blepharitis was evident, and mucocaceous exudates distended the lower conjunctival sacs. Left and right conjunctival sacs and the choana were cultured using mini-tip culturettes (Becton Dickinson Microbiology Systems, Cockeysville, Maryland, USA). The bird was humanely killed by cervical dislocation, and blood was collected for serologic testing. Necropsy was performed immediately after death, and tissue samples of the brain, trachea, lung, liver, heart, skeletal muscle, kidney, esophagus, ventriculus, proventriculus, small intestine, conjunctivae and eyes were obtained and fixed in 10% neutral buffered formalin.

Fortified Commercial broth (Macy,

1980) was inoculated with swabs from the left and right conjunctiva and the choana. Inoculated broths were incubated for 10 hr at 37 C and then were passed through a 0.45 µm filter (Gelman Sciences, Ann Arbor, Michigan, USA). Broths were plated onto Fortified Commercial agar (Macy, 1980), and plates were incubated in a humidified environment at 37 C for 38 hr. Within 48 hr heavy growth of mycoplasmas with typical fried-egg colony morphology (Freundt and Edward, 1979) was evident. The isolate catabolized glucose, failed to grow in the absence of serum, and failed to hemagglutinate or hemadsorb chicken erythrocytes. DNA sequence analysis of the 16S ribosomal RNA gene (Forsyth et al., 1996) demonstrated that this isolate represented a new species of mycoplasma, which was subsequently named *Mycoplasma sturni* (Forsyth et al., 1996). Swabs from the left and right conjunctiva and the choana also were used to streak bovine blood agar plates (Difco Laboratories, Detroit, Michigan, USA) that were incubated for 48 hr at 37 C; no other organism was recovered.

Serum was tested for the presence of antibodies to *Mycoplasma gallisepticum* (MG) and *Mycoplasma synoviae* (MS). Serum-plate agglutination tests (Kleven and Yoder, 1989), performed according to United States Department of Agriculture (1994) guidelines using S-6 Serotype MG antigen and S-Serotype MS antigen (Intervet, Nobilis, Millsboro, Delaware, USA), were negative. Hemagglutination tests (United States Department of Agriculture, 1994) using SR 100 MG antigen and SR 120 MS antigen (National Veterinary Services Laboratories, Ames, Iowa, USA) also were negative.

Formalin-fixed tissues were processed

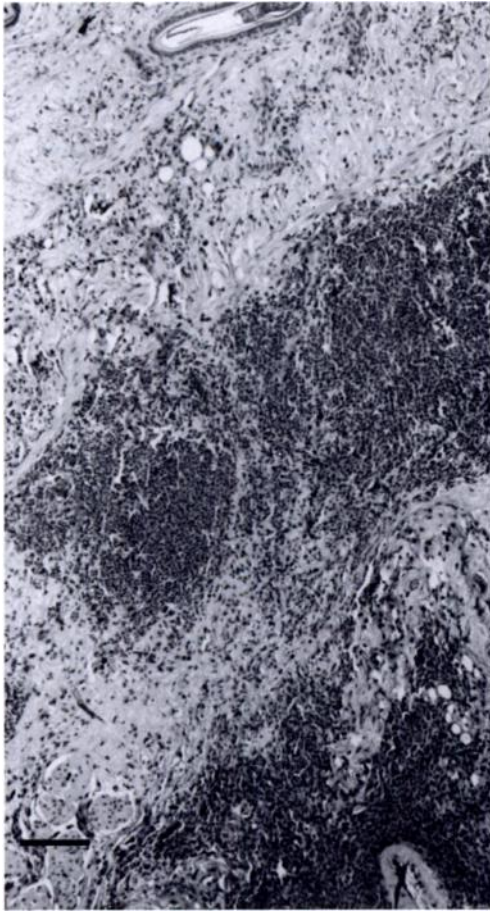


FIGURE 1. Deep subepithelial connective tissue of the palpebral conjunctiva with locally extensive hemorrhage. H&E. Bar = 100 μ m.

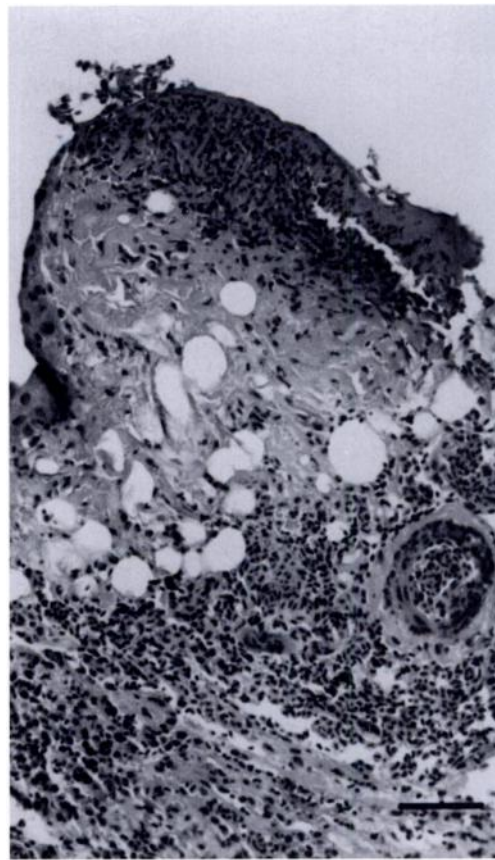


FIGURE 2. Conjunctiva of a European starling (*Sturnus vulgaris*) with necrosis of the mucosal epithelium accompanied by hemorrhage and infiltrates of heterophils and macrophages in the subepithelial connective tissue stroma. H&E. Bar = 50 μ m.

routinely, embedded in paraffin, sectioned at 3 μ m and stained with hematoxylin and eosin (HE). Tissue sections of the eye also were stained with periodic acid-Schiff, Wolbach's Giemsa, Warthin-Starry, and Brown and Hopps tissue Gram stain (Luna, 1968). Based on histologic examination, an acute conjunctivitis with focal mucosal ulceration was present. Congestion and locally extensive hemorrhage were present in subepithelial connective tissue of the conjunctiva, accompanied by aggregates of lymphocytes, macrophages and heterophils (Figs. 1, 2). Arterioles in subepithelial connective tissue had heterophilic infiltrations of the tunica media (Fig. 3). Marked hemorrhage along seg-

ments of the episclera was present with accumulations of heterophils and mononuclear leukocytes. Necrosis of myofibers of extraocular muscles was present, along with interstitial hemorrhage and aggregates of heterophils and macrophages. Severe hemorrhage was evident in the anterior and posterior chambers and vitreous body.

Upper respiratory tract infection of chickens and turkeys by *M. gallisepticum* characteristically results in epithelial cell hyperplasia with mycoplasmas adherent to cell surfaces, edema of subepithelial connective tissue and initial subepithelial infiltrates of heterophils followed by lymphocytes and lymphoid germinal centers

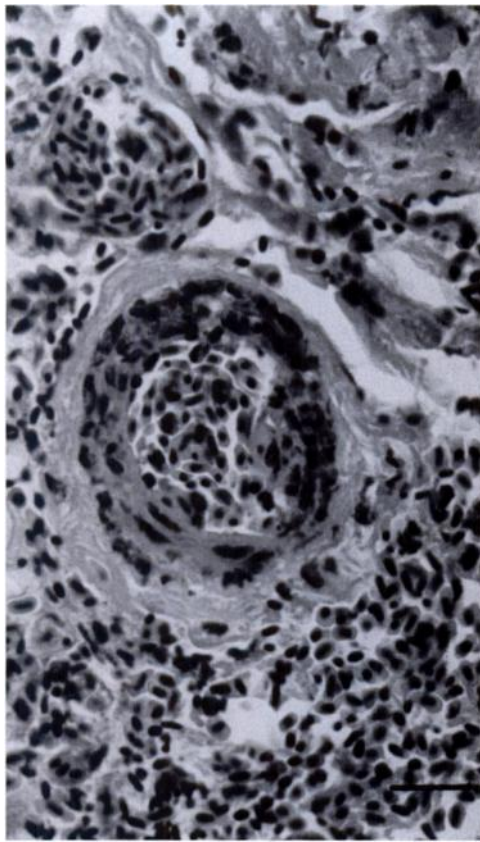


FIGURE 3. Higher magnification of Figure 2 demonstrating the segmental heterophilic infiltration of an arteriole of the subepithelial stroma. Note the hemorrhage surrounding this arteriole. H&E. Bar = 20 μ m.

(Jordan, 1975; Riddell, 1987). Although the clinical presentation mimicked that of epizootic conjunctivitis in house finches (*Carpodacus mexicanus*), the *M. sturni*-associated conjunctivitis was histologically different, possessing ulceration and heterophilic vasculitis and lacking the epithelial hyperplasia characteristic of MG infection and the lymphoplasmacytic infiltrates reported in house finches (Ley et al., 1996; Luttrell et al., 1996). In addition, the ocular lesions reported here differ substantially from those described in chickens infected with *M. gallisepticum*, where ocular changes are confined to the corneal epithelium and stroma (Nunoya et al., 1995).

Along with conjunctivitis and episcleritis, additional necropsy findings in this

bird included coccidiosis and esophageal, ventricular and intestinal nematodiasis. The emaciation indicates that this bird was chronically ill. However, the conjunctival lesions were acute to subacute based on histologic interpretation, suggesting that the bird had recently acquired the conjunctivitis. Conjunctivitis is a common lesion of viral respiratory diseases of poultry (Riddell, 1987), and viruses such as herpesvirus have been associated with epithelial necrosis and ulceration in birds such as pigeons (Calnek, 1991). The possibility of co-infection of this debilitated bird by another agent that was not identified cannot be dismissed, especially since attempts were not made at virus isolation. The role of *M. sturni* in conjunctivitis would be evaluated best by experimental infection.

The prevalence of *M. sturni* in wild populations of European starlings is not known. However, *M. sturni* has been isolated from a mockingbird (*Mimus polyglottos*) with conjunctivitis in Connecticut.

We acknowledge J. Dickson of the Connecticut Department of Environmental Protection, Wildlife Division, for coordinating the submissions of passerine birds, and we are grateful to J. Wrzesien of the Connecticut Veterinary Diagnostic Laboratory for performing the serologic tests. This is contribution #1708 of the Storrs Agricultural Experiment Station.

LITERATURE CITED

- CALNEK, B. W. 1991. Miscellaneous virus infections. In *Diseases of poultry*, 9th ed., B. W. Calnek, H. J. Barnes, C. W. Beard, W. M. Reid, and H. W. Yoder, Jr. (eds.). Iowa State University Press, Ames, Iowa, pp. 664–701.
- FORSYTH, M. H., J. G. TULLY, T. S. GORTON, L. HINCKLEY, S. FRASCA, JR., H. J. VAN KRUIINGEN, AND S. J. GEARY. 1996. *Mycoplasma sturni* sp. nov., from the conjunctiva of a European starling (*Sturnus vulgaris*). *International Journal of Systematic Bacteriology* 46: 716–719.
- FREUNDT, E. A., AND D. G. EDWARD. 1979. Classification and taxonomy. In *The mycoplasmas, cell biology*, Vol. 1, M. F. Barile and S. Razin (eds.). Academic Press, Inc., New York, New York, pp. 23–29.
- JORDAN, F. T. W. 1975. Avian mycoplasma and

- pathogenicity—A review. *Avian Pathology* 4: 165–174.
- KLEVEN, S. H., AND H. W. YODER. 1989. Mycoplasmosis. In *A laboratory manual for the isolation and identification of avian pathogens*, 3rd ed., H. G. Purchase, L. H. Arp, C. H. Domermuth, and J. E. Pearson (eds.). Kendall/Hunt Publishing Company, Dubuque, Iowa, pp. 57–62.
- LEY, D. H., J. E. BERKHOFF, AND J. M. McLAREN. 1996. *Mycoplasma gallisepticum* isolated from house finches (*Carpodacus mexicanus*) with conjunctivitis. *Avian Diseases* 40: 480–483.
- LUNA, L. G. 1968. *Manual of histologic staining methods of the Armed Forces Institute of Pathology*, 3rd ed. McGraw-Hill Book Company, New York, New York, pp. 1–258.
- LUTTRELL, M. P., J. R. FISCHER, D. E. STALLKNECHT, AND S. H. KLEVEN. 1996. Field investigation of *Mycoplasma gallisepticum* infections in house finches (*Carpodacus mexicanus*) from Maryland and Georgia. *Avian Diseases* 40: 335–341.
- MACY, M. L. 1980. Tests for mycoplasmal contamination of cultured cells as applied at the ATCC. *Tissue Culture Association Manual* 5: 1151–1155.
- NUNOYA, T., T. YAGIHASHI, M. TAJIMA, AND Y. NAGASAWA. 1995. Occurrence of keratoconjunctivitis apparently caused by *Mycoplasma gallisepticum* in layer chickens. *Veterinary Pathology* 32: 11–18.
- RIDDELL, C. 1987. Respiratory system. In *Avian histopathology*, 1st ed. The American Association of Avian Pathologists, University of Pennsylvania, Kennett Square, Pennsylvania, pp. 37–45.
- RIDDELL, C. 1987. Nervous system. In *Avian histopathology*, 1st ed. The American Association of Avian Pathologists, University of Pennsylvania, Kennet Square, Pennsylvania, pp. 75–81.
- UNITED STATES DEPARTMENT OF AGRICULTURE. 1994. National Poultry Improvement Plan and Auxiliary Provisions. Publication APHIS 91-55-021, Animal and Plant Health Inspection Service, U.S. Department of Agriculture, Hyattsville, Maryland, pp. 1–92.

Received for publication 2 September 1996.