

## **Gastric Intramural Hematoma and Hemoperitoneum in a Captive Northern Fur Seal**

Authors: Frasca, Salvatore, Van Kruiningen, Herbert J., Dunn, J. Lawrence, and St. Aubin, David J.

Source: Journal of Wildlife Diseases, 36(3) : 565-569

Published By: Wildlife Disease Association

URL: <https://doi.org/10.7589/0090-3558-36.3.565>

---

BioOne Complete (complete.BioOne.org) is a full-text database of 200 subscribed and open-access titles in the biological, ecological, and environmental sciences published by nonprofit societies, associations, museums, institutions, and presses.

Your use of this PDF, the BioOne Complete website, and all posted and associated content indicates your acceptance of BioOne's Terms of Use, available at [www.bioone.org/terms-of-use](http://www.bioone.org/terms-of-use).

Usage of BioOne Complete content is strictly limited to personal, educational, and non - commercial use. Commercial inquiries or rights and permissions requests should be directed to the individual publisher as copyright holder.

---

BioOne sees sustainable scholarly publishing as an inherently collaborative enterprise connecting authors, nonprofit publishers, academic institutions, research libraries, and research funders in the common goal of maximizing access to critical research.

## Gastric Intramural Hematoma and Hemoperitoneum in a Captive Northern Fur Seal

Salvatore Frasca, Jr.,<sup>1,3</sup> Herbert J. Van Kruiningen,<sup>1</sup> J. Lawrence Dunn,<sup>2</sup> and David J. St. Aubin<sup>2,1</sup> North-eastern Research Center for Wildlife Diseases, Department of Pathobiology, University of Connecticut, U-89, 61 North Eagleville Road, Storrs, Connecticut 06269-3089, USA; <sup>2</sup> Mystic Aquarium, 55 Coogan Boulevard, Mystic, Connecticut 06355-1997, USA; <sup>3</sup> Corresponding author (email: sfrasca@canr.uconn.edu).

**ABSTRACT:** A 16-yr-old adult male northern fur seal (*Callorhinus ursinus*) was found dead in its outdoor pool in November 1995. The animal was maintained at Mystic Aquarium (Mystic, Connecticut, USA) from March 1980 to November 1995. Gross necropsy findings included hemoperitoneum and locally extensive gastric intramural hemorrhage that involved the posterior fundic, antral, and pyloric regions and extended into the duodenum. The gastric mural thickening grossly resembled hemangioma, and the gastric serosa was ruptured at the site of maximal mural expansion. In histologic sections of the stomach, a cribriform network of fibrin, which encompassed numerous variably-sized aggregates of closely packed erythrocytes, markedly expanded the submucosa. No vascular endothelium was identified in serial histologic sections of the expanded gastric submucosa stained with hematoxylin and eosin or immunohistochemically with antibodies to vimentin and Factor VIII-related antigen, establishing an absence of hemangioma. Carstairs' and Weigert's histochemical stains confirmed that the framework expanding the submucosa was fibrin. Although the appearance of the gastric wall resembled hemangioma, a population of neoplastic endothelial cells was not identified within the submucosal expansion of hemorrhage and fibrin, and microscopic evidence was most consistent with the diagnosis of gastric intramural hematoma. This lesion is a rare pathologic event that has not been reported in marine mammals, but one that should be included in diagnostic considerations of hemoperitoneum and gastric mural expansion.

**Key words:** *Callorhinus ursinus*, case report, endothelium, gastric hematoma, hematoma, hemoperitoneum, immunohistochemistry, northern fur seal, stomach.

In this report we describe the gross pathology, histopathologic characteristics, and immunohistochemical and histochemical staining patterns of a gastric intramural hematoma with concomitant hemoperitoneum in an adult male northern fur seal (*Callorhinus ursinus*). Intramural

hematoma of the stomach is a rare condition that has been reported only in horses (Brown et al., 1981) and humans (Lloyd and Johnson, 1980; Melato et al., 1980; Molnar and Miko, 1982; Elliot and Bruce, 1987; Sheward et al., 1988; Geller and Gostout, 1998). The single case report of gastric intramural hematoma in a horse described an 80 cm diameter, smooth-surfaced, spherical mass arising from the greater curvature of the stomach with adhesions to the spleen and pancreas in a patient with colic (Brown et al., 1981). In humans, intramural or submucosal hematoma of the stomach is a well-recognized complication in patients with clotting disorders, especially hemophiliacs, and also can result from direct trauma during gastroscopy (Elliot and Bruce, 1987). Clinical features of spontaneous gastric hematoma in humans include upper abdominal discomfort, nausea, vomiting, and occasionally melena or severe epigastric pain (Elliot and Bruce, 1987). Spontaneous gastric intramural hematomas have occurred in the fundus, antrum, cardia, and larger portions of the stomach, such as the greater curvature, posterior wall and lesser curvature (Elliot and Bruce, 1987). Although the majority of cases have underlying coagulation defects, no direct cause for the formation of the hematoma was identified in approximately one-half of these cases; in the other half, the direct causes identified included gastric or duodenal ulceration, trauma, pancreatitis, and foreign body ingestion (Elliot and Bruce, 1987). Gastric intramural hematoma has been reported secondary to splenic rupture (Lloyd and Johnson, 1980) and has been associated

with hemoperitoneum (Lloyd and Johnson, 1980; Melato et al., 1980). When viewed radiographically and endoscopically, intramural gastric or esophagogastric hematoma can mimic neoplasia (Shepherd et al., 1988; Geller and Gostout, 1998).

The subject was a 16-yr-old 187 kg adult male that had been kept with conspecifics in an outdoor exhibit pool ( $2.8 \times 11.6 \times 6.7$  m) at Mystic Aquarium (Mystic, Connecticut, USA) from March 1980 to November 1995. The fur seal was kept in chlorinated freshwater, recirculated through high-rate sand filters. Its daily ration consisted of 14 kg of whole Atlantic herring (*Clupea harengus harengus*), capelin (*Mallotus villosus*), and squid (*Loligo pealei*) provided in two feedings, one mid-morning and one mid-afternoon. The animal had a long history of dental and gingival problems including gingivitis, gingival recession, gingival hyperplasia, dental abscesses and multiple extractions. Three days prior to its death, and one day after initiation of cephalosporin therapy, the animal was noted to have a small amount of blood present in its mouth. The prior history of dental problems suggested that the intermittent appetite and blood in the oral cavity stemmed from another dental problem. Injectable and oral cephalosporins were administered at this time to control the presumed oral infection. We initiated planning to remove the animal from the exhibit in order to conduct a full oral examination and blood sampling. The size and demeanor of the animal necessitated mechanical or chemical restraint in order to conduct blood sampling and an oral examination. Unfortunately the animal died before these plans could be realized.

Necropsy was performed at Mystic Aquarium. At postmortem examination, the abdominal cavity contained approximately 4 L of blood. Extending from the fundus through the antrum and pylorus along the lesser curvature, there was a well-demarcated zone, 23 cm long by 15 cm wide, over which the gastric wall was

markedly thickened, firm, and dark purple with hemorrhage. Intramural hemorrhage extended approximately 15 cm into the proximal duodenum. The gastric serosa was covered with blood and fibrin and was ruptured at the site of maximal mural expansion. There was locally extensive hemorrhage in the peripancreatic tissue at the head of the pancreas, in the duodenal loop. Multiple, 2 to 5 mm, linear or punctate, mucosal ulcers were located in the cardia and fundus. Feces in the colon were black.

Tissue samples of abdominal and thoracic viscera were fixed in 10% neutral buffered formalin, routinely processed for paraffin-embedding, sectioned at 4  $\mu$ m, and stained with hematoxylin and eosin (HE). Immunohistochemical stains with antibodies to vimentin and Factor VIII-related antigen were performed using a biotin-streptavidin immunoperoxidase technique (OmniTags<sup>®</sup> Plus<sup>™</sup>, Immunon<sup>™</sup>, Lipshaw, Inc., Pittsburgh, Pennsylvania, USA). Tissue sections of the stomach, as well as sections of canine and feline intestine, lymph node, tonsil, and salivary gland used as positive controls, were cut at 4  $\mu$ m, deparaffinized, treated with a solution of 1 part 30% hydrogen peroxide to 36 parts 70% methanol to quench the endogenous peroxidase activity of bloody specimens, and then sequentially incubated with primary antibody, followed by biotin-conjugated secondary antibody, and then streptavidin-horseradish peroxidase reagent. Signal development was achieved using amino-ethyl carbazole. Tissue sections stained with primary antibody to Factor VIII-related antigen received antigen retrieval pretreatment with 0.1% trypsin.

Microscopically, the fundic submucosa was markedly expanded two to three fold by hemorrhage and an extensive cribiform network of fibrin. Curvilinear bundles of fibrin intersected to create a honeycomb consisting of variably-sized, erythrocyte-filled spaces ranging in diameter from twenty to several hundred microns. No endothelium was identified along fibrin-lined

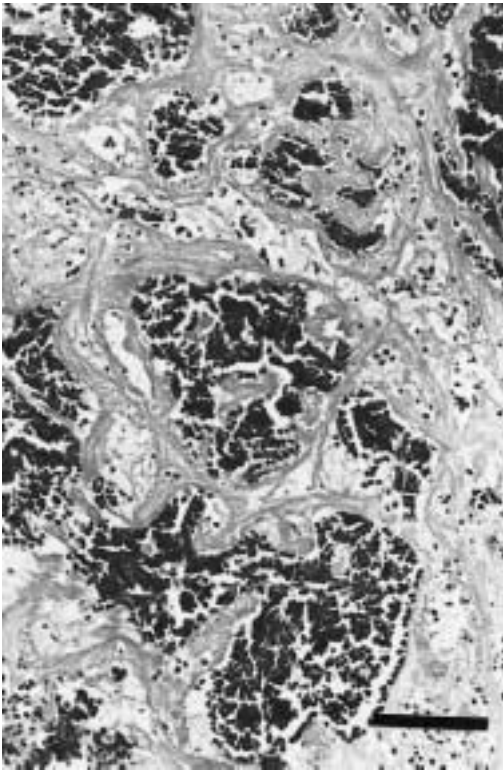


FIGURE 1. This photomicrograph is representative of the fundic submucosa from a northern fur seal with a gastric intramural hematoma. Intersecting curvilinear strands of fibrin form a honeycomb-like network consisting of variably-sized erythrocyte-filled spaces. H&E. Bar = 100  $\mu$ m.

spaces or in apposition to margined erythrocytes (Fig. 1). In tissue sections of the head of the pancreas, there was marked interlobular and intralobular septal hemorrhage, and there was hemorrhage in the peripancreatic mesentery.

Immunohistochemical stains using primary antibodies to vimentin and Factor VIII-related antigen (Immunon<sup>®</sup>, Lipshaw, Inc., Pittsburgh, Pennsylvania, USA) labeled endothelium of blood vessels in canine and feline positive control tissues, as well as endothelium of lamina propria or submucosal blood vessels of the fur seal stomach, i.e., internal positive controls. However, no such positive immunohistochemical labeling was evident along margins of erythrocyte-filled spaces or net-

works of fibrin in the expanded fundic submucosa, indicating that no endothelial cells could be demonstrated within the gastric intramural thickening. Histochemical staining using the Carstairs' and Weigert's staining methods (Sheehan and Hrapchak, 1980) demonstrated that the cribriform submucosal network was fibrin.

In this case, the gross and subgross appearances of the gastric mural thickening resembled hemangioma; however, microscopic examination at higher magnification, in concert with the results of immunohistochemical and histochemical stains, revealed that this gastric mural expansion was an intramural hematoma. Comparison to the condition in humans provides insight into predisposing and causative factors that also may play a role in the veterinary setting. Rupture of this gastric intramural hematoma would explain the hemoperitoneum observed at necropsy and would be consistent with reports of hemoperitoneum associated with gastric intramural hematoma in humans (Lloyd and Johnson, 1980; Melato et al., 1980). In humans, ruptures of caliber-persistent arteries in the gastric submucosa have resulted in gastric intramural hemorrhage, fatal rupture of the gastric wall, and hemoperitoneum (Molnar and Miko, 1982). Caliber-persistent arteries are muscular arteries with abnormally larger diameters than expected for their anatomic location; trauma to these vascular anomalies by internal or external forces can result in spontaneous hemorrhage (Molnar and Miko, 1982). However, serial tissue sections of the gastric wall in this case did not reveal the exact vascular location of the hemorrhage.

A direct cause of the gastric intramural hematoma was not ascertained from the necropsy results, histopathologic findings, or a review of the medical history of the animal, which included semi-annual hematologic and serum biochemical analyses. There was no evidence of a coagulation deficit, foreign body penetration, pancreatitis, gastroscopic trauma or splenic rup-

ture, nor was hemorrhage identified in any other location. Administration of some cephalosporins has been associated with a reduction in platelet aggregating ability, perhaps because cephalosporins and some other antibiotics coat the surfaces of platelets (Wilkins et al., 1995; Kariyazono et al., 1997). The role cephalosporin administration played in the development of hematoma and hemoperitoneum in this case cannot be determined. The animal had been administered a course of cephalosporins years earlier with no clinical signs of coagulation deficits, although no specific clotting time tests were conducted. Both prior to and after that cephalosporin administration, complete blood counts revealed normal hematologic values for the species and for this individual. A comparison of a complete blood count obtained within one month of death and those values obtained semi-annually for the 5 yr prior to death showed red blood cell parameters to be within reference ranges for this individual; platelet counts were adequate (i.e., 200,000 to 500,000/ $\mu$ l). Although multiple, 2 to 5 mm, linear or punctate gastric ulcers were found in the cardiac and fundic regions of the fur seal's stomach, none was seen in the fundic mucosa overlying the intramural hematoma. External trauma to the abdomen cannot be ruled-out as a cause, since fur seals routinely haul themselves out of the water and onto the concrete decks of the exhibit. In addition, this animal was housed with adult male conspecifics, and the potential for external trauma to the abdomen exists when conspecifics vie for preferred haul-out sites and during aggressive behaviors commonly displayed during the breeding season. In this case, no hemorrhage or edema was found in the muscle of the abdominal wall.

Gastric intramural hematoma in this case is similar to that of the horse (Brown et al., 1981) and human (Lloyd and Johnson, 1980; Melato et al., 1980; Molnar and Miko, 1982; Elliot and Bruce, 1987; Sheward et al., 1988; Geller and Gostout,

1998). This condition has gross and subgross appearances that mimic angiogenic neoplasia; however, a population of neoplastic endothelial cells was not identified in tissue sections of the stomach wall in this case. Documentation of gastric intramural hematoma in this northern fur seal serves to expand our knowledge of the range of species affected and provides reason for consideration of this lesion in the workup of gastric wall thickening and/or hemoperitoneum.

We acknowledge the staff of the Department of Husbandry of Mystic Aquarium for animal care and assistance with the necropsy. We are grateful to W. Ernst for her technical assistance with immunohistochemical staining and to I. Jackman and S. Gemme for tissue preparation. This manuscript is recorded as contribution #1860 by the Storrs Agricultural Experiment Station and as contribution #111 from the Sea Research Foundation.

#### LITERATURE CITED

- BROWN, C. M., M. A. COLLIER, AND K. A. JACOBSEN. 1981. Gastric hematoma in a horse. *Modern Veterinary Practice* 62: 617-618.
- ELLIOT, S., AND J. BRUCE. 1987. Submucosal gastric hematoma: A case report and review of the literature. *British Journal of Radiology* 60: 1132-1135.
- GELLER, A., AND C. J. GOSTOUT. 1998. Esophago-gastric hematoma mimicking a malignant neoplasm: Clinical manifestations, diagnosis, treatment. *Mayo Clinic Proceedings* 73: 342-345.
- KARIYAZONO, H., K. NAKAMURA, T. SHIKAWA, Y. MORIYAMA, H. TOYOHIRA, A. TAIRA, AND K. YAMADA. 1997. Inhibitory effects of antibiotics on platelet aggregation in vitro. *Human Experimental Toxicology* 16: 662-666.
- LLOYD, T. V., AND J. C. JOHNSON. 1980. Intramural gastric hematoma secondary to splenic rupture. *Southern Medical Journal* 73: 1675-1676.
- MELATO, M., G. FALCONIERI, R. MANCONI, AND S. BUCCONI. 1980. Intramural gastric hematoma and hemoperitoneum occurring in a patient affected by idiopathic myelofibrosis. *Human Pathology* 11: 301-302.
- MOLNAR, P., AND T. MIKO. 1982. Multiple arterial caliber persistence resulting in hematomas and fatal rupture of the gastric wall. *American Journal of Surgical Pathology* 6: 83-86.
- SHEEHAN, D. C., AND B. B. HRAPCHAK. 1980. Theory

- and Practice of Histotechnology, 2nd Edition. Battelle Press, Columbus, Ohio, 481 pp.
- SHEWARD, S. E., M. DAVIS, E. G. AMPARO, AND H. K. GOGEL. 1988. Intramural hemorrhage simulating gastric neoplasm. *Gastrointestinal Radiology* 13: 102-104.
- WILKINS, B., P. SULLIVAN, T. P. McDONALD, AND D. J. KRAHWINKEL. 1995. Effects of cephalothin, cefazolin, and cefmetazole on the hemostatic mechanism in normal dogs: Implications for the surgical patient. *Veterinary Surgery* 24: 25-31.

*Received for publication 13 May 1999.*