

Notoedric and Sarcoptic Mange in Free-ranging Lynx from Switzerland

Authors: Ryser-Degiorgis, Marie-Pierre, Ryser, Andreas, Bacciarini, Luca N., Angst, Christof, Gottstein, Bruno, et al.

Source: Journal of Wildlife Diseases, 38(1) : 228-232

Published By: Wildlife Disease Association

URL: <https://doi.org/10.7589/0090-3558-38.1.228>

BioOne Complete ([complete.BioOne.org](https://complete.bioone.org)) is a full-text database of 200 subscribed and open-access titles in the biological, ecological, and environmental sciences published by nonprofit societies, associations, museums, institutions, and presses.

Your use of this PDF, the BioOne Complete website, and all posted and associated content indicates your acceptance of BioOne's Terms of Use, available at www.bioone.org/terms-of-use.

Usage of BioOne Complete content is strictly limited to personal, educational, and non - commercial use. Commercial inquiries or rights and permissions requests should be directed to the individual publisher as copyright holder.

BioOne sees sustainable scholarly publishing as an inherently collaborative enterprise connecting authors, nonprofit publishers, academic institutions, research libraries, and research funders in the common goal of maximizing access to critical research.

Notoedric and Sarcoptic Mange in Free-ranging Lynx from Switzerland

Marie-Pierre Ryser-Degiorgis,^{1,4} Andreas Ryser,¹ Luca N. Bacciarini,² Christof Angst,¹ Bruno Gottstein,³ Martin Janovsky,² and Urs Breitenmoser^{1,1} KORA, Thunstrasse 31, 3074 Muri bei Bern, Switzerland; ² Centre for Fish- and Wildlife Health, Institute of Animal Pathology, University of Berne, Länggass-Strasse 122, 3012 Bern, Switzerland; ³ Institute of Parasitology, Länggass-Strasse 122, 3012 Bern, Switzerland; ⁴ Corresponding author (email: mpdegorgis@swissonline.ch).

ABSTRACT: Between March and December 1999, five free-ranging lynx (*Lynx lynx*) affected by mange were found dead or shot by game wardens in the Swiss Alps. In the first two cases, *Notoedres cati* was isolated from the skin; in the third and fourth case, *Sarcoptes scabiei* was the cause of the infection; and in the fifth case, a mixed infection was diagnosed. Red foxes (*Vulpes vulpes*) affected with sarcoptic mange and domestic cats infested with *N. cati* are likely to be the sources of infection. It seems improbable that mange will occur as an epidemic in lynx in Switzerland, but losses due to infections with *N. cati* and/or *S. scabiei* may have an impact on this small, geographically limited lynx population. This is the first report of notoedric mange in a free-ranging lynx and the first report of mange in lynx from Switzerland.

Key words: *Lynx lynx*, mange, mortality, parasites, *Notoedres cati*, *Sarcoptes scabiei*, Switzerland.

Mange is a highly contagious skin disease caused by mites (Muller et al., 1989). In lynx (*Lynx lynx*), mange caused by *Sarcoptes scabiei* has been reported in captivity in China (Jeu and Xiang, 1982), as well as in the wild in Norway and Sweden associated with an outbreak of sarcoptic mange in red fox (*Vulpes vulpes*; Holt and Berg, 1990; Mörner, 1992). Mange caused by *Notoedres cati* is rarely observed in lynx in zoos (Dobiàs, 1981) but to our knowledge, no case has been reported in free-ranging lynx.

In Switzerland, notoedric mange is a sporadic disease in domestic cats in the countryside but has not been reported in wildlife. In contrast, sarcoptic mange has been endemic in Swiss wildlife for at least 30 yr; infections with *S. scabiei* have been diagnosed in free-ranging red foxes and occasionally in stone martens (*Martes foina*, Wandeler, pers. comm.). In 1996–

98, an epidemic of sarcoptic mange was recorded in the northwestern Alps (Ochs et al., 1998) near the center of the lynx population (Fig. 1). This population of Eurasian lynx was reintroduced in the 1970s (Breitenmoser et al., 1998). Although locally high lynx abundance has been reported (Breitenmoser et al., 1999), the population as a whole is small, consisting of not more than 70 animals. Based on the Swedish and Norwegian experience, it was expected that lynx could be affected by sarcoptic mange. We report here the first cases of mange in the reintroduced lynx population of Switzerland.

Between March and December 1999, five free-ranging lynx with mange were found dead or shot by game wardens in the Swiss Alps (46°20' to 46°50' N, 7° to 7°50' E; Fig. 1). Animals were aged on the basis of body weight, date of death, and tooth wear (juvenile: <10 to 12-mo-old; adult >1-yr-old females and >2-yr-old males). Lynx 1, an adult male, was observed several times around farm houses during the day and it killed seven sheep within 20 days, including one inside a stable. The lynx was shaggy and had a short flight distance. It was shot on 8 April. Lynx 2 was a subadult male live-trapped on 3 March in the course of a population study and subsequently fitted with a radio collar. No sign of disease was observed at the time of capture. During 200 days of tracking, no evidence of illness was noticed. It was found dead on 21 September. Lynx 3, an adult female, killed a dog close to a farmhouse on 7 November. It showed little fear of humans and was shot the next day about 200 m from the dead dog. Lynx 4, a male kitten, was found frozen on 2 De-

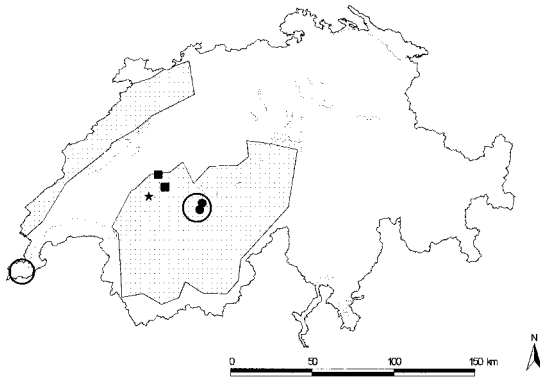


FIGURE 1. Map of Switzerland showing lakes and the location of cases of mange in free-ranging lynx: notoedric mange (●), sarcoptic mange (■), and mixed infection (★). Circles indicate the areas of the fox mange epidemics 1996–98 (Ochs et al., 1998), and shadowed areas show the distribution of the lynx population. Map source: Swiss Federal Office for Statistics.

cember on a forest road, about 250 m from the center of a small village and 5 km from the place where lynx 3 was shot almost a month earlier. It is likely that both belonged to the same family group. Lynx 5 was an adult male radio collared on 19 September. At that time, it appeared healthy. It was observed several times between 20 and 23 December, showing apathetic behaviour, sitting at the edge of the forest. It was inattentive and had a short flight distance when approached. Its fur was conspicuously disheveled and its face appeared swollen. It was found dead on 30 December at the edge of a forest.

All carcasses were immediately brought to the Centre for Fish and Wildlife Health (Berne, Switzerland) for complete standard necropsy. Mange mites were stimulated by light and increased temperature and migrated out of skin samples onto the lid of Petri dishes (Bornstein, 1995). The mites were examined by light microscopy and identified on the basis of typical morphologic characteristics (Neveu-Lemaire, 1938; Sloss and Kemp, 1978; Kettle, 1984). *Notoedres cati* was isolated from the skin of lynx 1 and 2 and *S. scabiei* was isolated from lynx 3 and 4. Both mite species were present on lynx 5. Representa-



FIGURE 2. Head of Eurasian lynx affected by mange. In this case, there was a mixed infection with *Notoedres cati* and *Sarcoptes scabiei*. Notice the thick crusts covering the pinnae and the face and mild alopecia.

tive specimens of the parasites were deposited in the Museum of Natural History (Berne, Switzerland, accession numbers AC-1 and AC-2).

At necropsy, all animals were cachectic. Macroscopically and histologically, there were only minor variations in the extent and severity of the skin lesions among the five animals. The lesions were most severe in the skin extending from the neck and pinnae to the head, face (Fig. 2), and the distal limbs. These lesions were characterized by thick gray scales, crusts, and excoriations with partial alopecia, marked lichenification and fissuring. Early lesions characterized by excoriation, hemorrhagic crusts, and partial patchy alopecia were present in other areas of the body. Microscopically, there was epidermal hyperplasia, mild spongiosis, compact hyperkeratosis, parakeratosis, crusting, and lympho-

cytic exocytosis. Superficial to deep perivascular, occasionally nodular, lymphohistiocytic infiltration with few eosinophils and varying number of mast cells was present in the dermis. Multifocal pigmentary incontinence was also present. In areas of excoriation, neutrophils and dermal scarring were evident. Abundant mites, mite eggs and feces were found in tunnels in the stratum corneum. In addition to the skin lesions, the lymph nodes of three animals were hyperplastic. Focal endogenous lipid pneumonia was found in two cases, and one lynx had moderate lymphohistiocytic interstitial pneumonia. Other lesions were mild diffuse lymphoplasmocytic enteritis (lynx 1), multiple gastric (lynx 5) or oral (lynx 2) ulcers, moderate to severe membranoproliferative glomerulonephritis (lynx 5), and, in lynx 5 a single histiocytic granuloma in the brainstem.

This is the first report of notoedric mange in free-ranging lynx and the first report of mange in lynx from Switzerland. Furthermore, to our knowledge this is the first report of a mixed infection with both *S. scabiei* and *N. cati* in any species. Based on lesions alone, it was not possible to determine the mite species causing the infections. Lesions were typical of chronic mange, except that alopecia was not as marked as reported in other species (Mörner, 1981; Pence et al., 1983, 1995; Schmitt et al., 1987). In addition, although Pence et al. (1995) stated that the lesions caused by *N. cati* in wild felids differed from those in domestic cats because they don't progress beyond the shoulders before the animals die, in the affected lynx the skin changes were distributed over the whole body. However, as reported by Pence et al. (1982, 1995) in bobcat (*Lynx rufus*) and ocelot (*Felis pardalis*), there were no signs of intense pruritus in lynx.

Until 1998, infectious diseases did not seem to be important in the reintroduced lynx population of Switzerland (Schmidt-Posthaus et al., 2002). In 1999, however, five cases of fatal mange were diagnosed. Cases of sarcoptic mange in lynx from the

area where red foxes had mange for the past 2 yr suggested that the lynx had contracted mange from red foxes. Sarcoptic mange is highly contagious and transmitted mainly by direct contact (Muller et al., 1989). In Switzerland, red foxes are occasional prey for lynx (Jobin, 1998), and it is likely that predation upon infected foxes is a way of disease transmission. The kitten could have been infected from the dam or through shared prey. Alternatively, if the kitten was orphaned, it may have tried to survive by hunting easy prey, such as diseased foxes.

Notoedric mange is a common disease of domestic cats (Guaguère, 1999), and lynx sometimes prey on them (Pulliainen et al., 1995; Jobin, 1998; Ryser, unpubl. data). Since notoedric mange has not been observed in free-ranging lynx in the past, it is likely that at least lynx 1 was exposed to *N. cati* through direct contact with an infected domestic cat. Lynx 2 could have been either infected by a domestic cat or by an infected lynx. Since lynx 1, 2, and 5 originated from the same area, it is possible that there was a link between these animals and/or the source of infection. Surprisingly, lynx 5 had a mixed infection with *S. scabiei*, although it was found in an area outside the region where foxes had been affected by mange. However, male lynx sometimes roam outside their home ranges (Haller and Breitenmoser, 1986), and we cannot exclude the possibility that lynx 5 visited the area of fox mange (Fig. 1) or the infected female lynx 3.

In experimental infections of red foxes, several months usually pass between appearance of the first signs of mange and death of the affected animal (Mörner and Christensson, 1984; Bornstein et al., 1995). In wild coyotes (*Canis latrans*) mange develops over several months (Pence et al., 1983). Although the lynx is a solitary species, mothers and kittens stay together for 10 mo, and males and females occasionally meet outside the mating season. Furthermore, during dispersion, subadult lynx may move over 100 km

(Schmidt, 1998; Zimmermann, 1998). Therefore, it is likely that intraspecific transmission can occur, which raises the question if mange can be a threat to the long-term survival of lynx in Switzerland. Mange is of concern for other endangered felid populations. Notoedric mange has been reported in cheetahs (*Acinonyx jubatus*, Young et al., 1972a) and leopards (*Panthera pardus*, Bailey, 1993) in South Africa, in free-ranging bobcats (Pence et al., 1982) and an ocelot (Pence et al., 1995) from southern Texas, and sarcoptic mange has been suspected to play a role in the decline of lynx in Sweden (Mörner, 1992). However, epidemics of sarcoptic mange have been reported only in social carnivores like red fox (Holt and Berg, 1990; Mörner, 1992), wolf (*Canis lupus*, Todd et al., 1981), coyote (Todd et al., 1981; Pence et al., 1983), or lion (*Panthera leo*, Young et al., 1972b), while there have been only few cases reported in solitary species like black bear (*Ursus americanus*, Schmitt et al., 1987), badger (*Meles meles*, Holt and Berg, 1990), and pine marten (Holt and Berg, 1990; Mörner, 1992). In conclusion, it is unlikely that mange will occur as an epidemic in lynx in Switzerland, but losses due to infections with *N. cati* and/or *S. scabiei* may have an immediate impact on this small, geographically limited population.

The authors acknowledge P. Olsson for his help in the field, H. Posthaus and P. Rehmann for their contribution to the postmortem examinations, and S. Bornstein for his support in mite identification.

LITERATURE CITED

- BAILEY, T. N. 1993. The African leopard: Ecology and behaviour of a solitary felid. Columbia University Press, New York, New York, 429 pp.
- BORNSTEIN, S. 1995. *Sarcoptes scabiei* infections of the domestic dog, red fox and pig: Clinical and serodiagnostic studies. Ph.D. Dissertation, Swedish University of Agricultural Sciences, and the National Veterinary Institute, Uppsala, Sweden, 127 pp.
- , G. ZAKRISSON, AND P. THEBO. 1995. Clinical picture and antibody response to experimental *Sarcoptes scabiei* var. *vulpes* infection in red foxes (*Vulpes vulpes*). Acta Veterinaria Scandinavica 36: 509–519.
- BREITENMOSER, U., C. BREITENMOSER-WÜRSTEN, AND S. CAPT. 1998. Re-introduction and present status of the lynx (*Lynx lynx*) in Switzerland. Hystrix 10: 17–30.
- , ———, ———, A. RYSER, F. ZIMMERMANN, C. ANGST, P. OLSSON, H.-J. BAUMGARTNER, A. SIEGENTHALER, P. MOLINARI, J. LAAS, A. BURRI, A. JOBIN, AND J.-M. WEBER. 1999. Lynx management problems in the Swiss Alps. Cat News 30: 16–18.
- DOBIAS, J. 1981. Erfolgreiche Behandlung einer Räudeerkrankung (*Notoedres cati*) bei Luchsen. Verhandlungsbericht des XXIII. Internationalen Symposiums über die Erkrankungen der Zootiere, Halle-Saale, Germany, pp. 253–255.
- GUAGUÈRE, E. 1999. Ectoparasitic skin diseases. In A practical guide to feline dermatology, E. Guaguère and P. Prélard (eds.). Merial, Paris, France, pp. 3.1–3.14.
- HALLER, H., AND U. BREITENMOSER. 1986. Zur Raumorganisation der in den Schweizer Alpen wiederangesiedelten Population des Luchses (*Lynx lynx*). Zeitschrift für Säugetierkunde 51: 289–311.
- HOLT, G., AND C. BERG. 1990. Sarcopteskab hos rodvov og andre villlevende rovdyr i Norge. Norsk Veterinaertidsskrift 102: 427–432.
- JEU, M., AND P. XIANG. 1982. Discovery of *Sarcoptes scabiei* infesting lynx in Chongqing, China. Zoological Research 3: 310.
- JOBIN, A. 1998. Predation patterns of Eurasian lynx in the Swiss Jura Mountains. Ph.D. Dissertation, University of Berne, Berne, Switzerland, 75 pp.
- KETTLE, S. S. 1984. Medical and veterinary entomology. Croom and Helm, London, UK, 351 pp.
- MÖRNER, T. 1981. The epizootic outbreak of sarcoptic mange in Swedish red foxes (*Vulpes vulpes*). Proceedings of the 4th international conference of the Wildlife Disease Association, Sydney, Australia, pp. 124–130.
- . 1992. Sarcoptic mange in Swedish wildlife. Revue Scientifique et Technique 11: 1,115–1,121.
- , AND D. CHRISTENSSON. 1984. Experimental infection of red foxes (*Vulpes vulpes*) with *Sarcoptes scabiei* var. *vulpes*. Veterinary Parasitology 15: 159–164.
- MULLER, G. H., R. W. KIRK, AND D. W. SCOTT. 1989. Small animal dermatology, 4th Edition. W.B. Saunders Company, Philadelphia, Pennsylvania, 1,007 pp.
- NEVEU-LEMAIRE, N. 1938. Traité d'entomologie médicale et vétérinaire. Vigot Frères, Paris, France, 200 pp.
- OCHS, H., U. MÜLLER, AND C. FISCHER. 1998. Fuchsräude kehrt in die Schweiz zurück. Jagd und Natur 11/98: 35–36.
- PENCE, D. B., F. D. MATTHEWS, AND L. A. WIND-

- BERG. 1982. Notoedric mange in the bobcat, *Felis rufus*, from southern Texas. *Journal of Wildlife Diseases* 18: 47–50.
- , L. A. WINDBERG, B. C. PENCE, AND R. SPROWLS. 1983. The epizootiology and pathology of sarcoptic mange in coyotes, *Canis latrans*, from southern Texas. *Journal of Parasitology* 69: 1,100–1,115.
- , M. E. TEWES, D. B. SHINDLE, AND D. M. DUNN. 1995. Notoedric mange in an ocelot (*Felis pardalis*) from Southern Texas. *Journal of Wildlife Diseases* 31: 558–561.
- PULLIAINEN, E., E. LINDGREN, AND P. S. TUNKKARI. 1995. Influence of food availability and reproductive status on the diet and body condition of the European lynx in Finland. *Acta Theriologica* 40: 181–196.
- SCHMIDT, K. 1998. Maternal behaviour and juvenile dispersal in the Eurasian lynx. *Acta Theriologica* 43: 391–408.
- SCHMIDT-POSTHAUS, H., C. BREITENMOSER-WÜRSTEN, H. POSTHAUS, L. BACCIARINI, AND U. BREITENMOSER. 2002. Pathological investigation of mortality in reintroduced Eurasian lynx (*Lynx lynx*) populations in Switzerland. *Journal of Wildlife Diseases* 38: 84–92.
- SCHMITT, S. M., T. M. COOLEY, AND P. D. FRIEDRICH. 1987. Clinical mange of the black bear (*Ursus americanus*) caused by *Sarcoptes scabiei* (Acarina, Sarcoptidae). *Journal of Wildlife Diseases* 23: 162–165.
- SLOSS, M. W., AND R. L. KEMP. 1978. *Veterinary clinical parasitology*. 5th Edition. Iowa State University Press, Ames, Iowa, 274 pp.
- TODD, A. W., J. R. GUNSON, AND W. M. SAMUEL. 1981. Sarcoptic mange: An important disease in coyotes and wolves of Alberta, Canada. *Worldwide Furbearer Conference Proceedings*, Frostburg, Maryland, pp. 706–729.
- YOUNG, E., F. ZUMPT, AND I. J. WHYTE. 1972a. *Notoedres cati* (Hering, 1838) infestation of the cheetah: Preliminary report. *Journal of the South African Veterinary Association* 43: 205.
- , ——— AND ———. 1972b. Sarcoptic mange in free-living lions. *Journal of the South African Veterinary Association* 43: 226.
- ZIMMERMANN, F. 1998. Dispersion et survie des lynx (*Lynx lynx*) subadultes d'une population réintroduite dans la chaîne du Jura. KORA Bericht Nr. 4, 50 pp.

Received for publication 25 January 2001.