

## **Disease Survey of Free-ranging Grey Brocket Deer (*Mazama gouazoubira*) in the Gran Chaco, Bolivia**

Authors: Deem, Sharon L., Noss, Andrew J., Villarroel, Richard, Uhart, Marcela M., and Karesh, William B.

Source: Journal of Wildlife Diseases, 40(1) : 92-98

Published By: Wildlife Disease Association

URL: <https://doi.org/10.7589/0090-3558-40.1.92>

---

BioOne Complete ([complete.BioOne.org](https://complete.BioOne.org)) is a full-text database of 200 subscribed and open-access titles in the biological, ecological, and environmental sciences published by nonprofit societies, associations, museums, institutions, and presses.

Your use of this PDF, the BioOne Complete website, and all posted and associated content indicates your acceptance of BioOne's Terms of Use, available at [www.bioone.org/terms-of-use](https://www.bioone.org/terms-of-use).

Usage of BioOne Complete content is strictly limited to personal, educational, and non - commercial use. Commercial inquiries or rights and permissions requests should be directed to the individual publisher as copyright holder.

---

BioOne sees sustainable scholarly publishing as an inherently collaborative enterprise connecting authors, nonprofit publishers, academic institutions, research libraries, and research funders in the common goal of maximizing access to critical research.

## Disease Survey of Free-ranging Grey Brocket Deer (*Mazama gouazoubira*) in the Gran Chaco, Bolivia

Sharon L. Deem,<sup>1,4,5</sup> Andrew J. Noss,<sup>2</sup> Richard Villarroel,<sup>2</sup> Marcela M. Uhart,<sup>3</sup> and William B. Karesh<sup>1</sup> <sup>1</sup>Field Veterinary Program, Wildlife Conservation Society, 2300 Southern Boulevard, Bronx, New York 10460, USA; <sup>2</sup>Proyecto Kaa-Iya, CABI-WCS Bolivia, Casilla 6272, Santa Cruz, Bolivia; <sup>3</sup>Field Veterinary Program, Wildlife Conservation Society, 14 de julio 430, (7000) Tandil, Buenos Aires, Argentina; <sup>4</sup>Current address: Department of Animal Health, Smithsonian's National Zoological Park, 3001 Connecticut Avenue NW, Washington, DC 20008, USA; <sup>5</sup>Corresponding author (email: deems@nzp.si.edu)

**ABSTRACT:** Samples from 17 free-ranging hunter-killed grey brocket deer (*Mazama gouazoubira*) in the Gran Chaco, Bolivia, were collected during June–August 1999. All 17 deer appeared to be in good condition at the time of death. Gross necropsies were performed, serum was collected for serologic evaluation of selected infectious disease agents, and feces and ectoparasites were collected for evaluation of internal and external parasites. Serologic tests were positive for antibodies against bovine respiratory syncytial virus and four *Leptospira interrogans* serovars, with questionable results for epizootic hemorrhagic disease virus serotypes 1 and 2. No antibodies were detected to *Anaplasma marginale*, *Babesia bigemina*, *Babesia bovis*, *Babesia odocoilei*, bluetongue virus (serotypes 2, 10, 11, 13, and 17), bovine viral diarrhea virus, *Brucella abortus*, foot-and-mouth disease virus, infectious bovine rhinotracheitis virus, *Mycobacterium avium* subsp. *paratuberculosis*, and parainfluenza-3 virus. Sixty-four percent (7/11) of the deer had endoparasites. *Amblyomma* spp. ticks were found on seven deer, flies of the family Hippoboscidae on six deer, and lice on six deer.

**Key words:** Bolivia, Gran Chaco, grey brocket deer, *Mazama gouazoubira*, parasites, serology.

Information on the health of captive and free-ranging brocket deer (*Mazama* spp.) is limited (Duarte et al., 2001). The majority of this literature is on ecto- and endoparasites of *Mazama* spp. To the authors' knowledge, no comprehensive disease survey of free-ranging grey brocket deer (*Mazama gouazoubira*) has been published.

The six species of *Mazama*, found primarily in woodland and forest, are distributed throughout Central and South America and are an important food source for jaguar (*Panthera onca*), puma (*Felis concolor*), and humans (Eisenberg and Red-

ford, 1999). In the Gran Chaco, Bolivia, grey brocket deer are common, and the conservation status of this species is considered to be "low risk" (Rumiz, 2002).

The objective of this study was to evaluate serologic evidence of infectious disease exposure in grey brocket deer. Ancillary health-related findings of grey brocket deer also were documented.

The Chaco ecosystem is a generally short (3–5 m canopy with emergents 8–15 m tall), dense, and thorny forest (Taber et al., 1997). Hunting is illegal in the Kaa-Iya National Park, but is extensive in the neighboring indigenous territory of the Izozog, with grey brocket deer being the principal prey species for subsistence hunters (Cuéllar, 2000). Large-scale commercial cattle ranching is present in the region, as is the presence of small herds of cattle. The study area includes all the 24 Izocéño communities in the Bolivian Chaco, together with their irrigated fields and domestic animals (goats, cattle, chickens, dogs, cats, and pigs). In addition to the presence of domestic species in the Chaco, there is a high level of species diversity, including at least 10 endemic mammal species and three deer species, including grey brocket deer, red brocket deer (*Mazama americana*), and pampas deer (*Ozotoceros bezoarticus*) (Taber et al., 1997). *Mazama americana* and *O. bezoarticus* are not known to occur in our study area.

All brocket deer were sampled from June to August 1999 in the Gran Chaco, Bolivia (19°S–19°40'S, 62°20'W–63°W). The 17 free-ranging deer were hunted within the Izozog indigenous territory adjacent to the Kaa-Iya National Park (Fig.

1). Brocket deer were approached on foot and shot by an Izoceño-Guaraní hunter with a 16-gauge shotgun or a .22 caliber rifle. Blood samples were collected within minutes of death by cardiac centesis. Body weight was taken with either a 12- or 50-kg spring scale, and age was determined by body size and molar wear (Maffei and Beccera, 2000). Gross necropsy was performed in the field within 2 hr of death. Fecal samples ( $n=11$ ) were collected manually from the colon or rectum and preserved in 10% formalin. Ectoparasites ( $n=11$ ) were collected and stored in 70% isopropyl alcohol. Representative tissue samples were collected for histologic evaluation and preserved in 10% buffered formalin.

Immediately following cardiac centesis, blood was placed in serum separator tubes (Corvac, Sherwood Medical, St. Louis, Missouri, USA). The sample tubes were placed in the shade until clot formation, and sera were separated by centrifugation in a portable 12-V centrifuge (Mobilespin, Vulcan Technologies, Gransview, Missouri) at  $3,000\times G$  for 15 min and stored in liquid nitrogen. Serum samples were exposed to 30  $\mu$ Gy of gamma irradiation during importation to the United States. Small aliquots of serum were removed prior to irradiation for foot-and-mouth disease (FMD) virus antibody testing.

Serologic testing for FMD was conducted at the US Foreign Animal Disease Diagnostic Laboratory (USDA, APHIS-Saddle Lab, New York, New York, USA) by the virus infection-associated antigen test (VIAA; McVicar and Suttmoller, 1970). *Leptospira interrogans* (18 serovars) antibody testing was conducted at the New York State Veterinary Diagnostic Laboratory (Cornell University, Ithaca, New York) by the microagglutination test (Cole et al., 1973). Indirect immunofluorescence assays (IFAT) for detecting antibodies to *Anaplasma marginale* (Tibbitts et al., 1992), *Babesia bigemina*, *Babesia bovis*, and *Babesia odocoilei* (Goff et al., 1993) were performed at Animal Disease Research

Unit (USDA Animal Disease Biotechnology Facility, Washington State University, Pullman, Washington, USA). Serum neutralization (SN) tests for detecting antibodies to bovine respiratory syncytial virus (BRSV; Gillette, 1983), bovine viral diarrhoea (BVD) virus (Edwards, 1990), infectious bovine rhinotracheitis (IBR) virus (Assaf et al., 1975), and parainfluenza-3 (PI-3) virus (Kadoi et al., 1998) were conducted at the Diagnostic Laboratory, Oklahoma State University (Stillwater, Oklahoma, USA). Competitive enzyme-linked immunodiffusion assay (cELISA; Bluetongue virus antibody test kit, c-ELISA, VMRD, Inc., Pullman, Washington, USA), card test (Brucellosis card test, Dickinson Microbiological Systems, Cockeysville, Maryland, USA), and agar gel immunodiffusion assay (AGID; Stallknecht et al., 1995), used to detect antibodies to bluetongue (BT) virus, *Brucella abortus*, and epizootic hemorrhagic disease (EHD) virus, respectively, were also conducted at the Diagnostic Laboratory, Oklahoma State University. *Mycobacterium avium* subsp. *paratuberculosis* antibody testing by AGID (ImmunCell® Corp., Portland, Maine, USA) was performed at the Texas Veterinary Medicine Diagnostic Laboratory (College Station, Texas, USA). Bluetongue virus serotypes 2, 10, 11, 13, and 17 and EHD virus serotypes 1 and 2 antibody testing conducted using AGID (Veterinary Diagnostic Technology, Inc., Wheat Ridge, Colorado, USA) and SN (Stallknecht et al., 1995) was performed at the Southeastern Cooperation for Wildlife Disease Studies (College of Veterinary Medicine, Athens, Georgia, USA).

Fecal samples were examined by direct microscopic examination, sodium nitrate flotation, and sedimentation methods at the New York State Veterinary Diagnostic Laboratory. Adult ticks were identified on the basis of external morphology with the keys of Jones et al. (1972). Hippoboscidae flies were identified on the basis of external morphology with the key of Maa (1969). Voucher specimens are deposited

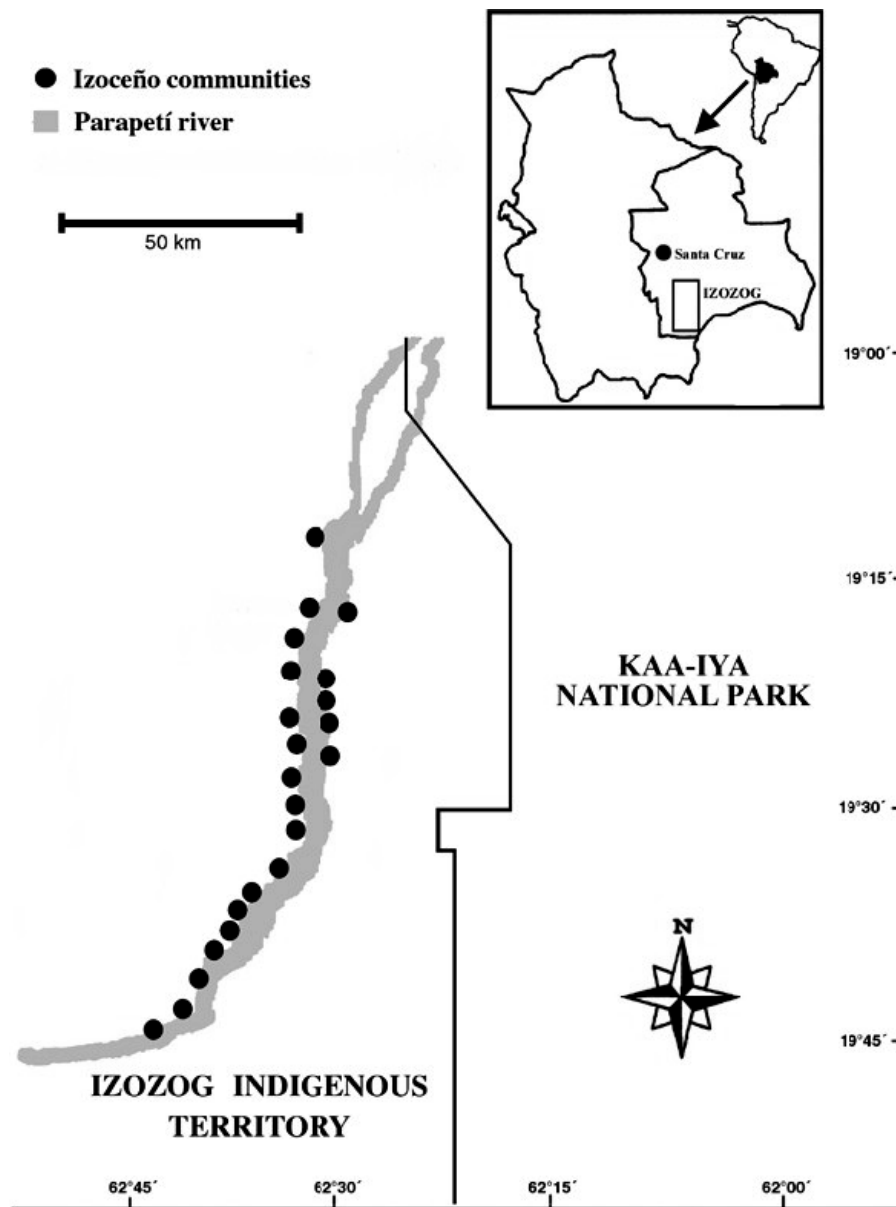


FIGURE 1. Map of the Izoceño study area within the Gran Chaco, Bolivia.

in Zoologisches Forschungsinstitut und Museum Alexander Koenig (13/2003).

All 17 deer (nine males, eight females) were judged to be in good body condition at the time of collection. Three of seven adult females were pregnant. All fetuses were in good condition. One male had a fibropapilloma on its chin.

Prevalence of cysticerciasis was high.

Forty-seven percent of the deer had cysts, 12% in lung, 18% in liver, and the remaining cysts in omentum and mesentery.

Seven of 11 deer had endoparasites based on fecal examination. Four deer had *Moniezia* sp.; one had *Eimeria* sp.; one had *Eimeria* sp. and strongyles; and one had *Moniezia* sp., strongyles, and *Trichuris ovis*. Ectoparasites were present on 50%

TABLE 1. Pathogen, serologic tests performed, antibody titer considered positive, and number of animals antibody-positive in the evaluation of infectious agent exposure in free-ranging grey brocket deer (*Mazama gouazoubira*) in the Gran Chaco, Bolivia.

| Pathogen  | Test method <sup>a</sup><br>(positive titer) | Number positive/<br>number tested |
|---|--|-----------------------------------|
| <i>Anaplasma marginale</i>                                | IFAT   | 0/15                              |
| <i>Babesia bigemina</i>                                   | IFAT   | 0/15                              |
| <i>Babesia bovis</i>                                      | IFAT   | 0/15                              |
| <i>Babesia odocoilei</i>                                  | IFAT   | 0/15                              |
| Bluetongue virus  | cELISA                                       | 0/15                              |
| Bluetongue virus (serotypes 2, 10, 11, 13, and 17)        | AGID (1:4)                                   | 0/15                              |
| Bovine respiratory syncytial virus                        | SN (1:4)                                     | 2/15                              |
| Bovine viral diarrhea virus                               | SN (1:4)                                     | 0/15                              |
| <i>Brucella abortus</i>                                   | Card test                                    | 0/15                              |
| Epizootic hemorrhagic disease virus (serotypes 1 and 2)   | AGID (1:4)                                   | 1/15                              |
| Epizootic hemorrhagic disease virus (serotypes 1 and 2)   | SN (1:4)                                     | 0/2                               |
| Foot-and-mouth disease virus                              | VIAA   | 0/14                              |
| Infectious bovine rhinotracheitis virus                   | SN (1:4)                                     | 0/15                              |
| <i>Mycobacterium avium</i> subsp. <i>paratuberculosis</i> | AGID   | 0/15                              |
| <i>Leptospira interrogans</i> (18 serovars) <sup>b</sup>  | Microagglutination (1:100)                   | 5/11                              |
| Parainfluenza-3 virus                                     | SN (1:4)                                     | 0/15                              |

<sup>a</sup> cELISA = competitive enzyme-linked immunodiffusion assay; IFAT = indirect fluorescent antibody test; SN = serum neutralization; AGID = agar gel immunodiffusion; VIAA = virus infection-associated antigen.

<sup>b</sup> *Leptospira interrogans* serovars tested included autumnalis, australis, ballum, bataviae, bratislava, canicola, grippityphosa, hardjo, icterohaemorrhagiae/COP, icterohaemorrhagiae, javanica, pomona, pyrogenes, saxkoebing, sejroe, szwajizak, tarassovi, and wolffi.

of the deer. *Amblyomma* spp. ticks were found on seven deer, *Lipoptena mazamae* flies of the family Hippoboscidae on six deer, and unidentified lice on six deer. Adult ticks were determined to be *Amblyomma parvum* and *Amblyomma pseudocolor*. However, a number of deer had *Amblyomma* spp. nymphs and larvae that could not be identified to species.

Serologic evidence of exposure to potential pathogens is summarized in Table 1.

The general body conditions of all the deer were judged to be good. Forty-two percent of the adult females were pregnant, which is lower than the 83% reported in a study conducted in the Paraguayan Chaco (Stallings, 1986). Differences between these two studies might be related to season, although brocket deer are believed to breed year-round throughout their range (Stallings, 1986). A single animal had a cutaneous fibroma, which is a common neoplastic condition of white-tailed deer (*Odocoileus virginianus*) and other cervids and is of viral origin (David-

son and Nettles, 1997). To the authors' knowledge, this is the first time a fibropapilloma has been reported in a brocket deer.

On the basis of gross findings, the most likely cause of the cysticerciasis is *Taenia hydatigena*. Adults of *T. hydatigena* are found in the intestines of canids and other carnivores, whereas the larval stage is found most commonly attached to the mesentery, omentum, and serosal surface of abdominal organs of ruminants (Smith and Sherman, 1994). Although *Taenia* spp. are not of public health concern, the adult stage of the closely related *Echinococcus* spp. tapeworms have zoonotic potential and can cause serious disease in humans (Hildreth et al., 1991). *Echinococcus* spp. is another possible cause of the cystic lesions present in the brocket deer in this study. Therefore, it would be beneficial to conduct further studies to determine the species of tapeworm in carnivores and the brocket deer.

Endoparasites we detected in feces of



the brocket deer are not known to be pathogenic for adult domestic small ruminants at the levels present in these deer (Smith and Sherman, 1994). Additionally, all these parasites have been reported in white-tailed deer (Prestwood and Pursglove, 1981). Presence of ticks, lice, and flies is common at low levels in many free-ranging ungulate populations, and at the levels we detected, they are most likely not significant. *Amblyomma* spp. ticks have been reported on *Mazama* spp. in other regions (reviewed in Duarte et al., 2001).

Deer had evidence of exposure to three of 14 infectious agents for which they were tested. Two brocket deer had antibodies to BRSV. We do not know the implication of this finding; respiratory syncytial virus infections of nondomestic ruminants might be subclinical or result in pneumonia (Van Campen and Early, 2001).

Evidence of exposure to *L. interrogans* was found in deer sampled in this study. Five of 11 deer had antibodies to four serovars: autumnalis, ballum, icterohaemorrhagiae, and sejroe. Although studies have found some *L. interrogans* serovars to be pathogenic to deer (Tainer et al., 1961; Abdulla et al., 1962), we do not know whether the serovars we detected cause illness in brocket deer.

We did not find clear evidence of EHD virus exposure in this survey. There are reports of exposure to EHD virus in brocket deer in Latin America (Arita, 1996; Pandolfi et al., 1998). Further studies to determine exposure of deer to this agent in the Gran Chaco is warranted because EHD virus is a significant cause of morbidity and mortality of some deer populations (Nettles and Stallknecht, 1992).

Negative antibody results for *A. marginale*, *B. bigemina*, *B. bovis*, *B. odocoilei*, BT virus, BVD virus, *B. abortus*, FMD virus, IBR virus, *M. avium* subsp. *paratuberculosis*, and PI-3 virus cannot be interpreted as a lack of exposure in this population to these pathogens because of our small sample size. Additionally, diagnostic tests we employed have not been standardized for

use in brocket deer, so the sensitivity and specificity of these tests in this species are unknown. It is possible that these diseases are highly virulent in brocket deer (e.g., FMD); thus, infected animals die prior to mounting an immune response and would not be present in the population at the time of sampling.

This limited study provides the most comprehensive disease survey of free-ranging grey brocket deer to date. The grey brocket deer is widespread in South America, and the findings of this study do not necessarily reflect the health status of other populations. More work needs to be done to understand the health status of this species because of its importance as a prey item for jaguar and puma and as a protein source for various human populations. Studies must be conducted with much larger sample sizes.

We gratefully acknowledge V. Greco, K. C. Kahler, and L. J. Starr for help with sample processing and travel logistics; R. G. Robbins, V. Smith, B. J. Sinclair, W. L. Goff, J. Gaydos, and M. J. Linn for laboratory diagnostic support; and the biologists and parabiologists that helped with sample collection. We also thank the communities of the Izozog for their participation and support. This publication was made possible by the financial support of the US Agency for International Development (USAID, Cooperative Agreement 511-A-00-01-00005). The opinions expressed are those of the authors and do not necessarily represent the criteria of USAID.

#### LITERATURE CITED

- ABDULLA, P. K., L. KARSTAD, AND N. A. FISH. 1962. Cultural and serological evidence of leptospirosis in deer in Ontario. *Canadian Veterinary Journal* 3: 71-78.
- ARITA, G. M. M. 1996. Bluetongue: Diagnostic in LARA/campinas. In *Anais Congresso panamericano de Ciencias Veterinárias*, Campo Grande, p. 15.
- ASSAF, R., G. MARSOLAIS, P. MAROIS, AND P. PAYMENT. 1975. Correlation between the serum neutralization test and the indirect immunofluorescent test for the detection of specific antibodies.

- ies to infectious bovine rhinotracheitis virus. Canadian Journal of Comparative Medicine 39: 224–226.
- COLE, J. R., C. R. SULZER, AND A. R. PURSELL. 1973. Improved microtechnique for the leptospiral microscopic agglutination test. Applied Microbiology 25: 976–980.
- CUÉLLAR, R. L. 2000. Uso de los animales silvestres por pobladores Izocéños. In Manejo de fauna silvestre en Amazonía y Latinoamérica, E. Cabrera, C. Mercolli, and R. Resquín (eds.). CITES Paraguay, Fundación Moises Bertoni, University of Florida, Gainesville, Florida, pp. 471–484.
- DAVIDSON, W. R., AND V. F. NETTLES. 1997. Cutaneous fibroma. In Field manual of wildlife diseases in the southeastern United States, 2nd Edition, Southeastern Cooperative Wildlife Disease Study, Athens, Georgia, pp. 34–35.
- DUARTE, J. M. B., M. L. MERINO, S. GONZALEZ, A. L. V. NUNES, J. M. GARCIA, M. P. J. SZOBÓ, J. R. PONDOLFI, I. G. ARANTES, A. A. DO NASCIMENTO, R. Z. MACHADO, J. P. ARAUGO, JR., J. L. CATAO-DIAS, K. WERTHER, J. E. GARCIA, R. J. S. GIRO, AND E. R. MATUSHIMA. 2001. Order Artiodactyla, family Cervidae (deer). In Biology, medicine, and surgery of South American wild animals, M. E. Fowler and Z. S. Cubas (eds.). Iowa State University Press, Ames, Iowa, pp. 402–422.
- EDWARDS, S. 1990. The diagnosis of bovine virus diarrhea-mucosal disease in cattle. Revue Scientifique et Technique 9: 115–130.
- EISENBERG, J. F., AND K. H. REDFORD. 1999. Mammals of the Neotropics, the central Neotropics, Vol. 3. Ecuador, Peru, Bolivia, Brazil. University of Chicago Press, Chicago, Illinois, 609 pp.
- GILLETTE, K. G. 1983. Enzyme-linked immunosorbent assay for serum antibody to bovine respiratory syncytial virus: Comparison with complement-fixation and neutralization tests. American Journal of Veterinary Research 44: 2251–2255.
- GOFF, W. L., D. A. JESSUP, K. A. WALDRUP, J. W. THOMFORD, P. A. CONRAD, W. M. BOYCE, J. R. GORHAM, AND G. G. WAGNER. 1993. The isolation and partial characterization of a *Babesia* sp. from desert bighorn sheep (*Ovis canadensis nelsoni*). Journal of Eukaryotic Microbiology 40: 237–243.
- HILDRETH, M. B., M. D. JOHNSON, AND K. R. KAZACOS. 1991. *Echinococcus multilocularis*: A zoonosis of increasing concern in the United States. Compendium on Continuing Education for the Practicing Veterinarian 13: 727–740.
- JONES, E. K., C. M. CLIFFORD, J. E. KEIRANS, AND G. M. KOHLS. 1972. The ticks of Venezuela (Acarina: Ixodoidea) with a key to the species of *Amblyomma* in the Western Hemisphere. Brigham Young University Science Bulletin, Biological Series 17: 1–40.
- KADOI, K., N. WATANABE, T. SASAGAWA, AND M. KOSASA. 1998. Antibody response of cattle experimentally inoculated with parainfluenza type-3 live vaccine in a post-tracheal position. New Microbiologist 21: 249–254.
- MAA, T. C. 1969. Further notes on Lipoteninae Diptera Hippoboscidae. Pacific Insects Monograph 20: 205–236.
- MAFFEI, L., AND M. N. BECERRA. 2000. Técnica básica para determinar la edad en ungulados silvestres en base al análisis de dientes. Ecología en Bolivia 34: 39–44.
- MCVICAR, J. W., AND P. SUTMOLLER. 1970. Foot-and-mouth disease: The agar gel diffusion precipitin test for antibody to virus-infection-associated (VIA) antigen as a tool for epizootiologic surveys. American Journal of Epidemiology 92: 273–278.
- NETTLES, V. F., AND D. E. STALLKNECHT. 1992. History and progress in the study of hemorrhagic disease of deer. Transactions of the North American Wildlife and Natural Resources Conference 57: 499–516.
- PANDOLFI, J. R. C., M. L. F. TAMANINI, J. P. ARÚJO, J. M. B. DUARTE, J. ANDERSON, J. THEVASSAGAYAM, A. A. PINTO, AND H. J. MONTASSIER. 1998. Presença da infecção pelos vírus da língua azul e da doença hemorrágica epizootica dos cervídeos em uma população de vida livre de cerrado-pantanal (*Blastocerus dichotomus*). Virus Reviews and Research Supplement 3, p. 55.
- PRESTWOOD, A. K., AND S. R. PURSGLOVE, JR. 1981. Gastrointestinal nematodes. In Disease and parasites of white-tailed deer, W. R. Davidson, F. A. Hayes, V. F. Nettles and F. E. Kellogg (eds.). Southeastern Cooperative Wildlife Disease Study, University of Georgia, Athens, Georgia, pp. 318–350.
- RUMIZ, D. I. 2002. An update of studies on deer distribution, ecology and conservation in Bolivia. Deer Specialist Group News 17: 6–10.
- SMITH, M. C., AND D. M. SHERMAN. 1994. Goat medicine. Lea and Febiger, Philadelphia, Pennsylvania, 620 pp.
- STALLINGS, J. R. 1986. Notes on the reproductive biology of the grey brocket deer (*Mazama gouazoubira*) in Paraguay. Journal of Mammalogy 67: 172–175.
- STALLKNECHT, D. E., V. F. NETTLES, E. A. ROLLOR, AND E. W. HOWERTH. 1995. Epizootic hemorrhagic disease virus and bluetongue virus serotype distribution in white-tailed deer in Georgia. Journal of Wildlife Diseases 31: 331–338.
- TABER, A. B., G. NAVARRO, AND M. A. ARRIBAS. 1997. A new park in the Bolivian Gran Chaco—An advance in tropical dry forest conservation and community-based management. Oryx 31: 189–198.
- TIBBITTS, T., W. GOFF, W. FOREYT, AND D. STILLER. 1992. Susceptibility of two Rocky Mountain bighorn sheep to experimental infection with *An-*

- aplasma ovis*. *Journal of Wildlife Diseases* 28: 125–129.
- TRAINER, D. L., L. KARSTAD, AND R. P. HANSON. 1961. Experimental leptospirosis in white-tailed deer. *The Journal of Infectious Diseases* 108: 278–286.
- VAN CAMPEN, H., AND G. EARLY. 2001. Orthomyxovirus and paramyxovirus infections. *In Infectious diseases of wildlife mammals*, 3rd Edition, E. S. Williams and I. K. Baker (eds.). Iowa State University Press, Ames, Iowa, pp. 271–279.
- Received for publication 25 January 2002.