

Cardiac Rhabdomyoma in a Juvenile Fallow Deer (*Dama dama*)

Authors: Kolly, Carine, Bidaut, Alexandre, and Robert, Nadia

Source: Journal of Wildlife Diseases, 40(3) : 603-606

Published By: Wildlife Disease Association

URL: <https://doi.org/10.7589/0090-3558-40.3.603>

BioOne Complete (complete.BioOne.org) is a full-text database of 200 subscribed and open-access titles in the biological, ecological, and environmental sciences published by nonprofit societies, associations, museums, institutions, and presses.

Your use of this PDF, the BioOne Complete website, and all posted and associated content indicates your acceptance of BioOne's Terms of Use, available at www.bioone.org/terms-of-use.

Usage of BioOne Complete content is strictly limited to personal, educational, and non - commercial use. Commercial inquiries or rights and permissions requests should be directed to the individual publisher as copyright holder.

BioOne sees sustainable scholarly publishing as an inherently collaborative enterprise connecting authors, nonprofit publishers, academic institutions, research libraries, and research funders in the common goal of maximizing access to critical research.

Cardiac Rhabdomyoma in a Juvenile Fallow Deer (*Dama dama*)

Carine Kolly,¹ Alexandre Bidaut,¹ and Nadia Robert^{1,2} ¹ Centre for Fish and Wildlife Health, Institute of Animal Pathology, Vetsuisse Faculty of the University of Berne, Länggassstrasse 122, Postfach, 3001 Berne, Switzerland; ² Corresponding author (email: nadia.robert@itpa.unibe.ch)

ABSTRACT: A cardiac rhabdomyoma is described in a 6-wk-old captive fallow deer (*Dama dama*) that died suddenly without previous clinical signs. The tumor was characterized by multiple nodules composed of large atypical vacuolated myoblastic cells. As previously reported in humans and other animal species, there is compelling evidence that the cardiac rhabdomyoma is a congenital developmental anomaly rather than a true neoplasm. To our knowledge, this is the first report of a cardiac tumor and a rhabdomyoma in a cervid species.

Key words: Cardiac rhabdomyoma, case report, congenital, *Dama dama*, fallow deer, juvenile.

Rhabdomyomas are rare benign multiple or solitary neoplasms originating from striated muscles. They are reported to occur in the myocardium and, less frequently, in skeletal muscles of the larynx and head region in humans and animals (Meuten, 2002). In humans, the cardiac form is congenital and mostly reported in children. Rhabdomyomas represent up to 80% of infantile cardiac tumors (Beghetti et al., 1997; Sallee et al., 1999). Other locations are mostly reported in adult patients (McGregor et al., 2003). In veterinary literature, cardiac rhabdomyomas have been reported in several domestic species, most frequently in swine (Omar, 1969; Tanimoto and Ohtsuki, 1995; Misdorp, 2003). It is typically diagnosed in young animals or as an incidental finding at slaughter. Rare cases have also been described in guinea pigs (Cintorino and Luzi, 1971; Hoch-Ligeti et al., 1986), dogs (Ware and Hopper, 1999; Mansfield et al., 2000), cattle, and sheep (Meuten, 2002). Numerous tumors have been reported in cervids, the most common being cutaneous fibromas and fibropapillomas associated with deer papillomavirus C infection (Sundberg and Nielsen, 1981; O'Banion

and Sundberg, 1987; Lowy and Howley, 2001). However, tumors of the musculature have rarely been described; one subcutaneous malignant rhabdomyosarcoma on the neck (Kidd and Reuter, 1989) and one cerebral mixed glioma and rhabdomyosarcoma were reported in a fallow deer (*Dama dama*) and a wild deer (*Odocoileus virginianus*), respectively (Holscher et al., 1977). We describe here a case of multiple cardiac rhabdomyomas in a juvenile, captive, male fallow deer.

The calf was born at a private breeding facility. At the age of 6 wk, the animal suddenly died after short agonal convulsions. No prior specific health or management problems were reported. At necropsy, the calf was in good body condition and weighed 14.5 kg. The left cardiac ventricular wall and the interventricular septum were moderately thickened by multiple nodular masses, sometimes protruding into the ventricular chambers. On the cut surface, the masses were paler than the surrounding myocardium, not well demarcated, and measured up to 2 cm in diameter (Fig. 1). Their consistency was similar to the adjacent normal myocardium. The lungs were edematous and markedly diffusely congested. The liver and the spleen were also markedly congested. No other macroscopic changes were observed. The stomach was filled with normal milk and plant material. Bacteriologic cultures of lung, liver, kidney, and spleen did not reveal pathogenic microorganisms. Various tissues were fixed in 4% buffered formalin, routinely processed, and stained with hematoxylin and eosin (H&E) for standard light microscopic examination. The heart sections were also stained with periodic acid Schiff (PAS) after diastase digestion, Van Gieson, and phosphotungsten acid he-

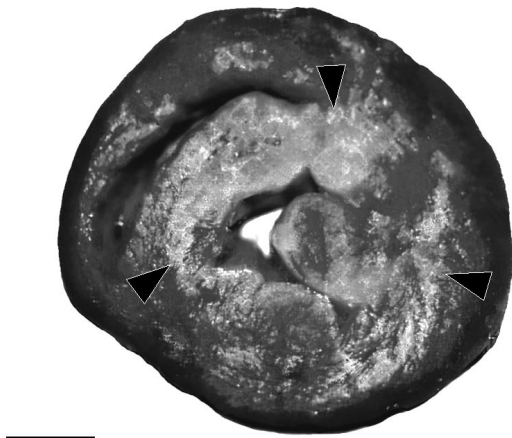


FIGURE 1. Heart, fallow deer. Multiple coalescing pale areas in the myocardium (arrowheads). Note the thickened left ventricle. Bar=1 cm.

matoxylin (PTAH). Additionally, immunohistochemistry was performed with the use of anti-desmin and anti-vimentin mouse antibodies (DAKO, Glostrup, Denmark), according to the manufacturer's protocols.

Histologically, the myocardium contained multiple, poorly demarcated, coalescing masses consisting of groups of tightly arranged, large, interlacing, atypical, pleomorphic, swollen myocytes measuring up to 100 μm diameter (Fig. 2). The cells had variably distinct cell borders. The cytoplasm was mostly deep eosinophilic and often contained aggregates of cross-striated fibers and occasionally large, empty vacuoles, giving the cell a typical "spider cell" appearance (Fig. 3). The nucleus was large, ovoid, centrally located, and contained stippled chromatin and one to two prominent nucleoli. No mitoses were seen. These atypical cells were embedded within an abundant fibrovascular tissue. Throughout the remaining myocardium, there were multiple small areas of fibrosis and mild lymphohistiocytic infiltration. In contrast to the adjacent normal myocytes, the cytoplasm of the atypical cells stained partially positive for PAS after diastase digestion, indicating high glycogen content. In the normal and atypical myocytes, PTAH, because of its affinity for

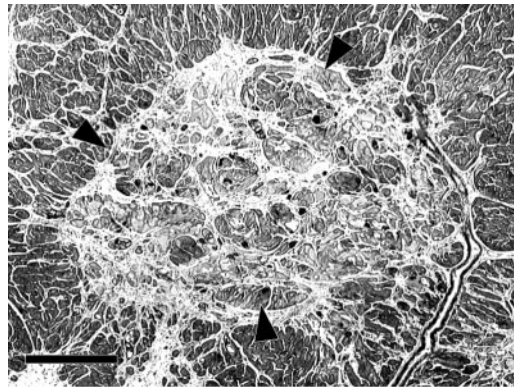


FIGURE 2. Heart, fallow deer. Multiple nodules (arrowheads) of large irregular rhabdomyoma cells embedded in fibrotic tissue. H&E stain. Bar=1 mm.

the Z-bands of contractile myofibrillar proteins, confirmed the striation of the cytoplasmic fibrils observed with H&E. Immunohistochemical staining for desmin, a specific myocytic intermediate filament, was strongly positive in the cytoplasm of normal and atypical myocytes. Immunohistochemical staining for vimentin, an intermediate filament present in cells of mesenchymal origin, weakly stained the cytoplasm of single atypical myocytes and did not react with the adjacent normal myocytes. The surrounding fibrotic areas were strongly positive. Finally, only the fi-

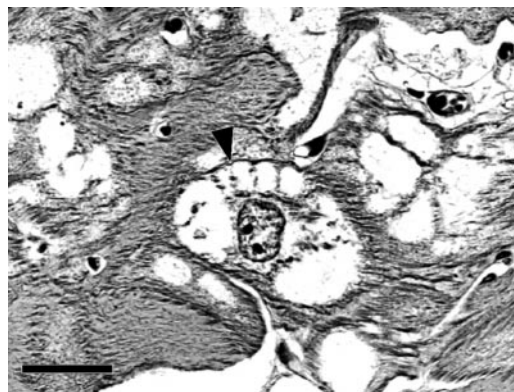


FIGURE 3. Heart, fallow deer. Large polygonal atypical myocytes with vacuolated cytoplasm. Note the radiated appearance of the cytoplasm around the nucleus of a so called "spider cell" (arrowhead). Aggregates of myofibrils in the cytoplasm of these cells are also present. H&E stain. Bar=50 μm .

brotic tissue stained red with Van Gieson, indicating collagen deposition in these areas.

On the basis of the age of the animal, location, gross appearance, distribution, and histologic, chemical, and immunohistochemical features, the lesion was diagnosed as cardiac rhabdomyoma. The absence of mitotic activity observed in this case indicated a benign tumor. The enlargement of the masses was mainly due to an increase in cellular size rather than in cell number, as suggested for rhabdomyomas previously described in swine (Tanimoto and Ohtsuki, 1995). The pulmonary edema and the severe congestion of lung, liver, and spleen were highly suggestive of cardiac failure, the most likely cause of death for this young deer. Indeed, the cardiac masses most probably interfered with cardiac function, either by direct mechanical impairment of myocardial contractile efficiency or by disruption of neuromuscular conduction and stimulation. In one dog, an intra-atrial rhabdomyoma was reported in association with right-sided heart failure (Mansfield et al., 2000). Whether rhabdomyomas represent true neoplasms or hamartomas, which are nonneoplastic developmental anomalies leading to an excessive amount of tissue, is controversial (Benvenuti et al., 2001). In 50% of pediatric cases, cardiac rhabdomyomas are associated with tuberous sclerosis, a hereditary, autosomal dominant, genetic disease caused by mutations in the genes *TCS-1* and *TCS-2*. These genes are thought to play a role in the regulation of the embryonic and neonatal growth and differentiation of cardiomyocytes (Pasumarthi et al., 2000; Vaughan et al., 2001). In pigs and guinea pigs, a familial predisposition to develop cardiac rhabdomyomas is described (Cintorino and Luzi, 1971; Misdorp, 2003), also suggesting a genetic basis of the lesion. However, no genetic analyses have been performed in these species. Malformations in other organs associated with cardiac rhabdomyomas have not been reported in animals. By means of histo-

chemical, immunohistochemical, and ultrastructural techniques, porcine cardiac rhabdomyomas have been shown to arise from remnants of pluripotent embryonic myocardial cells. Therefore, they are considered to result from a dysplastic process and not from a hamartomatous or neoplastic development (Tanimoto and Ohtsuki, 1995).

The features observed in the fallow deer resemble the findings reported in porcine rhabdomyomas. However, the distinction between hamartoma, dysplasia, and tumor remains unclear. No previous reports of a cardiac rhabdomyoma in cervids could be found. Considering that rhabdomyomas are usually clinically silent and are known to regress spontaneously in human cases (Beghetti et al., 1997), this lesion might be underdiagnosed in deer and in nondomestic species in general. To estimate the relevance and prevalence of this lesion in the deer population, a careful examination of the heart is warranted during meat inspection, as well as in the case of undetermined juvenile mortality.

LITERATURE CITED

- BEGHETTI, M., R. M. GOW, I. HANEY, J. MAWSON, W. G. WILLIAMS, AND R. FREEDOM. 1997. Pediatric primary benign cardiac tumors: A 15-years review. *American Heart Journal* 134: 1107–1114.
- BENVENUTI, L. A., V. D. AIELLO, S. FUKASAWA, AND M. L. HIGUCHI. 2001. Cardiac rhabdomyomas exhibit a fetal pattern of atrial natriuretic peptide immunoreactivity. *Experimental Molecular Pathology* 70: 65–69.
- CINTORINO, M., AND P. LUZI. 1971. Myocardial rhabdomyomas in the guinea pig. *Beitrag zur Pathologie* 142: 407–409.
- HOCH-LIGETI, C., C. RESTREPO, AND H. L. STEWART. 1986. Comparative pathology of cardiac neoplasms in humans and in laboratory rodents: A review. *Journal of the National Cancer Institute* 76: 127–142.
- HOLSCHER, M. A., D. L. PAGE, M. G. NETSKY, AND H. S. POWELL. 1977. Mixed glioma and rhabdomyosarcoma in brain of a wild deer. *Veterinary Pathology* 14: 643–647.
- KIDD, G. N., AND R. E. REUTER. 1989. Rhabdomyosarcoma in a fallow deer (*Dama dama*). *The Veterinary Record* 124: 466.
- LOWY, D. R., AND P. M. HOWLEY. 2001. Papillo-

- maviruses. *In* Fields virology, D. M. Knipe, P. M. Howley, D. E. Griffin, R. A. Lamb, M. A. Martin, B. Roizman, and S. E. Strauss (eds.). W. W. Lippincott, Philadelphia, Pennsylvania, p. 2232.
- MANSFIELD, C. S., J. J. CALLANAN, AND H. MCALLISTER. 2000. Intra-atrial rhabdomyoma causing chylopericardium and right-sided congestive heart failure in a dog. *The Veterinary Record* 147: 264–267.
- MCGREGOR, D. K., B. KRISHNAN, AND L. GREEN. 2003. Fine-needle aspiration of adult rhabdomyoma: A case report with review of the literature. *Diagnostic Cytopathology* 28: 92–95.
- MEUTEN, D. J. 2002. Tumors of muscle. *In* Tumors in domestic animals, D. J. Meuten (ed.). Iowa State Press, Ames, Iowa, pp. 319–363.
- MISDORP, W. 2003. Congenital and hereditary tumours in domestic animals. 2. Pigs. A review. *The Veterinary Quarterly* 25: 17–30.
- O'BANION, M. K., AND J. P. SUNDBERG. 1987. Papillomavirus genomes in experimentally induced fibromas in white-tailed deer. *American Journal of Veterinary Research* 48: 1453–1455.
- OMAR, A. R. 1969. Congenital cardiac rhabdomyoma in a pig. *Pathologia Veterinaria* 6: 469–474.
- PASUMARTHI, K. B., H. NAKAJIMA, H. O. NAKAJIMA, S. JING, AND L. J. FIELD. 2000. Enhanced cardiomyocyte DNA synthesis during myocardial hypertrophy in mice expressing a modified TSC2 transgene. *Circulation Research* 86: 1069–1077.
- SALLEE, D., M. L. SPECTOR, D. W. VAN HECKEREN, AND C. R. PATEL. 1999. Primary pediatric cardiac tumors: A 17 year experience. *Cardiology in the Young* 9: 155–162.
- SUNDBERG, J. P., AND S. W. NIELSEN. 1981. Deer fibroma: A review. *The Canadian Veterinary Journal* 22: 385–388.
- TANIMOTO, T., AND Y. OHTSUKI. 1995. The pathogenesis of so-called cardiac rhabdomyoma in swine: A histological, immunohistochemical and ultrastructural study. *Virchows Archive* 427: 213–221.
- VAUGHAN, C. J., M. VEUGELERS, AND C. T. BASSON. 2001. Tumors and the heart: Molecular genetic advances. *Current Opinion in Cardiology* 16: 195–200.
- WARE, W. A., AND D. L. HOPPER. 1999. Cardiac tumors in dogs: 1982–1995. *Journal of Veterinary Internal Medicine* 13: 95–103.

Received for publication 2 October 2003.