

NATURAL AND EXPERIMENTAL WEST NILE VIRUS INFECTION IN FIVE RAPTOR SPECIES

Authors: Nemeth, Nicole, Gould, Daniel, Bowen, Richard, and Komar, Nicholas

Source: Journal of Wildlife Diseases, 42(1) : 1-13

Published By: Wildlife Disease Association

URL: <https://doi.org/10.7589/0090-3558-42.1.1>

BioOne Complete (complete.BioOne.org) is a full-text database of 200 subscribed and open-access titles in the biological, ecological, and environmental sciences published by nonprofit societies, associations, museums, institutions, and presses.

Your use of this PDF, the BioOne Complete website, and all posted and associated content indicates your acceptance of BioOne's Terms of Use, available at www.bioone.org/terms-of-use.

Usage of BioOne Complete content is strictly limited to personal, educational, and non - commercial use. Commercial inquiries or rights and permissions requests should be directed to the individual publisher as copyright holder.

BioOne sees sustainable scholarly publishing as an inherently collaborative enterprise connecting authors, nonprofit publishers, academic institutions, research libraries, and research funders in the common goal of maximizing access to critical research.

NATURAL AND EXPERIMENTAL WEST NILE VIRUS INFECTION IN FIVE RAPTOR SPECIES

Nicole Nemeth,^{1,2,3} Daniel Gould,² Richard Bowen,² and Nicholas Komar¹

¹ Centers for Disease Control and Prevention, Fort Collins, Colorado 80522, USA

² College of Veterinary Medicine and Biomedical Sciences, Colorado State University, Fort Collins, Colorado 80523, USA

³ Corresponding author (email: nnemeth@colostate.edu)

ABSTRACT: We studied the effects of natural and/or experimental infections of West Nile virus (WNV) in five raptor species from July 2002 to March 2004, including American kestrels (*Falco sparverius*), golden eagles (*Aquila chrysaetos*), red-tailed hawks (*Buteo jamaicensis*), barn owls (*Tyto alba*), and great horned owls (*Bubo virginianus*). Birds were infected per mosquito bite, per os, or percutaneously by needle. Many experimentally infected birds developed mosquito-infectious levels of viremia ($>10^5$ WNV plaque forming units per ml serum) within 5 days postinoculation (DPI), and/or shed virus per os or per cloaca. Infection of organs 15–27 days postinoculation was infrequently detected by virus isolation from spleen, kidney, skin, heart, brain, and eye in convalescent birds. Histopathologic findings varied among species and by method of infection. The most common histopathologic lesions were subacute myocarditis and encephalitis. Several birds had a more acute, severe disease condition represented by arteritis and associated with tissue degeneration and necrosis. This study demonstrates that raptor species vary in their response to WNV infection and that several modes of exposure (e.g., oral) may result in infection. Wildlife managers should recognize that, although many WNV infections are sublethal to raptors, subacute lesions could potentially reduce viability of populations. We recommend that raptor handlers consider raptors as a potential source of WNV contamination due to oral and cloacal shedding.

Key words: American kestrel, barn owl, experimental infection, golden eagle, great horned owl, histopathology, raptors, red-tailed hawk, West Nile virus.

INTRODUCTION

West Nile virus (WNV; family *Flaviviridae*) emerged in North America in 1999 and has since spread across much of the United States, Canada, Mexico, and the Caribbean Basin, causing morbidity and mortality in people, horses, and hundreds of bird species (Komar, 2003). Avian disease due to WNV infections is a novel phenomenon; before 1998 natural occurrence had only been reported in two instances, each affecting a single bird (Work et al., 1953; Burt et al., 2002).

The extent of morbidity and mortality due to WNV in raptor species in the wild remains unknown. Although WNV infections have been reported from 36 species of raptors in the United States through February 2005 (Table 1), estimates of morbidity and mortality are not available. Raptor species that were infected experimentally failed to develop overt disease (Komar et al., 2003), but several cases of WNV-induced disease in raptor species

have been described (Garmendia et al., 2000; Steele et al., 2000; Ludwig et al., 2002; Fitzgerald et al., 2003; D'Agostino and Isaza, 2004; Gancz et al., 2004; Wünschmann et al., 2004). More data are needed to understand the impact of WNV infection on raptor populations and the full spectrum of disease syndromes that may occur in these species. Differential response of raptor species to WNV, in terms of viremia or clinical outcomes, has not been studied rigorously.

Raptors may play an important role in the transmission of WNV. To better understand the response of different raptor species to WNV infection, we infected American kestrels (*Falco sparverius*), red-tailed hawks (*Buteo jamaicensis*), great horned owls (*Bubo virginianus*), and barn owls (*Tyto alba*). For each infected bird, we evaluated viremia to determine infectiousness to mosquitoes, oral and cloacal shedding to determine potential risks to wildlife handlers, and clinical illness and pathologic effects on tissues

TABLE 1. Number of individuals of 36 raptor species found dead with WNV infection and reported in the USA from 1999 to 2004.^{a,b}

Common name	Scientific name	No.
Osprey	<i>Pandion haliaetus</i>	5
Swallow-tailed kite	<i>Elanoides forficatus</i>	1
White-tailed kite	<i>Elanus leucurus</i>	3
Mississippi kite	<i>Ictinia mississippiensis</i>	2
Bald eagle	<i>Haliaeetus leucocephalus</i>	23
Northern harrier	<i>Circus cyaneus</i>	3
Sharp-shinned hawk	<i>Accipiter striatus</i>	104
Cooper's hawk	<i>Accipiter cooperii</i>	145
Northern goshawk	<i>Accipiter gentilis</i>	16
Unidentified hawk	<i>Leucopternis</i> sp.	2
Harris' hawk	<i>Parabuteo unicinctus</i>	1
Red-shouldered hawk	<i>Buteo lineatus</i>	40
Broad-winged hawk	<i>Buteo platypterus</i>	10
Swainson's hawk	<i>Buteo swainsoni</i>	11
Red-tailed hawk	<i>Buteo jamaicensis</i>	299
Ferruginous hawk	<i>Buteo regalis</i>	7
Rough-legged hawk	<i>Buteo lagopus</i>	3
Golden eagle	<i>Aquila chrysaetos</i>	26
American kestrel	<i>Falco sparverius</i>	100
Merlin	<i>Falco columbarius</i>	12
Gyr falcon	<i>Falco rusticolus</i>	3
Peregrine falcon	<i>Falco peregrinus</i>	3
Prairie falcon	<i>Falco mexicanus</i>	4
Barn owl	<i>Tyto alba</i>	32
Taliabu masked owl	<i>Tyto nigrobrunnea</i>	1
Flammulated owl ^c	<i>Otus flammeolus</i>	1
Western screech owl	<i>Megascops kennicottii</i>	7
Eastern screech owl	<i>Megascops asio</i>	12
Great horned owl	<i>Bubo virginianus</i>	258
Snowy owl	<i>Bubo scandiacus</i>	10
Elf owl	<i>Micrathene whitneyi</i>	1
Burrowing owl	<i>Athene cunicularia</i>	3
Barred owl	<i>Strix varia</i>	16
Unidentified owl	NA	2
Long-eared owl	<i>Asio otus</i>	3
Short-eared owl	<i>Asio flammeus</i>	2
Northern saw-whet owl	<i>Aegolius acadicus</i>	2

^a Data collected through February 2005 provided by CDC Arbonet Surveillance System; Zoonotic Surveillance System for West Nile Virus; Anderson et al., 1999; Steele et al., 2000; Eidson et al., 2001.

^b Nomenclature follows the latest edition of the A.O.U. Check-List for North American bird species (American Ornithologists' Union, 2005) and the World Checklist of Birds (Monroe and Sibley, 1993) for Taliabu masked owl.

^c CDC, unpublished data.

NA, not applicable.

to document disease syndromes in these species. In addition, several naturally infected individuals of these four species, as well as golden eagles (*Aquila chrysaetos*), were examined postmortem for comparison.

MATERIALS AND METHODS

Source and husbandry of raptors

From July 2002 to March 2004, American kestrels, red-tailed hawks, great horned owls, and barn owls were received from various rehabilitation centers in Colorado, Nebraska,

Oregon, and California. Nonreleasable, but apparently healthy raptors were received opportunistically as they became available. Birds were held in a biosafety level-3 animal care facility at Colorado State University. Birds adjusted to their new environment for 3–7 days before experimental infection. All birds were fed laboratory mice (*Mus musculus*) ad libitum, and water was provided.

Thirteen naturally infected birds (WNV-seropositive) were provided by various raptor facilities. Of these, two great horned owls, one red-tailed hawk, and two golden eagles had shown severe neurologic signs (tremors, dysphagia, nystagmus, coma, ataxia, seizures, recumbency, and paralysis) and were euthanized at their respective facilities, except for one eagle that died naturally. One of the great horned owls was euthanized after having shown neurologic signs intermittently for approximately 5½ months. The clinically normal birds (three American kestrels and five red-tailed hawks) were included for pathologic comparison.

Komar et al. (2003) previously reported viremia, cloacal and oral shedding, and viral tropism in the mosquito-infected American kestrels and great horned owls, as well as a proportion of those fed infected mice; results are included here for purposes of comparison with other species and modes of infection, and correlation with pathology findings in the same individuals.

Infection of birds

Birds seronegative by plaque-reduction neutralization test (PRNT) were experimentally infected, while seropositive birds were observed for approximately two weeks before being euthanized. Experimental groups included mosquito-inoculated, orally exposed, and needle-inoculated groups. The mosquito-inoculated group consisted of two American kestrels and one great horned owl, infected via the bite of an adult, female *Culex tritaeniorhynchus* mosquito, which had been intrathoracically inoculated (strain WNV-NY99-6480, passed once in Vero cell culture) as described in Komar et al. (2003). The orally exposed group consisted of one great horned owl, five American kestrels, and three red-tailed hawks; birds in this group were fed WNV-infected mice. Adult mice were infected with WNV by needle-inoculation subcutaneously (WNV-NY99-4132, passed twice in Vero cell culture; 0.1 ml, $10^{3.8}$ plaque-forming units [PFU]) and euthanized 7–9 days postinfection (DPI) when clinical signs became evident. Three American kestrels consumed approximately one mouse

each and two consumed the head only, the great horned owl consumed three mice, and the red-tailed hawks consumed one mouse each. The needle-inoculated group consisted of two great horned owls, two barn owls, five red-tailed hawks, and one American kestrel infected by subcutaneous injection (WNV-NY99-4132, passed one to three times in Vero cell culture; 400–2,000 PFU). We evaluated direct contact transmission in two birds (one American kestrel and one red-tailed hawk) housed together with infected conspecifics in a room with dimensions 12×18×11 ft.

Evaluation of clinical signs

Infected birds were checked twice daily at approximately 12-hr intervals for abnormal behavior, including neurologic signs such as opisthotonus, head tilt, ataxia, and disorientation. Food intake was monitored daily. For some birds, daily weight changes were evaluated.

Sample collection for virology

Initial blood samples (0.6 ml) were removed by jugular (American kestrels and red-tailed hawks) or ulnar venipuncture (great horned owls and barn owls). Experimentally infected birds were observed for clinical abnormalities and blood was sampled daily for viremia titrations from 1–7 DPI. Blood samples (0.2 ml) were diluted into 0.9 ml BA1 medium, which consisted of Hank's M-199 salts, 1% bovine serum albumin, 350 mg/l sodium bicarbonate, 100 units/ml penicillin, 100 mg/l streptomycin, 1 mg/l Fungizone in 0.05 M Tris, pH 7.6. Diluted blood was held at room temperature for approximately 30 min before centrifugation at $2000 \times G$ for 10 min, and storage at -70°C .

Oropharyngeal and cloacal swab samples were collected daily from all experimentally infected birds for at least 7 DPI (up to 14 DPI for some birds). Cotton-tipped swabs were used to sample the oropharyngeal and cloacal cavities and were then placed in cryovials containing 0.5 or 1 ml of BA1 medium. Swab samples were placed immediately on ice and into a -70°C freezer within 30 min.

Tissue and casting homogenization

The following tissues were collected for virus isolation from experimentally and naturally infected birds: heart, lung, esophagus, liver, small intestine, spleen, kidney, gonad, skin, brain, and eye. Once removed, tissues (approximately 0.5 cm^3) were placed in cryovials on dry ice, and into a -70°C freezer

within 3 hr. Tissues were later homogenized by grinding each piece in a Ten Broeck tissue grinder with alundum grinding crystals and 2.0 ml BA1 medium containing 20% fetal bovine serum. Homogenates were placed in 1.7-ml Eppendorf tubes for centrifugation at $10,000 \times G$ for 3 min. Supernatant was stored in cryovials at -70°C and later tested for virus by plaque assay on Vero cells. Tissues from golden eagles were not tested by virus isolation with the exception of the heart of one eagle. Virus isolation from all WNV-positive tissues was confirmed through reisolation.

Castings from orally and mosquito-infected great horned owls were tested daily for WNV from 1 to 16 DPI. Approximately 0.5 cm^3 pieces were removed from the center of each casting, and this material was homogenized by the same methods as those described for tissues.

Plaque assay, PRNT, and RT-PCR

For quantification of virus in serum samples, oropharyngeal and cloacal swab samples, tissue homogenates, and great horned owl casting homogenates, Vero cell monolayers in six-well plates were inoculated in duplicate with 0.1 ml of sample per well. After 1 hr of incubation at 37°C , the cells were overlaid with 3 ml/well of 0.5% agarose (in M-199 medium supplemented with 350 mg/l sodium bicarbonate, 29.2 mg/l L-glutamine, and antibiotics as with BA1). Two days later, cells were overlaid with 0.5% agarose with 0.004% neutral red dye (Sigma Chemical Corp, St. Louis, Missouri, USA). Viral plaques were counted after 3 and 4 days of incubation.

Serum samples collected before experimental infection were screened at a dilution of 1:10 for WNV-neutralizing antibodies by PRNT using WNV-NY99-4132 (Beaty et al., 1995). To avoid potential effects of pre-existing heterogeneous cross-reactive flavivirus antibodies, specimens were also evaluated for neutralizing antibodies to St. Louis encephalitis virus (TBH-28 strain). On the day of euthanasia, blood samples from all experimentally inoculated birds were tested by PRNT to confirm the presence of neutralizing antibodies against WNV. Serial twofold dilutions of serum (beginning at a dilution of 1:10) from all needle-inoculated subjects were tested on 4, 5, 6, 7 DPI, and day of euthanasia (15–27 DPI) to determine end point 90% neutralization (PRNT_{90}) titers. The golden eagles were diagnosed postmortem by polymerase chain reaction (PCR) of either brain or pooled brain and kidney (Lanciotti et al., 2000).

Pathology

All birds except for the one spontaneous death were euthanized by sodium pentobarbital (100 mg/kg) overdose; experimentally infected birds were euthanized between 15 and 27 DPI. Most birds were necropsied within 2 hr of death, while several naturally infected bird carcasses were refrigerated between 6 and 20 hr before necropsy.

The following tissues were routinely collected at necropsy for histopathologic examination: heart, liver, spleen, kidney, skeletal muscle, lung, pancreas, duodenum, jejunum, large intestine, proventriculus, ventriculus, cerebrum, cerebellum, midbrain, and spinal cord. Tissues were preserved with 10% buffered formalin, embedded in paraffin, sectioned at $5\text{ }\mu\text{m}$ and stained with hematoxylin and eosin.

Three uninfected American kestrels were used as controls.

RESULTS

Clinical signs

No experimentally infected birds showed overt clinical signs or died from WNV during the study, although barn owls and great horned owls consumed noticeably fewer mice between 2–11 DPI than before infection.

Viremia and serology

All mosquito- and needle-inoculated birds became viremic and seroconverted, and all but the barn owls developed viremia levels considered infectious to *Culex pipiens* mosquitoes ($>10^5$ PFU WNV/ml blood; Turell et al., 2002) (Table 2). Of the orally exposed group, the one great horned owl and one of the five American kestrels (but none of three red-tailed hawks) developed viremia and seroconverted. None of the two in-contact birds were infected. The needle-inoculated American kestrel developed neutralizing antibodies on 6 DPI, with a reciprocal PRNT_{90} of 10, which increased to 40 by 7 DPI and 80 by 16 DPI. Each of the five needle-inoculated hawks had a similar pattern of neutralizing antibody development, first detectable on 5 DPI (reciprocal PRNT_{90} from 10 to 40), which increased to 80–

TABLE 2. West Nile virus (WNV) titers and duration of viremia (titers expressed as log PFU per ml serum) and shedding (titers expressed as log PFU per swab) in individuals of four species of raptors experimentally infected^a with WNV.

Species	Bird No.	Infection route	Viremia			Oral shedding ^g			Cloacal shedding		
			Peak titer	Peak day(s) ^b	Range (days)	Peak titer	Peak day(s)	Range (days)	Peak titer	Peak day(s)	Range (days)
American kestrel	AK9	Mice	5.7	2–3	1–7	4.4	6–7	2–13	2.8	6	2–13
	AK4	Mosquito	8.7	2	1–5	5.3	6	1–10 ^c	5.2	4	1–7 ^c
	AK5	Mosquito	6.1	3	1–4	4.6	5–6	1–9 ^c	4.5	3	1–6 ^c
	AK10	Needle	6.1	3–4	2–6	4.6	6	2–10 ^{d,e}	4.2	4	2–9 ^{d,e}
Great horned owl	GHO1	Mice	5.4	3	1–5	3.6	3–5	2–7 ^f	1.6	7	1–7 ^f
	GHO2	Mosquito	7.6	3	1–6	5.8	5	2–7 ^f	3.3	6	2–7 ^f
	GHO3	Needle	7.1	4	1–6	5.2	5	2–13 ^e	3.7	4–6	3–12 ^e
	GHO5	Needle	6.1	3	1–6	3.7	4–5	2–11 ^e	3.6	13	2–14 ^e
Barn owl	BO1	Needle	3.6	2–3	1–4	2.7	5	4–12 ^e	0	NA	NA
	BO2	Needle	3.0	4	2–4	2.7	5	3–12 ^e	0	NA	NA
Red-tailed hawk	RTH7	Needle	7.8	3	1–6	5.6	6	2–11 ^e	5.6	5–6	2–13 ^e
	RTH8	Needle	6	4	1–6	4.3	6	3–13 ^e	4.1	4	2–13 ^e
	RTH9	Needle	6	3	1–5	4.4	5	3–10 ^e	4	4	2–9 ^e
	RTH10	Needle	5.6	3	1–5	5.1	4	2–7 ^e	4.1	4	2–9 ^e
	RTH11	Needle	6.6	3	1–5	5	6	2–7 ^e	3.1	5	2–13 ^e

^a Birds that failed to develop viremia and seroconvert were considered uninfected and were not included in this table.

^b “Peak Day” refers to day postinoculation when peak titers were detected.

^c Some birds in this category not sampled after 11 DPI.

^d Not sampled on 11 or 12 DPI.

^e Some birds in this category not sampled after 13 DPI.

^f Not sampled after 7 DPI.

1,280 by 7 DPI, but decreased one- or twofold by 15 DPI in all but one hawk. The two needle-inoculated horned owls developed neutralizing antibodies on 6–7 DPI, each with a reciprocal PRNT₉₀ of 20, with titers of 320–640 by 15 DPI. Of the two needle-inoculated barn owls, one developed neutralizing antibodies on 7 DPI (reciprocal PRNT₉₀ of 10), but the other had not, and sera were not tested again until 27 DPI, at which time both birds had relatively low reciprocal PRNT₉₀ of 40 and 80.

Viral shedding

Shedding of WNV was detected in oropharyngeal and cloacal swabs beginning within the first 3 DPI and extending beyond the periods of viremia, except for cloacal swabs from the barn owls, which were never virus positive (tested 1–13 DPI; Table 2). No infectious

virus was detected in great horned owl castings.

Viral isolation from tissues

WNV was isolated from several tissues of experimentally infected birds upon euthanasia (Table 3). Low levels of virus were detected in various tissues from all American kestrels infected by mosquito or needle inoculation and from some needle-inoculated great horned owls and red-tailed hawks. Eye was the tissue from which virus was most commonly isolated. Tissues tested from clinically ill, naturally infected birds (two great horned owls, one red-tailed hawk, and two golden eagles) were negative by virus isolation except for the heart of one golden eagle that died during the acute phase of infection. Tissues from naturally infected, apparently healthy raptors (three American kestrels and five red-tailed hawks) were negative for WNV.

TABLE 3. West Nile virus isolation from various tissues of experimentally infected raptors (in PFU/0.5 cm³). Birds testing negative for all tissues are not included.^a

Species and identification	Euthanasia day (DPI)	Infection route	Tissue					
			Spleen	Kidney	Skin	Heart	Brain	Eye
Kestrel, AK4	15	mosquito	20	20	30	0	0	0
Kestrel, AK5	15	mosquito	10	0	0	0	0	0
Kestrel, AK10	16	needle	0	0	0	0	0	500
Horned owl, GHO3	15	needle	0	0	0	0	0	530
Horned owl, GHO5	27	needle	0	45	0	0	0	0
Barn owl, BO2	27	needle	0	0	0	0	0	15
Hawk, RTH7	15	needle	0	0	0	0	0	145
Hawk, RTH9	15	needle	5	0	0	10	0	0
Hawk, RTH11	15	needle	0	0	0	0	5	2,000

^a Experimentally infected raptors with negative tissues included an American kestrel (AK9, euthanized 45 DPI), great horned owls (GHO1 euthanized 19 DPI, GHO2 euthanized 18 DPI), a barn owl (BO1, euthanized 27 DPI), and red-tailed hawks (RTH8 and RTH10, euthanized 15 DPI).

Gross pathology

At necropsy, all birds were in excellent body condition and gross pathologic findings were limited. Individuals of all species examined except for eagles and barn owls had randomly distributed pale epicardial foci or streaking, varying in size from 2 to 6 mm and extending into the myocardium by 1–5 mm (2 of 7 American kestrels, 7 of 11 red-tailed hawks, 2 of 6 great horned owls) and splenomegaly (4 of 7 American kestrels, 5 of 11 red-tailed hawks, 5 of 6 great horned owls). The clinically ill, naturally infected

birds had varying lesions. A red-tailed hawk (RTH6) and great horned owl (GHO4) had distinctive softening of one cerebral hemisphere. Incidental findings included a peripharyngeal abscess in an American kestrel (AK10), and a cloacal abscess in a great horned owl (GHO6).

Common histologic lesions

Various histologic lesions were commonly observed among the raptor species examined (Table 4). These lesions included: mild to severe encephalitis, typically

TABLE 4. Summary of histologic lesion patterns in five raptor species experimentally and naturally infected with West Nile virus.

Species	n	Mononuclear cell ^a accumulation				Arteritis			
		Heart	Liver	Kidney	Brain ^b	Heart	Liver	Kidney	Brain
Experimental									
American kestrels	4	3/4	3/4	3/4	4/4	2/4	1/4	2/4	0/4
Great horned owls	4	4/4	3/4	4/4	2/4	1/4	0/4	0/4	0/4
Barn owls	2	0/2	1/2	0/2	0/2	0/2	0/2	0/2	0/2
Red-tailed hawks	5	5/5	2/5	4/5	5/5	1/5	0/5	0/5	3/5
Natural									
American kestrels	3	1/3	2/3	2/3	1/3	1/3	0/3	0/3	0/3
Great horned owls	2	2/2	2/2	2/2	0/2	0/2	0/2	0/2	0/2 ^c
Red-tailed hawks	6	2/6	2/6	3/6	5/6	0/6	0/6	0/6	1/6 ^c
Golden eagles	2	0/2	1/2	0/2	2/2	0/2	0/2	0/2	0/2

^a Mononuclear cells consisted of lymphocytes, plasma cells, and macrophages.

^b Brain lesions consisted of microglial cells with occasional lymphocytes.

^c Additional brain lesions included encephalomalacia with mineralization.

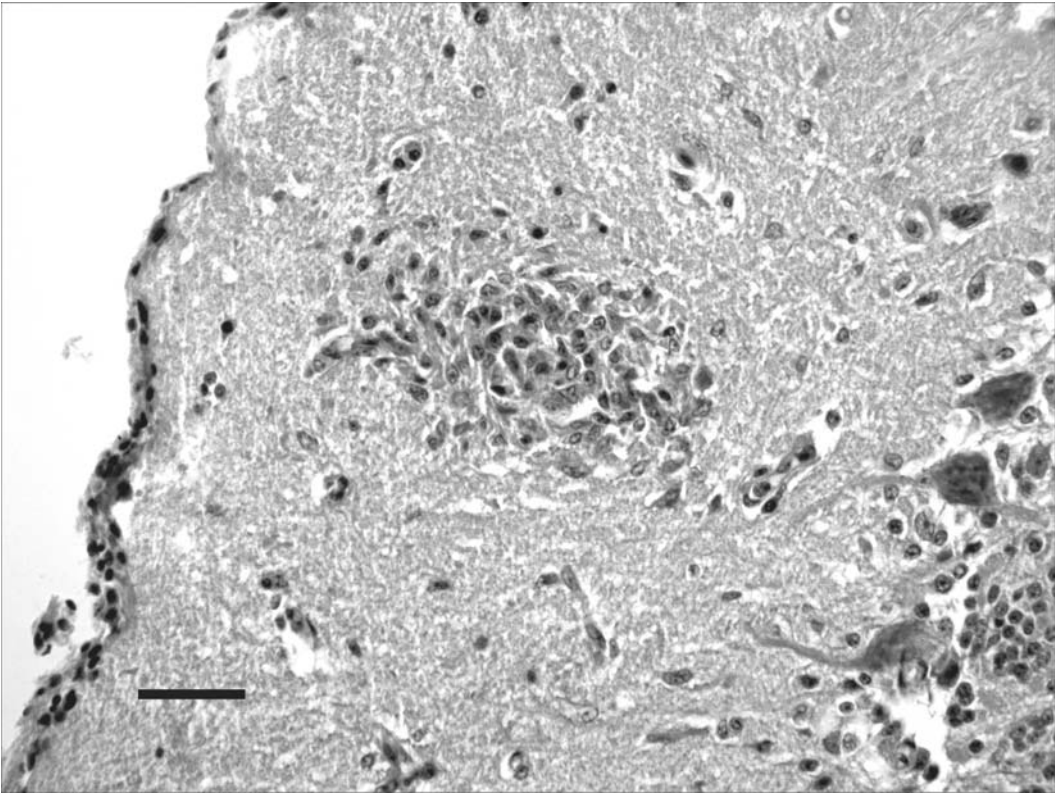


FIGURE 1. Glial nodule in molecular layer of cerebellum in an American kestrel (AK5) experimentally infected with West Nile virus by mosquito. Hematoxylin and eosin. Bar = 30 μ m.

with focal gliosis in the molecular layer of the cerebellum (Fig. 1) but sometimes in the cerebrum or midbrain; focal, randomly distributed subacute myocarditis; mild to severe, subacute heterophilic nephritis; and mild, multifocal subacute periportal hepatitis. Inflammation was usually characterized by lymphocytes, plasma cells, and macrophages. A mild, focal subacute pectoral myositis was less common (2 of 7 American kestrels, 3 of 11 red-tailed hawks, 1 of 6 great horned owls). There were no statistically significant differences in the frequencies ($P > 0.05$, Fisher's Exact Test) of these common lesions between the naturally and experimentally infected groups by species.

Uncommon histologic lesions

Especially severe lesions were observed in some organs of birds infected via

mosquito or needle. One mosquito- and one needle-infected American kestrel had severe encephalitis (AK5, AK10, respectively), whereas one naturally infected red-tailed hawk (RTH6) with clinical neurological signs had severe cerebral necrosis with arteritis; of the five needle-inoculated red-tailed hawks with encephalitis, three had cerebral arteritis (RTH7, 8, 10). The naturally infected great horned owl (GHO4) with severe clinical signs had necrosis and mineralization affecting the cerebellum and one cerebral hemisphere.

Mosquito-inoculated American kestrels (AK4, 5), needle-inoculated red-tailed hawks (RTH7, 8, 11), and mosquito- and needle-inoculated great horned owls (GHO2, 3, respectively) had the most extensive and severe myocarditis. Three American kestrels (2 mosquito-inoculated,

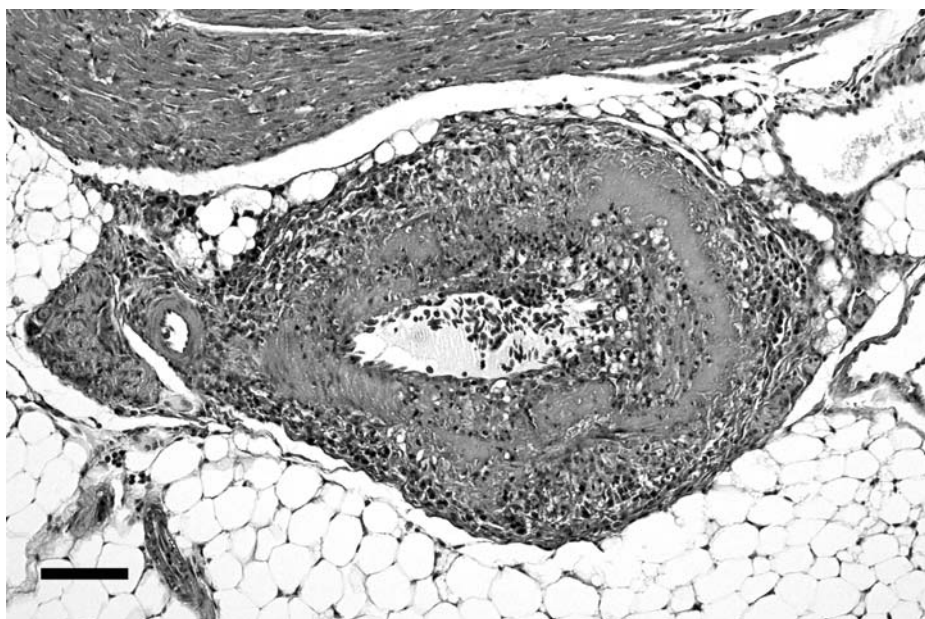


FIGURE 2. Coronary arteritis characterized by segmental necrosis, lymphocytes, and mononuclear cells in an American kestrel (AK5) experimentally infected with West Nile virus by mosquito. Hematoxylin and eosin. Bar = 100 μ m.

AK4 and 5, and one naturally infected, AK8), and a needle-inoculated great horned owl (GHO3) and red-tailed hawk (RTH7) had myocardial arteritis, usually accompanied by segmental necrosis, and sometimes fibrinoid change (Fig. 2).

Both mosquito-inoculated American kestrels (AK4, 5) and one naturally infected kestrel had moderate, subacute nephritis with severe necrotizing arteritis; one mosquito-inoculated and one naturally infected great horned owl (GHO2 and 3, respectively) had severe, subacute nephritis, the former with arteritis. One naturally infected American kestrel (AK6) had hepatic arteritis. One mosquito-inoculated great horned owl (GHO2) had severe heterophilic hepatitis, while one naturally infected great horned owl (GHO6) had severe granulomatous hepatitis with multinucleated giant cells. One naturally infected red-tailed hawk had inhalation pneumonia (RTH6), determined by microscopic examination.

Patterns of histologic lesions associated with infection route

The orally infected birds had relatively fewer histopathologic lesions than birds infected by other routes; lesions in these birds were limited to mild encephalitis (AK9) and moderate myocarditis and mild subacute nephritis (GHO1). The most severe lesions occurred in the myocardium and kidney of mosquito-infected birds (AK4, AK5, GHO2). In general, needle-inoculated and naturally infected birds had mild lesions patterns in the heart, kidney, liver, and brain.

Patterns of histologic lesions associated with species

Needle-inoculated barn owls were noteworthy for the absence of gross and histologic lesions (Table 4). Golden eagles had a relative lack of lesion development despite suffering from lethal natural infection. A common lesion pattern, arteritis, was observed among American kestrels, red-tailed hawks, and great horned

owls. Arteritis was observed most in kestrels (2 of 7 kidneys, 1 of 7 livers, 3 of 7 hearts), and hawks (4 of 11 brains, 1 of 11 hearts), with a single case in a great horned owl heart. However, the difference in frequencies of arteritis observations by species was not statistically significant, even when the four affected organs were combined ($P > 0.05$, Fisher's Exact Test).

DISCUSSION

It is not clear why we failed to observe clinical illness in 15 experimentally infected raptors. Apparently, expression of clinical disease in the four experimentally infected raptor species examined is variable. The WNV disease rate in a captive wildlife setting was 40% for Strigiformes and 0% for Falconiformes (Ludwig et al., 2002). High death rates associated with WNV were observed in five species of Strigiformes of northern native breeding range in a captive population of owls in southern Ontario, Canada, though within this population, only 1 of 13 (8%) infected great horned owls died, while 0 of 8 infected barn owls died (Gancz et al., 2004). Considering anecdotal reports of recent die-offs in wild raptors and documented events involving captive raptors with acute neurologic signs testing positive for WNV (Fitzgerald et al., 2003; D'Agostino and Isaza, 2004), we expected to observe clinical signs in some of the experimentally infected raptors. We did observe clinical illness in raptors naturally infected with WNV that culminated in death. One great horned owl exhibited intermittent, mild clinical signs for more than five months while receiving supportive care at a rehabilitation center. The reason(s) for differences in expression of clinical disease between experimentally and naturally infected birds is unresolved.

Viremia levels of infected raptors were as expected (except for barn owls) based on observations in preliminary studies in two American kestrels and one great horned owl (Komar et al., 2003). Levels

of viral shedding in American kestrels, great horned owls, and red-tailed hawks were similar to various corvid species. These results suggest that American kestrels, great horned owls, and red-tailed hawks (but not barn owls) are competent amplifying hosts for WNV in the transmission cycle. Viremias and shedding in barn owls were reduced relative to the other raptor species examined, and barn owls developed neutralizing antibodies slightly later than other species. Ludwig et al. (2002) suggested that Old-World birds (such as barn owls) may be less susceptible to disease from WNV than New-World birds (such as red-tailed hawks and great horned owls) because of coevolution, given that WNV is an Old-World virus.

Our finding that an American kestrel was infected by the oral route confirms previous reports from a great horned owl and passerine birds (Komar et al., 2003), cats (Austgen et al., 2004), and alligators (Klenk et al., 2004). We were unable to demonstrate susceptibility to oral infection among the red-tailed hawks. An encephalitic red-tailed hawk found in New York in February 2000 was speculated to have become infected after consumption of persistently infected prey (Garmendia et al., 2000). In our study, infected mice were euthanized in the acute phase of infection when they began to show clinical signs; as wild prey items, these infected rodents would be relatively easy prey for raptors. The predatory nature of raptors, along with reports of WNV-positive mammals (e.g., Heinz-Taheny et al., 2004), establish the possibility of oral infection in some free-ranging raptors through consumption of infected prey.

We detected WNV infection in tissues of surviving birds up to 23 days after the detection of viremia (Tables 2 and 3). These prolonged infections were uncommon and of low viral titer, except for some eye infections. Senne et al. (2000) were unable to isolate WNV from clinically normal chicken tissues after 10 DPI.

Komar et al. (2003) tested tissues from subclinically infected birds at 14–15 DPI, and found infectious WNV in 18 individuals of 10 species by Vero plaque assay, but never beyond 13 days after viremia; kidney, spleen, skin, and eye were most consistently positive. We were unable to detect virus in tissues of clinically normal, naturally infected birds. Although the number of days after infection that these tissues were tested was unknown, we suspect that infection had occurred within several months before testing based on the age of birds and first reports of WNV in regions where the birds originated.

In our study, we observed a limited number of birds with severe histologic lesions, although we frequently failed to isolate virus from organs with these lesions. This finding, combined with the lack of clinical signs and rapid antibody responses, suggests that most of these apparently healthy birds had a low-grade, nonprogressive infection, with successful immune-mediated clearance of infectious WNV. Birds with severe lesions and lack of virus in affected tissues included a mosquito-infected American kestrel with fibrinoid arteritis (AK5) (Fig. 2), a naturally infected red-tailed hawk (RTH6) with encephalitis and inhalation pneumonia (potentially a sequel to dysphagia), and a naturally infected great horned owl (GHO4) with cerebral malacia and mineralization. As expected, birds showing clinical neurologic signs had brains that were more affected both grossly and histologically. The subtle, though sometimes severe, arteritis lesions in both naturally and experimentally infected raptors could potentially affect survival in the wild.

The presence of arteritis in various organs (Table 4) had not been previously documented in raptors with WNV infection. It has been documented, however, in an Arctic wolf (*Canis lupus*) with severe renal lymphoplasmacytic vasculitis with fibrinoid degeneration of vessel walls (Lanthier et al., 2004), while farmed

alligators had heterophil stasis within blood vessels in brain and meninges (Miller et al., 2003). Immunohistochemistry revealed WNV antigen in smooth muscle cells of arteries in red-tailed hawks and Cooper's hawks (*Accipiter cooperi*) (Wünschmann et al., 2004). We found that vasculitis was relatively difficult to assess in veins and venules, while it was more conspicuous in thicker-walled vessels such as arteries and arterioles; therefore, we characterized only arteritis. The degree and character of arteritis varied by individual bird, as well as by tissue, but was most commonly observed in heart, kidney, and brain. In American kestrels, arteritis was observed in birds infected experimentally by mosquito, or by natural infection (most likely infected by mosquito), but not by needle inoculation or per os exposure. Although arteritis in these cases could be related to some concurrent disease processes unrelated to WNV, it is consistent with a type III hypersensitivity reaction (Fauci, 1983; Yancey et al., 1984). If the vascular lesions were a result of WNV infection, they may have resulted from deposition of antigen-antibody complexes in vessel walls or in areas of tissue damage, thereby eliciting an inflammatory response. In these cases, animals may seem clinically normal for an undetermined time postinfection. More work is needed in the area of pathogenesis of WNV and in comparing infections that lead to clinical signs versus those that are subclinical.

Although we observed unusual lesions not previously reported in birds infected with WNV, the general lesion patterns were consistent with previous studies. Our gross and histologic findings in raptors are similar to findings in chickens (Senne et al., 2000), turkeys (Swayne et al., 2000), hawks (Garmendia et al., 2000; Wünschmann et al., 2004), owls (Fitzgerald et al., 2003), and a variety of other bird species (Ludwig et al., 2002), including a bald eagle (*Haliaeetus leucocephalus*) and snowy owl (*Bubo scandiacus*) (Steele et al., 2000).

The results of this study have important

implications for the impact of WNV infection on raptor populations. Subclinical WNV infection may have very different effects on survival in wild birds than is evident in an experimental situation (Hanson, 1988). We suspect that many birds that do not develop clinical signs are indeed at higher risk of mortality in nature because of their pathologic lesions. Such mortality would not likely be attributed to WNV infection. Our observation of varying severity of WNV lesions among different species and individuals could have important management implications and requires further examination (our sample sizes were too small to elucidate interspecies differences). The possibility of enhanced transmission pressure on raptors due to oral transmission further places raptor populations at risk. Though the actual effects of WNV on free-ranging raptor populations are not well understood, the amplifying hosts and vectors of WNV are plentiful and widespread in raptor habitats, providing ample opportunity for WNV-induced reductions in raptor populations.

Our study has increased the understanding of WNV infections in raptors despite certain limitations. For example, all study birds originated from the wild and may have had pre-existing health conditions, including immunosuppression. Other factors related to captive life may also have influenced our results. In summary, we have shown that clinical disease in raptors is infrequent, yet subclinical pathology is considerable, including arteritis, which had not been previously reported for birds with WNV. Several Falconiform and Strigiform raptors are competent amplifying hosts, and because of shedding of large quantities of WNV, represent a threat to their handlers. The ability of some raptor species to be infected via the oral route likely increases the prevalence of infection in raptors. Presence of infectious WNV in organs of some raptors (up to 27 days) remains of unknown significance. Individual variation

in the ability to clear virus may be an important variable in how and why WNV appears to cause severe disease in some individuals and is effectively neutralized in others.

ACKNOWLEDGMENTS

The following rehabilitators made this work possible, and we sincerely thank them as well as their respective volunteers and staff members: G. Kratz and J. Scherpelz of the Rocky Mountain Raptor Program, L. Shimmel of the Cascades Raptor Center, S. Ueblacker of the Birds of Prey Foundation, N. Anderson and S. Heckly of the Lindsay Wildlife Museum, and B. Fitch of Raptor Recovery Nebraska. Additionally, we thank the following for their contributions: A. Price and J. Stoddart provided information regarding the golden eagles and allowed them to be part of the study. E. Edwards performed neutralization assays; K. Klenk, N. Panella, J. Velez, and S. Langevin provided valuable laboratory assistance; B. Podell and R. Zink of the Colorado State University Diagnostic Laboratory performed RT-PCR on eagle tissues and processed histopathology slides, respectively; R. Basaraba and K. Nelson performed initial necropsies; P. Gordy provided assistance in sampling birds; M. Bunning, T. Kloer, and P. Harrity gave valuable advice in the planning stages; S. Stephens, P. Oesterle, and A. Davis helped with preparation and husbandry; V. O'Brien and J. Liddell helped in providing food for the raptors; and N. Zeidner reviewed an early manuscript draft.

LITERATURE CITED

- AMERICAN ORNITHOLOGISTS' UNION. 2005. The A.O.U. Check-list of North American Birds, 7th Edition. www.aou.org/checklist/index.php3. Accessed March 9, 2005.
- ANDERSON, J. F., T. G. ANDREADIS, C. R. VOSSBRINCK, S. TIRRELL, E. M. WAKEM, R. A. FRENCH, A. E. GARMENDIA, AND H. J. VAN KRUIJNINGEN. 1999. Isolation of West Nile virus from mosquitoes, crows, and a Cooper's hawk in Connecticut. *Science* 286: 2331–2333.
- AUSTGEN, L. E., R. A. BOWEN, M. L. BUNNING, B. S. DAVIS, C. J. MITCHELL, AND G. J. CHANG. 2004. Experimental infection of cats and dogs with West Nile virus. *Emerging Infectious Diseases* 10: 82–86.
- BEATY, B. J., C. H. CALISHER, AND R. E. SHOPE. 1995. Arboviruses. In *Diagnostic procedures for viral, rickettsial, and chlamydial infections*, 7th Edition. E. H. Lennette, D. A. Lennette, and E. T.

- Lennette (eds.). American Public Health Association, Washington, D.C., pp. 189–212.
- BURT, F. J., A. A. GROBBELAAR, P. A. LEMAN, F. S. ANTHONY, G. V. GIBSON, AND R. SWANEPOEL. 2002. Phylogenetic relationships of southern African West Nile virus isolates. *Emerging Infectious Diseases* 8: 820–826.
- D'AGOSTINO, J. J., AND R. ISAZA. 2004. Clinical signs and results of specific diagnostic testing among captive birds housed at zoological institutions and infected with West Nile virus. *Journal of the American Veterinary Medical Association* 224: 1640–1643.
- IDSON, M., N. KOMAR, F. SORHAGE, R. NELSON, T. TALBOT, F. MOSTASHARI, R. MCLEAN, AND THE WEST NILE VIRUS AVIAN MORTALITY SURVEILLANCE GROUP. 2001. Crow deaths as a sentinel surveillance system for West Nile virus in the Northeastern United States, 1999. *Emerging Infectious Diseases* 7: 615–620.
- FAUCI, A. S. 1983. Vasculitis. *Journal of Allergy and Clinical Immunology* 72: 211–223.
- FITZGERALD, S. D., J. S. PATTERSON, M. KIUFEL, H. A. SIMMONS, S. D. GRIMES, C. F. SARVER, R. M. FULTON, B. A. STEFICEK, T. M. COOLEY, J. P. MASSEY, AND J. G. SIKARSKIE. 2003. Clinical and pathological features of West Nile virus infection in native North American owls (family Strigidae). *Avian Diseases* 47: 602–610.
- GANCZ, A. Y., I. K. BARKER, R. LINDSAY, A. DIBERNARDO, K. MCKEEVER, AND B. HUNTER. 2004. West Nile virus outbreak in North American owls, Ontario, 2002. *Emerging Infectious Diseases* 10: 2135–2142.
- GARMENDIA, A. E., H. J. VAN KRUININGEN, R. A. FRENCH, J. F. ANDERSON, T. G. ANDREADIS, A. KUMAR, AND B. WEST. 2000. Recovery and identification of West Nile virus from a hawk in winter. *Journal of Clinical Microbiology* 38: 3110–3111.
- HANSON, R. P. 1988. Koch is dead. *Journal of Wildlife Diseases* 24: 193–200.
- HEINZ-TAHENY, K. M., J. J. ANDREWS, M. J. KINSEL, A. P. PESSIER, M. E. PINKERTON, K. Y. LEMBERGER, R. J. NOVAK, G. J. DIZIKES, E. EDWARDS, AND N. KOMAR. 2004. West Nile virus infection in free-ranging squirrels in Illinois. *Journal of Veterinary Diagnostic Investigation* 16: 186–190.
- KLENK, K., J. SNOW, K. MORGAN, R. BOWEN, M. STEPHENS, F. FOSTER, P. GORDY, S. BECKETT, N. KOMAR, D. GUBLER, AND M. BUNNING. 2004. Alligators as West Nile virus amplifiers. *Emerging Infectious Diseases* 10: 2150–2155.
- KOMAR, N. 2003. West Nile virus: Epidemiology and ecology in North America. *Advanced Virus Research* 61: 185–234.
- , S. LANGEVIN, S. HINTEN, N. NEMETH, E. EDWARDS, D. HETTLER, B. DAVIS, R. BOWEN, AND M. BUNNING. 2003. Experimental infection of North American birds with the New York 1999 strain of West Nile virus. *Emerging Infectious Diseases* 9: 311–322.
- LANCIOTTI, R. S., A. J. KERST, R. S. NASCI, M. S. GODSEY, C. J. MITCHELL, H. M. SAVAGE, N. KOMAR, N. PANELLA, B. C. ALLEN, K. E. VOLPE, B. S. DAVIS, AND J. T. ROEHRIG. 2000. Rapid detection of West Nile virus from human clinical specimens, field-collected mosquitoes, and avian samples by a TaqMan reverse transcriptase-PCR assay. *Journal of Clinical Microbiology* 38: 4066–4071.
- LANTHIER, I., M. HEBERT, D. TREMBLAY, J. HAREL, A. D. DALLAIRE, AND C. GIRARD. 2004. Natural West Nile virus infection in a captive juvenile Arctic wolf (*Canis lupus*). *Journal of Veterinary Diagnostic Investigation* 16: 326–329.
- LUDWIG, G. V., P. P. CALLE, J. A. MANGIAFICO, B. L. RAPHAEL, D. D. DANNER, J. A. HILE, T. L. CLIPPINGER, J. F. SMITH, R. A. COOK, AND T. MCNAMARA. 2002. An outbreak of West Nile virus in a New York City captive wildlife population. *American Journal of Tropical Medicine and Hygiene* 67: 67–75.
- MILLER, D. L., M. J. MAUEL, C. BALDWIN, G. BURTLE, D. INGRAM, M. E. HINES II, AND K. S. FRAZIER. 2003. West Nile virus in farmed alligators. *Emerging Infectious Diseases* 9: 794–799.
- MONROE, B. L., AND C. G. SIBLEY. 1993. *A World checklist of birds*. Yale University Press, New Haven, Connecticut, 400 pp.
- SENNE, D. A., J. C. PEDERSEN, D. L. HUTTO, W. D. TAYLOR, B. J. SCHMITT, AND B. PANIGRAHY. 2000. Pathogenicity of West Nile virus in chickens. *Avian Diseases* 44: 642–649.
- STEELE, K. E., M. J. LINN, R. J. SCHOEPP, N. KOMAR, T. W. GEISBERT, R. M. MANDUCA, P. P. CALLE, B. L. RAPHAEL, T. L. CLIPPINGER, T. LARSEN, J. SMITH, R. S. LANCIOTTI, N. A. PANELLA, AND T. S. MCNAMARA. 2000. Pathology of fatal West Nile virus infections in native and exotic birds during the 1999 outbreak in New York City, New York. *Veterinary Pathology* 37: 208–224.
- SWAYNE, D. E., J. R. BECK, AND S. ZAKI. 2000. Pathogenicity of West Nile virus for turkeys. *Avian Diseases* 44: 932–937.
- TURELL, M. J., M. R. SARDELIS, M. L. O'GUINN, AND D. J. DOHM. 2002. Potential vectors of West Nile virus in North America. *Current Topics in Microbiology and Immunology* 267: 241–250.
- WORK, T. H., H. S. HURLBUT, AND R. M. TAYLOR. 1953. Isolation of West Nile virus from hooded crow and rock pigeon in the Nile Delta. *Proceedings of the Society for Experimental Biology and Medicine* 84: 719–721.
- WÜNSCHMANN, A., J. SHIVERS, J. BENDER, L. CARROLL, S. FULLER, M. SAGGESE, A. VAN WETTERE, AND P. REDIG. 2004. Pathologic findings in red-tailed hawks (*Buteo jamaicensis*) and Cooper's

hawks (*Accipiter cooperi*) naturally infected with West Nile virus. *Avian Diseases* 48: 570–580.

YANCY, K. B., AND T. J. LAWLEY. 1984. Circulating immune complexes: Their immunochemistry,

biology, and detection in selected dermatologic and systemic diseases. *Journal of the American Academy of Dermatology* 10: 711–734.

Received for publication 4 April 2005.