

Wasting and Neurologic Signs in a White-tailed Deer (*Odocoileus virginianus*) not Associated with Abnormal Prion Protein

Authors: Hamir, Amir N., Palmer, Mitchell V., and Kunkle, Robert A.

Source: Journal of Wildlife Diseases, 44(4) : 1045-1050

Published By: Wildlife Disease Association

URL: <https://doi.org/10.7589/0090-3558-44.4.1045>

BioOne Complete (complete.BioOne.org) is a full-text database of 200 subscribed and open-access titles in the biological, ecological, and environmental sciences published by nonprofit societies, associations, museums, institutions, and presses.

Your use of this PDF, the BioOne Complete website, and all posted and associated content indicates your acceptance of BioOne's Terms of Use, available at www.bioone.org/terms-of-use.

Usage of BioOne Complete content is strictly limited to personal, educational, and non - commercial use. Commercial inquiries or rights and permissions requests should be directed to the individual publisher as copyright holder.

BioOne sees sustainable scholarly publishing as an inherently collaborative enterprise connecting authors, nonprofit publishers, academic institutions, research libraries, and research funders in the common goal of maximizing access to critical research.

Wasting and Neurologic Signs in a White-tailed Deer (*Odocoileus virginianus*) not Associated with Abnormal Prion Protein

Amir N. Hamir,^{1,2} Mitchell V. Palmer,¹ and Robert A. Kunkle¹ ¹ National Animal Disease Center, ARS, USDA, 2300 Dayton Avenue, PO Box 70, Ames, Iowa 50010, USA; ² Corresponding author: (email: Amir.Hamir@ars.usda.gov)

ABSTRACT: A captive adult male white-tailed deer (*Odocoileus virginianus*) with wasting and neurologic signs similar to chronic wasting disease (CWD) was evaluated by histopathology, histochemistry, and immunohistochemistry (IHC) for disease-associated prion protein (PrP^d). On histologic examination, the brainstem had areas of vacuolation in neuropil and extensive multifocal mineralization of blood vessels with occasional occlusion of the lumen. Some of the clinical and pathologic features of this case were similar to the CWD of white-tailed deer. However, the tissues were negative for PrP^d by IHC. Because the lesions were more prominent in the obex region of the brainstem, it is speculated that this would have resulted in clinical signs similar to CWD in white-tailed deer. To our knowledge, neither cerebrovascular mineralization nor clinicopathologic changes resembling CWD have previously been described in white-tailed deer without the presence of PrP^d. Such a case should be considered in a differential diagnosis of CWD of white-tailed deer.

Key words: Cerebrovascular mineralization, neuronal vacuolation, white-tailed deer.

Chronic wasting disease (CWD) is a fatal, neurodegenerative transmissible spongiform encephalopathy (TSE) that has been identified in captive and free-ranging cervids (Williams, 2005). To our knowledge, neither nonprion-associated spongiform change nor mineralization of blood vessels in the brain has been previously reported in white-tailed deer (*Odocoileus virginianus*).

A 6.5-yr-old male white-tailed deer at the National Animal Disease Center (NADC) in Ames, Iowa was observed with weight loss and abnormal neurologic signs. The deer was from a herd in which CWD has not been detected for the past 15 yr. The deer had been purchased 3 yr earlier from a CWD-free deer farm in northwestern Wisconsin and was used for breeding purposes at the NADC.

For approximately 1 wk, the deer had been observed to be ataxic, with a wide-based stance, and had exhibited excessive salivation. Upon physical examination, the body temperature was within normal limits, the respiratory rate was increased, and the deer was noticeably thin and had several minor superficial abrasions–lacerations (fight wounds). Auscultation revealed abnormal respiratory sounds over the caudal dorsal lung field, with minimal to no respiratory sounds in the cranial ventral lung field. The deer was treated systemically with anti-inflammatory drugs and antibiotics and was separated from pen-mates for observation. Within 7 days of treatment, the deer was found in lateral recumbency, unable to rise, and was nonresponsive to treatment. Therefore, it was euthanized and a post-mortem examination was performed within 1 hr after euthanasia.

Upon gross examination, the deer was thin with minimal body fat. The rumen contained a normal amount of ingesta. There was a severe necropurulent pleuropneumonia with multifocal abscessation involving 75% of the lungs. The entire surface of the heart was covered by a thick layer of fibrinopurulent exudate. Within the oral cavity, there was a focally extensive necropurulent osteomyelitis of the right mandible. The upper right premolars and molars were missing. Bilaterally, the mandibular, parotid, and retropharyngeal lymph nodes were enlarged.

The whole brain and samples of lymph nodes, lung, liver, kidney, abomasum, intestines, and adrenal glands were immersion-fixed in 10% buffered formalin and submitted for histopathology. Because CWD was not suspected in this deer, fresh

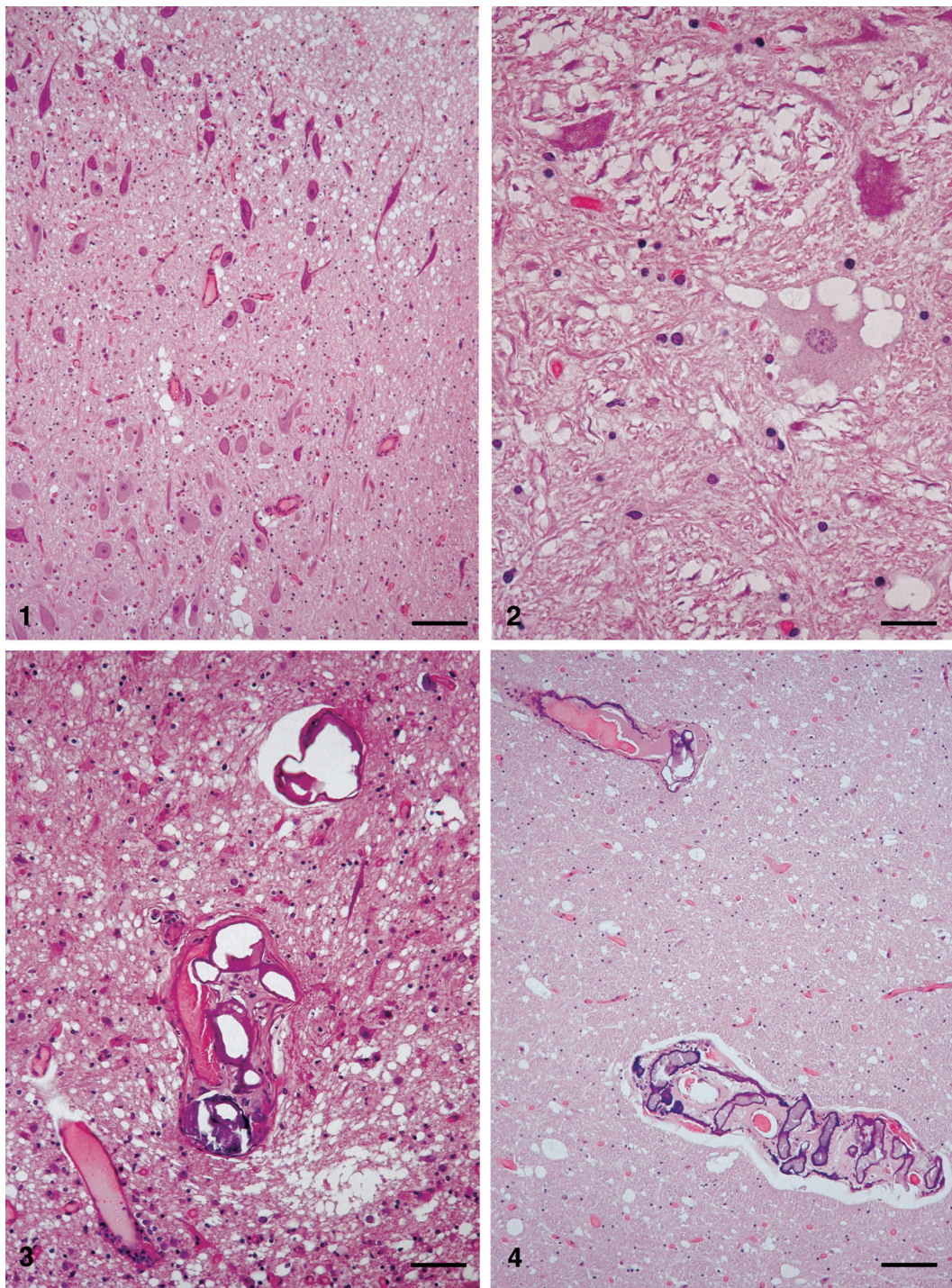


FIGURE 1. Photomicrograph of brainstem (obex) of white-tailed deer with wasting and neurologic signs. There is extensive vacuolation of neuropil. H&E stain. Bar=80 μ m. FIGURE 2. Photomicrograph of brainstem (obex) of white-tailed deer with wasting and neurologic signs. A neuron shows multiple clear vacuoles in the cytoplasm. H&E stain. Bar=20 μ m. FIGURE 3. Photomicrograph of brainstem (caudal to obex) of white-tailed deer with wasting and neurologic signs. Several blood vessels show multifocal and

tissues were not obtained. The tissues were processed for routine histopathology, embedded in paraffin wax, and sectioned at 5 μm . All sections were stained with hematoxylin and eosin. Sections of brain and lymph nodes were labeled by immunohistochemistry (IHC) for PrP^d using four different primary antibodies (a cocktail of 2 monoclonal antibodies [Mab] F89/160.5 and F99/97.6.1; Mab 6H4; Mab L42; and Mab 12F10). Past experience at the NADC has indicated that these antibodies would label PrP^d in various species of animals in which experimental TSEs have been reported (Cutlip et al., 1996; Hamir et al., 2005, 2006, 2007). Sections of the lung were also stained with Gram stain, and selected sections of the brain with suspected mineralized vessels were stained with von Kossa, Masson's trichrome, and Perl's iron for confirmation of mineralization, presence of fibrous connective tissue, and presence of iron, respectively.

Microscopically, significant lesions were confined to the sections of lung and brain. In the lung, there was a locally extensive area of necrosis with many large bacterial colonies. The necrotic central area was surrounded by a zone of extensive cellular debris and large numbers of neutrophils. Peripheral to this area, there were multifocal hemorrhages and thrombosed blood vessels. On Gram-stained sections, large numbers of intracellular and extracellular gram-positive, and lesser numbers of gram-negative, bacilli were seen.

In the brain, the most significant lesions were present in the dorsal obex area of the brainstem. The lesions consisted of extensive areas of vacuolation in the neuropil (Fig. 1). The vacuoles were usually circular, varied from a few micrometers up to

50 μm in diameter, and did not contain any stainable material. Occasional neurons had single or multiple vacuoles in the perikaryon (Fig. 2). Within areas of spongiosis, large numbers of glial cells appeared pyknotic. Examination of sections caudal to the obex showed multifocal and circumferential mineralization in the walls of medium-sized, thin-wall blood vessels (Fig. 3). The mineralization was confirmed by von Kossa stain. The affected vessels were dorsal to the central canal, were variably sized, and were present bilaterally. Some of the affected vessels were occluded and appeared to have been recanalized. There was moderately increased perivascular fibrous connective tissue (confirmed by Masson's trichrome stain) around the affected vessels (Fig. 3). Similar multifocal areas of mineralization of blood vessels, but with less severe vacuolation of neuropil, were also seen in cerebrum and bilaterally in superior colliculi, where a few mineralized blood vessels were seen (Fig. 4). In the cerebellum, some of the Purkinje cells contained a single large, clear vacuole in their cytoplasm. However, the blood vessels in this portion of the brain were normal. Perl's-stained sections were positive for iron in the walls of the mineralized blood vessels. All brain and lymph node tissue sections, examined by IHC using four different Mabs, were negative for PrP^d labeling.

In addition to examination of the brain in the above case, nine additional formalin-fixed brains of deer of various ages, from the same herd, were obtained for retrospective histopathologic examinations for the presence of cerebrovascular mineralization (Table 1). Four of these brains revealed vascular mineralization of medium-sized,

←

circumferential mineralizations. Vessels in the center of the field also show moderate perivascular fibrosis. H&E stain. Bar=50 μm . FIGURE 4. Photomicrograph of brain (superior colliculus) of white-tailed deer with wasting and neurologic signs. There is moderate vacuolation of neuropil and two multifocally mineralized blood vessels. H&E stain. Bar=80 μm .

TABLE 1. Results of retrospective histopathologic examination of brains of white-tailed deer (from the herd at the National Animal Disease Center, Ames, Iowa, USA) for the presence of vascular mineralizations (only positive cases are shown).

No.	Sex	Age (years)	Vascular mineralization					
			Cerebrum	Colliculus	Hippocampus	Cerebellum	Obex	C. cord ^a
1	F	10	+	+	—	—	—	—
2	F	9	—	+	—	+	—	+
3	F	7	—	+	—	—	—	—
4	F	0.5	—	—	—	—	+	—

^a Cervical spinal cord just caudal to the obex.

thin-wall blood vessels at various anatomic sites in the brain (Table 1). Similar to the clinical case, three were older (7, 9, and 10 yr) and one was younger (6.5 mo); all were females. One of the three had vascular mineralization near the obex region (Table 1). On examination of sections stained with Perl's, three deer brains with mineralized vessels had multifocal areas that were positive for iron.

Vascular mineralization in the brain of domestic animals is uncommon (Jubb et al., 1993). However, it is a common incidental finding in old horses, although it is not associated with observable clinical signs in affected horses (Jubb et al., 1993). Similarly, the four deer with cerebrovascular mineralization in the retrospective study had no abnormal neurologic signs. Therefore, finding of cerebrovascular mineralization in a white-tailed deer, with clinical findings of wasting and neurologic signs, was rather unusual. Also, the finding of focally extensive necrosuppurative pneumonia, with the presence of mixed bacterial flora, was suggestive of the aspiration pneumonia that has been documented in white-tailed deer with CWD (Williams, 2005). In CWD, the aspiration pneumonia is due to the presence of lesions in the obex region of the brainstem where the nucleus of the vagus nerve is located (Williams, 2005). Therefore, a similar pathogenesis could be attributed to the clinical deer described in this study.

The histologic characteristics of TSEs are spongiform change in neuropil and the presence of cytoplasmic vacuolation of

neurons (Hadlow, 1995). However, experimental transmission to cattle of sheep scrapie, and of CWD of mule deer and white-tailed deer, did not result in manifestation of spongiform lesions (Hamir et al., 2005, 2007). On the other hand, lesions of neuronal vacuolation may be present in conditions other than TSEs. For example, in animals, spongiform changes affecting the neuropil, as well as neuronal cell bodies, have been described in experimental as well as in natural cases of rabies in skunks (*Mephitis mephitis*), red foxes (*Vulpes vulpes*), and a heifer (*Bos Taurus*; cited by Hamir et al., 2001). Neuronal vacuolations have also been demonstrated in a variety of animals (Rottweiler pups, Angora goat kids, a neonatal calf, adult raccoons) with or without abnormal central nervous system signs (Field, 1952; Lancaster et al., 1987; Kortz et al., 1997; Hamir and Fischer, 1999). Isolated, clear vacuoles in neurons have also been seen as incidental findings in selected areas of the brain in normal cattle, sheep, and pigs, and in the dorsal root ganglia of rabbits (Zlotnik and Rennie, 1958; McGill and Wells, 1993; Ryder et al., 2000).

In the present case, spongiform change in the neuropil, as well as vacuolation of the neuronal perikarya, was seen in various anatomic locations in the brain (cerebrum, colliculi, brainstem, and proximal cervical spinal cord). Such findings are suggestive of CWD and other pathologic conditions. Identification of disease syndromes and morphologic lesions simi-

lar to those caused by TSEs is important in formulating a differential diagnosis for the disease. The latter would include chronic hemorrhagic disease (epizootic hemorrhagic disease), infestation by meningeal worm (*Parelaphstrongylus tenuis*), locoweed intoxication, encephalitis, and emaciation resulting from various infectious and nutritional causes (Williams, 2005).

In the presently described clinical case, although lesions resembled those seen in naturally occurring TSEs, neither the brain nor the lymphoid tissues of this deer were positive for PrP^d by IHC. In this deer, the mechanism for the formation of spongiform change appears to be unknown. It could be related, or be a sequel, to the mineralization and blockage of the vessels. On the other hand, it could also be that these two events may have occurred independently of each other.

Because in this case the confirmatory diagnostic test for PrP^d was negative, using multiple Mabs, it was concluded that this was not a case of TSE. As indicated previously, the IHC test used on this animal's tissues has enabled us to identify experimental animal TSEs at NADC (scrapie, CWD, and transmissible mink encephalitis) in various species (Cutlip et al., 1996; Hamir et al., 2005, 2006a,b, 2007). However, it may be argued by some that the monoclonal antibodies that were utilized in this case could create the possibility of being unable to diagnose a previously unknown TSE in this deer.

To our knowledge, nonprion-associated CNS vacuolation and mineralization of blood vessels in the brain has not been previously reported to induce CWD-like clinicopathologic findings in white-tailed deer. Therefore, such a case should be considered in a differential diagnosis of CWD of white-tailed deer.

The authors thank K. I. O'Rourke for providing the antibody for IHC and J. Fossi for the photomicrographs. M. Church, D. Orcutt, J. Lesan, S. Van Roekel, G. Montgomery, M. Fenneman, and the TSE animal caretakers provided expert technical

assistance. Mention of trade names or commercial products in this article is solely for the purpose of providing specific information and does not imply recommendation or endorsement by the US Department of Agriculture.

LITERATURE CITED

- CUTLIP, R. C., J. M. MILLER, R. E. RACE, A. L. JENNY, H. D. LEHMKUHL, AND M. M. ROBINSON. 1996. Bovine spongiform encephalopathy—The BSE dilemma, C. J. Gibbs (ed.). Springer-Verlag, New York, New York, pp. 92–96.
- FIELD, E. J. 1952. Vacuolated cells in the dorsal root ganglion of the rabbit. *Journal of Comparative Pathology* 62: 249–251.
- HADLOW, W. J. 1995. Neuropathology and the scrapie-kuru connection. *Brain Pathology* 5: 27–31.
- HAMIR, A. N., AND K. A. FISCHER. 1999. Neuronal vacuolations in raccoons from Oregon. *Journal of Veterinary Diagnostic Investigation* 11: 303–307.
- , P. HABECKER, A. JENNY, D. HUTTO, M. J. STACK, M. J. CHAPLIN, AND J. STASKO. 2001. Idiopathic disseminated intracytoplasmic neuronal vacuolation in a neonatal Holstein calf born in USA. *Journal of Veterinary Diagnostic Investigation* 13: 349–351.
- , R. A. KUNKLE, R. C. CUTLIP, J. M. MILLER, K. I. O'ROURKE, E. S. WILLIAMS, M. W. MILLER, M. J. STACK, M. J. CHAPLIN, AND J. A. RICHT. 2005. Experimental transmission of chronic wasting disease agent to cattle by intracerebral route. *Journal of Veterinary Diagnostic Investigation* 17: 276–281.
- , J. M. MILLER, J. C. BARTZ, AND J. A. RICHT. 2006a. First and second cattle passage of transmissible mink encephalopathy by intracerebral inoculation. *Veterinary Pathology* 43: 118–126.
- , R. C. CUTLIP, J. M. MILLER, E. S. WILLIAMS, AND J. A. RICHT. 2006b. Transmission of chronic wasting disease of mule deer to Suffolk sheep following intracerebral inoculation. *Journal of Veterinary Diagnostic Investigation* 18: 558–565.
- , J. M. MILLER, R. A. KUNKLE, S. M. HALL, AND J. A. RICHT. 2007. Susceptibility of cattle to inoculation with chronic wasting disease from white-tailed deer. *Veterinary Pathology* 44: 487–493.
- JUBB, K. V. F., AND C. R. HUXTABLE. 1993. The nervous system. Jubb, Kennedy & Palmer's pathology of domestic animals, Vol. 1. 4th Edition. Academic Press, San Diego, California, pp. 267–439.
- KORTZ, G. D., W. A. MEIER, R. J. HIGGINS, R. A. FRENCH, B. C. MCKIERNAN, R. FATZER, AND J. F.

- ZACHARY. 1997. Neuronal vacuolation and spinocerebellar degeneration in young Rottweiler dogs. *Veterinary Pathology* 34: 296–302.
- LANCASTER, M. J., I. J. GILL, AND P. T. HOOPER. 1987. Progressive paresis in Angora goats. *Australian Veterinary Journal* 64: 123–124.
- MCGILL, I. S., AND G. A. H. WELLS. 1993. Neuropathological findings in cattle with clinically suspect but unconfirmed bovine spongiform encephalopathy. *Journal of Comparative Pathology* 108: 241–260.
- RYDER, S. J., S. A. C. HAWKINS, M. DAWSON, AND G. A. H. WELLS. 2000. The neuropathology of experimental bovine spongiform encephalopathy in the pig. *Journal of Comparative Pathology* 122: 131–143.
- WILLIAMS, E. S. 2005. Chronic wasting disease. *Veterinary Pathology* 42: 530–549.
- ZLOTNIK, I., AND J. C. RENNIE. 1958. A comparative study of the incidence of vacuolated neurons in the medulla from apparently healthy sheep of various breeds. *Journal of Comparative Pathology* 68: 411–415.

Received for publication 11 February 2008.