

Percutaneous ultrasound-guided ethanol ablation for treatment of primary hyperparathyroidism in a cat

Authors: Riehl, Valentina, Hartmann, Antje, Rohrberg, Antje, and Neiger, Reto

Source: Journal of Feline Medicine and Surgery Open Reports, 5(2)

Published By: SAGE Publishing

URL: <https://doi.org/10.1177/2055116919860276>

The BioOne Digital Library (<https://bioone.org/>) provides worldwide distribution for more than 580 journals and eBooks from BioOne's community of over 150 nonprofit societies, research institutions, and university presses in the biological, ecological, and environmental sciences. The BioOne Digital Library encompasses the flagship aggregation BioOne Complete (<https://bioone.org/subscribe>), the BioOne Complete Archive (<https://bioone.org/archive>), and the BioOne eBooks program offerings ESA eBook Collection (<https://bioone.org/esa-ebooks>) and CSIRO Publishing BioSelect Collection (<https://bioone.org/csiro-ebooks>).

Your use of this PDF, the BioOne Digital Library, and all posted and associated content indicates your acceptance of BioOne's Terms of Use, available at www.bioone.org/terms-of-use.

Usage of BioOne Digital Library content is strictly limited to personal, educational, and non-commercial use. Commercial inquiries or rights and permissions requests should be directed to the individual publisher as copyright holder.

BioOne is an innovative nonprofit that sees sustainable scholarly publishing as an inherently collaborative enterprise connecting authors, nonprofit publishers, academic institutions, research libraries, and research funders in the common goal of maximizing access to critical research.



Percutaneous ultrasound-guided ethanol ablation for treatment of primary hyperparathyroidism in a cat

Valentina Riehl, Antje Hartmann, Antje Rohrberg and Reto Neiger

Journal of Feline Medicine and Surgery Open Reports
1–6

© The Author(s) 2019

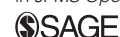Article reuse guidelines:

sagepub.com/journals-permissions

DOI: 10.1177/2055116919860276

journals.sagepub.com/home/jfmsopenreports

This paper was handled and processed by the European Editorial Office (ISFM) for publication in *JFMS Open Reports*



Abstract

Case summary A 9-year-old male neutered European Shorthair cat was presented owing to vomiting and mild weight loss. Clinical examination was normal, but biochemistry results showed increased concentrations of total calcium (4.05 mmol/l; reference interval [RI] 2.20–2.90 mmol/l) and ionised calcium (iCa) (2.19 mmol/l; RI 1.12–1.40 mmol/l), as well as hypophosphataemia (2.5 mg/dl; RI 3.1–7.5 mg/dl). Parathyroid hormone (PTH) concentration (>1000 pg/ml) was markedly increased, while parathyroid hormone-related protein concentration (<0.8 pmol/l) was normal. Neck ultrasound showed a large left parathyroid mass (13 × 7 × 6 mm). Under general anaesthesia and with ultrasonographic guidance, a fine-needle aspiration of the mass followed by chemical ablation with 2 ml 96% ethanol was performed. The cat was re-evaluated and iCa concentration measured 24 h, 72 h, 5 days, 4 weeks and 4 months post-ablation. Normocalcaemia was reached within 24 h, remained stable throughout the whole evaluation period and the concentration of PTH normalised 4 months later. Vomiting stopped promptly after chemical ablation and a slight change in voice, as well as a mild prolapse of the nictitating membrane, were the only side effects after the treatment but resolved some weeks later.

Relevance and novel information To our knowledge, this is the first report of successful chemical ablation of a parathyroid mass in a cat with primary hyperparathyroidism. Chemical ablation might therefore be a possible alternative to parathyroidectomy in cats.

Keywords: Hypercalcaemia; endocrine; PHPT; parathyroid

Accepted: 5 June 2019

Introduction

Primary hyperparathyroidism in cats, which causes autonomous secretion of parathyroid hormone (PTH), is commonly due to a parathyroid adenoma, rarely due to an adenomatous hyperplasia and only a few parathyroid carcinomas have been reported. It leads to a massive increase of total and ionised calcium concentrations.^{1–4} In contrast to secondary hyperparathyroidism, primary hyperparathyroidism uncommonly affects cats, compared with dogs.⁵ In dogs there are various treatment options for primary hyperparathyroidism, including surgical parathyroidectomy, heat ablation or chemical ablation.^{1,3,6,7} To our knowledge, no chemical ablation of a primary hyperparathyroidism in a cat has been described so far.

Case description

A 9-year-old male neutered European Shorthair cat with a body weight of 4.8 kg and a body condition score of 6/9 was presented to the referring veterinarian owing to acute vomiting and a subjectively perceived mild weight loss. A blood examination by the referring veterinarian revealed a markedly increased concentration of total calcium (tCa) (15 mg/dl; reference interval [RI] 7.8–11.3 mg/dl), as

Veterinary Clinic Hofheim, Hofheim am Taunus, Germany

Corresponding author:

Valentina Riehl Veterinary Clinic Hofheim, Katharina-Kemmler Straße 7, 65719 Hofheim am Taunus, Germany
Email: valentina_riehl@web.de



Creative Commons Non Commercial CC BY-NC: This article is distributed under the terms of the Creative Commons

Attribution-NonCommercial 4.0 License (<http://www.creativecommons.org/licenses/by-nc/4.0/>) which permits non-commercial use, reproduction and distribution of the work without further permission provided the original work is attributed as specified on the SAGE and Open Access pages (<https://us.sagepub.com/en-us/nam/open-access-at-sage>).

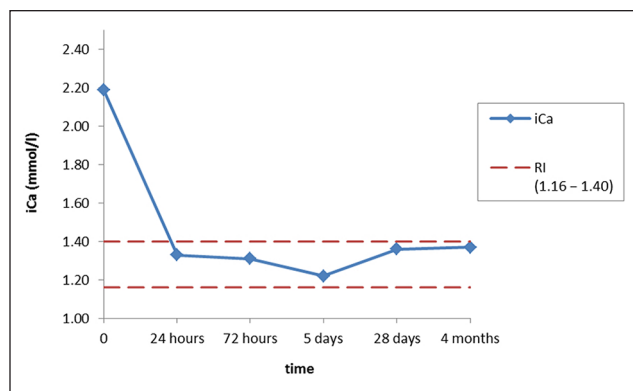


Figure 1 Concentration of ionised calcium (iCa) over time with a reference interval (RI) of 1.16–1.40 mmol/l

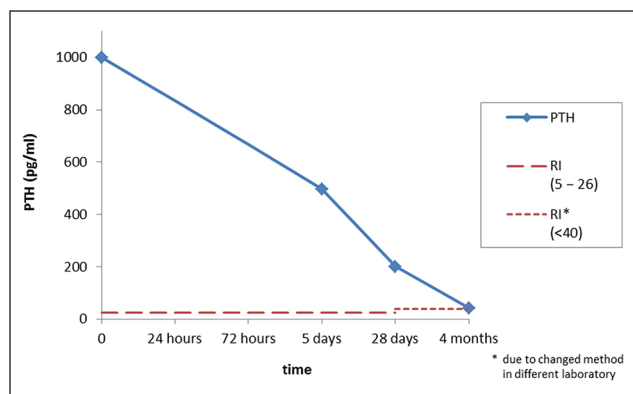


Figure 2 Concentration of parathyroid hormone (PTH) over time. RI = reference interval

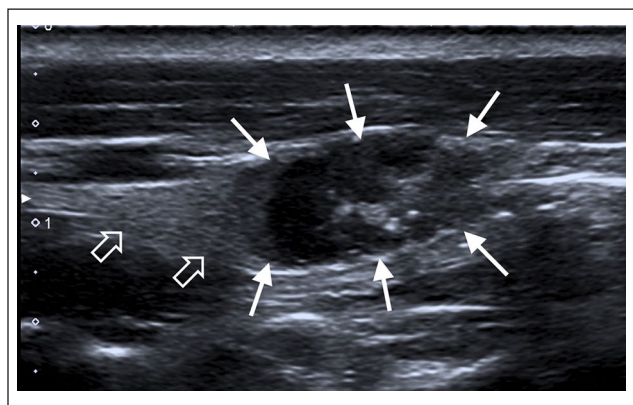


Figure 3 Ultrasonographic images of the parathyroid mass (solid arrows) localised within the left thyroid gland in a longitudinal view. Part of the thyroid tissue is visible cranial to the mass (open arrows)

well as a mild hypophosphataemia (2.5 mg/dl; RI 3.1–7.5 mg/dl). Haematology and the remaining biochemistry

results showed no relevant abnormalities (mild hyperglycaemia attributed to stress and a mild hyperglobulinaemia of 5.4 g/dl [RI 2.8–5.1 g/dl]). The cat was referred for further investigation of hypercalcaemia.

Physical examination 12 days later showed no abnormal findings and no cervical mass was palpable. A complete blood count was repeated, which showed normal values. Ionised calcium (iCa) concentration measured on site with a hand-held device (i-STAT; Abbott) showed an increased concentration of 2.19 mmol/l (RI 1.16–1.40 mmol/l) (Figure 1).⁸ Biochemistry profile confirmed markedly increased tCa concentration (4.05 mmol/l; RI 2.20–2.90 mmol/l) and hypophosphataemia (2.6 mg/dl; RI 3.4–5.3 mg/dl). Plasma for PTH and parathyroid hormone-related protein (PTHrP) measurement was sent to an external laboratory (Alomed, Radolfzell, Germany) to investigate the cause of hypercalcaemia. Possible differential diagnoses for markedly increased concentrations of tCa and iCa combined with hypophosphataemia were hyperparathyroidism, hypercalcaemia of malignancy and idiopathic hypercalcaemia. Markedly increased PTH concentration >1000 pg/ml (Figure 2) and normal PTHrP concentration <0.5 pmol/l (RI <0.8 pmol/l) was consistent with primary hyperparathyroidism in this cat.

Two days later, a cervical ultrasound was performed under intravenous propofol (Narcofol; CP Pharma) anaesthesia to look for a possible parathyroid mass. At this time, the owner reported polydipsia and polyuria over the past couple of days. The cat was positioned in dorsal recumbency and the region of the thyroid and parathyroid glands was clipped. Ultrasonographic examination was performed by a board-certified radiologist (AH) with an 18 MHz linear transducer (Toshiba applio400). Within the left thyroid gland a heterogeneous mass (size: 13 × 7 × 6 mm) with a mixed echogenicity was visible. The mass showed areas containing corpuscular fluid, as well as solid hypoechoic areas. Location of the mass was compatible with the caudal left parathyroid gland (Figures 3 and 4).

The region was surgically prepared and an ultrasound-guided fine-needle aspiration of the mass was obtained with a 22 G needle. Afterwards, the amount of ethanol needed for chemical ablation of the mass was calculated based on earlier studies in dogs, where half of the mass volume was set to be the target amount of ethanol.³ Calculation led to a target amount of 2 ml of 96% ethanol, which was administered under ultrasound guidance, observing dissemination within the mass, with a 22 G needle attached to a 2 ml syringe. The ultrasonographic appearance of the gland and dissemination of fluid was recorded and a good blanching was ultra sonographically visible (Figure 5). Owing to the high volume of ethanol, 0.23 ml (0.015 mg/kg IV) of buprenorphine (Buprenodale Multidose; Dechra) was

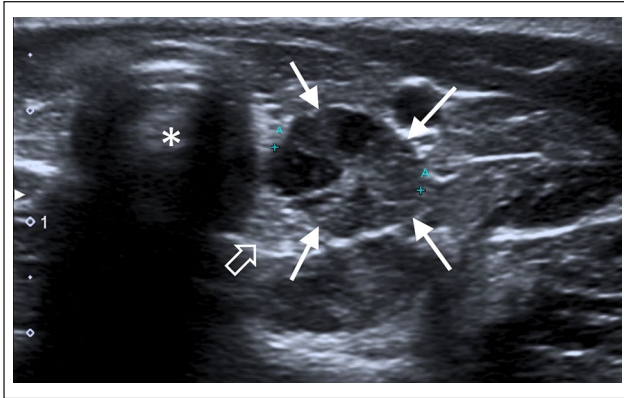


Figure 4 Ultrasonographic image of the parathyroid mass in a transverse view. The image shows the left thyroid gland (open arrow) and the parathyroid mass (solid arrows) to the right of the trachea (*). Note the mixed echogenicity with areas containing corpuscular fluid and solid hypoechoic areas

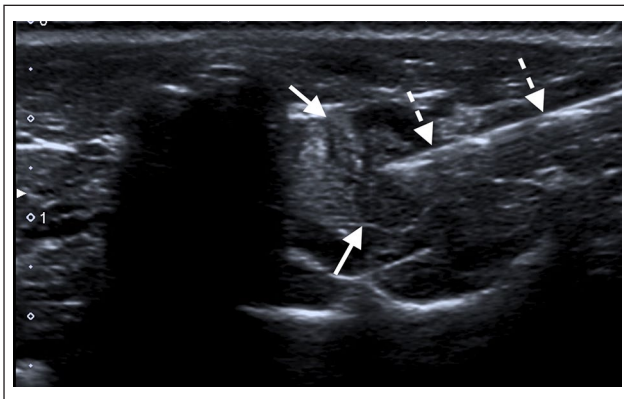


Figure 5 Transverse ultrasonographic image showing the needle (broken arrows) in the parathyroid mass (solid arrows) for ethanol ablation

injected intravenously as an analgesic. The cat was allowed to recover from anaesthesia immediately afterwards.

Cytology showed neuroendocrine tissue but could not differentiate between benign or malignant tissue.

Approximately 24 h and 72 h, as well as 5 days, 4 weeks and 4 months, after ethanol injection, the cat was re-examined and iCa concentration was measured. Furthermore, the owner was told to present the cat immediately should any clinical sign of hypocalcaemia occur, such as tetany, facial rubbing (pruritus), seizures or weakness. By 24 h after chemical ablation the iCa concentration was within the RI (Figure 1). The owner reported normal general demeanour, no polyuria or polydipsia, and the cat was clinically normal and vomiting stopped. Similar findings were seen 72 h and 5 days after chemical ablation, except that there was a mild voice change and a mild prolapse of the nictitating membrane 4 days after

the injection. Repeated measurements of PTH concentration were performed 5 days, 4 weeks and 4 months after the ablation (Figure 2), which showed a gradual decrease of the hormone almost into the RI. Four weeks after chemical ablation, the cat still had a mild prolapse of the nictitating membrane and the voice change persisted, but both findings were no longer present at the re-examination at 4 months. PTH concentration was measured in a different laboratory (Cambridge Specialist Laboratories, UK) at the final re-examination due to a change in techniques in the initial laboratory reporting a slightly different RI (<40 pg/ml). Body weight 4 weeks and 4 months after ablation was 4.6 kg and 5.4 kg, respectively.

Discussion

Chemical ablation of a parathyroid or thyroid mass is used in humans when surgery and general anaesthesia are high-risk procedures.⁹ There are several studies of chemical ablation of parathyroid masses in dogs with primary hyperparathyroidism mentioning varying success rates. In the first report in 7/8 dogs, ablation was successful after one procedure, whereas the other dog needed two procedures. Physiological PTH concentration was reached within 24 h in seven dogs and within 5 days in the remaining dog. However, 5/8 dogs developed temporary hypocalcaemia within the first 5 days, with one dog having clinical signs and requiring treatment.³ Chemical ablation was used in five dogs in another study of primary hyperparathyroidism, one having two procedures. Two dogs showed a reduction in iCa concentration following the procedure, and it never returned to within normal limits. The three other dogs that underwent chemical ablation showed no reduction in the tCa concentration.¹⁰ Chemical ablation was successful in 13/18 procedures, although heat ablation and surgical treatment of the parathyroid mass was preferred owing to a more reliable outcome.¹ Finally, 24 dogs that primary hyperparathyroidism that underwent 27 procedures showed success in 23 of these procedures.¹¹

To our knowledge this is the first report of a chemical ablation of the parathyroid gland in a cat. Chemical ablation has been described in hyperthyroid cats as an alternative treatment option. While chemical ablation led to normal thyroxine concentrations in 4/4 cats with an unilateral mass during an observation period of 12 months,¹² ablation in cats with bilateral nodules resulted in euthyroidism lasting only 2–27 weeks and cannot be recommended.¹³ Chemical ablation currently is the standard treatment of primary hyperparathyroidism in dogs in our veterinary clinic and with the cat already under general anaesthesia for ultrasonographic examination of the parathyroid glands, we decided together with the owners that chemical ablation should be tried with such a large parathyroid mass present.

The cat reported here showed mild and non-specific clinical signs before presentation to the referring veterinarian and hypercalcaemia was detected incidentally. Typical signs in dogs with hypercalcaemia are polyuria and polydipsia but they are uncommon in cats.¹⁴ Polyuria and polydipsia were only mentioned later in the course of disease in the cat reported here. Furthermore, no cervical mass was palpable in our cat. In contrast to reported clinical examination findings of other hyperparathyroid cats in which a palpable cervical mass was found,^{5,15,16} this is uncommon in dogs.¹⁷

Side effects of chemical ablation in the cat were limited to a slight change of voice for 6 weeks and a mild prolapse of the nictitating membrane until 10 weeks after chemical ablation. These side effects can be reasoned with transient nerve damage due to leakage of ethanol and have been reported in dogs.^{3,6}

In the cat reported here, iCa returned to within the RI within 24 h. Normocalcaemia within 72 h was found in 22/23 successful procedures of ethanol injection in functional parathyroid nodules in dogs.¹¹ Twenty of them showed normocalcaemia within 48 h, two resolved by day 3 and the last dog needed 3 weeks until normocalcaemia was reached. Our cat is comparable to eight dogs treated with chemical ablation, where physiological concentrations of calcium were measured in seven dogs within 24 h and just one dog needed 5 days to resolve hypercalcaemia.³ Finally, in 12/15 dogs that underwent a single chemical ablation procedure, hypercalcaemia resolved within 1–4 days (mean 1.9 ± 1.4 days).¹

In dogs, the time to reach normocalcaemia is similar after chemical ablation or parathyroidectomy. Normocalcaemia was reached after a median time of 36 h (range 24 h–6 days) in 17/19 dogs after parathyroidectomy; no information is available for the two remaining dogs.¹⁰ Parathyroidectomy resulted in calcium concentrations within the RI in 50 dogs after 16–24 h.⁴ Finally, hypercalcaemia resolved in 44/47 dogs undergoing surgery within 1–6 days (mean 1.6 ± 1.1 days). Normocalcaemia was reached within 48 h in 29 of these dogs, in 3–4 days in 13 dogs and in 4–6 days in the remaining two dogs.¹

In cats, little information is available at which time after parathyroidectomy they become normocalcaemic. In two cats with parathyroid adenoma undergoing parathyroidectomy, calcium concentration within the RI was found within 2 days in one cat, while the other developed a clinical irrelevant hypocalcaemia.¹⁵ Parathyroidectomy in a cat with a parathyroid carcinoma and an increase of both tCa and iCa before intervention resulted in a mild decline of tCa but still apparent hypercalcaemia the day after intervention. Five days postoperatively a nadir within the RI of tCa was measured, whereas the concentration of iCa was below the RI (0.95 mmol/l, RI 1.13–1.38 mmol/l). iCa

concentration normalised within 24 days after surgery and no supplementation was given.¹⁶

Differentiation between an adenoma and carcinoma was not possible based on the cytological samples. This is not surprising as even histologically, differentiation between benign and malignant parathyroid masses is difficult.^{4,18}

Plasma PTH concentration in the cat presented here was markedly increased, being above the assay's upper detection level of 1000 pg/ml (RI 5–26 pg/ml). Up to 75% of dogs suffering from primary hyperparathyroidism have a PTH concentration within the RI before any treatment.^{3,11,19} In cats, there is a lack of data regarding PTH concentrations before and after therapy. Only preoperative PTH concentrations are available in 2/7 hyperparathyroid cats; one had a PTH concentration of 8 pmol/l and the other 19.5 pmol/l (RI 2–13 pmol/l).⁵ In 3/4 cats with primary hyperparathyroidism PTH concentrations were within the RI in another report, whereas the concentration of the fourth cat was not determined.¹⁴ In contrast to this, and similar to the case reported here, Faucher et al reported a PTH concentration of 868 pg/ml (RI <40 pg/ml) in a hyperparathyroid cat with a parathyroid carcinoma.¹⁶

Whenever data are available, the decline of PTH concentration after treatment is prompt. Parathyroidectomy in dogs resulted in a median decline of 84.9% of PTH 10 mins post-procedure.² Chemical ablation resulted in a decrease to within or below the RI within 24 h in 7/8 dogs.³ Unfortunately, most studies do not report on PTH follow-up concentrations in cats post-procedure. Only one cat showed normalisation of PTH concentration post-parathyroidectomy, but the details are not mentioned.⁵ The time until normalisation of PTH concentration is rather long in the cat presented here. The reason for this long duration is currently unknown.

In humans, up to 40% of the patients have a persistently elevated PTH concentrations despite normocalcaemia after parathyroidectomy.^{20–24} There are several hypotheses for this unusual pathogenesis. Bone remineralisation could be the reason for increased PTH secretion, in order to maintain normal iCa concentration.^{21,25} A vitamin D deficiency might play a role,²⁶ but no abnormal vitamin D concentration was seen in 19/76 patients who underwent parathyroidectomy due to a single adenoma and had postoperatively elevated PTH concentrations.²⁰ Further hypotheses are a decreased peripheral sensitivity to PTH,²⁷ or a residual hyperfunctioning parathyroid tissue.²² While a definitive mechanisms for persistently high postoperative PTH concentrations are unclear, in humans an increased preoperative PTH concentration serves as a predictor for persistently high postoperative PTH concentration.²⁰ Overall, postoperatively elevated PTH concentrations

are commonly transient in humans and resolve within 5 months of parathyroidectomy.²¹

Conclusions

To our knowledge, this is the first report of ultrasound-guided chemical ablation of a parathyroid mass in a cat with primary hyperparathyroidism. Although implementation requires a lot of ultrasonographic experience, findings of the current case report indicate that chemical ablation for the treatment of primary hyperparathyroidism in a cat stands as a worthy alternative to the more invasive parathyroidectomy.

Conflict of interest The authors declared no potential conflicts of interest with respect to the research, authorship, and/or publication of this article.

Funding The authors received no financial support for the research, authorship, and/or publication of this article.

Ethical approval This work involved the use of client-owned animal(s) only, and followed established internationally recognised high standards ('best practice') of individual veterinary clinical patient care. Ethical approval from a committee was not therefore needed.

Informed consent Informed consent (either verbal or written) was obtained from the owner or legal custodian of all animal(s) described in this work for the procedure(s) undertaken. No animals or humans are identifiable within this publication, and therefore additional informed consent for publication was not required.

References

- Rasor L, Pollard R and Feldman EC. **Retrospective evaluation of three treatment methods for primary hyperparathyroidism in dogs.** *J Am Anim Hosp Assoc* 2007; 43: 70–77.
- Graham KJ, Wilkinson M, Culvenor J, et al. **Intraoperative parathyroid hormone concentration to confirm removal of hypersecretory parathyroid tissue and time to postoperative normocalcaemia in nine dogs with primary hyperparathyroidism.** *Aust Vet J* 2012; 90: 203–209.
- Long CD, Goldstein RE, Hornof WJ, et al. **Percutaneous ultrasound-guided chemical parathyroid ablation for treatment of primary hyperparathyroidism in dogs.** *J Am Vet Med Assoc* 1999; 215: 217–221.
- Milovancev M and Schmiedt CW. **Preoperative factors associated with postoperative hypocalcemia in dogs with primary hyperparathyroidism that underwent parathyroidectomy: 62 cases (2004–2009).** *J Am Vet Med Assoc* 2013; 242: 507–515.
- Kallet AJ, Richter KP, Feldman EC, et al. **Primary hyperparathyroidism in cats: seven cases (1984–1989).** *J Am Vet Med Assoc* 1991; 199: 1767–1771.
- Pollard RE, Long CD, Nelson RW, et al. **Percutaneous ultrasonographically guided radiofrequency heat ablation for treatment of primary hyperparathyroidism in dogs.** *J Am Vet Med Assoc* 2001; 218: 1106–1110.
- Bucy D, Pollard R and Nelson R. **Analysis of factors affecting outcome of ultrasound-guided radiofrequency heat ablation for treatment of primary hyperparathyroidism in dogs.** *Vet Radiol Ultrasound* 2017; 58: 83–89.
- Elliott J, Syme HM, Reubens E, et al. **Assessment of acid-base status of cats with naturally occurring chronic renal failure.** *J Small Anim Pract* 2003; 44: 65–70.
- Monzani F, Caraccio N, Goletti O, et al. **Five-year follow-up of percutaneous ethanol injection for the treatment of hyperfunctioning thyroid nodules: a study of 117 patients.** *Clin Endocrinol* 1997; 46: 9–15.
- Gear RNA, Neiger R, Skelly BJS, et al. **Primary hyperparathyroidism in 29 dogs: diagnosis, treatment, outcome and associated renal failure.** *J Small Anim Pract* 2005; 46: 10–16.
- Guttin T, van Knox W and Diroff JS. **Outcomes for dogs with primary hyperparathyroidism following treatment with percutaneous ultrasound-guided ethanol ablation of presumed functional parathyroid nodules: 27 cases (2008–2011).** *J Am Vet Med Assoc* 2015; 247: 771–777.
- Goldstein RE, Long C, Swift NC, et al. **Percutaneous ethanol injection for treatment of unilateral hyperplastic thyroid nodules in cats.** *J Am Vet Med Assoc* 2001; 218: 1298–1302.
- Wells AL, Long CD, Hornof WJ, et al. **Use of percutaneous ethanol injection for treatment of bilateral hyperplastic thyroid nodules in cats.** *J Am Vet Med Assoc* 2001; 218: 1293–1297.
- Savary KC, Price GS and Vaden SL. **Hypercalcemia in cats: a retrospective study of 71 cases (1991–1997).** *J Vet Intern Med* 2000; 14: 184–189.
- den Hertog E, Goossens MM, van der Linde-Sipman JS, et al. **Primary hyperparathyroidism in two cats.** *Vet Q* 1997; 19: 81–84.
- Faucher MR, Freiche V, Bongrand Y, et al. **Primary hyperparathyroidism caused by a parathyroid carcinoma in a 16-year-old male neutered cat with concurrent chronic kidney disease.** *Vet Q* 2014; 34: 37–40.
- Sawyer ES, Northrup NC, Schmiedt CW, et al. **Outcome of 19 dogs with parathyroid carcinoma after surgical excision.** *Vet Comp Oncol* 2012; 10: 57–64.
- Sakals SA, Gillick MS, Kerr ME, et al. **Diagnosing the etiology of hypercalcemia in a dog.** *Vet Pathol* 2010; 47: 579–581.
- Feldman EC, Hoar B, Pollard R, et al. **Pretreatment clinical and laboratory findings in dogs with primary hyperparathyroidism: 210 cases (1987–2004).** *J Am Vet Med Assoc* 2005; 227: 756–761.
- Mizrachi A, Gilat H, Bachar G, et al. **Elevated parathyroid hormone levels after parathyroidectomy for primary hyperparathyroidism.** *Head Neck* 2009; 31: 1456–1460.
- Mittendorf EA and McHenry CR. **Persistent parathyroid hormone elevation following curative parathyroidectomy for primary hyperparathyroidism.** *Arch Otolaryngol Head Neck Surg* 2002; 128: 275–279.
- Wang TS, Ostrower ST and Heller KS. **Persistently elevated parathyroid hormone levels after parathyroid surgery.** *Surgery* 2005; 138: 1130–1135.
- Ning L, Sippel R, Schaefer S, et al. **What is the clinical significance of an elevated parathyroid hormone level after curative surgery for primary hyperparathyroidism?** *Ann Surg* 2009; 249: 469–472.

- 24 Lang BH-H, Wong IY-H, Wong KP, et al. **Eucalcemic parathyroid hormone elevation after parathyroidectomy for primary sporadic hyperparathyroidism: risk factors, trend, and outcome.** *Ann Surg Oncol* 2012; 19: 584–590.
- 25 Westerdahl J, Valdemarsson S, Lindblom P, et al. **Postoperative elevated serum levels of intact parathyroid hormone after surgery for parathyroid adenoma: sign of bone remineralization and decreased calcium absorption.** *World J Surg* 2000; 24: 1323–1329.
- 26 Denizot A, Pucini M, Chagnaud C, et al. **Normocalcemia with elevated parathyroid hormone levels after surgical treatment of primary hyperparathyroidism.** *Am J Surg* 2001; 182: 15–19.
- 27 Nordenström E, Westerdahl J, Isaksson A, et al. **Patients with elevated serum parathyroid hormone levels after parathyroidectomy: showing signs of decreased peripheral parathyroid hormone sensitivity.** *World J Surg* 2003; 27: 212–215.