

Ununited accessory caudal glenoid ossification centre and associated joint mouse as a cause of lameness in a cat

Authors: Serck, Boris MA, and Wouters, Erik EG

Source: Journal of Feline Medicine and Surgery Open Reports, 5(2)

Published By: SAGE Publishing

URL: <https://doi.org/10.1177/2055116919879255>

The BioOne Digital Library (<https://bioone.org/>) provides worldwide distribution for more than 580 journals and eBooks from BioOne's community of over 150 nonprofit societies, research institutions, and university presses in the biological, ecological, and environmental sciences. The BioOne Digital Library encompasses the flagship aggregation BioOne Complete (<https://bioone.org/subscribe>), the BioOne Complete Archive (<https://bioone.org/archive>), and the BioOne eBooks program offerings ESA eBook Collection (<https://bioone.org/esa-ebooks>) and CSIRO Publishing BioSelect Collection (<https://bioone.org/csiro-ebooks>).

Your use of this PDF, the BioOne Digital Library, and all posted and associated content indicates your acceptance of BioOne's Terms of Use, available at www.bioone.org/terms-of-use.

Usage of BioOne Digital Library content is strictly limited to personal, educational, and non-commercial use. Commercial inquiries or rights and permissions requests should be directed to the individual publisher as copyright holder.

BioOne is an innovative nonprofit that sees sustainable scholarly publishing as an inherently collaborative enterprise connecting authors, nonprofit publishers, academic institutions, research libraries, and research funders in the common goal of maximizing access to critical research.



Ununited accessory caudal glenoid ossification centre and associated joint mouse as a cause of lameness in a cat

Journal of Feline Medicine and Surgery Open Reports
1–4

© The Author(s) 2019

Article reuse guidelines:

sagepub.com/journals-permissions

DOI: 10.1177/2055116919879255

journals.sagepub.com/home/jfmsopenreports

This paper was handled and processed by the European Editorial Office (ISFM) for publication in *JFMS Open Reports*



Boris MA Serck and Erik EG Wouters

Abstract

Case summary A 16-year-old neutered female domestic shorthair cat was evaluated for chronic lameness of the right thoracic limb. On clinical examination, pain was localised to the right glenohumeral joint. Radiography and arthrography of the right glenohumeral joint revealed an ununited accessory caudal glenoid ossification centre, abbreviated here to ununited caudal glenoid (UCG), and a joint mouse. The UCG and attached joint mouse were removed via arthroscopy and this resulted in complete resolution of the clinical signs. The cat was euthanased 3 years later, for an unrelated cause, having shown no recurrence of lameness.

Relevance and novel information UCG should be considered as a differential diagnosis for cats with lameness of the thoracic limb. The clinical implications of a UCG have been described in dogs, but to our knowledge have not yet been described in cats. Excision of the UCG, as described in dogs, may be an effective treatment for this condition.

Keywords: Orthopaedic; lameness; shoulder; surgery; arthroscopy; glenoid

Accepted: 9 September 2019

Introduction

Incomplete ossification centres have been described in several clinical entities, with an ununited anconeal process perhaps being the most common example seen in dogs. Incomplete ossification of the accessory caudal glenoid ossification centre, abbreviated here to ununited caudal glenoid (UCG), have been described both as an incidental and a clinically significant finding only in dogs.¹ To our knowledge, UCG as a cause of lameness in cats has never been described.

Case description

A 16-year-old neutered female domestic shorthair cat was presented with a history of progressively worsening lameness of 8 months' duration. The lameness gradually worsened, despite the use of non-steroidal anti-inflammatory drugs (NSAIDs).

At presentation, the cat was reluctant to walk but showed an overall stiff gait. On video excerpts made by

the owner, moderate lameness of the right thoracic limb was observed. On initial physical examination, the cat was bright and alert. The cat was obese, with a body weight of 5.6 kg and a body condition score of 6/9. Body temperature (38.1°C) was normal and further general clinical examination revealed no abnormalities. No deficits could be observed on neurological examination. Abnormal findings on orthopaedic evaluation included a decrease in muscle mass of the infra- and supraspinatus muscles of the right thoracic limb, a decreased range of motion (ROM) of the right and left carpus and a

AniCura Dierenziekenhuis Drechtstreek, Dordrecht, The Netherlands

Corresponding author:

Boris MA Serck DVM, resident ECVS, AniCura Dierenziekenhuis Drechtstreek, Jan Valsterweg 26, Dordrecht, 3315 LG, The Netherlands
Email: boris.serck@anicura.nl



Creative Commons Non Commercial CC BY-NC: This article is distributed under the terms of the Creative Commons

Attribution-NonCommercial 4.0 License (<http://www.creativecommons.org/licenses/by-nc/4.0/>) which permits non-commercial use, reproduction and distribution of the work without further permission provided the original work is attributed as specified on the SAGE and Open Access pages (<https://us.sagepub.com/en-us/nam/open-access-at-sage>).

decreased ROM, with pain on manipulation, of the right shoulder. Medial, lateral, cranial and caudal stability of both shoulders was assessed and deemed normal.

In accordance with the owner's wishes, conservative therapy was first elected. The patient was given cage rest, nutritional supplements (Hill's Prescription Diet j/d Feline), caloric restriction and continued treatment with meloxicam 0.05 mg/kg lean body weight (Metacam; Boehringer Ingelheim) for 1 month.

One month later at the follow-up examination, no improvement of the clinical signs was noted.

Despite caloric restrictions, the cat's weight had increased to 5.8 kg. This was attributed to poor owner compliance. Neurological and orthopaedic examinations were as before and the patient was scheduled for radiography under general anaesthesia. Pre-anaesthetic blood screening was unremarkable.

The patient was sedated with an intravenous administration of 1 mg midazolam (Midazolam Actavis 5 mg/ml; Actavis), 20 mg ketamine (Ketamine 100 inj.; ASTfarma) and 0.12 mg buprenorphine (Buprecare multidosis 0.3 mg/ml; AST Farma). Radiographic examination included a mediolateral and craniocaudal view of the right and left carpal and glenohumeral joints. No abnormalities were noted in the right and left carpal joints. Radiographic findings indicated a bilateral UCG (Figures 1 and 2). In the right shoulder a large mineralised body caudal to the humeral head, probably located inside the caudal pouch of the glenohumeral joint, was observed (Figure 1).

An arthrogram of the right glenohumeral joint was performed (Figure 3). The skin over the right shoulder was aseptically prepared and 2 ml of iodine contrast agent (Iohexol, OMNIPAQUE 140 mg I/ml; GE Healthcare) was injected intra-articularly. The mineralised body was completely obscured by the contrast agent, indicating the intra-articular position of the joint mouse. Also, a small filling defect was seen opposite the UCG, indicative of impingement on the glenohumeral joint by the UCG. Based on the clinical and radiographic findings, an arthroscopy of the right glenohumeral joint was recommended to the owner.

At the time of arthroscopy, the cat was premedicated with the same protocol. Anaesthesia was induced with 8 mg alfaxalone (Alfaxan 10 mg/ml; Dechra) and maintained with isoflurane (Isoflo 100% isoflurane/ml; AST Farma) in oxygen. A standard arthroscopic approach of the right shoulder was performed. Arthroscopic inspection using a 2.4 mm-wide, 30°-angled arthroscope of the joint revealed synovitis of the joint capsule, an unstable UCG, severe cartilage wear (modified Outerbridge scoring 4)² of the humeral head opposite the UCG, and a large free-floating mineralised body, which was attached to the UCG by a string of fibrous tissue (Figure 4). No other abnormalities were noted inside the joint.

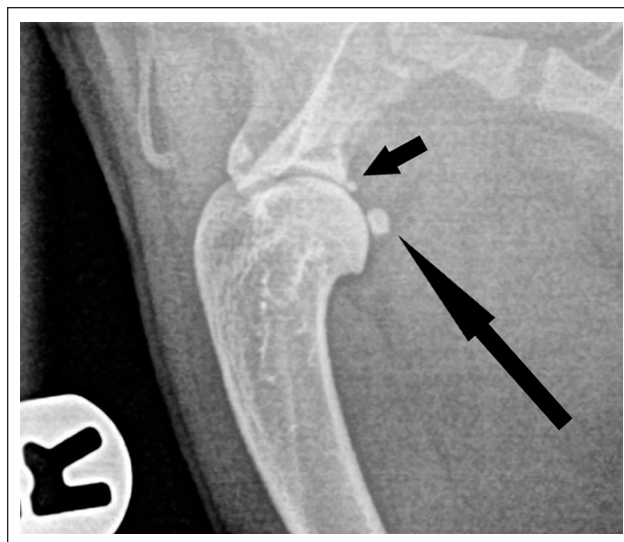


Figure 1 Radiography of the right glenohumeral joint with a ununited caudal glenoid (short arrow) and a joint mouse (long arrow)

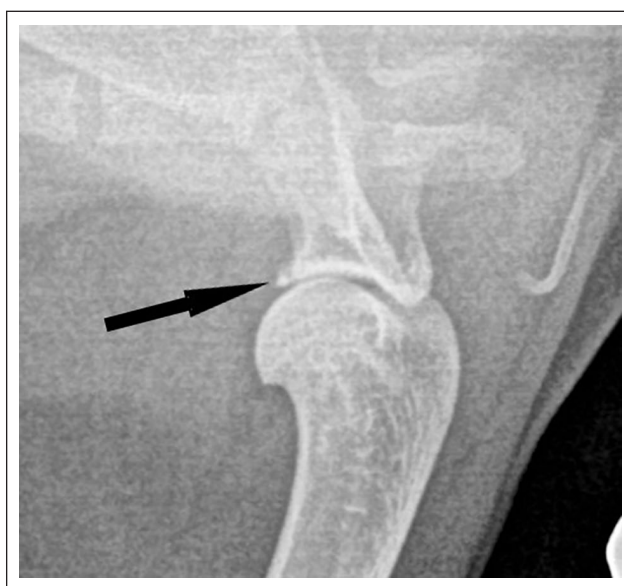

Figure 2 Radiography of the left glenohumeral joint with an ununited caudal glenoid (arrow)

The UCG was embedded in, and connected to, the glenoid with fibrous tissue. It consisted of necrotic bone with a characteristic yellow crumbly appearance. It was unstable on gentle probing.

Cartilage wear of the humeral head was only localised opposite the UCG and showed a focal severe loss of cartilage with the appearance of subchondral bone. It is described as a kissing lesion with a modified Outerbridge scoring of 4.²

Under arthroscopic visualisation, the UCG was carefully dissected free and both it and the mineralised body (Figure 5) were removed via the arthroscopic portals.

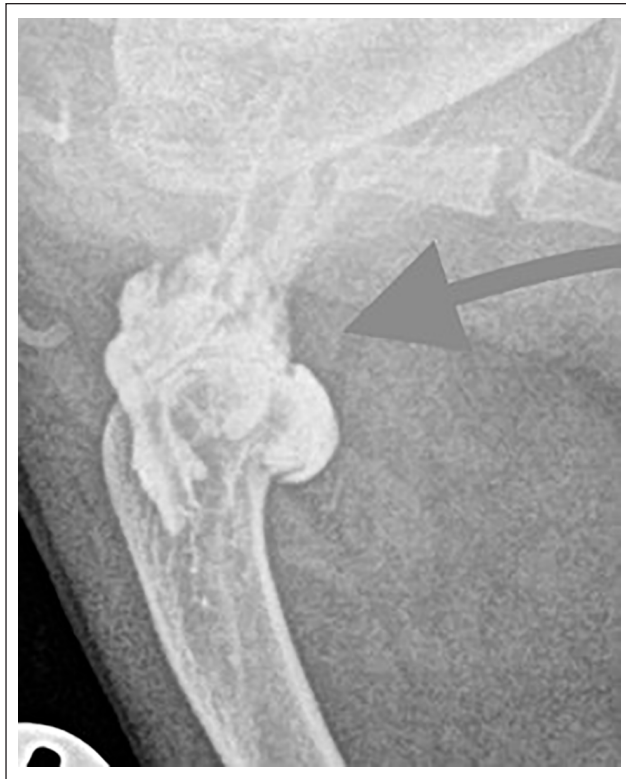

Figure 3 Arthrogram of the right glenohumeral joint; filling defect (arrow) opposite the ununited caudal glenoid

Skin closure was routine and 2.5mg of bupivacaine (Marcaine 5 mg/ml; Astra Zeneca) was injected intra-articularly after closure.

The patient was sent home with activity restrictions and a 3-week course of meloxicam 0.05 mg/kg lean body weight (Metacam; Boehringer Ingelheim).

A follow-up examination was performed 3 weeks after surgery. The two incisions for the arthroscopic portals had healed without complications. The owner reported that the patient had markedly improved. NSAIDs were discontinued and a follow-up appointment was made for 3-weeks later. The owners did not meet this appointment and were interviewed by telephone 2 months later. By then, the patient was not on any medications and showed no lameness. Three years later, the patient was euthanased because of signs related to chronic kidney disease, having shown no recurrence of the lameness.

Discussion

Incomplete ossification is hypothesised to be the result of osteochondrosis or genetic, traumatic and other growth disorders, while the exact cause usually remains unknown.¹ The mobility of a UCG and the secondary inflammation have been shown to be a primary cause of lameness in dogs.¹ This is the first report of a clinically significant UCG in a cat.

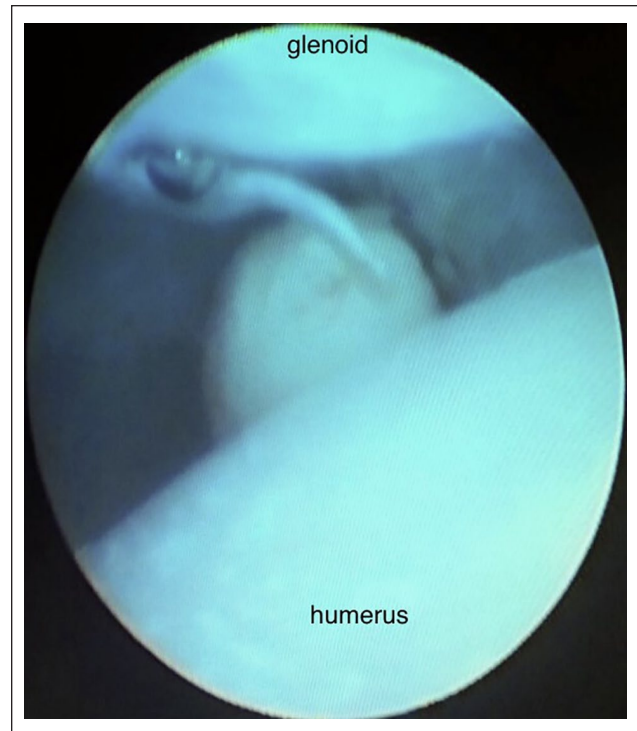


Figure 4 Arthroscopic image of the joint mouse attached to the ununited caudal glenoid by a string of fibrous tissue

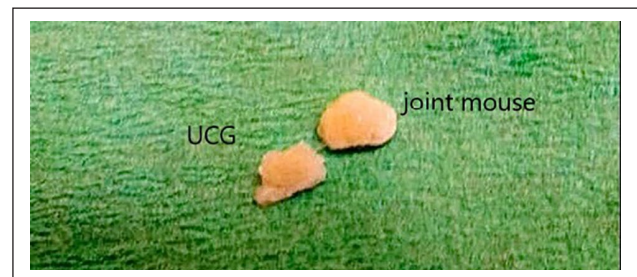

Figure 5 Ununited caudal glenoid with joint mouse attached, after resection and removal

In dogs, UCG can be seen on plain radiography. Only a presumptive diagnosis can be made on the basis of clinical examination and radiographic screening, as UCG can be an incidental finding.³ Other possible causes of lameness should be excluded and further diagnostics should be made to diagnose UCG as the cause of lameness. Further diagnostics that have been described in dogs are nuclear scintigraphy, arthrography or arthroscopy.¹

This case report shows a similar work-up as has been described in dogs.¹ Plain radiographs and arthrography revealed a UCG and a joint mouse. Arthroscopy demonstrated instability of the UCG, synovitis of the joint capsule, cartilage wear opposite the UCG and an attached joint mouse. This work-up and the resolution of clinical signs following treatment are indicative of a clinically significant disease.

The contralateral shoulder demonstrates that UCG can be an incidental finding in cats. The possibility that other causes of shoulder pain, mainly the joint mouse, and not the UCG are the real and only source of pain in this patient, therefore cannot be excluded. We feel that both the preoperative work-up and the intraoperative findings are indicative of the UCG as an important source of lameness in this patient. The arthrography revealed a filling defect opposite the UCG, suggesting the inflammation associated with the UCG was impinging on the joint space. Furthermore, the intraoperative findings clearly demonstrated synovitis and instability of the UCG and cartilage wear opposite the UCG. In dogs, it has been speculated that instability of the UCG within the joint probably causes synovitis and pain.³ A similar mechanism of disease can be speculated in cats.

The origins of the joint mouse and its contribution to the patient's lameness and pathology could not be elucidated further. The joint mouse was physically attached to the UCG. A common origin or pathology can therefore be expected. Unfortunately, the specimens were not sent for further pathological analysis so no definite explanation can be given to the relationship of the joint mouse and the UCG. The joint mouse could be an inflammatory reaction to chronic synovitis, but we speculate that the joint mouse could be a break-away part of the UCG, following a traumatic or inflammatory degrading of the UCG. A traumatic origin can further explain why the right shoulder developed a clinically significant UCG and the left shoulder did not.

In dogs, the treatment of clinically significant UCG always includes removal of the fragment, either by arthrotomy or arthroscopy.¹ In this case, arthroscopic removal of the UCG and attached joint mouse was performed.

Good clinical outcomes can be expected in dogs.¹ This case report also describes an excellent clinical outcome in a cat.

Conclusions

UCG can be an incidental finding in cats but should not be dismissed as a possible cause of lameness. The disease work-up and treatment are similar to that described in dogs. To the authors' knowledge, this is the first case report of clinically relevant UCG with an associated joint mouse, where arthroscopic removal of the bodies resulted in complete resolution of the lameness.

Conflict of interest The authors declared no potential conflicts of interest with respect to the research, authorship, and/or publication of this article.

Funding The authors received no financial support for the research, authorship, and/or publication of this article.

Ethical approval This work involved the use of non-experimental animal(s) only (owned or unowned), and followed established internationally recognised high standards ('best practice') of individual veterinary clinical patient care. Ethical approval from a committee was not necessarily required.

Informed consent Informed consent (either verbal or written) was obtained from the owner or legal custodian of all animal(s) described in this work for the procedure(s) undertaken. No animals or humans are identifiable within this publication, and therefore additional informed consent for publication was not required.

References

- 1 Olivieri M, Piras A, Marcellin-Little DJ, et al. **Accessory caudal glenoid ossification centre as possible cause of lameness in nine dogs.** *Vet Comp Orthop Traumatol* 2004; 17: 131–135.
- 2 Johnston S and Tobias K. **Modified Outerbridge score.** In: *Veterinary surgery small animal*. 2nd ed. St Louis, MO: Saunders Elsevier, 2018, p 860.
- 3 Beale B, Hulse D, Shulz K, et al. **Incomplete fusion of the caudal glenoid ossification center.** In: *Small animal arthroscopy*. Philadelphia, PA: Saunders Elsevier, 2003, pp 46–47.