

Histochemical and Electron Microscopic Properties of the Masseter Muscle in the Japanese Field Vole *Microtus montebelli*

Authors: Sugasawa, Katsumi, Andō, Kōichi, Mōri, Takayuki, and Shiraishi, Satoshi

Source: Zoological Science, 14(2) : 369-374

Published By: Zoological Society of Japan

URL: <https://doi.org/10.2108/zsj.14.369>

The BioOne Digital Library (<https://bioone.org/>) provides worldwide distribution for more than 580 journals and eBooks from BioOne's community of over 150 nonprofit societies, research institutions, and university presses in the biological, ecological, and environmental sciences. The BioOne Digital Library encompasses the flagship aggregation BioOne Complete (<https://bioone.org/subscribe>), the BioOne Complete Archive (<https://bioone.org/archive>), and the BioOne eBooks program offerings ESA eBook Collection (<https://bioone.org/esa-ebooks>) and CSIRO Publishing BioSelect Collection (<https://bioone.org/csiro-ebooks>).

Your use of this PDF, the BioOne Digital Library, and all posted and associated content indicates your acceptance of BioOne's Terms of Use, available at www.bioone.org/terms-of-use.

Usage of BioOne Digital Library content is strictly limited to personal, educational, and non-commercial use. Commercial inquiries or rights and permissions requests should be directed to the individual publisher as copyright holder.

BioOne is an innovative nonprofit that sees sustainable scholarly publishing as an inherently collaborative enterprise connecting authors, nonprofit publishers, academic institutions, research libraries, and research funders in the common goal of maximizing access to critical research.

Histochemical and Electron Microscopic Properties of the Masseter Muscle in the Japanese Field Vole *Microtus montebelli*

Katsumi Sugasawa¹, Kōichi Andō², Takayuki Mōri^{1*} and Satoshi Shiraishi¹

¹*Zoological Laboratory, Faculty of Agriculture, Kyushu University 46-06, Fukuoka 812-81, Japan*

²*Biological Laboratory, Department of Regional Culture, Faculty of International Studies of Culture, Kyushu Sangyo University, Fukuoka 813, Japan*

ABSTRACT—The masseter muscles of the Japanese field vole *Microtus montebelli* were studied histochemically and electron microscopically. The masseter muscles were composed of only fast-twitch oxidative (FO) fibers. As to ultrastructural features of the fibers, mitochondria, sarcoplasmic reticula and transverse tubules were well developed. It is concluded that the masseter muscles in *M. montebelli* have the structural characteristics that they can contract fast and enduringly. Thus, they appear to be highly adapted to herbivorous food habit.

INTRODUCTION

The masticatory activity is largely carried out by masseter, temporalis, medial and lateral pterygoid muscles. The jaw muscles of herbivorous mammals differ from those of carnivorous mammals, i.e. the masseter muscles in herbivores are relatively large in size, and in carnivores the temporal muscles are relatively large in size (Hildebrand, 1988). The former needs functionally slow and long-term exercise, but the latter fast and short-term exercise. In omnivorous mammals, the intermediate type between herbivores and carnivores is recognized in the masseteric muscles (Suzuki, 1977).

In rodents, the masseter muscle is the largest masticatory muscle and it seems to be the most important muscle for biting hard food. The masseter muscles of the Japanese field vole *Microtus montebelli* are larger than those of the other members of Myomorpha (Miyao *et al.*, 1962). Moreover, dissection of the masticatory musculature of microtines (arvicolines) shows an increase in the potential anterior vector component and in the potential vertical vector component of these muscles relative to the molar tooth row, thus voles and lemmings are the most successful group of rodents for herbivorous habit (Kesner, 1980).

Skeletal muscles of vertebrates have two or more fiber types that differ in histochemical properties, having various proportion of fiber types to functional demands (Edström and Kugelberg, 1968; Moody and Cassens, 1968; Barnard *et al.*, 1971; Burke *et al.*, 1971). Although a number of functional

studies on mammalian masticatory muscles have been made, there is no study on histochemical and ultrastructural characteristics of the masticatory muscles in the Japanese field vole.

The purpose of the present study is to clarify histological characteristics of the masseter muscle fibers in *M. montebelli*, comparing to those of Tokara goat which is one of typical herbivores and laboratory mice belonging to Rodentia.

MATERIALS AND METHODS

Adult eleven voles, five mice and one Tokara goat were used in this study, and their *Musculus masseter* were immediately removed under ether anaesthesia.

For the light microscopic examination, muscle tissues were rapidly frozen in isopentane solution cooled with dry ice. Serial cross-sections of the muscles, 8 µm thick, were obtained and stained for myosin adenosine triphosphatase (ATPase) (Padykula and Herman, 1955) after acid (pH 4.3) or alkaline (pH 10.5) preincubation (Brooke and Kaiser, 1970a, b; Suzuki, 1977), for reduced nicotinamide adenine dinucleotide dehydrogenase (NADH-DH) (Burstone, 1962) and for phosphorylase (Takeuchi and Kuriaki, 1955) activities. In the vole, other sections were also stained with Periodic Acid-Schiff (PAS) and Sudan black B, respectively.

Fibers were classified as slow-twitch oxidative (SO), fast-twitch oxidative glycolytic (FOG), fast-twitch glycolytic (FG), fast-twitch oxidative (FO) by Peter *et al.* (1972) and Armstrong *et al.* (1977).

For the electron microscopic examination, the masseter muscles of the vole were fixed in 3% glutaraldehyde buffered with 0.1 M sodium cacodylate at pH 7.2 for 2 hr, then washed briefly in the same buffer and further fixed for 2 hr in 1% osmium tetroxide buffered with sodium cacodylate at pH 7.2. The tissues were dehydrated in alcohol series and embedded in Epon 812. Thin sections (600Å) for electron microscopy were cut with a glass knife on Porter-Blum MT-1 microtome, and doubly stained with lead and uranyl acetate. The sections were examined in an Hitachi-H600A electron microscope.

* Corresponding author: Tel. +81-92-642-2948;
FAX. +81-92-642-2804.

RESULTS

Histochemical observations

The masseter muscles in *M. montebelli* were composed of only FO fiber which was strongly reactive for myosin ATPase after preincubation at pH 10.5 (Fig. 1A), unreactive at pH 4.3 (Fig. 1B), strongly reactive for NADH-DH (Fig. 1C) and weakly reactive for phosphorylase (Fig. 1D). In NADH-DH activity, large granular diformazan deposits and strong reaction at subsarcolemmal region were recognized in the muscle fibers. The glycogen (Fig. 1E) and sudanophilic granules (Fig. 1F) were less rich. The diameter of the fiber was 18.19 ± 1.81 (S.D.) μm .

The masseter muscles of the mouse were composed of FOG (51%) and FG (49%) fibers (Fig. 2A). NADH-DH activity of FOG fiber of the muscle was weak and the diformazan deposits were smaller than that of the vole. The diameters of FOG and FG fibers were 22.00 ± 3.76 and 33.17 ± 6.86 μm , respectively.

The masseter muscle of the Tokara goat was composed of only SO fiber. In NADH-DH activity, large granular diformazan deposits and strong reaction at subsarcolemmal region were recognized in the muscle fibers as observed in the muscle fibers of the vole (Fig. 2B). The diameter of fiber was 40.38 ± 4.80 μm .




Fig. 1. Histochemical profiles of the masseter muscle in *M. montebelli*. These myofibers are all strongly reactive for myosin ATPase after preincubation at pH 10.5 (A), unreactive for myosin ATPase after preincubation at pH 4.3 (B), strongly reactive for NADH-DH (C), weakly reactive for phosphorylase (D), less rich in glycogen (PAS reaction) (E), and less rich in fat content (Sudan black B staining) (F). Bar = 50 μm .

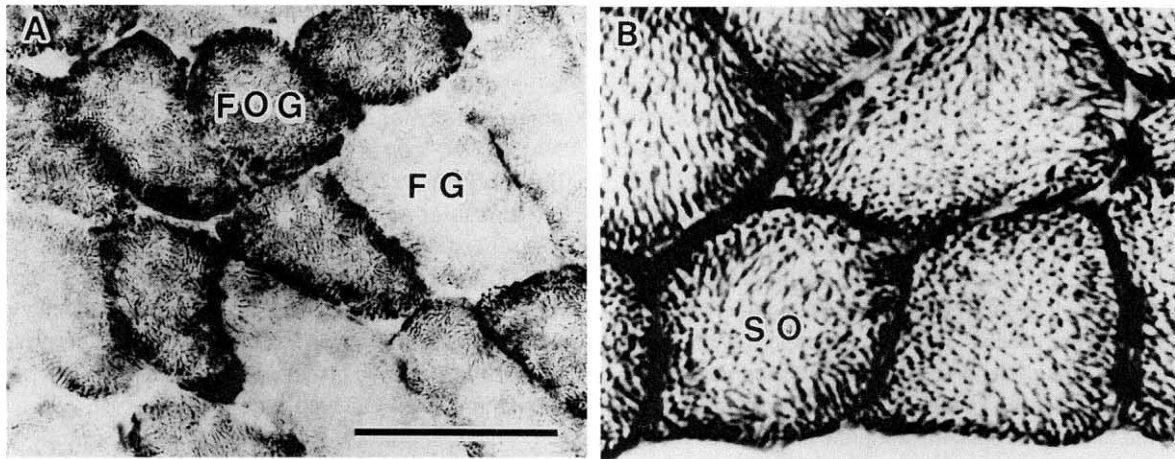


Fig. 2. NADH-DH activities of the masseter muscle. (A) Mouse. (B) Tokara goat. FOG, fast-twitch oxidative glycolytic fiber; FG, fast-twitch glycolytic fiber; SO, slow-twitch oxidative fiber. Bar = 50 μ m.

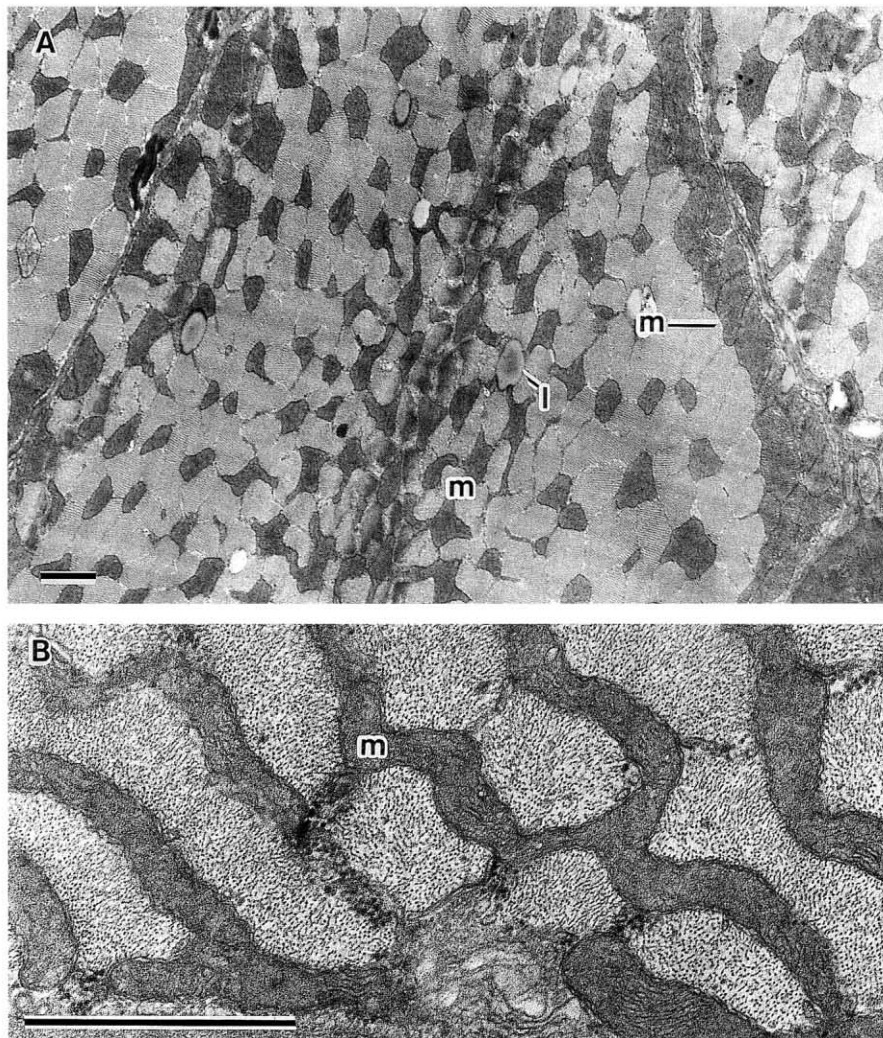


Fig. 3. Ultrastructure of the masseter muscle in the vole. (A) Cross-section showing large mitochondria with dense mitochondrial matrix arranged in transversal rows between myofibrils. The mitochondria with abundant cristae primarily consisting of parallel sheets are arranged just beneath the sarcolemma. Note the lipid droplets associated with them. (B) There are bizarrely shaped mitochondria in the transverse section of fibers. l, lipid droplet; m, mitochondrion. Bar = 1 μ m.

Electron microscopic observations

The masseter muscles of the vole were composed of a single type of fiber characterized by densely packed mitochondria (Fig. 3A, B). The large mitochondria with dense mitochondrial matrix were arranged in transversal rows between myofibrils. Especially, there were many bizarrely shaped mitochondria in the transverse sections of fibers. The mitochondria of which abundant cristae primarily consisted of parallel sheets aggregated beneath the sarcolemma. Many lipid droplets were frequently associated with mitochondria.

The transverse tubules and sarcoplasmic reticula were well developed, and glycogen granules were moderate in the interfibrillar sarcoplasm. Triads occurred near A-I junctions (Fig. 4). In the terminal axoplasm, moderate numbers of vesicle and mitochondria occurred (Fig. 5A, B). Junctional folds are regular, long and numerous.

DISCUSSION

Skeletal muscle fibers in mammals are highly differentiated in adulthood, and can be designated as fast or slow on the basis of the pH lability of histochemical staining for myosin ATPase. Fast-twitch fibers are subdivided into three types in accordance with the nature of metabolic enzyme for their energy source, fibers utilizing oxidative (FO) or glycolytic (FG) or both (FOG) enzyme, while slow-twitch fibers are primarily oxidative (SO) (Pette and Vrbová, 1985; Powers *et al.*, 1991).

al., 1991).

All the fibers of the vole masseter muscles react strongly for myosin ATPase after alkaline preincubation (fast isoform), stain strongly for oxidative mitochondrial enzymes such as NADH-DH, and weakly for glycolytic markers such as phosphorylase. These histochemical data clearly show that the masseter muscles of the vole, as well as of the mouse (present study), rat (Rokx *et al.*, 1984) and guinea pig (Suzuki, 1977), are composed of fast-twitch fibers, but the masseter muscle of the vole are of FO type, being distinctly different from those of the other three rodents that comprise a high amount of glycolytic enzyme (both FOG and FG types for the mouse and rat; FOG type for the guinea pig).

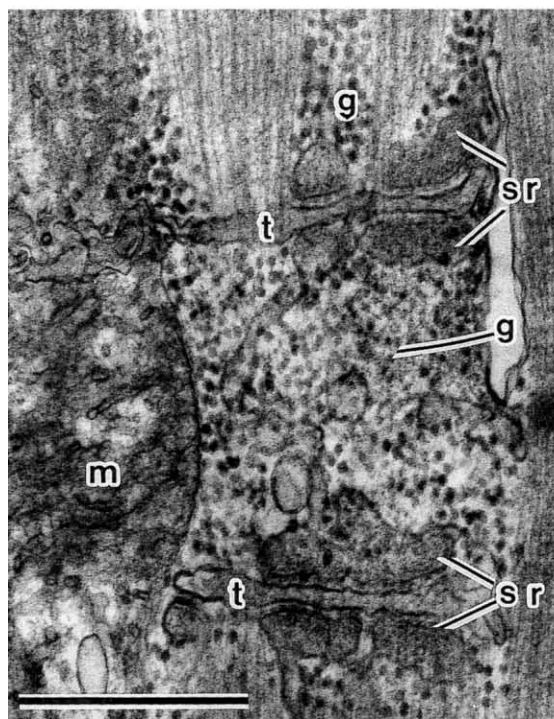


Fig. 4. Longitudinal section illustrating organization of sarcotubular system of the masseter muscle in the vole. Glycogen granules are found in the interfibrillar sarcoplasm. g, glycogen granule; m, mitochondrion; sr, sarcoplasmic reticulum; t, transverse tubule. Bar = 1 μ m.

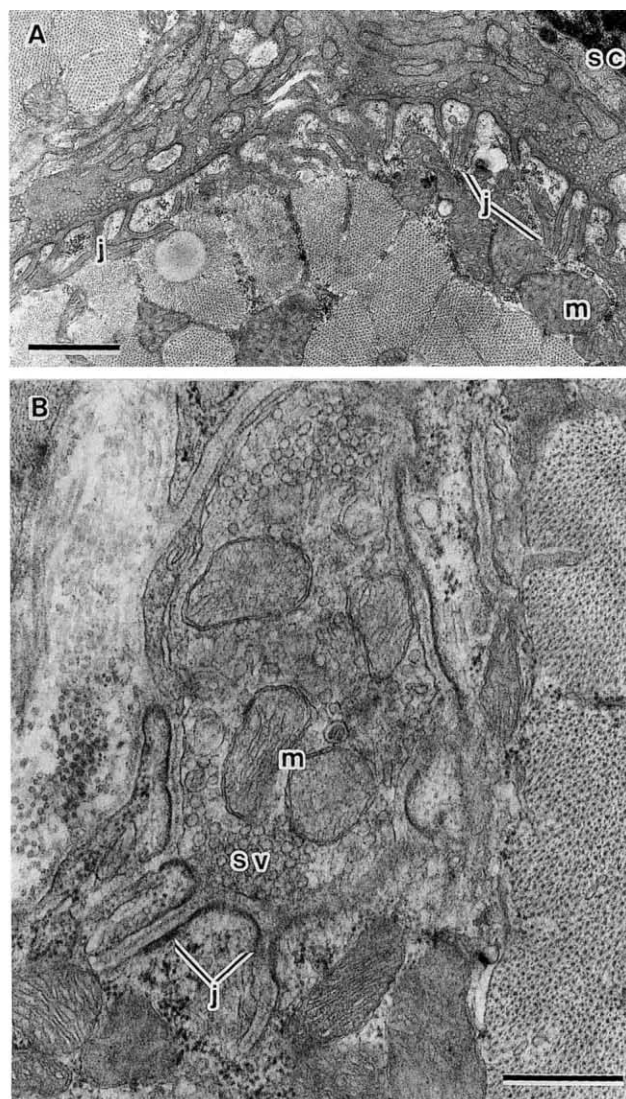


Fig. 5. Neuromuscular junction of the masseter muscle fibers in the vole. (A) The invaginated sarcoplasmic surface at the neuromuscular junction of the fiber is illustrated in this low-power electron micrograph. (B) In the terminal axoplasm, moderate numbers of synaptic vesicles and mitochondria occur, and the junctional folds are relatively long, unbranched and straight. j, junctional fold; m, mitochondrion; sc, Schwann's cell; sv, synaptic vesicle. Bar = 1 μ m.

In addition to the histochemical evidence, FO fibers in the vole are considerably smaller in diameters than FOG ones in the mouse (present study), rat (Rokx *et al.*, 1984) and guinea pig (Suzuki, 1977), and FG fibers in the mouse (present study) and rat (Rokx *et al.*, 1984). This fact, as pointed out by Hill (1965), seems to imply that FO fibers are favorable for rapid diffusion of oxygen and nutrient essential for muscle contraction. The ultrastructural features of the vole masseter muscle fibers, i.e. well developed sarcoplasmic reticula, transverse tubules and neuromuscular junctions, seem to directly related to fast muscle contraction as proposed for other mammals (Ohtsu and Uchida, 1979; Schmalbruch, 1979; Flucher, 1992). On the other hand, densely packed mitochondria, and numerous lipid droplets deposited around mitochondria may be closely associated to sustaining muscle contraction (Gauthier, 1969).

The above histochemical and ultrastructural findings emphasize strongly the following view that the FO fibers are specialized for fast and sustained contraction in which supplies of lipid droplets may be exhausted quickly. Accordingly, the masseter muscles of the vole can masticate fast and enduringly. However, the masseter muscles of the vole have a markedly less store of glycogen granules than those of the mouse (present study) and rat (Rokx *et al.*, 1984), and are less dependent on anaerobic glycolysis as SO fibers of the goat (present study), cattle and sheep (Suzuki, 1977) which are typical herbivores. For this reason, the vole masseters do not appear to engage in powerful or sudden activity for biting or gnawing as the mouse and rat which are adaptive for omnivorous food habit. Thus, such structural properties of masseter muscles in the vole, having an intermediate profile between omnivorous rodents and herbivorous ruminants, must be considered in relation to the functional differentiation of this masticatory muscle required for its own characteristic properties of herbivorous food habit.

Now, several isoforms of myosin heavy chain have been identified in mammalian muscle fibers (Bar and Pette, 1988; Hämäläinen and Pette, 1993; Schiaffino and Reggiani, 1994). According to Hermanson *et al.* (1991), the pectoral muscle of a microchiropteran species, which is known to be markedly well-developed on account of the adaptation for flight, and to be composed of only FO fiber (Powers *et al.*, 1991), comprises rat Ila myosin heavy chain alone. This study has also indicated the functional involvement of this myosin isoform for flying. It remains to be elucidated whether FO fibers of the vole masseter muscle are equipped with such nature of myosin molecule, as the result of its masticatory adaptation.

ACKNOWLEDGMENTS

We are much indebted to Professor H. Takahara and Associate Professor H. Iwamoto and graduate students of Laboratory of Animal Husbandry II, Faculty of Agriculture, Kyushu University, for their facilities for histochemical examination and to Associate Professor M. Muguruma of Laboratory of Chemistry and Technology of Animal Products, Faculty of Agriculture, Kyushu University, for comments on the manuscript.

REFERENCES

- Armstrong RB, Ianuzzo CD, Kunz TH (1977) Histochemical and biochemical properties of flight muscle fibers in the little brown bat, *Myotis lucifugus*. *J Comp Physiol* 119: 141–154
- Bar A, Pette D (1988) Three fast myosin heavy chains in adult rat skeletal muscle. *FEBS Lett* 235: 153–155
- Barnard RJ, Edgerton VR, Furukawa T, Peter JB (1971) Histochemical, biochemical, and contractile properties of red, white, and intermediate fibers. *Am J Physiol* 220: 410–414
- Brooke MH, Kaiser KK (1970a) Three 'myosin adenosine triphosphatase' system: the nature of their pH lability and sulfhydryl dependence. *J Histochem Cytochem* 18: 670–672
- Brooke MH, Kaiser KK (1970b) Muscle fiber types: How many and what kind? *Arch Neurol* 23: 369–379
- Burke RE, Levine DN, Zajac III FE, Tsairis P, Engel WK (1971) Mammalian motor units: Physiological-histochemical correlation in three types in cat gastrocnemius. *Science* 174: 709–712
- Burstone MS (1962) *Enzyme Histochemistry*. Academic Press, London, England
- Edström L, Kugelberg E (1968) Histochemical composition, distribution of fibers and fatigability of single motor units. *J Neurol Neurosurg Psychiatry* 31: 424–433
- Flucher BE (1992) Structural analysis of muscle development: transverse tubules, sarcoplasmic reticulum, and the triad. *Dev Biol* 154: 245–260
- Gauthier GF (1969) On the relationship of ultrastructural and cytochemical features to color in mammalian skeletal muscle. *Z Zellforsch* 95: 462–482
- Hämäläinen N, Pette D (1993) The histochemical profiles of fast fiber types IIB, IID, and IIA in skeletal muscles of mouse, rat, and rabbit. *J Histochem Cytochem* 41: 733–743
- Hermanson JW, LaFramboise WA, Daoood MJ (1991) Uniform myosin isoforms in the flight muscles of little brown bats, *Myotis lucifugus*. *J Exp Zool* 259: 174–180
- Hildebrand M (1988) Feeding. In "Analysis of Vertebrate Structure" John Wiley & Sons, Inc, New York, Chichester, Brisbane, Toronto, Singapore, pp 609–637
- Hill AV (1965) The diffusion of oxygen through tissues. In "Trails and Trials in Physiology, a Bibliography" Williams and Wilkins, Baltimore, pp 208–241
- Kesner MH (1980) Functional morphology of the masticatory musculature of the rodents subfamily Microtinae. *J Morph* 165: 205–222
- Miyao T, Morozumi T, Morozumi M (1962) The relative size of the mandible and the masseter in rats and mice of Murinae and Microtinae. *Medicine and Biology* 64: 50–54 (in Japanese)
- Moody WG, Cassens RG (1968) Histochemical differentiation of red and white muscle fibers. *J Anim Sci* 27: 961–968
- Ohtsu R, Uchida TA (1979) Further studies on histochemical and ultrastructural properties of the pectoral muscles of bats. *J Fac Agr Kyushu Univ* 24:145–155
- Padykula HA, Herman E (1955) Factors affecting the activity of adenosine triphosphatase and other phosphatases as measured by histochemical techniques. *J Histochem Cytochem* 3: 161–169
- Peter JB, Barnard RJ, Edgerton VR, Gillespie CA, Stempel KE (1972) Metabolic profiles of three fiber types of skeletal muscle in guinea pigs and rabbits. *Biochemistry* 11: 2627–2633
- Pette D, Vrbová G (1985) Invited review: Neural control of phenotypic expression in mammalian muscle fibers. *Muscle Nerve* 8: 676–689
- Powers LV, Kandarian SC, Kunz TH (1991) Ontogeny of flight in the little brown bat, *Myotis lucifugus*: behavior, morphology, and muscle histochemistry. *J Comp Physiol A* 168: 675–685
- Rokx JTM, van Willigen JD, Jansen HWB (1984) Muscle fiber types and muscle spindles in the jaw musculature of the rat. *Archs Oral Biol* 29: 25–31

- Schiaffino S, Reggiani C (1994) Myosin isoforms in mammalian skeletal muscle. *J Appl Physiol* 77: 493–501
- Schmalbruch H (1979) The membrane system in different fiber types of the triceps surae muscle of cat. *Cell Tissue Res* 204: 187–200
- Suzuki A (1977) A comparative histochemical study of the masseter muscle of the cattle, sheep, swine, dog, guinea pig and rat. *Histochemistry* 51: 121–131
- Takeuchi T, Kuriaki H (1955) Histochemical detection of phosphorylase in animal tissue. *J Histochem Cytochem* 3: 153–160

(Received October 17, 1996 / Accepted January 24, 1997)