

A Case of Leucocytozoonosis in A Wild Mallard

Author: KARSTAD, LARS

Source: Bulletin of the Wildlife Disease Association, 1(3) : 33-34

Published By: Wildlife Disease Association

URL: <https://doi.org/10.7589/0090-3558-1.3.33>

The BioOne Digital Library (<https://bioone.org/>) provides worldwide distribution for more than 580 journals and eBooks from BioOne's community of over 150 nonprofit societies, research institutions, and university presses in the biological, ecological, and environmental sciences. The BioOne Digital Library encompasses the flagship aggregation BioOne Complete (<https://bioone.org/subscribe>), the BioOne Complete Archive (<https://bioone.org/archive>), and the BioOne eBooks program offerings ESA eBook Collection (<https://bioone.org/esa-ebooks>) and CSIRO Publishing BioSelect Collection (<https://bioone.org/csiro-ebooks>).

Your use of this PDF, the BioOne Digital Library, and all posted and associated content indicates your acceptance of BioOne's Terms of Use, available at www.bioone.org/terms-of-use.

Usage of BioOne Digital Library content is strictly limited to personal, educational, and non-commercial use. Commercial inquiries or rights and permissions requests should be directed to the individual publisher as copyright holder.

BioOne is an innovative nonprofit that sees sustainable scholarly publishing as an inherently collaborative enterprise connecting authors, nonprofit publishers, academic institutions, research libraries, and research funders in the common goal of maximizing access to critical research.

A Case of Leucocytozoonosis in A Wild Mallard

LARS KARSTAD

Division of Zoonoses and Diseases of Wildlife, Ontario Veterinary College, Guelph, Canada

Received for publication 30 April 1965

During the first week of August, 1963, a juvenile male mallard (*Anas platyrhynchos*) was found moribund in the Presque Isle Park area, Ontario. It was examined and necropsied by Dr. R. Julian at the Regional Veterinary Laboratory, Brighton, Ontario. Other than extreme emaciation, no gross lesions were noted. Tissues from a variety of organs were fixed in formalin and submitted for histologic examination.

Breast muscle tissues were typical of advanced nutritional dystrophy. An average of 36 poorly developed megaloschizonts of *Leukocytozoon* sp. were found per cm² of muscle tissues sectioned at 6-7 μ . The most striking lesions, however, were in the brain. There, megaloschizonts were found 300 to 400 per cm², in all stages of development from the trophozoite stage to cysts 160-190 μ in diameter (fig. 1). In addition, there was proliferation of capillaries and extreme proliferative changes in the intima of larger vessels, to the extent that many arteries and veins were nearly obstructed (fig. 2). Thrombi were not seen but hemorrhages associated with mature or ruptured megaloschizonts were common.

Blood vessels in all organs contained large numbers of *Leukocytozoon* gametocytes. Schizonts were not found in the liver, lung, kidney and testicle. The spleen was not submitted for examination.

Megaloschizonts were always found closely associated with blood vessels. Release of merozoites from mature megaloschizonts appeared to be a gradual

process. This was accompanied by activity of glial phagocytes or Gitter cells in the surrounding tissue. Gitter cells became filled with the merozoites released from cysts and frequently invaded the cysts. It is possible that in carrying debris and merozoites back into the circulating blood Gitter cells may serve a function mutually beneficial to both host and parasite. Cysts which were emptied of merozoites either had collapsed or had become filled with blood, suggesting "recanalization" by the blood stream.

Discussion and Conclusions

The large size (190 μ) and number of the megaloschizonts in the brain of this duck suggest that this tissue is favorable for their development. This is contrary to the conclusions of Cowan (1955), who found development of megaloschizonts in the brains of domestic ducks to be retarded in comparison to their development in the spleen. The largest size of megaloschizonts in the spleen recorded by Cowan was 206 μ and the largest brain megaloschizonts observed by Newberne (1957) were 118 μ . It is unfortunate, in our case, that the spleen was not available for comparison.

Signs of weakness and starvation shown by this duck were probably due to heavy parasitism with *Leukocytozoon*, with resultant anemia, neurologic disease, and inability to feed. The clinical and gross pathological observations in this case suggest that ducks found in the field in weakened or starving condition should be examined histologically for evidence of *Leukocytozoon* infection.

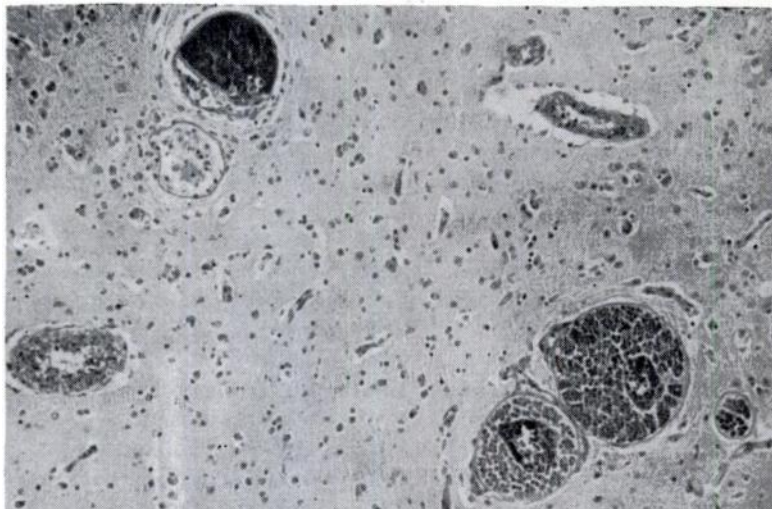


FIGURE 1

Cerebrum with *Leucocytozoon megaloschizonts* in various stages of development to the mature cyst containing many small dark merozoites (upper left). Below it, is a cyst emptied of merozoites.

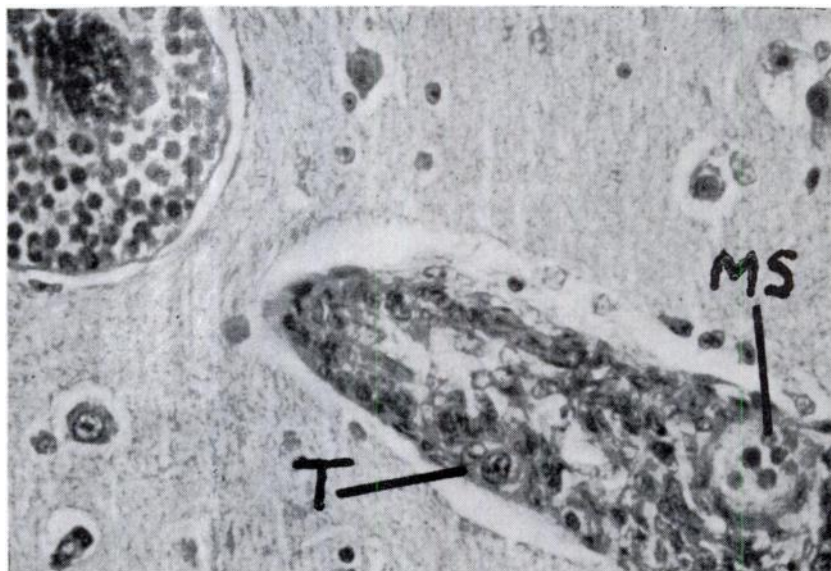


FIGURE 2

Cerebrum with megaloschizont to show the central body and cytomeres. The blood vessel has a markedly proliferated intima containing trophozoites (T) and an early megaloschizont (MS).

REFERENCES

- COWAN, ARCHIBALD B. 1955. The development of megaloschizonts of *Leucocytozoon simondi* Mathis and Leger. J. Protozool. 2:158-167.
 NEWBERNE, JAMES W. 1957. Studies on the histopathology of *Leucocytozoon simondi* infection. Am. J. Vet. Res. 16:191-199.