

## **PAPILLOMAS IN BLACK AND WHITE COLOBUS MONKEYS (*Colobus polykomus*)**

Authors: BOEVER, WILLIAM J., and KERN, TOM

Source: Journal of Wildlife Diseases, 12(2) : 180-181

Published By: Wildlife Disease Association

URL: <https://doi.org/10.7589/0090-3558-12.2.180>

---

The BioOne Digital Library (<https://bioone.org/>) provides worldwide distribution for more than 580 journals and eBooks from BioOne's community of over 150 nonprofit societies, research institutions, and university presses in the biological, ecological, and environmental sciences. The BioOne Digital Library encompasses the flagship aggregation BioOne Complete (<https://bioone.org/subscribe>), the BioOne Complete Archive (<https://bioone.org/archive>), and the BioOne eBooks program offerings ESA eBook Collection (<https://bioone.org/esa-ebooks>) and CSIRO Publishing BioSelect Collection (<https://bioone.org/csiro-ebooks>).

Your use of this PDF, the BioOne Digital Library, and all posted and associated content indicates your acceptance of BioOne's Terms of Use, available at [www.bioone.org/terms-of-use](http://www.bioone.org/terms-of-use).

Usage of BioOne Digital Library content is strictly limited to personal, educational, and non-commercial use. Commercial inquiries or rights and permissions requests should be directed to the individual publisher as copyright holder.

---

BioOne is an innovative nonprofit that sees sustainable scholarly publishing as an inherently collaborative enterprise connecting authors, nonprofit publishers, academic institutions, research libraries, and research funders in the common goal of maximizing access to critical research.

## PAPILLOMAS IN BLACK AND WHITE COLOBUS MONKEYS (*Colobus polykomus*)

WILLIAM J. BOEVER<sup>1</sup> and TOM KERN<sup>2</sup>.

**Abstract:** Numerous Papillomas ranging in size from 10-25 mm were found on two Colobus monkeys, *Colobus polykomus*. These cauliflower-shaped growths were located on the palms and soles of all four feet and on the dorsal surfaces of several fingers and toes.

### INTRODUCTION

Cutaneous papillomas have been recognized as virus-induced clinical entities in many domestic and wild animal species, notably various ungulates (cattle, goats and horses), canines, rabbits,<sup>6</sup> and in man. The human papilloma was the first neoplasm to be experimentally transmitted between members of a host species<sup>2</sup> and the first whose viral etiology was confirmed by electron microscopy.<sup>7</sup> The prevalence and distribution of papillomatosis in non-human primates are not well documented. The intent of this paper is to document cutaneous papillomas of unknown etiology in two captive East African Colobus monkeys, *Colobus polykomus*.

There are few reports of cutaneous papillomatosis in subhuman primates. Lucke *et al.*<sup>4</sup> described lesions in a Capuchin monkey (*Cebus sp.*) which spread to other sites on the same monkey; and to 11 of 13 other monkeys, both New and Old World species. These lesions regressed within 8 months and no malignant transformation occurred. Cutaneous horns, observed on other animals and man, also have been seen in the Rhesus Macaque (*Macaca mulatta*) and seem to be heavily keratinized papillomatous growths.<sup>1</sup> This case report adds another species to the already long list of animals with this type of neoplasia.

### HISTORY

In 1961, the St. Louis Zoo received a male and a female Black and White Colobus Monkey, *C. polykomus*, each 5 years old. In October, 1968, the female delivered one female offspring which remained with the parents to complete a family display. In 1972, an unrelated 2 year old wild-caught female was procured from an animal dealer and introduced into the exhibit. These primates have been maintained on a diet of mixed fruits, vegetables and monkey chow.

Around 1970, the original pair developed gradually enlarging multiple horny growths on the palms of their hands and the soles of their feet. The exact date is not known because the animals were not observed at close range. Only the original pair developed growths.

On May 17, 1974, the oldest female, 18 years of age, weighing 10.25 kg, was immobilized with 100 mg of ketamine hydrochloride<sup>3</sup> intramuscularly via hand syringe.

Horny growths were present on the palms and soles of all four feet and on the dorsal surfaces of several fingers and toes. They were hard, black, cauliflower-shaped, and ranged in size from 10 to 25 mm (Figs. 1, 2). These were removed and the hemorrhage controlled with electrocautery. The animal recovered uneventfully from anesthesia and was returned to the display.

<sup>1</sup> Staff Veterinarian, St. Louis Zoo, St. Louis, Missouri, and Research Associate, Department of Veterinary Pathology, University of Missouri School of Veterinary Medicine, Columbia, Missouri, USA.

<sup>2</sup> Veterinary student, Missouri University School of Veterinary Medicine, Columbia, Missouri, on preceptorship at the St. Louis Zoo.

<sup>3</sup> Vetalar ®—Parke Davis.

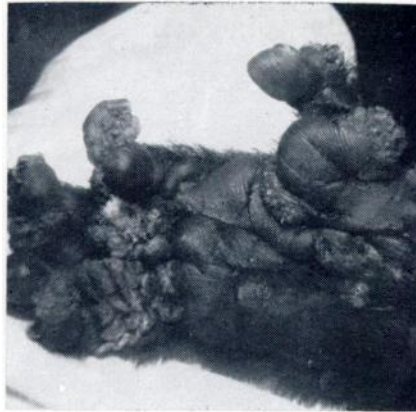


FIGURE 1. Papillomas on feet of Colobus monkey.

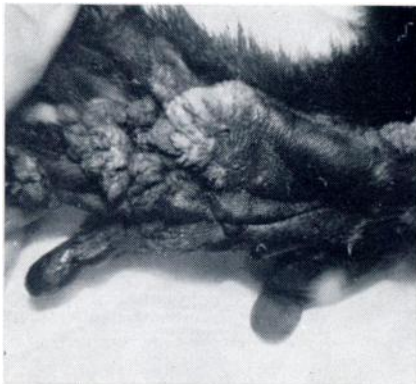

FIGURE 2. Papillomas on feet of Colobus monkey.

Specimens were fixed in 10% formalin and submitted for histologic preparation.

#### HISTOLOGY

Histologically, the growths appeared as papillomas. The lesions consisted of greatly thickened epidermis which was both acanthotic and hyperkeratotic supported in elaborate fronds by a core of hyperplastic dermis. Inclusion bodies suggestive of viral etiology were not evident.

#### DISCUSSION

These epidermic growths have been described as occurring on any area of the skin surface and also in the oral cavity. They may be small, round, dimpled elevations or composed of filiform papillae. Most have the well-known cauliflower appearance.<sup>3</sup>

The spectrum of conceivable causes of papillomas extends beyond purely viral consideration. Other classic causes of neoplasia must be recalled, notably radiation (from sunlight and medical or industrial equipment), carcinogenic chemicals, and chronic local irritation. At best, the elucidation of the actual cause of neoplasia in any specific case may be equivocal.

The possibility of employing a ground-tissue autogenous vaccine to control the papillomas in the two affected monkeys and perhaps to prevent these growths in the two younger monkeys, (if indeed the cause is infectious) is being investigated. Dramatic results have been obtained in the bovine using this therapy.<sup>5</sup>

#### LITERATURE CITED

1. BROWN, R. J., W. E. BRITZ, J. L. KUPPER and W. P. TREVATHAN. 1972. Cutaneous Horn in a Rhesus Monkey. *Lab. Anim. Sci.* 22: 112-113.
2. BURDETTE, W. J. 1966. *Viruses Inducing Cancer*. University of Utah Press.
3. JUBB, K. V. J. and P. C. KENNEDY. 1963. *Pathology of Domestic Animals*, Vol. 2. Academic Press, New York.
4. LUCKE, B., H. RATCLIFFE and C. BREEDIS. 1950. Transmissible Papilloma in Monkeys. *Fed. Proc.* 9: 337.
5. SIEGMUND, O. H. (Ed.) 1967. *The Merck Veterinary Manual*. Merck & Co. Inc., Rahway, New Jersey.
6. SMITH, H. A. and T. C. JONES. 1966. *Veterinary Pathology*. Lea & Febiger, Philadelphia Pa.
7. STRAUSS, M. J., E. W. SHAW, H. BUNTING and J. L. MELNICK. 1949. Crystalline Virus-like Particles From Skin Papillomas Characterized by Intracellular Inclusion Bodies. *Proc. Soc. Exp. Biol. Med.* 72: 46-50.

Received for publication 19 May 1975