

## **ASPERGILLOSIS IN COMMON CROWS IN NEBRASKA, 1974**

Author: ZINKL, JOSEPH G.

Source: Journal of Wildlife Diseases, 13(2) : 191-193

Published By: Wildlife Disease Association

URL: <https://doi.org/10.7589/0090-3558-13.2.191>

---

The BioOne Digital Library (<https://bioone.org/>) provides worldwide distribution for more than 580 journals and eBooks from BioOne's community of over 150 nonprofit societies, research institutions, and university presses in the biological, ecological, and environmental sciences. The BioOne Digital Library encompasses the flagship aggregation BioOne Complete (<https://bioone.org/subscribe>), the BioOne Complete Archive (<https://bioone.org/archive>), and the BioOne eBooks program offerings ESA eBook Collection (<https://bioone.org/esa-ebooks>) and CSIRO Publishing BioSelect Collection (<https://bioone.org/csiro-ebooks>).

Your use of this PDF, the BioOne Digital Library, and all posted and associated content indicates your acceptance of BioOne's Terms of Use, available at [www.bioone.org/terms-of-use](http://www.bioone.org/terms-of-use).

Usage of BioOne Digital Library content is strictly limited to personal, educational, and non-commercial use. Commercial inquiries or rights and permissions requests should be directed to the individual publisher as copyright holder.

---

BioOne is an innovative nonprofit that sees sustainable scholarly publishing as an inherently collaborative enterprise connecting authors, nonprofit publishers, academic institutions, research libraries, and research funders in the common goal of maximizing access to critical research.

## ASPERGILLOSIS IN COMMON CROWS IN NEBRASKA, 1974

JOSEPH G. ZINKL,<sup>[1]</sup> U.S. Fish and Wildlife Service, Denver Wildlife Research Center,  
Bldg. 16, Federal Center, Denver, Colorado 80225, USA

JOSEPH M. HYLAND<sup>[2]</sup> and JAMES J. HURT,<sup>[3]</sup> Nebraska Game and Parks Commission,  
2200 North 33rd Street, Lincoln, Nebraska 68503, USA

**Abstract:** During fall 1974, approximately 1,000 to 1,500 common crows (*Corvus brachyrhynchos*) died of aspergillosis in south-central Nebraska. The birds were debilitated, lethargic and dyspneic. On necropsy, typical lesions of aspergillosis were found in the lungs and air sacs. Histopathologic examination revealed granulomatous lesions around fungal hyphae in the respiratory system.

### INTRODUCTION

The fungal disease aspergillosis has been reported in a variety of wild birds in many geographical locations.<sup>1,3,4,6,7</sup> Waterfowl and other game birds are the most frequently cited avian hosts, but perhaps this only reflects the more frequent examination of those species for disease. Certainly many other species of birds, including passerines,<sup>1,3,6</sup> are susceptible to *Aspergillus*. There is only one reference to aspergillosis in common crows (*Corvus brachyrhynchos*)<sup>6</sup> and little information concerning its nature is available. Therefore, we decided to describe an outbreak of the disease in crows that occurred in Nebraska in the fall, 1974.

### HISTORY

During October, 1974, personnel of the Nebraska Game and Parks Commission noticed an unusually high rate of mortality in crows near the Sacramento-Wilcox Game Management Area in the south-central part of the state. The die-off continued through October

and November. Near the end of November, the remaining crows migrated and dead crows were no longer found. A rough estimate is that at least 10% of a population of 10-15,000 crows died during the epornitic.

This management area has a confined flock of giant Canada geese (*Branta canadensis maxima*) used to propagate birds for reestablishing historical breeding populations within the state. Since crows contacted geese in the pen area and at feeders, concern developed that the disease affecting crows might be contagious for geese. Therefore, diagnostic assistance was requested from the U.S. Fish and Wildlife Service.

### CLINICAL SIGNS

Affected crows were lethargic and could be approached to within 10-20 m before fleeing either by walking or by weakly flying a short distance. Severely affected birds were easily caught with a long-handle fish net. Captured birds were quite listless, dyspneic, in poor condition, and usually died within 1 to 5 days.

[1] Present address: Department of Clinical Pathology, University of California, Davis, California 95616, USA.

[2] Nebraska Game and Parks Commission, Rt. 4, North Platte, Nebraska 69101, USA.

[3] Nebraska Game and Parks Commission, Department of Biology, Kearney State College, Kearney, Nebraska 68847, USA.

### GROSS PATHOLOGY

Examination of eight crows revealed general debility. The birds were dehydrated and little food was present in their digestive tracts. Gross lesions were confined to the respiratory system. Firm, 1 to 10 mm diameter, yellow-green nodules were scattered throughout the lungs. Nodules were most prevalent in peripheral portions of the lung. Two birds had yellow, disc-shaped structures up to 10 mm in diameter on the air sacs adjacent to the lungs. These structures had centers raised about 2 mm above the surrounding area.

### HISTOPATHOLOGY

Liver, kidney, intestinal tract, brain, spleen and respiratory tissues were placed in buffered neutral 10% formalin, embedded in paraffin, sectioned at 6  $\mu$ m and stained with hematoxylin and eosin (H and E). Some liver and respiratory sections also were stained by the periodic acid-Schiff (PAS) technique, and by the Ziehl-Neelsen acid-fast method.

Lesions were confined to the respiratory system. The nodules in the lungs were granulomatous reactions around fungal hyphae (Fig. 1). In some lungs, a diffuse pneumonia involving airways as well as alveoli also was present. Cel-

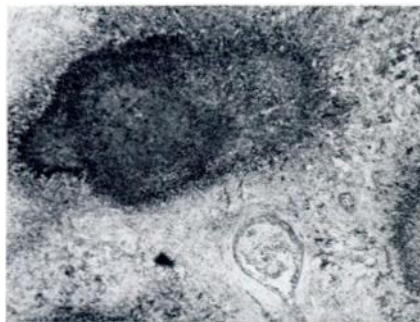

FIGURE 1. Granulomatous reaction surrounding *Aspergillus* hyphae in the lung of a crow. PAS positive hyphae are also present at the edge of the lesions, PAS X 75.

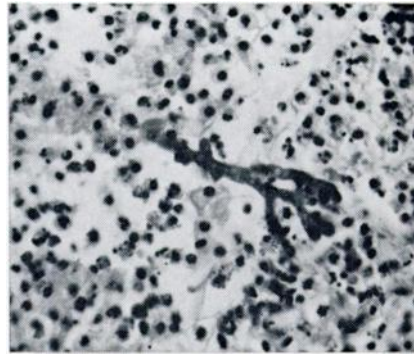


FIGURE 2. Diffuse pneumonia around an *Aspergillus* hypha in the lung of a crow, H and E X 565.

lular debris, fibrin, mucus and inflammatory cells occurred in these areas; both PAS and H and E staining revealed the presence of fungal hyphae (Fig. 2). Typical *Aspergillus* fruiting bodies were found in some of the larger airways, on the surface of the lungs, and on the air sacs. No acid-fast organisms were found in the livers or lungs.

### DISCUSSION

Although many species of birds are susceptible to aspergillosis,<sup>6</sup> the pathogenesis of the disease remains obscure. Factors such as stress, other diseases, contaminated food, excessive dust and low humidity have been implicated in the establishment and transmission of the disease.<sup>4</sup> In domestic birds, the mucus sheet covering the respiratory epithelium, and the epithelium's ciliary action, expel inhaled particles, including *Aspergillus* spores. Low humidity and excessive dust can compromise this system, thus allowing *Aspergillus* spores to proliferate and produce the disease.<sup>4</sup> Since the summer and fall of 1974 were quite dry in this area of Nebraska,<sup>5</sup> perhaps the action of the respiratory epithelium was inhibited by the low humidity and the disease developed after the birds had come into contact with the spores.

The source of the infectious fungus was not determined; the ubiquitous nature of the spores preclude finding the source. Conceivably the source could have been local or at some distance. The chronic nature of aspergillosis suggests that the crows would be able to travel some distance before becoming ill. Since this incident occurred during migration, the birds could have come from as far away as Saskatchewan, Canada.<sup>2</sup>

#### LITERATURE CITED

1. CLARK, G. M. 1960. Aspergillosis in naturally infected cowbirds and grackles. *Avian Dis.* 4: 94-96.
2. HOUSTON, C. S. 1971. Recoveries of the common crow banded in Saskatchewan. *Blue Jay* 27: 84-88.
3. LOCKE, L. N. 1965. Additional records of aspergillosis among passerine birds in Maryland and the Washington, D.C. metropolitan area. *Chesapeake Sci.* 6: 120-121.
4. McDOUGLE, H. E. and R. W. VAUGHT. 1968. An epizootic of aspergillosis in Canada geese. *J. Wildl. Manage.* 32: 415-417.
5. NATIONAL OCEANIC AND ATMOSPHERIC ADMINISTRATION, ENVIRONMENTAL DATA SERVICE, Asheville, N.C. Reports for May-November, 1974, for Nebraska.
6. O'MEARA, D. C. 1968. Unpublished data. Cited in O'Meara, D. C. and Witter, J. F. Aspergillosis. In: *Infectious and Parasitic Diseases of Wild Birds*. Ed. by J. W. Davis, R. C. Anderson, L. Karstad and D. O. Trainer. Iowa State Univ. Press, Ames, Iowa. p. 153-162.
7. ROSEN, M. N. 1964. Aspergillosis in wild and domestic birds. *Avian Dis.* 8: 1-6.

*Received for publication 25 October 1976*