

A FATAL CASE OF SALMONELLOSIS IN A DUGONG

Authors: ELLIOTT, HEATHER, THOMAS, ANNETTE, LADDS, P.W.,
and HEINSOHN, G.E.

Source: Journal of Wildlife Diseases, 17(2) : 203-208

Published By: Wildlife Disease Association

URL: <https://doi.org/10.7589/0090-3558-17.2.203>

The BioOne Digital Library (<https://bioone.org/>) provides worldwide distribution for more than 580 journals and eBooks from BioOne's community of over 150 nonprofit societies, research institutions, and university presses in the biological, ecological, and environmental sciences. The BioOne Digital Library encompasses the flagship aggregation BioOne Complete (<https://bioone.org/subscribe>), the BioOne Complete Archive (<https://bioone.org/archive>), and the BioOne eBooks program offerings ESA eBook Collection (<https://bioone.org/esa-ebooks>) and CSIRO Publishing BioSelect Collection (<https://bioone.org/csiro-ebooks>).

Your use of this PDF, the BioOne Digital Library, and all posted and associated content indicates your acceptance of BioOne's Terms of Use, available at www.bioone.org/terms-of-use.

Usage of BioOne Digital Library content is strictly limited to personal, educational, and non-commercial use. Commercial inquiries or rights and permissions requests should be directed to the individual publisher as copyright holder.

BioOne is an innovative nonprofit that sees sustainable scholarly publishing as an inherently collaborative enterprise connecting authors, nonprofit publishers, academic institutions, research libraries, and research funders in the common goal of maximizing access to critical research.

A FATAL CASE OF SALMONELLOSIS IN A DUGONG

HEATHER ELLIOTT, ¹ ANNETTE THOMAS, ² P.W. LADDIS ³ and G.E. HEINSOHN ⁴

Abstract: *Salmonella lohbruegge* was isolated from the kidney and the liver of a captive dugong calf (*Dugong dugon*) which died after an illness of at least several weeks. Clinical signs included diarrhoea and anorexia and were apparent for a week before death. Necropsy and histopathologic examination revealed thickening of the intestinal mucosa, epithelial degeneration, and epithelioid cell infiltration of mucosa, submucosa and contiguous smooth muscle. Enlargement of intestinal lymphoid tissue was apparent, and occasional focal granulomas were found in the liver. The source of the *Salmonella* infection was not ascertained.

INTRODUCTION

The dugong (*Dugong dugon*) is found in shallow tropical and subtropical waters in the Indo-West Pacific,^{4,9,13} and is unique in being the only herbivorous mammal restricted to the sea. It feeds chiefly on seagrasses of the Families Potamogetonaceae and Hydrocharitaceae.⁸ Dugongs rarely have been kept in captivity and most attempts to do so have been unsuccessful. Knowledge of diseases in sirenians (dugongs and manatees) is thus very limited, particularly when compared to some other marine mammals of the Orders Cetacea and Pinnipedia, where knowledge is increasing rapidly as a result of their closer contact with man.

This report describes a fatal case of salmonellosis in a captive dugong.

HISTORY

An unweaned female dugong, estimated to be approximately six months of age (H. Marsh, pers. comm.) and

weighing 69 kg, was accidentally trapped in a fishing net in Trinity Bay near Cairns, Australia, on 23 March 1978. It was immediately transferred to a marine aquarium, where it remained until its death on 31 July 1978.

The dugong was kept in a concrete pool (7.63 m × 15.25 m × 2.14 m) together with one loggerhead turtle (*Caretta caretta*), six hawksbill turtles (*Eretmochelys imbricata*) and about 20 marine fish of several species. The pool attendants swam in the pool daily while cleaning the walls, and up to four children also occasionally swam in it. The dugong was offered a diet of seagrass obtained from the Cairns Harbour into which effluent from two sewerage treatment plants and one abattoir is discharged. Fresh seawater from Cairns Harbour was pumped through a sand filter into the pool for several hours daily or on alternate days. Overflow water from the pool was held in settling tanks where it was dissipated by seepage. Occasionally, when seawater was considered to be too

¹ Department of Zoology, James Cook University of North Queensland, Townsville, Queensland 4811, Australia.

² Department of Primary Industries, Animal Health Station Oonoonba, Townsville, Queensland 4810, Australia.

³ Department of Tropical Veterinary Science, James Cook University of North Queensland, Townsville, Queensland 4811, Australia.

⁴ Present address: Faculty of Veterinary Science, University of Queensland, St. Lucia, Brisbane, Queensland 4067, Australia.

dirty (as a result of adverse weather or tidal factors), water from the settling tanks was pumped back into the pool. A trap constructed over the pool outlet prevented solid matter, including seagrass waste, from fouling the settling tanks.

Two to three weeks after capture, the dugong showed a decreasing interest in its surroundings, and this was reflected in its food intake. Approximately 2 kg of seagrass were consumed daily during the first three weeks of capture; this decreased to less than 0.5 kg daily. The dugong lost weight from the time of capture, dropping in weight from 69 kg on 3 April to 60.5 kg on 21 May. Its bodyweight stabilised after receiving full cream milk fortified with cereal, glucose and vitamins. The animal gradually adjusted to the pool, and consumption of seagrass increased, reaching a max-

imum of about 4 kg/day by six weeks before death, at which time very little milk was consumed.

Two weeks prior to death, mild lethargy and anorexia were noted for a period of two to three days. Apparent recovery ensued for several days, after which the animal relapsed. It became extremely lethargic, was disinterested in people and avoided being handled; its appetite was markedly reduced. Bottle feeding was recommended at this stage and continued until the day preceding death. One week before death the dugong was observed to be floating higher in the water than normal, exposing its full dorsal surface. Severe diarrhoea occurred during the last five days.

Signs of dehydration and weight loss were indicated by excess skin wrinkling anterior to the flippers. Two days before death, 90 cc of Hartman's solution were




FIGURE 1. Small intestine. Note adherence of some pseudomembrane (A), abnormal mucosa (B) with epithelial loss and fusion of villi, apparent thickening of the muscularis mucosa and submucosa by macrophage infiltration (C), and enlargement of a lymphoid follicle (D). H&E $\times 36$.

given subcutaneously along with 6 cc of a procaine penicillin dihydrostreptomycin preparation consisting of 200 mg and 250 mg/ml respectively.[□] The following day 300 mg of oxytetracycline[□] was administered intramuscularly. At this stage the dugong could not swim and was supported by either the pool attendant or a sling, until it died.

PATHOLOGIC FINDINGS

Prior freezing and thawing of the dugong carcass precluded a fully satisfactory examination. Macroscopically, there appeared to be some thickening of the intestines. Occasional pale foci up to 2 mm in diameter were present beneath the capsule of one kidney.

Microscopically, major changes were seen in the small intestine, where lesions were observed in sections of tissue derived from different locations: superficial coagulation necrosis with pseudomembrane formation; loss of epithelium; fusion of villi; microabscesses in crypts; marked epithelioid infiltration of the lamina propria, submucosa and contiguous smooth muscle; and enlargement of intestinal lymphoid tissue with epithelioid proliferation and central necrosis (Figures 1 and 2). In sections stained by the Gram-Twort method, occasional gram negative rods were identified in areas of epithelioid proliferation.

Occasional focal granulomas composed of pleomorphic epithelioid cells were present in the liver (Figure 3). Examination of the kidney failed to reveal changes responsible for the white foci observed grossly.

MICROBIOLOGY

Liver, lung and kidney tissues were submitted for microbiologic examina-

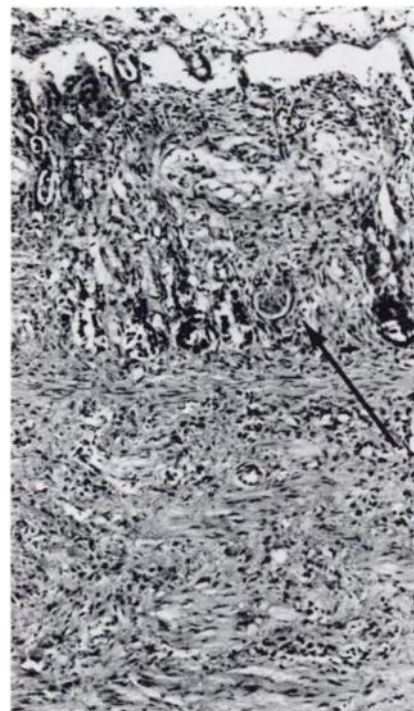

FIGURE 2. Higher magnification of mucosal-submucosal junction of small intestine as in Figure 1. Note marked epithelial loss with remnants in some crypts only, a crypt microabscess (arrow) and cellular accumulation in smooth muscle. H&E $\times 90$.

tion. They were cultured both aerobically and anaerobically at 37 C. A *Salmonella* sp. was isolated in pure culture from the liver and kidney samples and in a mixed culture with a *Pseudomonas* sp. and an α -haemolytic *Streptococcus* from the lung tissue. No anaerobes were isolated. The *Salmonella* was identified as *S. lohbruegge* by the Salmonella Reference Laboratory, Adelaide, South Australia.

[□] Depomycin injection: Pitman-Moore/Ethnor, 1-5 Khartoum Road, North Ryde, N.S.W., Australia.

[□] Duracycline: Ilium Products, Rydalmere, N.S.W., Australia.

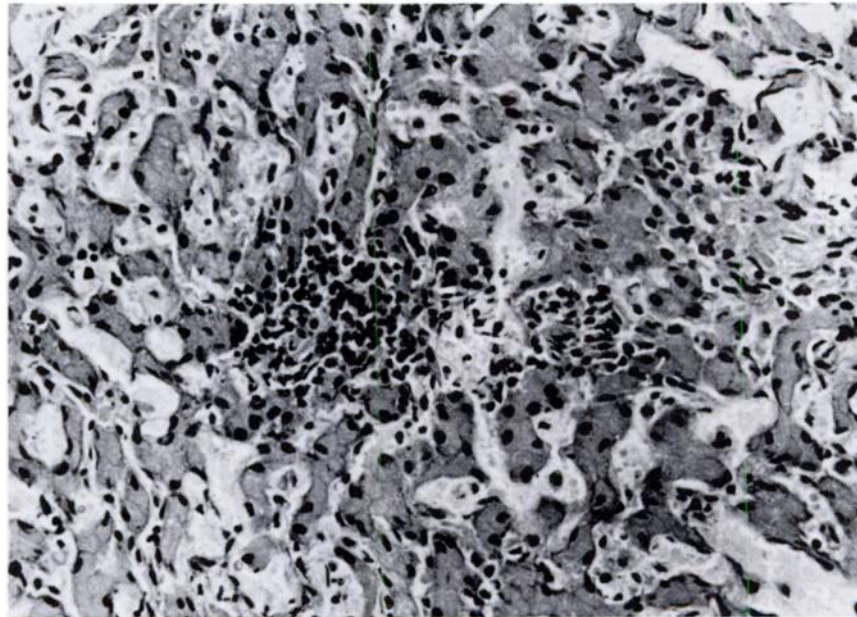


FIGURE 3. Focal granuloma resembling "paratyphoid" granulomas, characteristic of salmonellosis in other species. Poor cytology with apparent pyknosis of most nuclei was attributed to autolysis. H&E $\times 227$.

DISCUSSION

Dugongs have been held in captivity only rarely,^{1,3,7,11,12,16} and no definite records of infectious diseases have been found. There are at least seven reports on apparent causes of mortality in dugongs.^{1,3,7,16} Four appeared to have died from malnutrition,^{1,3} one from copper sulphate poisoning,¹⁶ and one from gastric impaction.¹ The reported causes of death are mostly anecdotal, and only two of the captive dugongs that died were reported to have indications of enteric disorders.¹

Although other marine mammals have been more thoroughly studied, information on cases of salmonellosis is meagre. Death from salmonellosis in a formula fed, orphaned manatee (*Trichechus manatus*) was reported by Jenkins (See: Brownell *et al.*⁶). *Salmonella* spp. have been isolated from other marine mam-

mals¹⁷ and may become the cause of disease problems. Salmonellosis caused by *S. enteritidis* may have contributed significantly to mortality of fur seal pups (*Callorhinus ursinus*).¹⁰ *S. typhimurium* has been recovered from the spleen and small intestine of a bottlenosed dolphin (*Tursiops truncatus*) that died in captivity.⁵ Needham¹⁵ reported that salmonellosis caused septicaemia in a hooded seal and bacillary dysentery in fur seals. Nakaya¹⁴ reported a bottlenosed whale (*Hyperoodon* sp.) infected with *S. enteritidis* and an outbreak of food poisoning in 172 persons who ate meat from the whale.

It is interesting to speculate on the origin of the serotype in the captive dugong considered here. In Australia, *S. lohbruegge* has been confirmed from humans, reptiles, sewage and abattoir effluent.² It is a comparatively rare

serotype in man and warm-blooded animals but is more common in reptiles (S. Dixon, pers. comm.). If it is presumed that the dugong was infected after its capture, possible sources of the organism were from a) other wildlife in the pool; b) humans; and c) contaminated food or water.

Irrespective of the source of *Salmonella* infection in the dugong, it seems that stress associated with introduction to a captive environment contributed to the disease becoming established. The concept of stress associated with captivity of wild animals is well recognised. Whatever the origin of the infection, the chronic intestinal lesions indicate that the dugong was infected by *S. lohbruegge* at an early stage of its captivity.

Microscopically, the changes observed in both intestine and liver in this dugong, are comparable to those seen in salmonellosis in domestic animals. These involve macrophage infiltration of the intestinal mucosa, reticulo-endothelial hyperplasia in lymphoid tissue and so-called "paratyphoid nodules" in the liver.¹⁸

The occurrence of such an enteric disease in captivity raises problems of management and public health which are not easily resolved. Circulation of water at a rate which might provide adequate dilution of fecal microflora of healthy animals could not be expected to cope with eliminating an enteric pathogen if it is excreted in large numbers as would be expected with some diarrhoea.

Acknowledgements

We especially wish to acknowledge the assistance of Mr. V. Oke and family of the Cairns Oceanarium, Cairns, Queensland. This work was financed in part by a grant from the Australian Research Grants Committee and a consultatory contract from the Australian National Parks and Wildlife Service.

LITERATURE CITED

1. ALLEN, J.F., M.M. LÉPES, I.T. BUDIARSO, SUMITRO and HAMMOND. 1976. Some observations on the biology of the dugong (*Dugong dugon*), from the waters of South Sulawesi. *Aquatic Mammals* 4: 33-48.
2. Anonymous. 1974, 1975, 1976, 1977. Annual Report of Salmonella Reference Laboratory, Adelaide, South Australia.
3. AUNG, S.H. 1967. A brief note on dugongs. *Int. Zoo Yearb.* 7: 221.
4. BERTRAM, G.C.L. and C.K.R. BERTRAM. 1973. The modern Sirenia: their distribution and status. *Linn. Soc. Lond., Biol. J.* 5: 297-338.
5. BROWN, D.H., R.W. MCINTYRE, C.A. DELLI QUADRI and R.J. SCHROEDER. 1960. Health problems of captive dolphins and seals. *J. Am. vet. med. Ass.* 137: 534-538.
6. BROWNELL, R.L. Jr., K. RALLS and R.R. REEVES. 1978. Report of the West Indian Manatee Workshop, Orlando, Florida, 27-29 March 1978, 37 pp.
7. HARRY, R.R. 1956. "Eugenie" the dugong mermaid. *Pacific Discovery* 9: 21-27.
8. HEINSOHN, G.E. and W.R. BIRCH. 1972. Food and feeding habits of the dugong, *Dugong dugon* (Erxleben) in northern Queensland, Australia. *Mammalia* 36: 414-422.
9. ———, J. WAKE, H. MARSH and A.V. SPAIN. 1977. The dugong *Dugong dugon* (Müller) in the seagrass system. *Aquaculture* 12: 235-248.

10. JELLISON, W.L. and C.M. KELSEY. 1958. Salmonellosis (bacillary dysentery) of fur seals. *J. Wildl. Manage.* 22: 199-200.
11. JONES, S. 1959. On a pair of captive dugongs *Dugong dugon* (Erxleben). *J. Mar. Biol. Ass., India* 1: 198-202.
12. KASUYA, T. and M. NISHIWAKI. 1978. On the age characteristics and anatomy of the tusk of *Dugong dugon*. *Sci. Rep. Whales Res. Inst.*, No. 30, 14 pp.
13. MARSH, H., A.V. SPAIN and G.E. HEINSOHN. 1978. Minireview. Physiology of the dugong. *Comp. Biochem. Physiol.* 61A: 159-168.
14. NAKAYA, R. 1950. *Salmonella enteritidis* in a whale. *Jap. Med. J.* 3: 279-280.
15. NEEDHAM, D.J. 1978. Diseases of marine animals. pp. 675-708. In: *Proceed. No. 36, Course for Veterinarians (The J.D. Stewart Course for 1978), Fauna Part B. Postgrad. Comm. in Vet. Sci., Univ. of Sydney*, 784 pp.
16. OKE, V.R. 1967. A brief note on the dugong, *Dugong dugon*, at Cairns Oceanarium. *Int. Zoo Yearb.* 7: 220-221.
17. RIDGWAY, S.H. 1972. Homeostasis in the aquatic environment. In: *Mammals of the Sea*. S.H. Ridgway, Ed., Thomas, Springfield, Ill. p. 704.
18. SMITH, H.A., T.C. JONES and R.D. HUNT. 1972. *Veterinary Pathology*. Lea and Febiger, Philadelphia. p. 605.

Received for publication 30 January 1980
