

Pathology Associated with a Natural *Edwardsiella ictaluri* Infection in Channel Catfish (*Ictalurus punctatus* Rafinesque) 1

Authors: Jarboe, H. H., Bowser, P. R., and Robinette, H. R.

Source: Journal of Wildlife Diseases, 20(4) : 352-354

Published By: Wildlife Disease Association

URL: <https://doi.org/10.7589/0090-3558-20.4.352>

The BioOne Digital Library (<https://bioone.org/>) provides worldwide distribution for more than 580 journals and eBooks from BioOne's community of over 150 nonprofit societies, research institutions, and university presses in the biological, ecological, and environmental sciences. The BioOne Digital Library encompasses the flagship aggregation BioOne Complete (<https://bioone.org/subscribe>), the BioOne Complete Archive (<https://bioone.org/archive>), and the BioOne eBooks program offerings ESA eBook Collection (<https://bioone.org/esa-ebooks>) and CSIRO Publishing BioSelect Collection (<https://bioone.org/csiro-ebooks>).

Your use of this PDF, the BioOne Digital Library, and all posted and associated content indicates your acceptance of BioOne's Terms of Use, available at www.bioone.org/terms-of-use.

Usage of BioOne Digital Library content is strictly limited to personal, educational, and non-commercial use. Commercial inquiries or rights and permissions requests should be directed to the individual publisher as copyright holder.

BioOne is an innovative nonprofit that sees sustainable scholarly publishing as an inherently collaborative enterprise connecting authors, nonprofit publishers, academic institutions, research libraries, and research funders in the common goal of maximizing access to critical research.

Pathology Associated with a Natural *Edwardsiella ictaluri* Infection in Channel Catfish (*Ictalurus punctatus* Rafinesque)¹

H. H. Jarboe,² P. R. Bowser,³ and H. R. Robinette,² Department of Wildlife and Fisheries,² Department of Animal Health Research,³ Mississippi Agricultural and Forestry Experiment Station and College of Veterinary Medicine,³ Mississippi State University, Mississippi State, Mississippi 39762, USA

Edwardsiella ictaluri was first described as a pathogen of channel catfish by Hawke (1979, J. Fish. Res. Board Can. 36: 1508-1512). Initially the bacterium was described as a previously unidentified species of *Edwardsiella* and the disease was referred to as enteric septicemia of catfish (ESC). The bacterium was characterized and given the name *Edwardsiella ictaluri* by Hawke et al. (1981, Int. J. Syst. Bacteriol. 31: 396-400). The purpose of this report is to provide a detailed clinical description of a natural epizootic of enteric septicemia of catfish.

An outbreak of ESC occurred in channel catfish held in ponds on the South Farm Research Unit, Mississippi Agricultural and Forestry Experiment Station, Mississippi State, Mississippi. Four ponds of a nine-pond nutrition experiment were affected. Each of the 0.04-ha ponds contained approximately 300 fish with a total fish weight of 121 kg. Water temperature during the epizootic (1 June to 31 June 1983) was 23.8 to 28.5 C.

Behavioral signs of affected fish included reduced feeding activity, listless swimming at the pond surface, spiralling, and occasional rapid swimming at the pond surface. A total of 14 fish showing clinical signs representative of the epizootic were collected and brought to the laboratory alive for examination. Clinical signs of affected fish included petechial hemor-

rhages around the mouth, pale gills, slight exophthalmia, and numerous circular white, slightly elevated epithelial lesions 1 to 10 mm in diameter (Fig. 1). Upon necropsy numerous petechial hemorrhages were found on the liver, intestine, adipose tissue, supporting mesenteries and abdominal serosa. The abdominal cavities contained a cloudy red fluid. The intestines also contained cloudy red fluid and were partially filled with gas. Moderate infestations by specimens of *Ambiphrya* sp., *Trichodina* sp. and *Trichophrya* sp. were observed on the gills. The bacterium *Edwardsiella ictaluri* was isolated on blood agar incubated at 25 C. *Edwardsiella ictaluri* was recovered from the posterior kidneys of all fish collected for examination. No other bacteria were isolated.

Tissues were fixed in neutral buffered 10% formalin, embedded in paraplast, sectioned (5 µm), stained with hematoxylin and eosin and examined for microscopic lesions. A moderate diffuse interlamellar tissue proliferation was observed in the gills. A few adjacent lamellae of the gills were fused. Such gill lesions could be associated with poor water quality or parasite infestation. At the site of the skin lesions, the epidermis was missing and a mild focal mononuclear infiltration was present in the underlying muscle myomeres. A severe multifocal mononuclear infiltration, primarily lymphocytes and macrophages, was observed in the liver (Fig. 2). This lesion was most pronounced in the pancreatic tissue surrounding the hepatic vasculature. Germinal centers of the anterior kidneys and spleen appeared

Received for publication 3 February 1984.

¹ Journal Contribution No. 5739 of the Mississippi Agricultural and Forestry Experiment Station.




FIGURE 1. Channel catfish from an epizootic caused by *Edwardsiella ictaluri* with numerous circular epithelial lesions.

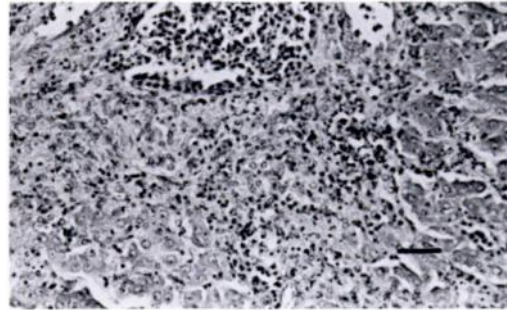


FIGURE 2. Severe multifocal lymphocytic infiltration in the liver of a channel catfish infected with *Edwardsiella ictaluri*. H&E, bar = 100 μ m.

depleted. Focal concentrations of siderophages were observed near the arteries of splenic capsules. A diffuse necrosis was observed in the interstitial tissue of the posterior kidneys. The mucosa and submucosa of the anterior portion of the intestine were diffusely necrotic and the villi of the anterior intestine appeared shortened. The mucosa and submucosa of the posterior portion of the intestine were diffusely necrotic. No lesions were observed in the brain. Microhematocrit values for eight moribund fish ranged from 3.7 to 33.0% (mean = 15.0%, SD = 10.6%). A normal value for channel catfish for this size of fish and time of year is 32.8%.

The bacterium was sensitive to oxytetracycline sensitivity discs placed on freshly streaked blood agar plates. Fish in all four ponds received an oxytetracycline treated feed at 2.5 g oxytetracycline/100 lb of fish/day for 10 days. Mortalities ceased in all ponds 4 to 10 days after commencement of the oxytetracycline treatment. The apparent success in antibiotic therapy may have been due in part to the increase in water temperature in the ponds above the 22–28 C range which has been observed in other *E. ictaluri* infections (J. R. MacMillan, pers. comm.). Three of the ponds also received a CuSO_4 treatment (0.75 mg/liter) to reduce protozoan parasite infestation on the gills. Examination of five fish per pond following the treatment revealed minor parasite intensities. Cumulative percent mortalities for the af-

ected ponds were 14.0, 12.4, 12.4, and 6.0%.

The clinical signs were fairly consistent in the four affected pond populations of catfish. We did not observe the open lesion in the fontanelle of the frontal bone of the skull reported by Hawke (1979, op. cit.). Hawke suggested that the lesion on the skull may be less commonly observed on fish larger than 15 cm. All fish involved in this present report had a total length in excess of 35 cm. Intestinal lesions were observed in fish we examined. This finding together with that of Areechan and Plumb (1983, J. World Maricult. Soc. In press), in which no intestinal lesions were observed in fingerling channel catfish injected intraperitoneally with 2.0×10^4 *Edwardsiella ictaluri* cells, suggest the route of challenge may contribute to a variation in clinical signs.

In evaluating the clinical findings, we concluded that the most probable cause of mortalities was *Edwardsiella ictaluri*. Although external protozoa may have been a contributing factor, we did not judge the degree of infestation to be severe enough to warrant consideration as a major factor. Our plan for therapy included a CuSO_4 treatment for the protozoa to prevent an increase in severity of infestation to the point where the fish might become anorectic and would not receive any benefit from the oxytetracycline added to the ra-

tion. Under commercial production conditions the CuSO₄ treatment would have likely been judged unnecessary and not cost effective. Under the circumstances of the epizootic we took all action we felt appropriate to avoid the loss of the experiment in the ponds.

We acknowledge the assistance provided by Dr. C. P. McCoy, College of Veterinary Medicine, Mississippi State University, in the evaluation of samples prepared for histological examination.

Journal of Wildlife Diseases, 20(4), 1984, pp. 354–357
© Wildlife Disease Association 1984

Cyclopia, Congenital Limb Deformity, and Osteomyelitis in the Collared Peccary, *Tayassu tajacu* (L.)

E. C. Hellgren,¹ R. L. Lochmiller,¹ M. W. Thomas,² and W. E. Grant,¹ ¹Department of Wildlife and Fisheries Sciences, Texas A&M University, College Station, Texas 77843, USA, and ²Department of Large Animal Medicine and Surgery, College of Veterinary Medicine, Texas A&M University, College Station, Texas 77843, USA

The collared peccary is a social ungulate and the sole member of the family Tayassuidae in North America. Knowledge of this species' natural history has increased in recent years (for reviews, see Sows, 1978, *In Big Game of North America*, Schmidt and Gilbert (eds.), Stackpole Books, Harrisburg, Pennsylvania, pp. 191–205; Bissonette, 1982, *In Wild Mammals of North America*, Chapman and Feldhamer (eds.), John Hopkins University Press, Baltimore, Maryland, pp. 841–850). Pathology of the collared peccary remains one of the least studied aspects of its biology. Indeed, with the exception of the description of anomalous canine tooth development in a peccary in Arizona (Neal and Kirkpatrick, 1957, *J. Mammal.* 38: 420), skeletal anomalies have not been reported. This paper reports skeletal lesions in three wild and captive peccaries from southern Texas.

Cyclopia refers to a gross malformation of the central nervous system characterized by a single, median orbital fossa. Eyeballs may be absent or ranging from a single, almost perfect eyeball through all

degrees of doubling to two complete, closely adjacent globes of reduced size (Potter and Craig, 1975, *Pathology of the Foetus and the Infant*, Yearbook Medical Publishers, Chicago, 697 pp.; Morison, 1970, *Foetal and Neonatal Pathology*, Appleton-Century-Crofts, New York, 641 pp.). In cases where two eyes are present in varying degrees of fusion, the condition may also be termed synophthalmos (Yanoff and Fine, 1975, *Ocular Pathology*, Harper and Row, Hagerstown, Maryland, 748 pp.). This malformation is not uncommon among domestic animals, especially swine, which are the closest taxonomic relatives of peccaries. Cyclopia has been observed in three piglets of a litter of eight (Potter and Craig, 1975, *op. cit.*). To our knowledge, a report by Bubenik (1982, *Saugetierk. Mitt.* 30: 158–160) on cyclopia in a male white-tailed deer fawn (*Odocoileus virginianus* (Zimmermann)) is the only such report of this anomaly in a wild ungulate species.

Between September 1981 and July 1983, captive collared peccaries housed in a 30-m-square enclosure on the campus of Texas A&M University farrowed 57 young in 32 litters (Lochmiller et al., 1984, *Zoo Biol.* In press). In June 1983, a female peccary

Received for publication 9 December 1983.