

Tuberculous Osteomyelitis Caused by *Mycobacterium* intracellulars in the Brush-tailed Bettong

Authors: Richardson, Kenneth C., and Read, Richard A.

Source: Journal of Wildlife Diseases, 22(3) : 425-429

Published By: Wildlife Disease Association

URL: <https://doi.org/10.7589/0090-3558-22.3.425>

The BioOne Digital Library (<https://bioone.org/>) provides worldwide distribution for more than 580 journals and eBooks from BioOne's community of over 150 nonprofit societies, research institutions, and university presses in the biological, ecological, and environmental sciences. The BioOne Digital Library encompasses the flagship aggregation BioOne Complete (<https://bioone.org/subscribe>), the BioOne Complete Archive (<https://bioone.org/archive>), and the BioOne eBooks program offerings ESA eBook Collection (<https://bioone.org/esa-ebooks>) and CSIRO Publishing BioSelect Collection (<https://bioone.org/csiro-ebooks>).

Your use of this PDF, the BioOne Digital Library, and all posted and associated content indicates your acceptance of BioOne's Terms of Use, available at www.bioone.org/terms-of-use.

Usage of BioOne Digital Library content is strictly limited to personal, educational, and non-commercial use. Commercial inquiries or rights and permissions requests should be directed to the individual publisher as copyright holder.

BioOne is an innovative nonprofit that sees sustainable scholarly publishing as an inherently collaborative enterprise connecting authors, nonprofit publishers, academic institutions, research libraries, and research funders in the common goal of maximizing access to critical research.

Tuberculous Osteomyelitis Caused by *Mycobacterium intracellulare* in the Brush-tailed Bettong

Kenneth C. Richardson and Richard A. Read, School of Veterinary Studies, Murdoch University, Murdoch, Western Australia 6150, Australia

The brush-tailed bettong (*Bettongia penicillata*) is a rare and endangered species of small kangaroo found in a few isolated areas of southwestern Australia and Queensland (Christensen, 1983, Complete Book of Australian Mammals, Angus and Robertson, Sydney, Australia, pp. 184-185). These animals weigh about 1 kg and are unusual in that their natural diet is thought to be principally the fruiting bodies of fungi supplemented with tubers, seeds and insects (Christensen, 1983, Forests Dept. West. Aust. Bull. 91: 1-90).

There has been some breeding success when these animals were maintained in small enclosures. Occasionally captive bettongs and other small marsupials (i.e., bandicoots *Perameles* spp.) developed swollen hock joints that resulted in chronic lameness. This paper documents a case of chronic lameness in the hock joints of a bettong; the tail and the digits of the forelimb were also involved.

Four bettongs were kept for 3 yr in a totally enclosed outside pen which had a concrete pad 3 × 4 m at one end adjoining a run of 6 × 4 m with a deep sand floor. Food and water were provided on the concrete pad. One bettong developed a firm swelling of the left hock joint (Fig. 1). This was treated by intramuscular injection of a benzathine penicillin/procaine penicillin suspension over a 10-day period and the swelling diminished.

Eight wk later the swelling recurred and resulted in lameness. The swelling was firm for 2-3 cm both above and below the hock

joint. There were several soft circular swellings each of about 8 mm in diameter over the immediate area of the hock joint. Two of these swellings were lanced, purulent material was expressed and the cavity swabbed for bacteriologic culture and its sensitivity tested. *Staphylococcus aureus* was cultured and the bettong was then treated for 10 days with procaine penicillin G. The swelling only subsided slightly so a second 2-wk course of penicillin was implemented.

Two mo later there was a similar swelling in the middle of the tail. Radiographs were taken of the left hock joint and the tail and these revealed osteolysis with multiple circular radiolucent areas present (Fig. 2). There was destruction of the articular surfaces of the hock joints and one of the intervertebral joints of the tail. Culture of the hock joint revealed *Proteus mirabilis* and *Staphylococcus epidermidis*. There was no response to a course of treatment with streptomycin. Hematologic findings at this stage were normal apart from a moderate mature neutrophilia.

After a further 2 mo, similar lesions had developed in the right hock joint and the phalanges of both forefeet. Because of the severe destructive nature of these lesions as seen on radiography, the bettong was euthanized. Whole body radiography revealed that the bony lesions were confined to the hock joints, tail and forefeet.

On postmortem examination, the carcass was in good condition. The pathologic findings were restricted to the areas surrounding the lesions. In these areas the bone was extensively eroded and replaced with a mixture of fibrous tissue and thick,

Received for publication 21 August 1985.




FIGURE 1. An adult brush-tailed bettong with multiple swellings around the hock joint.

white purulent exudate (Fig. 3). In several areas the lesion extended through all layers of the surrounding soft tissue, with occasional ulceration through the skin. In the left hock joint, the infection had tracked up the sheath of the gastrocnemius tendon and a purulent exudate was found at the musculotendinous junction. The lymph nodes that drained all the affected areas appeared normal.

Bacteriologic specimens were taken from the depths of the lesions in both hock joints and from the lesion in the gastrocnemius muscle. Blocks of bone from both hock joints, the tail and a forefoot were fixed in formalin and then decalcified in formic acid. Sections were prepared by routine histologic methods and stained with hematoxylin and eosin and by the modified Ziehl-Neelsen technique. Additional sections from the left gastrocnemius muscle were fixed, processed and stained

as above. Direct aerobic and anaerobic cultures were negative. *Staphylococcus epidermidis* was identified from two samples which were enriched in cooked meat medium. Cultures for fungi and mycoplasmas were negative. An acid-fast bacillus was cultured after 3 wk on mycobacterial media (B83 and a GE6) and identified as *Mycobacterium intracellulare*.

Microscopic sections of the hock joints, tail and forefoot revealed extensive osteolysis surrounded by an intense pyogranulomatous reaction (Fig. 4).

There were areas of caseation surrounded by a dense reactive zone of macrophages and a mixture of neutrophils, lymphocytes and plasma cells. Large numbers of acid-fast bacilli were demonstrated in these areas when stained with the Ziehl-Neelsen technique. In both hock joints the articular surfaces and subchon-

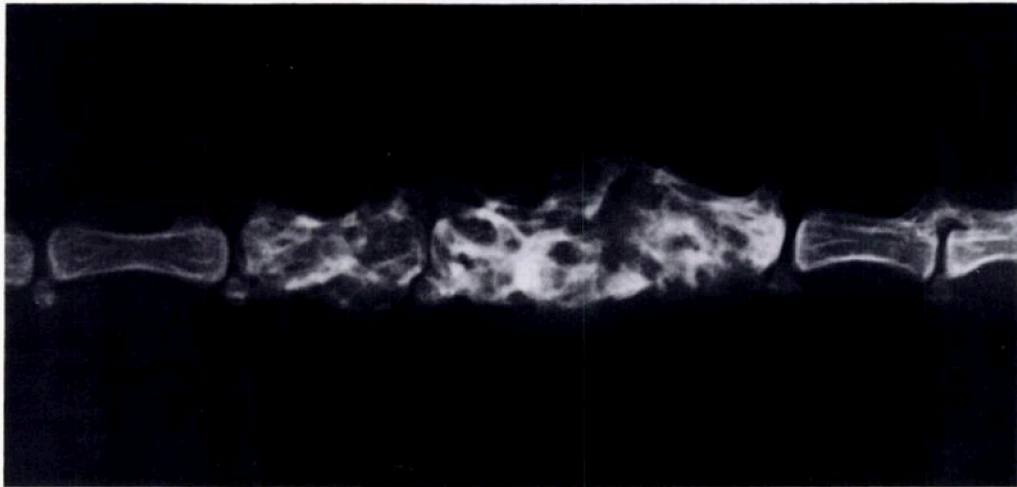


FIGURE 2. A lateral radiograph of the tail of a brush-tailed bettong showing extensive bone destruction and remodelling of three coccygeal vertebrae.

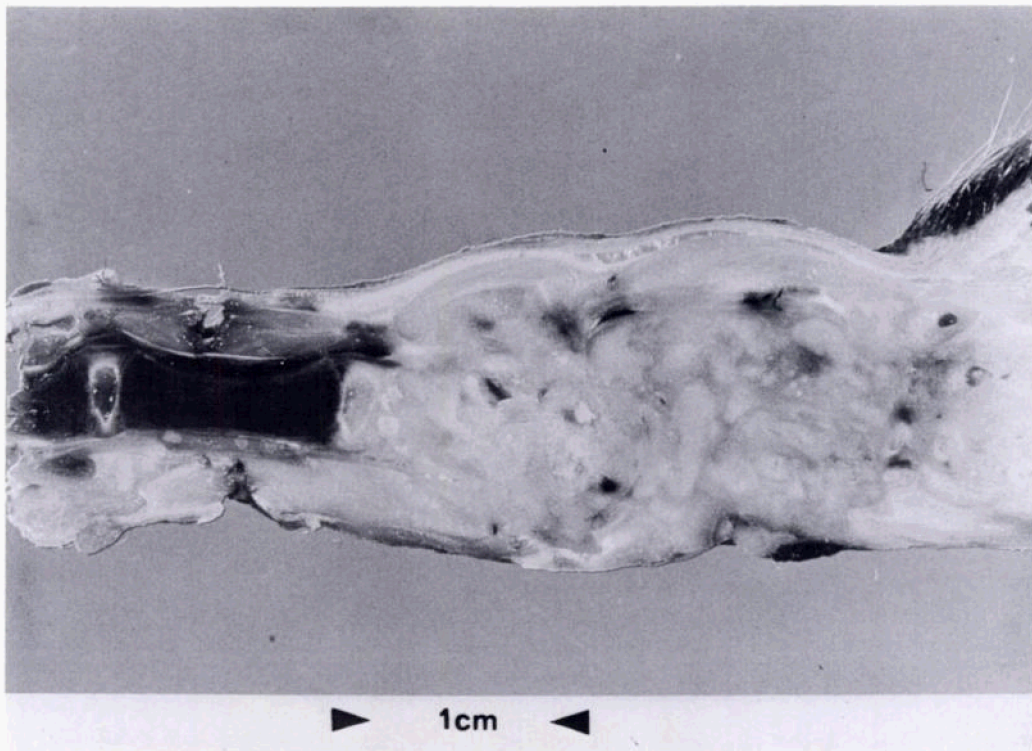


FIGURE 3. A longitudinal section of the same region of the tail of a brush-tailed bettong as in Figure 2. In addition to the generalized swelling, there is an admixture of fibrous tissue and caseous material as well as the absence of recognizable bone.

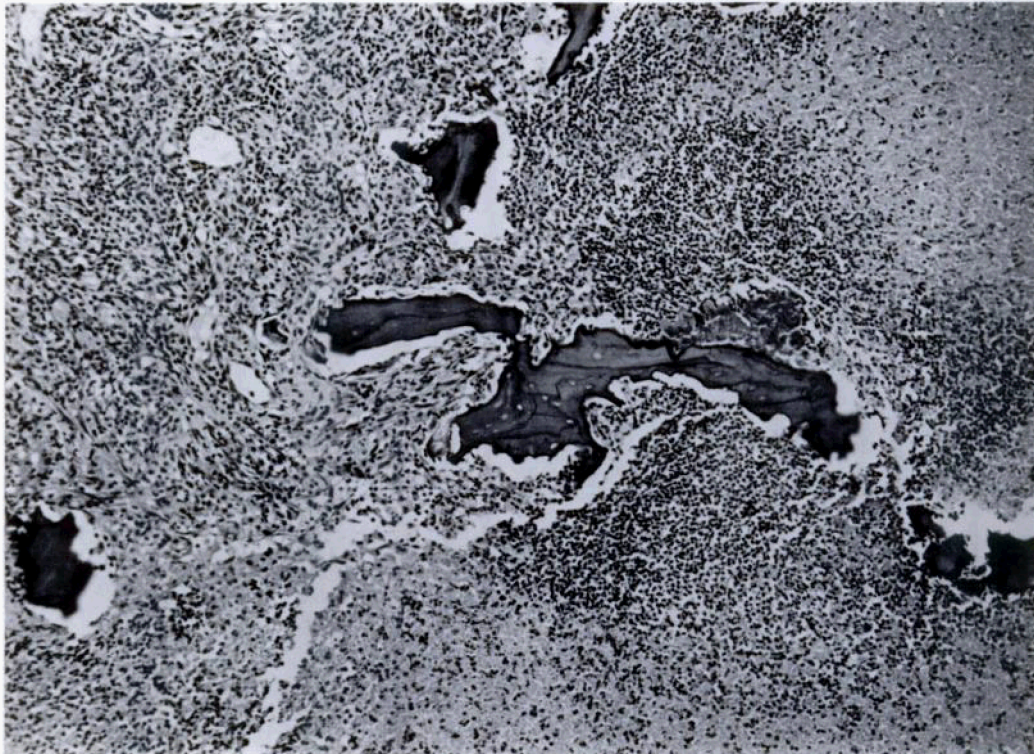


FIGURE 4. Remnants of necrotic bone surrounded by caseation and a dense zone of macrophages in the affected tail of a brush-tailed bettong. H & E, $\times 90$.

dral bone were severely eroded; it was difficult to determine where the joint spaces had been. Small fragments of necrotic bone were still present in some areas, but there was no evidence of osteogenesis, even at the periphery of the lesions. Sections of the gastrocnemius muscle also revealed extensive caseation surrounded by a similar pyogranulomatous reaction containing acid-fast bacilli.

Naturally occurring tuberculosis principally affecting the viscera was reported in the rat kangaroo (*Aepyprymnus rufescens*) (Lucas, 1925, J. Pathol. Bacteriol. 28: 123–124). Barker et al. (1963, Vet. Bull. 33: 539–544) reviewed the occurrence of a number of diseases in marsupials. They reported that *Mycobacterium avium* was the cause of most tuberculous lesions in kangaroos. An atypical mycobacterial in-

fection in two quokkas (*Setonix brachyurus*) resulted in encapsulated granulomatous lesions in the thorax of one animal and similar lesions in the mesenteries of the other (Kakulas, 1964, Aust. J. Sci. 27: 115–116).

In the brush-tailed possum (*Trichosurus vulpecula*) *Mycobacterium bovis* was a common causal agent of visceral tuberculosis in wild animals in New Zealand (Ekdahl et al., 1970, N.Z. Vet. J. 18: 44–45), but was virtually absent in Australian populations (Corner and Presidente, 1980, Vet. Microbiol. 5: 309–321).

Mycobacterium intracellulare has been found rarely in marsupials. Moore et al. (1961, J. Infect. Dis. 123: 569–578) reported that it caused a proliferative pneumonitis and caseous lesions of the mesenteric lymph nodes, spleen and liver of the

opossum, *Didelphis marsupialis virginiana*.

Mycobacterial infection in marsupials principally affecting the musculoskeletal system has not been reported previously. The osseous lesions were typical of tuberculous osteomyelitis (skeletal tuberculosis) in man and other species (Murray and Jacobson, 1977, *The Radiology of Skeletal Disorders*, Churchill Livingstone, New York, 2,033 pp.). The infection usually begins in cancellous bone and in man, vertebral lesions are the most common. The lesions are destructive with occasional sequestrum formation. Involvement of major joints is also common in man, with gradual destruction of articular surfaces and invasion of adjacent bone (Murray and Jacobson, 1977, op. cit.). The formation of caseous abscesses frequently leads to necrosis of the overlying skin and secondary infection. This occurred in the present case since *Proteus mirabilis* and *Staphylococcus epidermidis* were isolated from cultures of the affected areas. In man, as the infection subsides, reactive sclerosis develops, but in the bettong the lesions were progressing actively and there was no radiographic evidence of a reactive sclerotic zone. There was also no histologic evidence of new bone formation around the periphery of the lesions. Absence of regenerative osteophyte formation is typical of skeletal tuberculosis in animals, as is the spread of the infection into surrounding soft tissues as seen in this case (Jubb et al., 1985, *Pathology of Domestic Animals*, 3rd Ed., Vol. 1, Academic Press, Inc., New York, 574 pp.).

Skeletal tuberculosis in man is believed to be caused by hematogenous spread from a primary focus (Murray and Jacobson, 1977, op. cit.). Some strains of *M. intracellulare* cause abscesses in and around the

joints of rabbits when inoculated intravenously (Armstrong et al., 1967, *Am. Rev. Respir. Dis.* 95: 20-32). These lesions are characterized by granuloma formation and osteolysis as well as necrotizing tendinitis and bursitis. The lesions in this bettong were all located in weight-bearing areas and hence were possibly sites subject to superficial abrasion, particularly on the concrete pad at one end of the run. It is postulated that the organism gained entry via this route. This hypothesis is supported by the finding that animals kept in naturally grassed enclosures at a number of zoos have not developed lesions of this nature, nor have they been found in wild-caught animals. However, it is also possible that the multiple lesions resulted from hematogenous spread from a primary focus. Although no such primary lesion was found on postmortem examination, the original lesion in the left hock joint may have been the primary source for hematogenous spread to other sites.

The current environmental conditions in Perth may favor the proliferation and spread of mycobacterial infections of animals. Over the recent 12 mo four cases (two cats and two dogs) of panniculitis caused by *Mycobacterium smegmatis* have been confirmed in the Murdoch University Veterinary Hospital. It is possible that many more cases of mycobacterial infection causing chronic lamenesses in marsupials may have escaped diagnosis due to failure to use specific mycobacterial culture techniques.

Financial support for this research was provided by the E. A. Weston and I. E. Fernie Research Fund and by a Special Research Grant from Murdoch University. We appreciate the assistance of John Atherton, Geoff Griffiths and Judy Robertson.