

PATHOGENESIS OF INFECTION WITH SARCOCYSTIS RAUSCHORUM (APICOMPLEXA) IN EXPERIMENTALLY INFECTED VARYING LEMMINGS (DICROSTONYX RICHARDSONI)

Authors: Stackhouse, L. L., Cawthorn, R. J., and Brooks, R. J.

Source: Journal of Wildlife Diseases, 23(4) : 566-571

Published By: Wildlife Disease Association

URL: <https://doi.org/10.7589/0090-3558-23.4.566>

The BioOne Digital Library (<https://bioone.org/>) provides worldwide distribution for more than 580 journals and eBooks from BioOne's community of over 150 nonprofit societies, research institutions, and university presses in the biological, ecological, and environmental sciences. The BioOne Digital Library encompasses the flagship aggregation BioOne Complete (<https://bioone.org/subscribe>), the BioOne Complete Archive (<https://bioone.org/archive>), and the BioOne eBooks program offerings ESA eBook Collection (<https://bioone.org/esa-ebooks>) and CSIRO Publishing BioSelect Collection (<https://bioone.org/csiro-ebooks>).

Your use of this PDF, the BioOne Digital Library, and all posted and associated content indicates your acceptance of BioOne's Terms of Use, available at www.bioone.org/terms-of-use.

Usage of BioOne Digital Library content is strictly limited to personal, educational, and non-commercial use. Commercial inquiries or rights and permissions requests should be directed to the individual publisher as copyright holder.

BioOne is an innovative nonprofit that sees sustainable scholarly publishing as an inherently collaborative enterprise connecting authors, nonprofit publishers, academic institutions, research libraries, and research funders in the common goal of maximizing access to critical research.

PATHOGENESIS OF INFECTION WITH *SARCOCYSTIS RAUSCHORUM* (APICOMPLEXA) IN EXPERIMENTALLY INFECTED VARYING LEMMINGS (*DICROSTONYX RICHARDSONI*)

L. L. Stackhouse,¹ R. J. Cawthorn,^{2,4} and R. J. Brooks³

¹ Veterinary Diagnostic Laboratory, Department of Livestock, P.O. Box 997, Bozeman, Montana 59711, USA

² Department of Veterinary Microbiology, Western College of Veterinary Medicine, University of Saskatchewan, Saskatchewan, Canada S7N 0W0

³ Department of Zoology, College of Biological Science, University of Guelph, Guelph, Ontario, Canada N1G 2W1

⁴ Present address: Department of Pathology and Microbiology, Atlantic Veterinary College, University of Prince Edward Island, Charlottetown, Prince Edward Island, Canada C1A 4P3

ABSTRACT: This study describes the sequential formation of lesions associated with the endogenous development of *Sarcocystis rauschorum* (Apicomplexa: Sarcocystidae) in varying lemmings, *Dicrostonyx richardsoni*. Lethal doses of sporocysts (>500) were orally administered to lemmings examined 1–6 days postinoculation (DPI) whereas sublethal doses were administered to lemmings examined subsequently. Transient necrosis and purulent inflammation, in association with precystic merogony, occurred in the liver by 4.5 DPI, peaked at 6 DPI and subsided beginning at 11 DPI with the liver returning to normal by 15 DPI. Cyst formation in skeletal and cardiac muscle was associated with purulent inflammation and sarcolemmal proliferation beginning at 9 DPI. These lesions persisted to 42 DPI. In addition, multifocal nonsuppurative meningoencephalitis was present in six of 11 infected lemmings examined between 11 and 15 DPI.

Key words: *Sarcocystis rauschorum*, pathology, experimental infection, varying lemmings, *Dicrostonyx richardsoni*.

INTRODUCTION

Endogenous development of *Sarcocystis rauschorum* (Apicomplexa: Sarcocystidae) in the varying lemming (*Dicrostonyx richardsoni*) has been documented recently (Cawthorn et al., 1984; Cawthorn and Brooks, 1985). A single cycle of precystic merogony occurred in hepatocytes between 4 and 6 days postinoculation (DPI). Infections may be lethal to lemmings even when sporocyst dose rates are relatively low. Cyst formation occurred subsequently in striated muscle as early as 9 DPI, but rarely in cardiac muscle. Other species of *Sarcocystis* utilizing rodents as intermediate hosts and raptorial birds as definitive hosts have been found to cause disease in the intermediate hosts (reviewed by Cawthorn et al., 1984). The purpose of the present study was to describe, at the light microscopic level, lesions associated with precystic merogony and cyst development of *S. rauschorum* in experimentally infected varying lemmings.

MATERIALS AND METHODS

Sporocysts of *S. rauschorum* were obtained from the intestinal mucosa of a snowy owl (*Nyctea scandiaca*), and prepared for inoculation as reported previously (Cawthorn et al., 1984). Varying lemmings were obtained from breeding colonies at the University of Guelph (Guelph, Ontario, Canada N1G 2W1) and were maintained as described earlier (Cawthorn et al., 1984).

One group of eight lemmings was inoculated orally with 10,000 sporocysts each and the lemmings were killed sequentially 1, 2, 3, 3.5, 4, 4.5, 5, 5.5 and 6 days postinoculation (DPI). A second group of 16 lemmings was inoculated with 500 sporocysts each. They were killed at 6, 7, 8, 9, 9.5, 10, 10.5, 11, 11.5, 12, 12.5, 13, 13.5, 14, 14.5 and 15 DPI. Five lemmings were used as uninfected controls and killed at 3, 6, 9, 12 and 15 DPI. An additional group of lemmings was inoculated with sporocysts varying in dosages from 250 to 100,000 sporocysts per animal. Members of this group were sacrificed at intervals up to 150 DPI and examined for skeletal and cardiac muscle changes only.

Lemmings were killed with an overdose of halothane (Fluothane, Fort Dodge Laboratories, Inc., 800 Fifth Street, N.W., Fort Dodge, Iowa

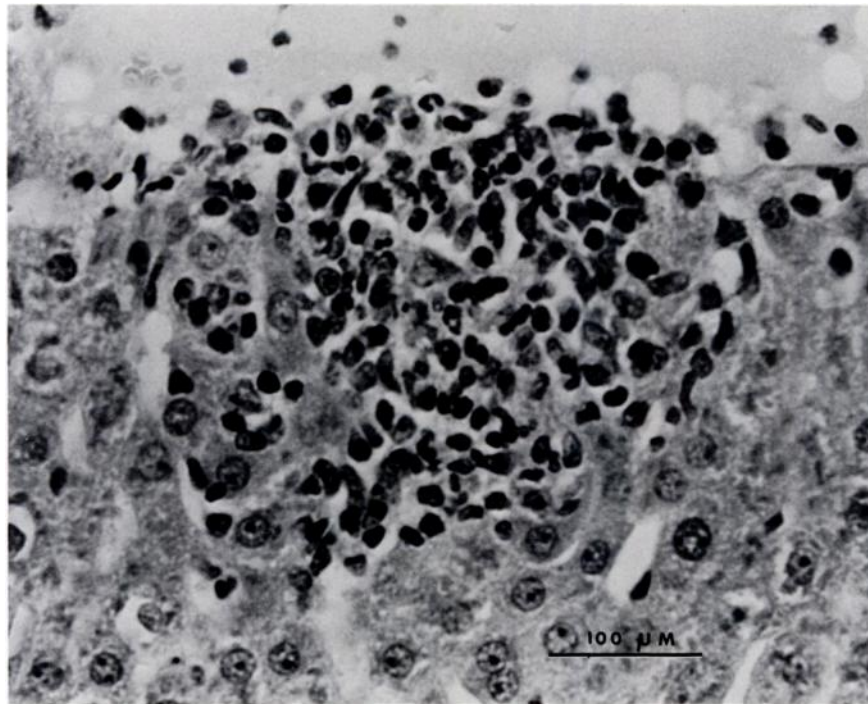


FIGURE 1. Focal infiltrate of mixed leukocytes adjacent to a central vein in the liver of a lemming at 4.5 DPI. H&E.

50501, USA) and portions of the following tissues were fixed in 10% neutral buffered formalin: eye, brain, tongue, thymus, oesophagus, heart, lung, liver, adrenal, kidney, spleen, urinary bladder, gonads, pancreas, stomach, duodenum, jejunum, ileum, colon, rectum, brown fat, diaphragm and skeletal muscle from various locations. Tissues were embedded in paraffin, cut at 5 μ m thickness and stained with hematoxylin and eosin.

RESULTS

Lemmings inoculated with <500 sporocysts did not display any clinical illness whereas those inoculated with \geq 500 sporocysts exhibited severe signs of weakness and ataxia beginning at 5–6 DPI. The lemmings became moribund and died approximately 12 hr after the onset of clinical disease.

In lemmings which died or were killed when moribund at 5.5 and 6 DPI, the livers were enlarged and coalescing white foci were visible on the capsular surface and

throughout the parenchyma on the cut surface.

Histopathologic changes were detected in the liver, heart, skeletal muscle and brain of lemmings examined between 4.5 and 9 DPI. No significant lesions were detected in the other tissues examined.

The earliest detectable lesions were limited to the liver and occurred at 4.5 DPI. These were characterized by small multifocal accumulations of histiocytes, lymphocytes and neutrophils (Fig. 1). While randomly distributed throughout the hepatic lobule, there was a slight predilection for these to occur adjacent to central veins and portal areas. By 5 DPI, the number and size of these inflammatory foci had increased. At this time, necrosis was evident and neutrophils predominated. Mature meronts of *S. rauschorum* were numerous and in proximity to the inflammatory foci (Fig. 2). The most intense reaction was present at 6 DPI. Purulent foci were scat-

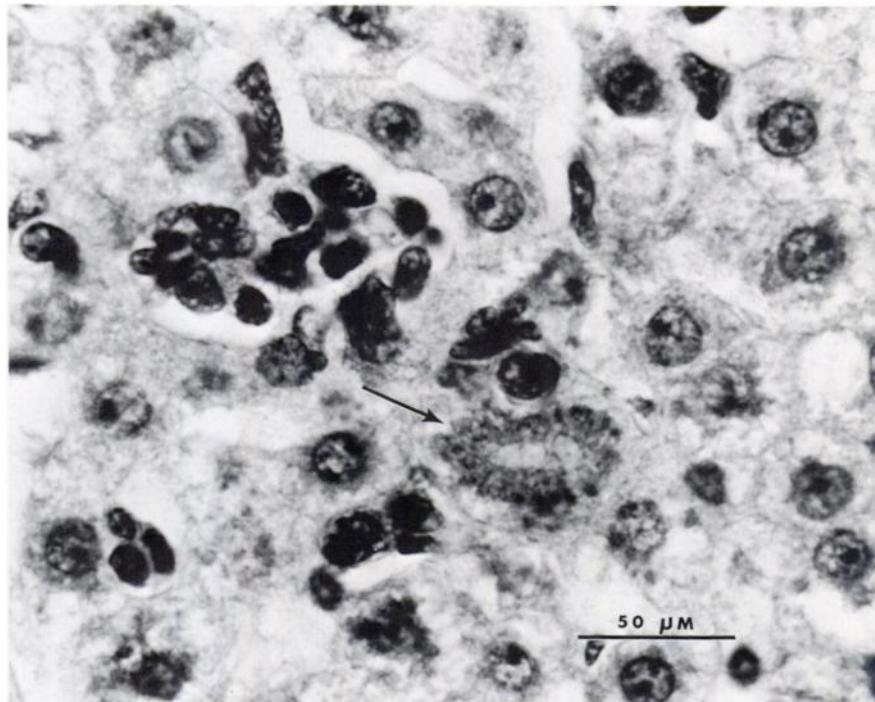


FIGURE 2. Mature meront (arrow) of *Sarcocystis rauschorum* adjacent to a focus of leukocytic infiltration in the liver. Lemming at 5 DPI. H&E.

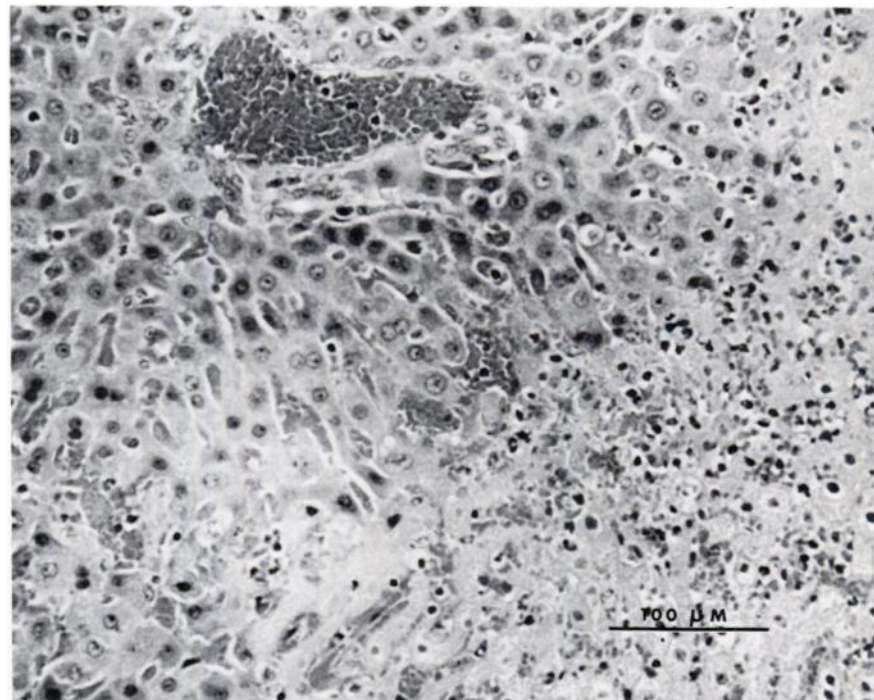


FIGURE 3. Coalescing foci of hepatic necrosis at 6 DPI. H&E.

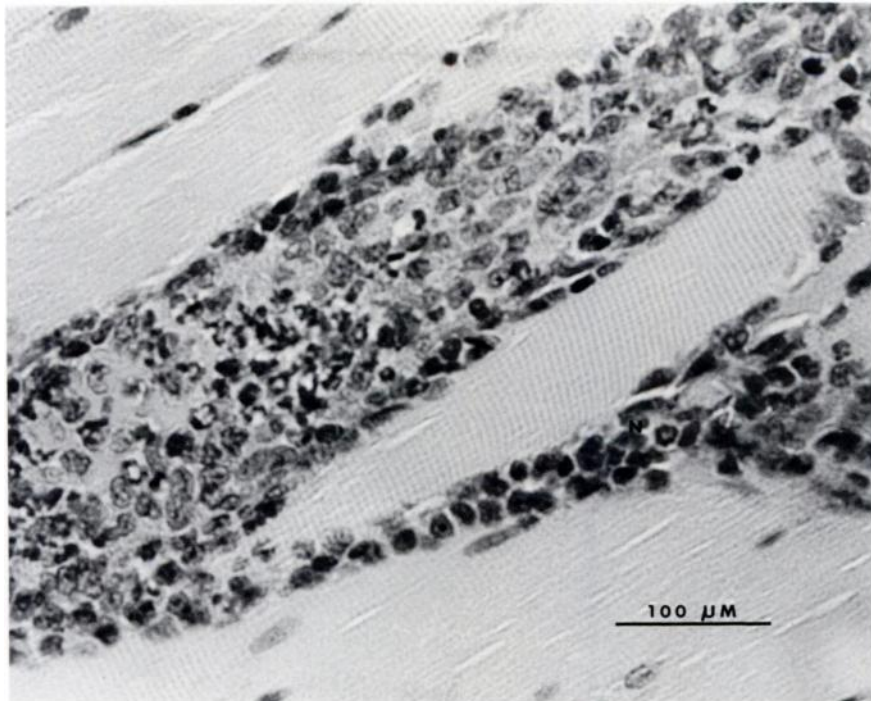


FIGURE 4. Necrosis of myofiber and mixed leukocytic infiltrate in a lemming at 9 DPI. H&E.




FIGURE 5. Myositis associated with cysts of *Sarcocystis rauschorum* at 11 DPI. H&E.

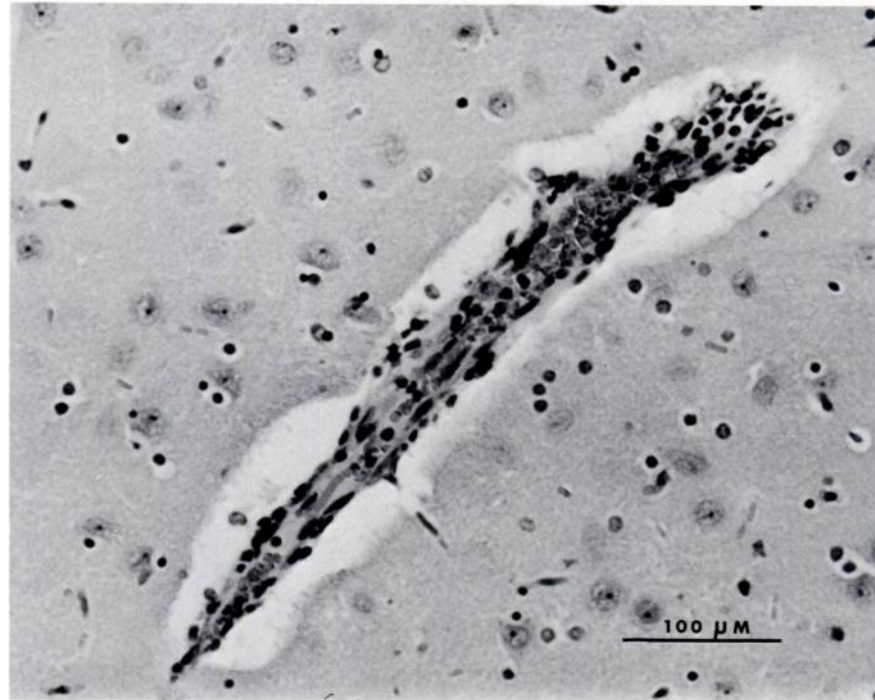


FIGURE 6. Perivascular cuff of mononuclear cells in the cerebrum of a lemming at 11 DPI. H&E.

tered throughout the liver and occasionally coalesced to form large zones of necrosis (Fig. 3). Inflammation began to subside by 11 DPI and the liver returned to a near normal appearance by 15 DPI. Significant lesions were not seen in the control animals killed during this period.

At 9 DPI, skeletal muscle contained multifocal areas of necrosis and mixed cellular infiltrates (Fig. 4). Similar changes were seen in all skeletal muscles examined. The cellular reactions were characterized by moderate numbers of neutrophils, histiocytes and lymphocytes. There was moderate hyperplasia and hypertrophy of sarcolemmal nuclei. Cardiac muscle had a similar, but less intense, inflammatory reaction. A few cysts of *S. rauschorum* were present primarily in skeletal muscle at 9 DPI and they were quite numerous by 11 DPI (Fig. 5). The most intense inflammatory reaction was present between 15 and 21 DPI. By 30 DPI, the inflammatory reaction had substantially subsided. Cysts

were still present at 150 DPI with very few leukocytes present. Significant lesions were not seen in the control animals killed during this period.

Lesions were observed in six of 11 brains from animals killed after 11 DPI. Small inflammatory foci were randomly distributed throughout the brain and they were characterized by endothelial cell swelling and perivascular cuffs of mononuclear cells (Fig. 6). In all instances, the reaction was mild and no etiologic agent was identified. Significant lesions were not seen in the control animals killed during this period.

DISCUSSION

The sequential development of hepatic and muscular lesions, observed in the present study, paralleled previous observations on precystic merogony and cyst formation of *S. rauschorum* in varying lemmings (Cawthorn and Brooks, 1985). The extent of the lesions would be sufficient in themselves to explain the lethal effects of the

infections established by doses of >500 sporocysts. The major pathophysiological abnormality may be related to hepatic insufficiency, although this remains to be demonstrated. Additional adverse effects may be produced by the muscle and brain lesions, and it is possible that the parasites themselves release toxic metabolites.

Sarcolemmal proliferation, myositis and muscle necrosis are associated with cyst formation of *S. rauschorum* in varying lemmings. The pathogenesis of muscle lesions associated with sarcocysts is not well understood. It is generally accepted that intact mature cysts do not stimulate a host response (Dubey and Fayer, 1982; Dubey et al., 1982). However, cyst rupture, whether induced by senescence or extreme host response leads to a florid reaction typical of a cell-mediated immunity (Warnecke, 1983; Orr et al., 1984).

The cause and significance of the neural lesions are unknown. Meronts and cysts of *S. rauschorum* were not observed in nervous tissues, but could have been there in very small numbers or have existed previously. Similar brain lesions occur in *S. gigantea* infections of sheep subsequent to the completion of a schizogonous phase (Obendorf and Munday, 1986). Other possibilities are that other agents present in the inoculum, or toxic metabolites from elsewhere in the body, result in the development of the neural lesions.

Lemmings infected with *S. rauschorum* are probably more susceptible to aerial predation (Quinn et al., 1986) as a result of the pathophysiological effects of the infection. This may provide an important mechanism for optimizing the survival of this protozoan.

ACKNOWLEDGMENTS

The project was funded by a University Research Fellowship operating grant and International Collaborative Research Grant from the

Natural Sciences and Engineering Research Council (NSERC) of Canada to R. J. Cawthorn. R. J. Brooks is the recipient of a NSERC operating grant. Photographic facilities and expertise were provided by Dr. C. A. Speer, Director of the Electron Microscopy Laboratory, and M. Mendenhall, biomedical photographer, Montana State University. Histologic preparations were made in the Department of Veterinary Pathology, Western College of Veterinary Medicine, University of Saskatchewan.

LITERATURE CITED

- CAWTHORN, R. J., AND R. J. BROOKS. 1985. Histological observations on precystic merogony and merozoite formation of *Sarcocystis rauschorum* (Apicomplexa: Sarcocystidae) in varying lemmings, *Dicrostonyx richardsoni*. Canadian Journal of Zoology 63: 2907–2912.
- , A. A. GAJADHAR, AND R. J. BROOKS. 1984. Description of *Sarcocystis rauschorum* sp. n. (Protozoa: Sarcocystidae) with experimental cyclic transmission between varying lemmings (*Dicrostonyx richardsoni*) and snowy owls (*Nyctea scandiaca*). Canadian Journal of Zoology 62: 217–225.
- DUBEY, J. P., AND R. FAYER. 1982. Sarcocystosis. British Veterinary Journal 139: 371–377.
- , C. A. SPEER, AND G. P. EPLING. 1982. Sarcocystosis in newborn calves fed *Sarcocystis cruzi* sporocysts from coyotes. American Journal of Veterinary Research 43: 2147–2164.
- OBENDORF, D. L., AND B. L. MUNDAY. 1986. Demonstration of schizogonous stages of *Sarcocystis gigantea* in experimentally infected sheep. Veterinary Parasitology 19: 35–38.
- ORR, M. B., G. H. COLLINS, AND W. A. G. CHARLESTON. 1984. *Sarcocystis capracanis*: Experimental infection of goats. II. Pathology. International Goat and Sheep Research 3: 202–211.
- QUINN, S. C., R. J. BROOKS, AND R. J. CAWTHORN. 1987. Effects of the protozoan *Sarcocystis rauschorum* on field behaviour of its intermediate host, *Dicrostonyx richardsoni*. The Journal of Parasitology 73: In press.
- WARNECKE, H. 1983. Histopathologische Untersuchungen über den Abbau von Sarkosporidienzysten nach Chemotherapie sowie über die Regeneration und Reparation der Muskulatur. Inaugural Dissertation, Tierärztliche Hochschule Hannover, Hannover, Federal Republic of Germany, 97 pp.

Received for publication 26 September 1986.