

HEMATOZOA OF WILD TURKEYS FROM THE MIDWESTERN UNITED STATES: TRANSLOCATION OF WILD TURKEYS AND ITS POTENTIAL ROLE IN THE INTRODUCTION OF PLASMODIUM KEMPI

Authors: Castle, Marc D., and Christensen, Bruce M.

Source: Journal of Wildlife Diseases, 26(2) : 180-185

Published By: Wildlife Disease Association

URL: <https://doi.org/10.7589/0090-3558-26.2.180>

The BioOne Digital Library (<https://bioone.org/>) provides worldwide distribution for more than 580 journals and eBooks from BioOne's community of over 150 nonprofit societies, research institutions, and university presses in the biological, ecological, and environmental sciences. The BioOne Digital Library encompasses the flagship aggregation BioOne Complete (<https://bioone.org/subscribe>), the BioOne Complete Archive (<https://bioone.org/archive>), and the BioOne eBooks program offerings ESA eBook Collection (<https://bioone.org/esa-ebooks>) and CSIRO Publishing BioSelect Collection (<https://bioone.org/csiro-ebooks>).

Your use of this PDF, the BioOne Digital Library, and all posted and associated content indicates your acceptance of BioOne's Terms of Use, available at www.bioone.org/terms-of-use.

Usage of BioOne Digital Library content is strictly limited to personal, educational, and non-commercial use. Commercial inquiries or rights and permissions requests should be directed to the individual publisher as copyright holder.

BioOne is an innovative nonprofit that sees sustainable scholarly publishing as an inherently collaborative enterprise connecting authors, nonprofit publishers, academic institutions, research libraries, and research funders in the common goal of maximizing access to critical research.

HEMATOZOA OF WILD TURKEYS FROM THE MIDWESTERN UNITED STATES: TRANSLOCATION OF WILD TURKEYS AND ITS POTENTIAL ROLE IN THE INTRODUCTION OF *PLASMODIUM KEMPI*

Marc D. Castle^{1,2} and Bruce M. Christensen¹

¹ Department of Veterinary Science, 1655 Linden Drive, University of Wisconsin, Madison, Wisconsin 53706, USA

² Present address: USDA, ARS, LPSI, Biosystematic Parasitology Laboratory, Beltsville, Maryland 20705, USA

ABSTRACT: Twenty-three of 310 blood samples taken from live-trapped eastern wild turkeys (*Meleagris gallopavo silvestris*) from Missouri (USA), and hunter-killed birds from Wisconsin, North Dakota and Minnesota (USA), and inoculated into domestic broad-breasted-white turkey poults were positive for two species of *Plasmodium*. Twenty-one of the positive samples were infected with *P. (Novyella) kemp*i, and two samples from Wisconsin were infected with *P. (Giovannolaia) lophurae*. Twenty percent of 310 blood smears were positive for *Haemoproteus meleagridis*, while only 3% were infected with *Leucocytozoon smithi*. A statistically higher prevalence of *Plasmodium* spp. from 1983 to 1984 was observed in Wisconsin, and in the samples from Minnesota when compared with both Missouri and Wisconsin. Turkeys from Wisconsin and Minnesota had both a statistically higher prevalence and mean intensity of *H. meleagridis* than birds from Missouri. Evidence indicates that *P. kemp*i has been introduced into other states along with the vertebrate hosts. It is suggested that greater care should be exercised when translocated wild turkeys are introduced into areas where there are other endangered or threatened avian species.

Key words: Eastern wild turkeys, *Meleagris gallopavo silvestris*, *Plasmodium kemp*i, translocation, *Plasmodium lophurae*, *Haemoproteus meleagridis*, *Leucocytozoon smithi*, prevalence.

INTRODUCTION

With the exception of Alaska, wild turkeys are found in every state, with eighteen of those states actively involved in acquiring turkeys from other states or from Mexico (National Wild Turkey Federation, 1986). In Wisconsin, a concerted effort has been made in the past to establish eastern wild turkeys (*Meleagris gallopavo silvestris*) by the translocation of wild-caught birds from Missouri. The effort proved highly successful, and the wild turkey population reached harvestable levels in the southwestern area of the state by 1983. Consequently, Spring turkey hunts were initiated by the Department of Natural Resources beginning in April and May of 1983, and have continued thereafter.

Reports of *Plasmodium* spp. in wild turkeys of North America have increased in recent years, due mainly to the use of isodagnosis as a sampling technique. Using this technique, Telford and Forrester (1975) isolated the first *Plasmodium* sp. from wild

turkeys in North America, *P. (Huffia) hermani* from native wild turkeys in Florida, Christensen et al. (1983) first isolated *P. (Novyella) kemp*i from Iowa, and Castle et al. (1988) recently reported a *P. (N.) hexamerium*-like species from Rio Grande wild turkeys (*M. gallopavo intermedia*) of southern Texas.

The wild turkey population in Iowa was established through the translocation of birds from Missouri. Therefore, it is possible that *P. kemp*i was introduced into Iowa along with its vertebrate host. The initiation of turkey hunts in Wisconsin, along with the active release of birds from Missouri, provided an opportunity to determine if *Plasmodium* sp.-infected birds were being introduced and/or had been established in Wisconsin. In addition, a small number of blood samples from North Dakota and Minnesota were received and tested during this same time.

Herein, we report (1) the isolation of *P. kemp*i from turkeys translocated into Wisconsin from Missouri, and from hunter-

killed birds from Wisconsin, North Dakota and Minnesota; (2) the isolation of *P. lophurae* from established Wisconsin flocks; and (3) the prevalence and intensity of *Haemoproteus meleagridis* and *Leucocytozoon smithi*.

MATERIALS AND METHODS

Study area—Wisconsin

Ninety-seven hunter killed turkeys were sampled from Wisconsin (47°7' to 42°30'N, 92°54' to 86°45'W) at five check stations in 1983, and 57 blood samples were obtained from six check stations in 1984 (Fig. 1). The Tower Hill station was added in 1984. Turkeys sampled at each station were killed in that general area of the state, but exact locations were not determined. Weight and approximate age (juvenile or adult), based on spur length and weight (Williams, 1981), were determined for each bird.

Sample collections and parasite isolation

Using a heparinized syringe, blood samples were taken from hunter-killed wild turkeys from Minnesota (49°23' to 43°30'N, 97°15' to 89°30'W), North Dakota (49° to 45°56'N, 104°3' to 96°33'W) and Wisconsin, and live-trapped turkeys from Missouri (40°37' to 36°N, 95°47' to 89°6'W). Birds from Missouri were bled immediately prior to their release into Wisconsin. Thin blood smears were made and the remaining blood (0.2 to 2.0 ml) was refrigerated (4 C) and later inoculated either intraperitoneally (IP) or intravenously (IV) into 5- to 31-day-old domestic turkey poults (Nicholas broad-breasted-white; obtained at 1 day of age from Jerome Foods, Barron, Wisconsin 54812, USA). Time between collection of blood and inoculation ranged from 1 to 8 days. There was no significant difference in the percentage of positive samples due to the age of collected blood. All recipient birds were housed in the Charmany Farm semi-isolation facilities operated by the Department of Veterinary Science (University of Wisconsin, Madison, Wisconsin 53706, USA). All studies were done in winter or early spring when accidental feeding by indigenous mosquitoes would not take place.

Beginning 1 wk postinoculation, blood smears were made twice weekly for 6 to 9 wk, and were stained with Giemsa's stain at pH 7.2 to 7.3 (1:10 dilution for 1 hr). A minimum of 20,000 erythrocytes were examined per slide using oil immersion optics (1,250×). Erythrocyte numbers were estimated by counting the number of erythrocytes in ten random fields per slide, taking the average, and then counting the number of fields observed until a minimum of 20,000

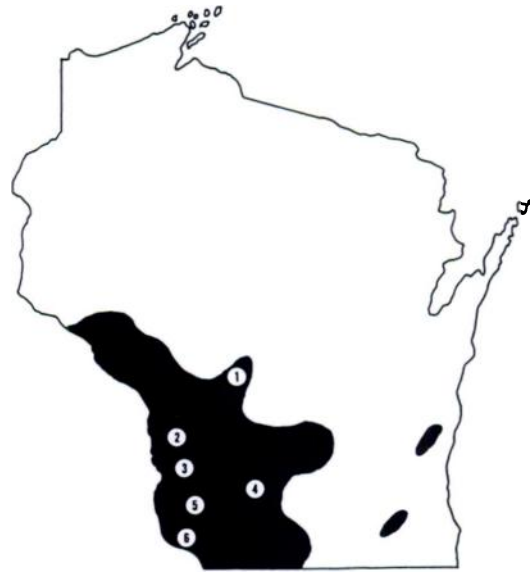

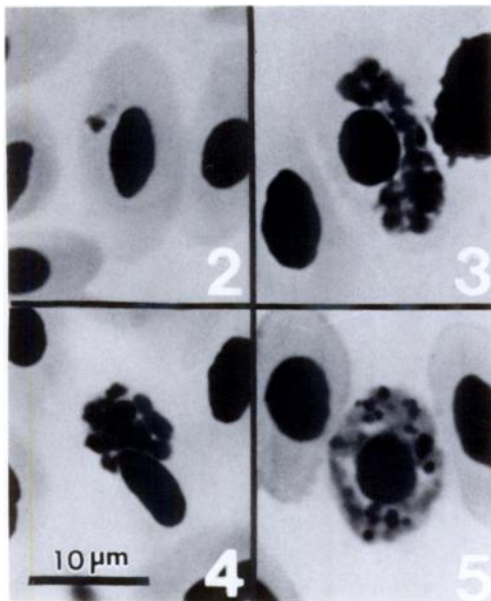
FIGURE 1. Map of Wisconsin showing hunter-check stations where blood samples from wild turkeys were obtained, 1983–1984. Shaded area indicates range of wild turkeys in Wisconsin. Study sites include (1) Necedah, Juneau County; (2) Romance Tavern, Vernon County; (3) Gays Mills, Crawford County; (4) Tower Hill, Iowa County; (5) Boscobel, Grant County; (6) Cassville, Grant County.

erythrocytes had been viewed. Counts of *H. meleagridis* were all based on 10,000 erythrocytes.

Representative specimens of *L. smithi*, *H. meleagridis*, *P. kemp*i, and *P. lophurae* were deposited in the International Reference Centre for Avian Haematozoa (Memorial University of Newfoundland, St. Johns, Newfoundland, Canada A1B 3X9; accession numbers 107649–107652) and in the U.S. National Parasite Collection (Beltsville, Maryland 20705, USA; as accession number 80968-80971).

Statistical analysis

Prevalence data for *H. meleagridis* were analyzed using Chi-square analysis of 2 × 2 contingency tables, and intensity data were analyzed by Student's *t*-test. After testing intensity data for normality, log transformations were performed and the data again retested for normality. All analyses were done from statistical packages on a Hewlett-Packard HP 86 microcomputer system (Hewlett-Packard Co., N.E. Circle Blvd., Corvallis, Oregon 97330, USA). Differences were considered significant at *P* < 0.05.



FIGURES 2-5. Erythrocytic stages of *Plasmodium lophurae* isolated from two eastern wild turkeys from Wisconsin, 1984. 2. Mature trophozoite. 3. Mature schizont. 4. Mature schizont. 5. Mature macrogametocyte.

RESULTS

Prevalence and intensity

Two species of *Plasmodium* were isolated in blood samples taken from birds in Wisconsin, *P. lophurae* and *P. kemp*i (Table 1). Only the latter species, however, was identified in birds from Missouri, North Dakota and Minnesota. *Haemoproteus meleagridis* and *L. smithi* were found in birds from Wisconsin, Missouri and Minnesota (Table 1). A statistically significant difference was observed in the prevalence of *Plasmodium* spp. from 1983 to 1984 in Wisconsin, and in the samples from Minnesota (29%) when compared to both Wisconsin (7%) and Missouri (4%). Both samples from North Dakota birds were positive for *P. kemp*i.

Turkeys from Wisconsin and Minnesota had both a statistically higher prevalence and intensity of *H. meleagridis* than birds from Missouri (Table 1). Direct smears were not made from blood samples from Wisconsin in 1983 or from the two samples

TABLE 1. Prevalence and intensity of hematozoan parasites of eastern wild turkeys from four states in the midwestern USA, 1983-1984.

State	<i>Plasmodium</i> spp.	<i>Haemoproteus meleagridis</i>	<i>Leucocytozoon smithi</i>
Wisconsin			
1983	3 (3/97) ^a	NDS ^b	NDS
1984	12 (7/57) ^c	34 (42/125) (8.8 ± 2.3; 1-87) ^d	2 (3/125) (1.0; 1)
Missouri			
1983	10 (3/30)	8 (2/25) (1.0; 1)	4 (1/25) (1.0; 1)
1984	3 (3/107)	4 (2/25) (1.0; 1)	4 (4/111) (1.0; 1)
North Dakota			
1983	100 (2/2)	NDS	NDS
Minnesota			
1984	29 (5/17)	44 (8/18) (7.2 ± 2.5; 1-19)	6 (1/18) (1.0; 1)
Total	7 (23/310)	20 (56/279) (7.8 ± 1.8; 1-87)	3 (9/279) (1.0; 1)

^a % prevalence (number positive/number examined).

^b NDS = No direct smear.

^c Two *P. lophurae*, five *P. kemp*i.

^d Number parasites/10,000 erythrocytes ± SE; range.

received from North Dakota. Nine samples were positive for *L. smithi*, with no significant difference in prevalence or intensity from any state or within a state from year to year.

***Plasmodium lophurae* erythrocytic stages**

Erythrocytic stages of *Plasmodium lophurae* are presented in Figures 2–5. Measurements were made using a calibrated ocular micrometer and are expressed in μm . Only mature erythrocytes were infected by the stages of the parasite, with little or no nuclear displacement exhibited by any stage. Only rarely was there multiple invasion of an erythrocyte.

Mature trophozoites were large, vacuolated, averaged 2.3 to 3.6 μm (1.5 to 3.6 \times 2.9 to 5.2 μm ; $n=10$), and exhibited little to no ameboidicity (Fig. 2). Distribution within the erythrocyte was apparently random, but most were found polarly located. Pigment granules were present in one localized area.

Nuclei of mature schizonts were prominent, with a range of 7 to 15 and a mean of 10, while schizonts averaged 3.3 to 8.2 μm (2.2 to 4.4 \times 5.8 to 12.4 μm ; $n=10$) (Fig. 3–4). Schizonts were often found looping around the erythrocyte nucleus, but never completely surrounded it (Fig. 4). Pigment granules were clumped.

Mature gametocytes were often found filling the entire cytoplasm of the erythrocyte (Fig. 5). Microgametocytes either stained very poorly or were brick red color, and averaged 2.1 to 14.7 μm (1.5 to 2.2 \times 9.5 to 17.5 μm ; $n=10$), while macrogametocytes typically stained a dark blue, and averaged 2.3 to 12.5 μm (1.5 to 3.6 \times 9.5 to 16.8 μm ; $n=10$). Pigment granules were numerous and scattered throughout the parasite.

DISCUSSION

With the exception of North Dakota, all states sampled have received wild birds from Missouri, and although the prevalence of *P. kemp*i was low in translocated birds sampled from Missouri (4%) and re-

leased into Wisconsin, it was present. These data do not incriminate positively Missouri as the source of *P. kemp*i infections in wild turkeys, but they provide evidence that *P. kemp*i is being translocated along with its host. Because no birds from Missouri were tested for *Plasmodium* sp. infections prior to the first report of *P. kemp*i from Iowa, it is impossible to determine definitively that Missouri was the initial focus for *P. kemp*i. The isolation of *P. kemp*i from all four states indicates that this species, regardless of its origin, is being maintained and transmitted in the populations of wild turkeys. Kentucky was another state that received wild turkeys from Missouri, but 22 blood samples from hunter-killed wild turkeys in the western part of the state and inoculated into domestic turkey poults were negative for any *Plasmodium* sp. infection (Castle and Christensen, 1984). The possibility exists that environmental and/or biological conditions in Kentucky may not be favorable for the maintenance of *P. kemp*i.

Potential effects of *P. kemp*i on wild turkeys are at this time unknown. However, although there are no controlled studies on its pathogenicity, domestic turkey poults inoculated with *P. kemp*i seemingly have no apparent difficulty in dealing with the infection. Infected birds are thrifty, active and exhibit no outward signs of distress. Possible sublethal effects or synergism with other pathogens have not been assessed.

Castle et al. (1988) discussed characteristics and problems associated with several reported species in the subgenus *Novyella*, including *P. kemp*i, *P. hexamerium* and *P. vau*ghani. They also postulated that *P. kemp*i could be included in a species-complex which includes *P. hexamerium* and *P. vau*ghani. Evidence for this included minor morphological and biological differences of the three species, as well as a report by Corradetti et al. (1963) which stated that *P. vau*ghani is still undergoing speciation, making correct identifications difficult.

If our diagnosis of the second *Plasmodium* sp. is correct, it marks the first isolation of *P. lophurae* from a wild host in North America. The species was first reported from a Borneo fire-backed pheasant (*Lophura igniti igniti*) at the New York Zoological Park (Coggeshall, 1938). There has been one erroneous report of this species in North America in an abstract of a paper presented to the American Microscopical Society in 1966, which was later identified as *P. circumflexum* by Folz (1968). Of the avian species of *Plasmodium*, only *P. lophurae* and *P. circumflexum* possess gametocytes which encircle completely the erythrocyte nucleus (Laird and Lari, 1957; Garnham, 1966). These two species can be differentiated further by merozoites of *P. circumflexum* invading erythroblasts, whereas those of *P. lophurae* do not (Laird and Lari, 1957). This, coupled with the absence of erythrocytic schizonts surrounding the host cell nucleus, are the criteria used in calling this parasite *P. lophurae*. Unfortunately, the isolate was lost before vertebrate host specificity and laboratory vector studies could be performed, which would have identified conclusively the *Plasmodium* sp. in question.

Reports of *H. meleagridis* and *L. smithi* infecting wild turkeys are numerous (see Bennett et al., 1982; Castle and Christensen, 1984; Castle et al., 1988). Lesions resulting from infections with *L. smithi*, documented mainly from domestic turkeys (Hinshaw and McNeil, 1938; Banks, 1943; Savage and Isa, 1945; Bierer, 1954; Wehr, 1962), occur in the hepatic system including an increase of lymphocytes in the liver and hepatic hemosiderosis, lung congestion (Newberne, 1955) splenomegaly, and hemorrhagic enteritis (Simpson et al., 1956). The pathology associated with experimental *H. meleagridis* infections was discussed by Atkinson et al. (1986), where they described extensive myopathy and lameness with associated alterations in liver and spleens of infected domestic turkey poults. Atkinson and Forrester (1987) reported recently similar lesions in a natu-

rally infected wild turkey; these may have contributed to the death of the bird.

Because avian species of *Plasmodium* are usually capable of infecting several species of birds, translocations of *Plasmodium* sp.-infected turkeys pose a potentially serious problem. Although both the domestic turkey poults and the wild turkeys are capable of handling the infections with no apparent difficulty, other gallinaceous birds such as quail (*Colinus virginianus*) and pheasants (*Phasianus colchicus*), or even endangered species like the lesser prairie chicken (*Tympanuchus cupido attwateri*), may be severely affected by one or more of the *Plasmodium* species. With this in mind, we believe greater care should be taken when translocations of wild birds bring them into contact with threatened or endangered avian species.

ACKNOWLEDGMENTS

We thank Terry Amundson and the Wisconsin Department of Natural Resources, T. E. Rocke, all the students who collected blood samples, Jerome Foods for donating turkey poults, and B. Huff, K. Harris, J. Conti, E. Grunden, C. Tiller, and J. Gustafson for their able technical assistance. This study was supported in part by the College of Agriculture and Life Sciences, University of Wisconsin-Madison, Animal Health Project Number 2676, and by a Grant-In-Aid from the National Wild Turkey Federation.

LITERATURE CITED

- ATKINSON, C. T., E. C. GREINER, AND D. J. FORRESTER. 1986. Pre-erythrocytic development and associated host responses to *Haemoproteus meleagridis* (Haemosporina: Haemoproteidae) in experimentally infected domestic turkeys. *Journal of Protozoology* 33: 375-381.
- , AND D. J. FORRESTER. 1987. Myopathy associated with megaloschizonts of *Haemoproteus meleagridis* in a wild turkey from Florida. *Journal of Wildlife Diseases* 23: 495-498.
- BANKS, W. C. 1943. *Leucocytozoon smithi* infection and other diseases of turkey poults in central Texas. *Journal of the American Veterinary Medical Association* 102: 467-468.
- BENNETT, G. F., M. WHITEWAY, AND C. WOODWORTH-LYNAS. 1982. A host-parasite catalogue of the avian haematozoa. *Memorial University of Newfoundland Occasional Papers*

- in Biology, No. 5, Memorial University of Newfoundland, St. John's, Newfoundland, Canada, 243 pp.
- BIERER, B. W. 1954. Buffalo gnats and leucocytozoon infections of poultry. *Veterinary Medicine* 49: 107-110.
- CASTLE, M. D., AND B. M. CHRISTENSEN. 1984. Blood and gastrointestinal parasites of eastern wild turkeys from Kentucky and Tennessee. *Journal of Wildlife Diseases* 20: 190-196.
- , ———, AND T. E. ROCKE. 1988. Hematozoan parasites of Rio Grande wild turkeys from southern Texas. *Journal of Wildlife Diseases* 24: 88-96.
- CHRISTENSEN, B. M., H. J. BARNES, AND W. A. ROWLEY. 1983. Vertebrate host specificity and experimental vectors of *Plasmodium* (*Novyella*) *kempi* sp. n. from the eastern wild turkey in Iowa. *Journal of Wildlife Diseases* 19: 204-213.
- COGGESHALL, L. T. 1938. *Plasmodium lophurae*, a new species of malaria parasite for the domestic fowl. *American Journal of Hygiene* 18: 615-619.
- CORRADETTI, A., P. C. C. GARNHAM, AND M. LAIRD. 1963. New classification of the avian malarial parasites. *Parassitologia* 5: 1-4.
- FOLZ, S. D. 1968. Phenotypic variations of plasmodia in fowl. 1. Periodicity and morphological changes of plasmodia in fowl. 2. Biological studies on two new strains of *Plasmodium circumflexum*. Ph.D. Thesis. University of Wisconsin-Madison, Madison, Wisconsin, 288 pp.
- GARNHAM, P. C. C. 1966. Malaria parasites and other haemosporidia. Blackwell Scientific Publications, Oxford, England, 1,114 pp.
- HINSHAW, W. R., AND E. MCNEIL. 1938. *Leucocytozoon* sp. from turkeys in California. *Poultry Science* 22: 268.
- LAIRD, M., AND F. A. LARI. 1957. Observations on *Plasmodium circumflexum* Kikuth and *P. vaughani* Novy and Macneal from east Pakistan. *The Journal of Parasitology* 43: 136-152.
- NATIONAL WILD TURKEY FEDERATION. 1986. Guide to the American Wild Turkey. National Wild Turkey Federation, Inc., Edgefield, South Carolina, 189 pp.
- NEWBERNE, J. W. 1955. The pathology of *Leucocytozoon* infection in turkeys with a note on its tissue stages. *American Journal of Veterinary Research* 16: 593-597.
- SAVAGE, A., AND J. M. ISA. 1945. An outbreak of *Leucocytozoon* disease in turkeys. *Cornell Veterinarian* 35: 270-272.
- SIMPSON, C. F., D. W. ANTHONY, AND F. YOUNG. 1956. Parasitism of adult turkeys in Florida by *Leucocytozoon smithi* (Laveran and Lucet). *Journal of the American Veterinary Medical Association* 129: 573-576.
- TELFORD, S. R., AND D. J. FORRESTER. 1975. *Plasmodium* (*Huffia*) *hermani* sp. n. from wild turkeys (*Meleagris gallopavo*) in Florida. *Journal of Protozoology* 22: 324-328.
- WEHR, E. E. 1962. Studies on leucocytozoonosis of turkeys, with notes on schizogony, transmission, and control of *Leucocytozoon smithi*. *Avian Diseases* 6: 195-210.
- WILLIAMS, L. E., JR. 1981. *The Book of the Wild Turkey*. Winchester Press, Tulsa, Oklahoma, 181 pp.

Received for publication 14 August 1987.