

Inclusion Bodies Containing Adenovirus-Like Particles in the Intestine of a Psittacine Bird Affected by Inclusion Body Hepatitis

Authors: Gómez-Villamandos, J. C., Mozos, E., Sierra, M. A., Pérez, J., and Mendez, A.

Source: Journal of Wildlife Diseases, 28(2) : 319-322

Published By: Wildlife Disease Association

URL: <https://doi.org/10.7589/0090-3558-28.2.319>

The BioOne Digital Library (<https://bioone.org/>) provides worldwide distribution for more than 580 journals and eBooks from BioOne's community of over 150 nonprofit societies, research institutions, and university presses in the biological, ecological, and environmental sciences. The BioOne Digital Library encompasses the flagship aggregation BioOne Complete (<https://bioone.org/subscribe>), the BioOne Complete Archive (<https://bioone.org/archive>), and the BioOne eBooks program offerings ESA eBook Collection (<https://bioone.org/esa-ebooks>) and CSIRO Publishing BioSelect Collection (<https://bioone.org/csiro-ebooks>).

Your use of this PDF, the BioOne Digital Library, and all posted and associated content indicates your acceptance of BioOne's Terms of Use, available at www.bioone.org/terms-of-use.

Usage of BioOne Digital Library content is strictly limited to personal, educational, and non-commercial use. Commercial inquiries or rights and permissions requests should be directed to the individual publisher as copyright holder.

BioOne is an innovative nonprofit that sees sustainable scholarly publishing as an inherently collaborative enterprise connecting authors, nonprofit publishers, academic institutions, research libraries, and research funders in the common goal of maximizing access to critical research.

Inclusion Bodies Containing Adenovirus-Like Particles in the Intestine of a Psittacine Bird Affected by Inclusion Body Hepatitis

J. C. Gómez-Villamandos,* E. Mozos,** M. A. Sierra,** J. Pérez, and A. Mendez,** * Department of Electron Microscopy, University of Córdoba, Spain; ** Department of Veterinary Pathology, University of Córdoba, Spain

ABSTRACT: This paper reports a case of inclusion body hepatitis with intranuclear inclusion bodies in the liver and the intestine of a Yellow-naped Amazon parrot (*Amazona ochrocephala*). Structurally, basophilic intranuclear inclusion bodies were found in hepatic cells and enterocytes. Ultrastructurally, icosahedral adenovirus-like particles, 60–75 nm in diameter, were found in the same cells.

Key words: Adenovirus, Amazon parrot, liver, small intestine, inclusion body hepatitis, *Amazona ochrocephala*.

Inclusion body hepatitis (IBH) was first described in chickens in 1963 (Hemboldt and Frasier, 1963). McFerran et al. (1976) demonstrated that it was caused by an adenovirus.

This disease was reported in other avian species such as American kestrels (Sileo et al., 1983), pigeons (Coussement et al., 1984), geese (Riddell, 1984), and merlin (Schelling et al., 1989). The characteristic lesion of the disease is the presence of large basophilic intranuclear inclusion bodies (IIB's) in hepatocytes.

IBH has also been described in psittacines (Scott et al., 1986; Pass, 1987; Mori et al., 1989); in some cases, inclusion bodies containing adenovirus-like particles in the epithelial cells of renal tubules were found (Mori et al., 1989).

In this report, we describe inclusion bodies and adenovirus-like virions in the intestinal epithelium of a IBH-affected psittacine bird, which constitutes the first description of this disease in a psittacine from Europe.

An adult Yellow-naped Amazon parrot (*Amazona ochrocephala*) with anorexia, slight yellowish diarrhea and nasal mucus secretion, died 48 hr after external nares were cleaned with physiological saline so-

lution. At necropsy, a serous rhinitis was observed. The most significant lesions were hepatomegaly and a yellowish decoloration of the liver. Aside from a yellowish aqueous intestinal content, no other abnormalities were found.

Samples from various organs were fixed in 10% buffered formalin and referred to our laboratory. After being embedded in paraffin, the samples were sliced into thin sections (3 to 4 μ m thick) that were stained by the hematoxylin-eosin and Feulgen techniques. For the ultrastructural study, small pieces of tissue were post-fixed in osmium tetroxide, embedded in Epon 812, sliced into 60 nm sections and contrasted with uranyl acetate and lead citrate.

The histopathological study of the liver revealed extensive fatty degeneration and multifocal necrotic hepatitis with mononuclear cells infiltrate (lymphocytes and monocytes). The nucleus of some hepatocytes and Kupffer cells were enlarged and showed peripheral margination of the chromatin and basophilic inclusion bodies (Fig. 1). The Feulgen positive reaction of these inclusion bodies suggested that they were the result of a DNA virus-infection.

The small intestine showed shortened villi, with numerous intraepithelial lymphocytes. Numerous apical and mild-villar enterocytes, especially in jejunum, had enlarged, rounded nuclei with margination of the chromatin and large inclusion bodies (Fig. 2). The majority were located in the center of the nucleus and had a clear peripheral halo. In other cases, the inclusion bodies occupied the whole nucleus, similar to those observed in hepatocytes.

Ultrastructurally, hexagonal viral particles, 60 to 75 nm in diameter, and mature

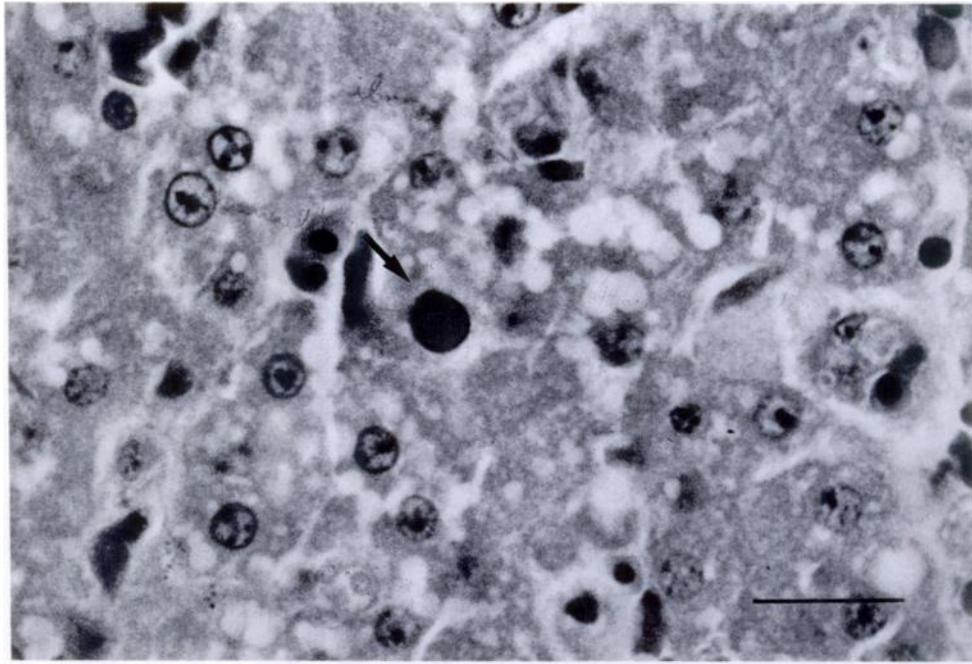


FIGURE 1. Basophilic inclusion bodies in an hepatocyte (arrow) of an Amazon parrot. H&E. Bar = 20 μ m.

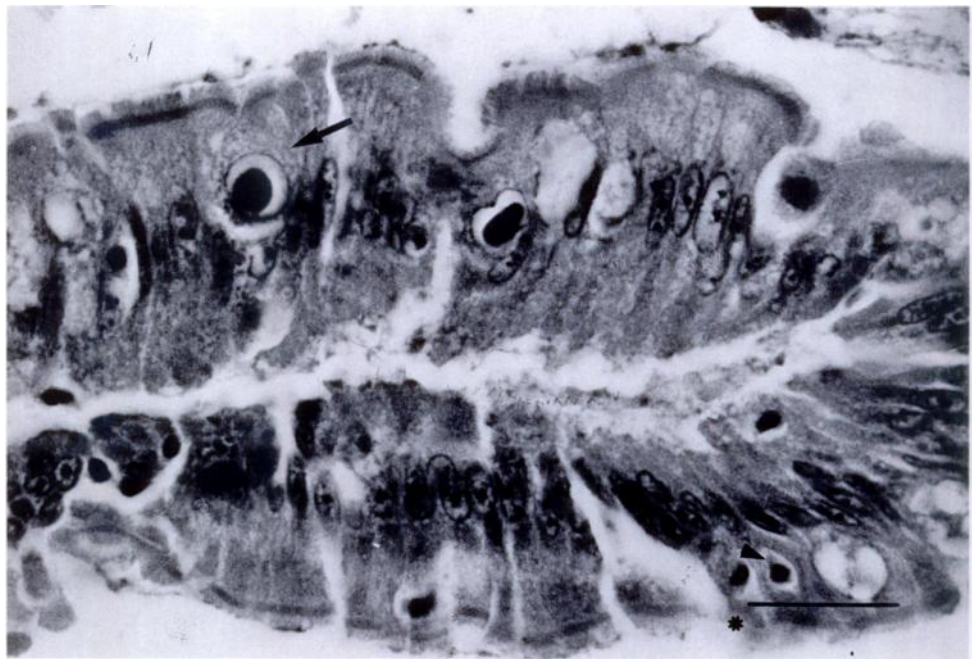


FIGURE 2. Basophilic inclusion bodies in enterocytes (arrow) and intraepithelial lymphocytes (arrowhead) in the jejunum of an Amazon parrot. H&E. Bar = 20 μ m.

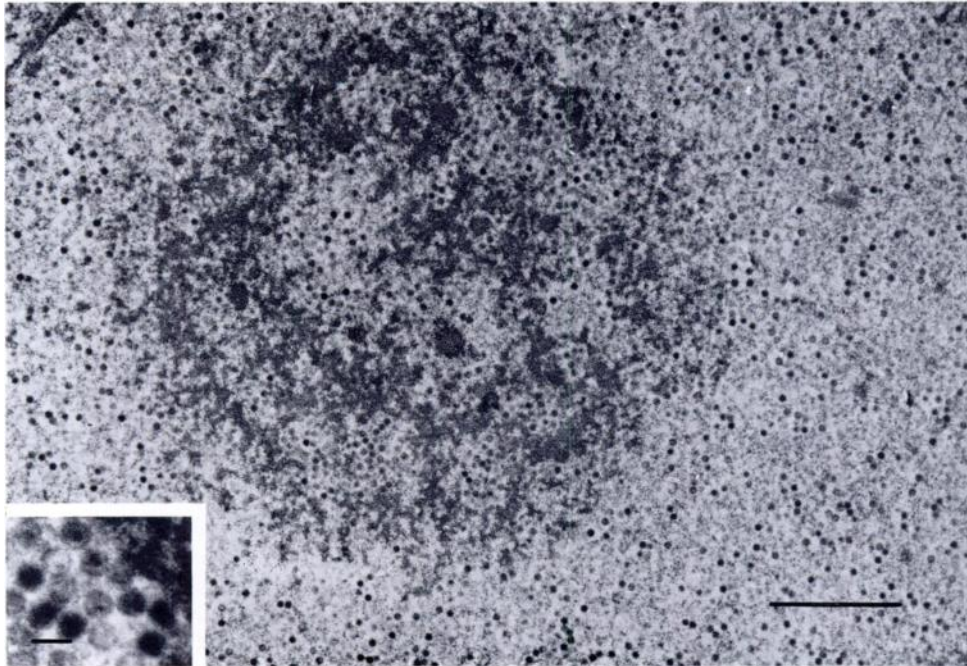


FIGURE 3. Adenovirus-like particles in an enterocyte inclusion body of an Amazon parrot. Bar = 2 μ m; Insert = 100 nm.

viral particles containing electron-dense nucleoids, were observed in hepatocytes, Kupffer cells and in the epithelium of small intestine.

The lesions and inclusion bodies observed at the ultrastructural level in this case are similar to those described in birds affected with IBH (Sileo et al., 1983; Coussement et al., 1984; Ridell, 1984; Scott et al., 1986; Pass, 1987; Mori et al., 1989; Schelling et al., 1989) and the ultrastructural study revealed adenovirus-like-particles as the aetiological agents of the disease (Silim et al., 1977; Sileo et al., 1983; Scott et al., 1986; Mori et al., 1989; Schelling et al., 1989).

The pathological changes observed in this case do not allow confirmation of the adenoviral infection as the primary cause of the disease. The stress conditions imposed on the bird in order to clean the nasal mucus could have activated a latent adenoviral infection (Sileo et al., 1983; Lowenstein and Fry, 1985).

In Pacheco's disease, produced by a her-

pesvirus, intranuclear inclusion bodies are also present in hepatocytes (Panigrahy and Grumbles, 1983). These IIB's are usually acidophilic although in recent studies they have been described as acidophilic and basophilic (Scott et al., 1986). The presence of IIB's caused by adenovirus in the intestinal epithelium of psittacine birds affected with IBH has not been described previously.

We wish to acknowledge the excellent assistance of T. Moyano, Chief of the Department of Electron Microscopy, University of Córdoba.

LITERATURE CITED

- COUSSEMENT, H. J. C., R. DUCATTELLE, P. LEMAHIEU, R. FROYMAN, L. DEVRIESE, AND J. HOORENS. 1984. Pathology of adenovirus infection in pigeons. *Vlaamse Diergeneeskunde Tijdschrift* 53: 277-283.
- HEMBOLDT, C. F., AND M. N. FRASIER. 1963. Avian hepatic inclusion bodies of unknown significance. *Avian Diseases* 7: 446-450.
- LOWENSTEIN, L. J., AND D. M. FRY. 1985. Adenovirus-like particles associated with intranucle-

- ar inclusion body in the kidney of a common murre (*Uria aalge*). *Avian Diseases* 29: 208–213.
- McFERRAN, J. B., T. J. CONNOR, AND R. M. MC-CRACKEN. 1976. Isolation of adenovirus and reovirus from avian species other than domestic fowl. *Avian Diseases* 20:519–524.
- MORI, F., A. TOUCHI, T. SUWA, C. ITAKURA, A. HASHIMOTO, AND K. HIRAI. 1989. Inclusion bodies containing adenovirus-like particles in the kidney of psittacine birds. *Avian Pathology* 18: 197–202.
- PANIGRAHY, B., AND L. C. GRUMBLES. 1983. Pacheco's disease in Psittacine birds. *Avian Diseases* 28: 808–812.
- PASS, D. A. 1987. Inclusion bodies and hepatopathies in psittacines. *Avian Pathology* 16: 581–597.
- RIDDELL, C. 1984. Viral hepatitis in domestic geese in Saskatchewan. *Avian Diseases* 28: 774–782.
- SCHELLING, S. H., D. S. GARLICK, AND J. ALROY. 1989. Adenoviral hepatitis in a merlin (*Falco columbarius*). *Veterinary Pathology* 26: 529–530.
- SCOTT, P. C., R. J. COUDRON, AND R. L. REECE. 1986. Inclusion body hepatitis associated with adenovirus-like particles in a cockatiel (*Psittaciformes; Nymphicus hollandicus*). *Australian Veterinary Journal* 63: 337–338.
- SILEO, L., J. C. FRANSON, D. L. GRAHAM, C. H. DOMERMUTH, B. A. RATTNER, AND O. H. PATTEE. 1983. Hemorrhagic enteritis in captive American kestrels (*Falco sparverius*). *Journal of Wildlife Diseases* 19: 244–247.
- SILIM, A., J. THORSEN, AND H. C. CARLSON. 1977. Experimental of chickens with hemorrhagic enteritis virus. *Avian Diseases* 22: 106–114.

Received for publication 15 February 1991.