

Rabies in an American Bison from North Dakota

Authors: Stoltenow, Charles L., Solemsass, Kris, Niezgoda, Michael, Yager, Pamela, and Rupprecht, Charles E.

Source: Journal of Wildlife Diseases, 36(1) : 169-171

Published By: Wildlife Disease Association

URL: <https://doi.org/10.7589/0090-3558-36.1.169>

The BioOne Digital Library (<https://bioone.org/>) provides worldwide distribution for more than 580 journals and eBooks from BioOne's community of over 150 nonprofit societies, research institutions, and university presses in the biological, ecological, and environmental sciences. The BioOne Digital Library encompasses the flagship aggregation BioOne Complete (<https://bioone.org/subscribe>), the BioOne Complete Archive (<https://bioone.org/archive>), and the BioOne eBooks program offerings ESA eBook Collection (<https://bioone.org/esa-ebooks>) and CSIRO Publishing BioSelect Collection (<https://bioone.org/csiro-ebooks>).

Your use of this PDF, the BioOne Digital Library, and all posted and associated content indicates your acceptance of BioOne's Terms of Use, available at www.bioone.org/terms-of-use.

Usage of BioOne Digital Library content is strictly limited to personal, educational, and non-commercial use. Commercial inquiries or rights and permissions requests should be directed to the individual publisher as copyright holder.

BioOne is an innovative nonprofit that sees sustainable scholarly publishing as an inherently collaborative enterprise connecting authors, nonprofit publishers, academic institutions, research libraries, and research funders in the common goal of maximizing access to critical research.

Rabies in an American Bison from North Dakota

Charles L. Stoltzenow,^{1,4} Kris Solemsass,² Michael Niezgoda,³ Pamela Yager,³ and Charles E. Rupprecht³

¹ Department of Veterinary and Microbiological Sciences, North Dakota State University, 164 Van Es Hall, Fargo, North Dakota 58105, USA; ² Pinkerton Animal Hospital, 2105 Broadway North, Minot, North Dakota 58701, USA;

³ Centers for Disease Control and Prevention, 1600 Clifton Road, MS G33, Atlanta, Georgia 30333, USA; ⁴ Corresponding author (cstolten@ndsux.ndsu.edu).

ABSTRACT: In North Dakota (USA) during April 1998, a ranched female bison (*Bison bison*) was found dead. At gross necropsy, there was profound hair loss and consolidated lung lobes. Intracytoplasmic neuronal inclusions suggestive of Negri bodies were observed in the brain stem and hippocampus, and a diagnosis of rabies was confirmed by the fluorescent antibody test. Antigenic typing demonstrated the occurrence of a rabies virus variant associated with skunks from the upper mid-western USA. This case of a rabid bison was one of only four such instances recorded from the USA over the past 40 yr, and is the first case report of rabies in a bison that reports clinical, pathologic, and antigenic findings. Although rabies in bison is rare, veterinarians and wildlife managers that work closely with such non-traditional species are reminded of the dangers that zoonoses such as rabies present.

Key words: American bison, *Bison bison*, case report, rabies, zoonoses.

Rabies is an acute encephalomyelitis caused by RNA viruses in the genus *Lysavirus*, family *Rhabdoviridae*. Although primary reservoirs consist of representatives among the *Carnivora* and *Chiroptera*, all mammals are believed to be susceptible. However, rabies in some species, such as the American bison (*Bison bison*), is rare. Since 1960 only three documented cases of rabid bison were reported in the USA. Two cases were reported from South Dakota (USA) in 1996 (Krebs et al., 1997), and one case was reported from that same state in a “buffalo”, presumably a bison, during 1979 (CDC, 1981). Little is known about the pathogenesis, clinical manifestations, and epidemiology of these apparently rare events.

In April 1998, a veterinarian was called to a bison ranch in northwestern North Dakota (USA; 48°55'N, 101°25'W) to perform a necropsy on a bison found dead by the ranch owner. The owner reported that

the animal, a four-year-old female, was listless and lethargic, and had been wandering and standing away from the herd for the two previous days.

Gross necropsy findings by the veterinarian included profound hair loss over the back and rump and severely consolidated cranial ventral lung lobes with small areas of adhesions and granulomas. Fresh (brain, lung, spleen, small intestine, large intestine, and liver) and fixed tissues (brain, lung, spleen, trachea, esophagus, small intestine, large intestine, omasum, abomasum, kidney and liver) were submitted to the North Dakota State University Veterinary Diagnostic Laboratory (NDSU-VDL; Fargo, North Dakota, USA) for analysis. The submitting veterinarian's differential diagnoses included malignant catarrhal fever (MCF), rabies, and bronchopneumonia of bacterial origin.

Routine microscopic examination of tissues revealed occasional mononuclear perivascular cuffs observed in the kidney, but vasculitis was not present. In the spleen, there was a paucity of lymphocytes in the red pulp. Lung lesions were characterized by marked purulent infiltrates which occupied smaller bronchioles and alveoli. Fibrin, hyalin crescents and scattered foci of necrosis were in affected areas as well. Some brain sections showed mild to severe disseminated subacute lymphocytic encephalitis characterized by presence of perivascular cuffs, primarily mononuclear lymphocytes. Occasional intracytoplasmic inclusion bodies were observed in neurons adjacent to vascular lesions in the brainstem and hippocampus, which were presumed to be Negri bodies.

Fluorescent antibody tests on the brain stem and hippocampus were positive for

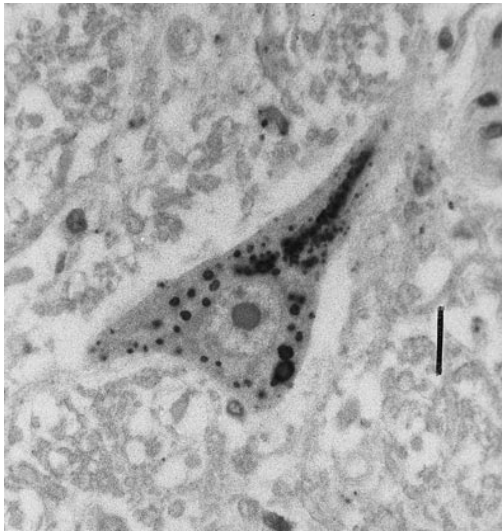


FIGURE 1. Section of brainstem from a rabid bison demonstrating intracytoplasmic inclusions within the perikaryon of a neuron. Anti-rabies monoclonal antibody staining with avidin-biotin complex immunoperoxidase and Gill's hematoxylin counterstain. Bar = 16 μ m.

rabies virus antigen. As policy of the NDSU-VDL, all other diagnostic tests and procedures were halted because of the zoonotic risk associated with rabies infected material. Frozen and fixed tissues were submitted to the Centers for Disease Control and Prevention (Atlanta, Georgia, USA). Based on antigen found in frozen brain tissue, a north central skunk rabies virus variant was identified by anti-rabies monoclonal antibody staining, as described (Smith, 1989, 1996). Fixed tissues were examined by immunohistochemistry with anti-rabies monoclonal antibody and avidin-biotin complex immunoperoxidase, as described (Hamir et al., 1996). Rabies specific inclusions were observed only in neurons throughout the brain tissue (Fig. 1).

The primary differential diagnosis by the veterinarian in this case was MCF, based on the clinical history and lack of other significant findings. Bison appear to be relatively resistant to several livestock diseases associated with production, yet appear to exhibit an increased susceptibility to MCF, which has been reported in a

number of bison fatalities (Ruth et al., 1977; Schultheiss et al., 1998). The veterinarian included rabies in the differential diagnosis primarily because brain tissue was being submitted for primary MCF determination. Due to the distribution of rabies throughout the state, many local practitioners request routine rabies diagnosis in any unexplained animal death. Although the presence of bronchopneumonia was considered coincidental, respiratory complications related to dysphagia and aspiration are not uncommon in the terminal stages of rabies.

North Dakota is an enzootic area for skunk rabies (Krebs et al., 1997), with diagnosed cases of rabid skunks reported during 1990 through 1997 ranging between six and 115 animals per year. These data from passive surveillance are considered to represent only a fraction of rabies cases in the area. Although specific reports of rabid bison are unusual, skunks (*mephitis mephitis*) are common where ranches bison reside. Antigenic identification of the rabies virus from this bison as the variant associated with rabid skunks in the region, implies that it was infected by a skunk. Tenacious biting and aggressive behavior by these small carnivores, when rabid (Charlton et al., 1991) could explain the potential interaction between skunk and bison. Conversely, investigative contact on pasture initiated by a bison to a dying skunk with paralytic rabies could easily result in a bite from a skunk to the muzzle or face of a bison.

Many of the significant infectious conditions that affect other bovids have also been associated with free-ranging or ranches bison, but often to a much lesser extent (Zarnke and Erickson, 1990; Vestweber, 1991; Taylor et al., 1997). Major diseases that have been reported in bison include brucellosis (Williams et al., 1993; Meyer and Meagher, 1995), tuberculosis (Thoen et al., 1988), anthrax (Gates et al., 1995), ostertagiasis (Wade et al., 1979) and pasteurellosis (Dyer and Ward, 1998). Rabies in bison is considered a rare event.

However, the management of morbidity and mortality in non-traditional hoofed stock is always a challenge as concerns accurate diagnosis, treatment and prevention (Haigh, 1996). Frequently, few objective data exist upon which to base sound medical decisions. This case exemplifies the need for veterinarians and other biomedical professionals to continually be aware of the zoonotic disease potential that exists in the management of both wild and domestic species. Rabies should be considered in the differential diagnosis of any mammal with acute behavioral changes suggestive of an encephalitis.

LITERATURE CITED

- CENTERS FOR DISEASE CONTROL (CDC). 1981. Rabies surveillance annual summary, 1979. U.S. Department of Health and Human Services, Public Health Service, Atlanta, Georgia, 20 pp.
- CHARLTON, K. M., W. A. WEBSTER, AND G. A. CASEY. 1991. Skunk rabies. In *The natural history of rabies*, 2nd Edition, G. M. Baer (ed.). CRC Press, Boca Raton, Florida, pp. 307–324.
- DYER, N. W., AND C. S. WARD. 1998. Pneumonic pasteurellosis associated with *Pasteurella hemolytica* serotype A6 in American bison (*Bison bison*). *Journal of Diagnostic Investigations* 10: 360–362.
- GATES, C. C., B. T. ELKIN, AND D. C. DRAGON. 1995. Investigation, control and epizootiology of anthrax in a geographically isolated, free-roaming bison population in northern Canada. *Canadian Journal of Veterinary Research* 59: 256–264.
- HAIGH, J. C. 1996. Management practices to minimize infectious and parasitic diseases of farmed and ranched cervids and bison. *Revue Scientifique et Technique* 15: 209–226.
- HAMIR, A. N., G. MOSER, T. WAMPLER, A. HATTEL, B. DIETZSCHOLD, AND C. E. RUPPRECHT. 1996. Use of a single anti-nucleocapsid monoclonal antibody to detect rabies antigen in formalin-fixed, paraffin-embedded tissues. *Veterinary Record* 138: 114–115.
- KREBS, J. W., J. S. SMITH, C. E. RUPPRECHT, AND J. E. CHILDS. 1997. Rabies surveillance in the United States during 1996. *Journal of the American Veterinary Medical Association* 211: 1525–1539.
- MEYER, M. E., AND M. MEAGHER. 1995. Brucellosis in free-ranging bison (*Bison bison*) in Yellowstone, Grand Teton, and Wood Buffalo National Parks: A review. *Journal of Wildlife Diseases* 31: 579–598.
- RUTH, G. R., D. E. REED, C. A. DALEY, M. W. VORHIES, K. WOHLGEMUTH, AND H. SHAVE. 1977. Malignant catarrhal fever in bison. *Journal of the American Veterinary Medical Association* 171: 913–917.
- SCHULTHEISS, P. C., J. K. COLLINS, L. E. AUSTGEN, AND J. C. DEMARTINI. 1998. Malignant catarrhal fever in bison, acute and chronic cases. *Journal of Veterinary Diagnostic Investigation* 10: 255–262.
- SMITH, J. S. 1989. Rabies virus epitopic variation: Use in ecologic studies. *Advances in Virus Research* 36: 215–253.
- . 1996. New aspects of rabies with emphasis on epidemiology, diagnosis, and prevention of the disease in the United States. *Clinical Microbiology Reviews* 9: 166–176.
- TAYLOR, S. K., V. M. LANE, D. L. HUNTER, K. G. EYRE, S. KAUFMAN, S. FRYE, AND M. R. JOHNSON. 1997. Serologic survey for infectious pathogens in free-ranging American bison. *Journal of Wildlife Diseases* 33: 308–311.
- THOEN, C. O., K. J. THROLSON, L. D. MILLER, E. M. HIMES, AND R. L. MORGAN. 1988. Pathogenesis of *Mycobacterium bovis* infection in American bison. *American Journal of Veterinary Research* 49: 1861–1865.
- VESTWEBER, J. G., G. L. MERRILL, J. J. STAATS, AND J. VEATCH. 1991. Serologic survey for selected microbial pathogens in bison from Kansas. *Journal of Wildlife Diseases* 27: 473–476.
- WADE, S. E., W. M. HASCHEK, AND J. R. GEORGI. 1979. Ostertagiosis in captive bison in New York State: Report of nine cases. *Cornell Veterinarian* 69: 198–205.
- WILLIAMS, E. S., E. T. THORNE, S. L. ANDERSON, AND J. D. HERRIGES, JR. 1993. Brucellosis in free-ranging bison (*Bison bison*) from Teton County, Wyoming. *Journal of Wildlife Diseases* 29: 118–122.
- ZARNKE, R. L., AND G. A. ERICKSON. 1990. Serum antibody prevalence of parainfluenza 3 virus in a free-ranging bison (*Bison bison*) herd from Alaska. *Journal of Wildlife Diseases* 26: 416–419.

Received for publication 28 February 1999.