

Exertional Myopathy in a Grizzly Bear (*Ursus arctos*) Captured by Leghold Snare

Authors: Cattet, Marc, Stenhouse, Gordon, and Bollinger, Trent

Source: Journal of Wildlife Diseases, 44(4) : 973-978

Published By: Wildlife Disease Association

URL: <https://doi.org/10.7589/0090-3558-44.4.973>

The BioOne Digital Library (<https://bioone.org/>) provides worldwide distribution for more than 580 journals and eBooks from BioOne's community of over 150 nonprofit societies, research institutions, and university presses in the biological, ecological, and environmental sciences. The BioOne Digital Library encompasses the flagship aggregation BioOne Complete (<https://bioone.org/subscribe>), the BioOne Complete Archive (<https://bioone.org/archive>), and the BioOne eBooks program offerings ESA eBook Collection (<https://bioone.org/esa-ebooks>) and CSIRO Publishing BioSelect Collection (<https://bioone.org/csiro-ebooks>).

Your use of this PDF, the BioOne Digital Library, and all posted and associated content indicates your acceptance of BioOne's Terms of Use, available at www.bioone.org/terms-of-use.

Usage of BioOne Digital Library content is strictly limited to personal, educational, and non-commercial use. Commercial inquiries or rights and permissions requests should be directed to the individual publisher as copyright holder.

BioOne is an innovative nonprofit that sees sustainable scholarly publishing as an inherently collaborative enterprise connecting authors, nonprofit publishers, academic institutions, research libraries, and research funders in the common goal of maximizing access to critical research.

SHORT COMMUNICATIONS

Journal of Wildlife Diseases, 44(4), 2008, pp. 973–978
© Wildlife Disease Association 2008

Exertional Myopathy in a Grizzly Bear (*Ursus arctos*) Captured by Leghold Snare

Marc Cattet,^{1,3} Gordon Stenhouse,² and Trent Bollinger¹ ¹ Canadian Cooperative Wildlife Health Centre, Department of Veterinary Pathology, University of Saskatchewan, 52 Campus Drive, Saskatoon, Saskatchewan S7N 5B4, Canada; ² Foothills Model Forest, Box 6330, Hinton, Alberta T7V 1X6, Canada; ³ Corresponding author (email: marc.cattet@usask.ca)

ABSTRACT: We diagnosed exertional myopathy (EM) in a grizzly bear (*Ursus arctos*) that died approximately 10 days after capture by leghold snare in west-central Alberta, Canada, in June 2003. The diagnosis was based on history, post-capture movement data, gross necropsy, histopathology, and serum enzyme levels. We were unable to determine whether EM was the primary cause of death because autolysis precluded accurate evaluation of all tissues. Nevertheless, comparison of serum aspartate aminotransferase and creatine kinase concentrations and survival between the affected bear and other grizzly bears captured by leghold snare in the same research project suggests EM also occurred in other bears, but that it is not generally a cause of mortality. We propose, however, occurrence of nonfatal EM in grizzly bears after capture by leghold snare has potential implications for use of this capture method, including negative effects on wildlife welfare and research data.

Key words: Aspartate aminotransferase, AST, creatine kinase, CK, exertional myopathy, grizzly bear, leghold snare, *Ursus arctos*.

Exertional myopathy (EM) is a noninfectious disease of animals characterized by degenerative or necrotizing damage to skeletal and cardiac muscles associated with physiologic imbalances after extreme exertion and stress (Williams and Thorne, 1996). In mammals, the disease has been documented primarily in artiodactyls after capture or restraint, hence common use of the more restrictive term “capture myopathy.” It is widely recognized, however, that EM may occur in any order of mammals under appropriate conditions of exertion and stress, and it is not always associated with capture. Reports of EM in carnivores are few, but the disease has been documented in red fox (*Vulpes*

vulpes; Kreeger et al., 1990), North American river otter (*Lutra Canadensis*; Hartup et al., 1999), mountain lion (*Puma concolor*; Wolfe and Miller, 2005), coyote (*Canis latrans*), badger (*Taxidea taxus*), and black-footed ferret (*Mustela nigripes*; Williams and Thorne, 1996). Here, we report a case of EM in a free-ranging grizzly bear (*Ursus arctos*) that died approximately 10 days after capture by leghold snare.

On 2 June 2003, we captured an adult (10-yr-old) male grizzly bear along the Berland River in west-central Alberta, Canada (53°43'N, 118°27'W) as part of the Foothills Model Forest Grizzly Bear Research Project (research goals are summarized by Stenhouse and Graham, 2005). The bear was captured by Aldrich leghold snare (Margo Supplies Ltd., High River, Alberta, Canada) and restrained by the left forelimb for 5–15 hr before arrival of the capture team. It was anesthetized by remote drug delivery (Pneu-Dart Inc., Williamsport, Pennsylvania, USA) using a combination of xylazine and zolazepam–tiletamine administered intramuscularly as xylazine (Cervizine 300®, Wildlife Pharmaceuticals, Inc., Fort Collins, Colorado, USA) at 2 mg/kg and Telazol® (Fort Dodge Laboratories, Inc., Fort Dodge, Iowa, USA) at 3 mg/kg estimated body weight (Cattet et al. 2003a). At the conclusion of handling, we administered atipamezole (Antisedan®, Novartis Animal Health Canada Inc., Mississauga, Ontario, Canada) at 0.15–0.20 mg/kg, half-volume intramuscularly and half-volume intravenously, to reverse effects of xylazine.

We recorded pulse and respiratory rates, rectal temperature, and hemoglobin oxygen saturation (Nellcor NPB-40 pulse oximeter, Nellcor, Pleasanton, California, USA) at onset of handling and every 15 min thereafter during an 80-min handling period. Vital signs remained stable and unremarkable (by temporal order, pulse rate, 95–71 beats/min; respiratory rate, 20–18 breaths/min; rectal temperature, 38.8–39.3 °C; hemoglobin oxygen saturation, 88–99%). We extracted a premolar tooth to estimate age by counting cementum annuli (Stoneberg and Jonkel, 1966). We collected blood from the femoral vein into sterile tubes for biochemistry analysis, and into an EDTA tube for measurement of complete blood count. The blood was centrifuged within 8 hr of collection, and serum was extracted and frozen (–20 °C) for biochemistry analysis using an Abbott Spectrum® Series II biochemistry analyzer (Abbott Laboratories Diagnostic Division, Abbott Park, Illinois, USA). We also chilled a whole blood sample in EDTA for determination of complete blood cell count within 24 hr of collection using an Abbott Cell-Dyn® 3200 hematology analyzer (Abbott). We weighed the bear in a sling suspended beneath a load scale (MSI-7200 Dynalink, Precision Giant Systems Inc., Edmonton, Alberta, Canada). It weighed 245 kg and was in normal body condition for sex, age, and time of year (Cattet et al., 2008). With respect to capture-induced injuries, we noted a 2 mm puncture in the right shoulder at the site of dart injection and a 2.5-cm laceration on the medial aspect of the snared wrist (carpus). We fitted the bear with a Televilt Simplex global positioning system (GPS) radiocollar (Televilt®, TVP Positioning AB, Lindesberg, Sweden) programed to acquire 3-dimensional locations at 4-hr time intervals. Our research protocol was reviewed and approved by the University of Saskatchewan's Committee on Animal Care and Supply and was in accordance with guidelines provided by the Canadian Council on Animal Care (2003).

We sighted the bear by helicopter twice over a 5-day period after release; 1 day after capture, moving through forest approximately 1.3 km from the capture site; and 5 days after capture, again moving through forest 2.8 km from the capture site. We were unable to observe the bear again until 15 days after capture when it was found dead in the same general area as on day 5. From GPS locations, we estimated the bear's movement rates during the first 5 days after capture to start at 27.4 m/hr over the first 12 hr, and then 65.9 m/hr over 19 hr, 34.3 m/hr over 39 hr, and 1.8 m/hr over 33 hr. After 5 days, movement rates remained low (<1 m/hr), and GPS locations became concentrated in the same general area. Average movement rate over the first 3 days after capture (41.7 m/hr) was low relative to many bears after capture, but it was still within expected range for an adult male captured in June (mean=71 m/hr and 95% confidence interval [CI]=36–106 m/hr calculated from movement records of 91 grizzly bears captured 150 times; Cattet et al., 2008). The GPS data indicated the bear died approximately 10 days after capture.

We recovered and transported the carcass to the Western College of Veterinary Medicine (University of Saskatchewan, Saskatoon, Saskatchewan, Canada) for pathologic examination. Although carcass weight was not recorded, the carcass seemed to be in moderate body condition based on presence of subcutaneous and visceral fat stores. Damage to the left front foot was greater than recognized at time of capture; the laceration was deep and medial metacarpal bone (I) was fractured, with the distal 1 cm missing. Autolysis prevented accurate detection of lesions in many tissues, including heart and kidneys. Nevertheless, the left superficial pectoral and biceps muscles were swollen and pale (Fig. 1). Furthermore, microscopic evaluation of sections of affected muscle stained with hematoxylin and eosin (H&E) re-

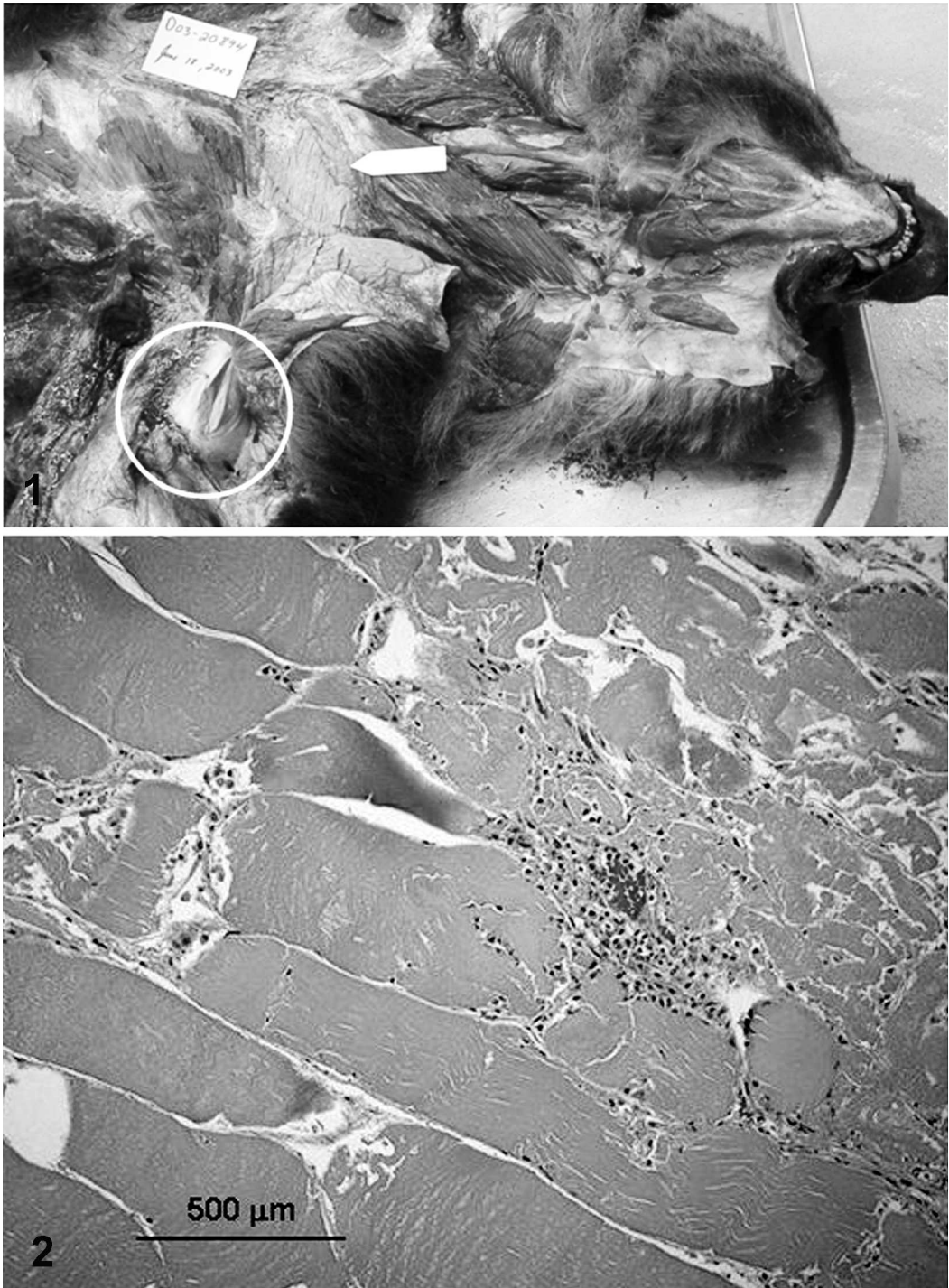


FIGURE 1. Widespread pallor of the left superficial pectoral (arrow) and biceps (circle) muscles of a grizzly bear that died approximately 10 days after capture by leghold snare.

FIGURE 2. Photomicrograph of the superficial pectoral muscle of a grizzly bear with severe exertional myopathy. The tissue section is characterized by degeneration and necrosis of myofibers, with moderate mononuclear inflammatory cell infiltrate. H&E stain. Bar=500 μ m.

vealed extensive degeneration and necrosis of myofibers (Fig. 2). The dart wound terminated as a large (3–4-cm) abscess with some associated muscle necrosis and heavy infection with the bacterium *Clostridium perfringens* confirmed by culture and polymerase chain reaction (PCR) detection of *C. perfringens* α -toxin.

Analysis of blood collected at capture showed a large number of neutrophils ($23.2 \times 10^9/l$), with many exhibiting toxic change, and a small number of lymphocytes ($0.6 \times 10^9/l$), a leukogram consistent with inflammation and stress. In comparison with reference intervals for captive brown bears (*Ursus arctos*; Teare, 2002), serum electrolyte results suggested mild loss of body water (sodium=158 mmol/l vs. 127–147 mmol/l and chloride=123 mmol/l vs. 94–110 mmol/l). In addition, serum enzyme concentrations (creatinine kinase [CK]=8,047 U/l vs. 3–167 U/l, aspartate aminotransferase [AST]=894 U/l vs. 27–167 U/l, and alanine aminotransferase [ALT]=172 U/l vs. 19–79 U/l) were moderately elevated. Although elevations in the aminotransferases AST and ALT can arise from either liver or skeletal muscle damage, the ratio of AST:ALT concentrations, and elevated CK suggest skeletal muscle injury was the most likely cause (Ishak, 2004).

A diagnosis of EM was supported on the basis of capture history (i.e., capture and prolonged restraint by leghold snare), slow movement rate between release and death, and findings from gross necropsy, histopathology, and serum biochemistry. We were unable, however, to determine whether EM was the primary cause of death in this bear because autolysis precluded gross and microscopic evaluation of some tissues, e.g., heart and kidney. Nevertheless, comparison of serum enzyme levels in this bear with results from 127 leghold snare captures of grizzly bears for the Foothills Model Forest Grizzly Bear Research Project from 1999 to 2006 suggests EM is not generally a cause of mortality in this species. Although enzyme

values for this bear were moderately elevated, we measured higher serum concentrations of AST (1171–1665 U/l) or CK (8,729–37,280 U/l) in 14 other snared bears, but all were known to have survived over the research period with exception of two bears killed by poachers. Assuming AST and CK levels are associated with relative severity of muscle injury in grizzly bears as documented in other species (Ishak, 2004; Singh et al., 2005) it would seem bears with more severe or extensive muscle lesions survived. We suggest the cumulative effect of EM with other capture-related factors contributed to the eventual death of this bear 10 days after capture. Although existence of these factors is speculative, we suggest one possibility may have been systemic infection arising from an open fracture of the left front foot. The other visible injury, the abscess associated with the dart wound, was less likely to have contributed to the bear's death because the abscess was well contained. Nonetheless, it should be noted that fatal clostridial myonecrosis in a black bear in association with dart injection has been reported previously (Barnes and Rogers, 1980).

Our diagnosis of “nonfatal” EM in a grizzly bear after capture by leghold snare has potential implications for use of leghold snares, a method of capture used extensively for ursids, but also for other wild carnivores, especially canids and felids. Although this is the first report of EM in a snared grizzly bear, several reports of elevated serum enzymes in snared bears similar or higher to values reported here exist (e.g., see Huber et al., 1997; Powell, 2005), including a previous report of the Foothills Model Forest Grizzly Bear Research Project (Cattet et al., 2003b). In addition, EM has been diagnosed in other species captured by leghold snare or traps, including red foxes (Kreeger et al., 1990), coyotes, and badgers (Williams and Thorne, 1996). If EM is typically nonfatal in these carnivore species, including grizzly bears, it does not

preclude the possibility that it may cause prolonged and unnecessary suffering. Furthermore, from the standpoint of scientific inquiry, nonfatal EM may seriously bias movement, survival, and mortality data obtained from radiocollared animals (Williams and Thorne, 1996). Within the Foothills Model Forest Grizzly Bear Research Project, we have documented movement rates of radiocollared grizzly bears to decrease on average 43% below normal (95% CI=26–55%) immediately after capture and then return to approximately normal rates in 3–6 wk with severity of effect greater when AST levels are high (Cattet et al., 2008). Obviously, the need exists to modify application of this method to reduce injury or to develop safer capture techniques that are as effective and practical as leghold snares. At the same time, we require sensitive techniques to detect and evaluate injury on-site before a captured animal is released. Analysis of serum biochemistry markers as done in this study is of limited value because of the delay between collection and analysis of blood.

For funding, we thank the many partners of the Foothills Model Forest Grizzly Bear Research Program, including Ainsworth Engineered Canada, Alberta Conservation Association, Alberta Innovation and Science, Alberta Newsprint Company Timber Ltd., Alberta Sustainable Resource Development, Anadarko Canada Corporation, Burlington Resources Canada Ltd., Canadian Forest Products Ltd., Conoco Phillips Canada, Daishowa-Marubeni International Ltd., Devon Canada Corporation, Encana, Foothills Model Forest, Hinton Wood Products, Husky Oil, Manning Forestry Research Fund, Millar Western, Natural Science and Engineering Research Council (NSERC) of Canada, Parks Canada (Jasper National Park), Petro Canada Ltd., Shell Canada Ltd., Spray Lakes Sawmills, Sundance Forest Industries Ltd., Talisman Energy Inc., TransCanada Pipeline, University of

Saskatchewan, and Weyerhaeuser Company Ltd. For field support during bear captures, we thank R. Booker, N. Caulkett, M. Dupuis, E. Geymonat, B. Goski, D. Hobson, J. Honeyman, T. Larsen, C. Mamo, G. McHutchon, T. Orban, J. Saunders, M. Urquhart, and numerous Alberta Fish and Wildlife Officers and Jasper park wardens who provided support during bear capture. We also thank J. Cranston and J. Duval for geographic information system support and K. Graham and R. Munro for expertise in programming and management of our radiocollars and GPS data.

LITERATURE CITED

- BARNES, D. M., AND L. L. ROGERS. 1980. Clostridial myonecrosis in a black bear associated with drug administration. *Journal of Wildlife Diseases* 16: 315–317.
- CANADIAN COUNCIL ON ANIMAL CARE. 2003. CCAC guidelines on the care and use of wildlife. Canadian Council on Animal Care, Ottawa, Ontario, Canada.
- CATTET, M. R. L., N. A. CAULKETT, AND G. B. STENHOUSE. 2003a. Anesthesia of grizzly bears using xylazine-zolazepam-tiletamine. *Ursus* 14: 88–93.
- , K. CHRISTISON, N. A. CAULKETT, AND G. B. STENHOUSE. 2003b. Physiologic responses of grizzly bears to different methods of capture. *Journal of Wildlife Diseases* 39: 649–654.
- , J. BOULANGER, G. STENHOUSE, R. A. POWELL, AND M. J. REYNOLDS-HOGLAND. 2008. An evaluation of long-term capture effects in ursids: Implications for wildlife welfare and research. *Journal of Mammalogy* 89: In press.
- HARTUP, B. K., G. V. KOLLIAS, M. C. JACOBSEN, B. A. VALENTINE, AND K. R. KIMBER. 1999. Exertional myopathy in translocated river otters from New York. *Journal of Wildlife Diseases* 35: 542–547.
- HUBER, D., KUSAK, J., ŽVORC, Z., AND R. B. RAFAJ. 1997. Effects of sex, age, capturing method, and season on serum chemistry values of brown bears in Croatia. *Journal of Wildlife Diseases* 33: 790–794.
- ISHAK, K. 2004. Hepatobiliary and skeletal muscle enzymes and liver function tests. *In* Veterinary laboratory medicine interpretation and diagnosis. 3rd Edition, D. J. Meyer and J. W. Harvey (eds.). W. B. Saunders Co., St. Louis, Missouri. pp. 169–192.
- KREEGER, T. J., P. J. WHITE, U. S. SEAL, AND J. R. TESTER. 1990. Pathological responses of red

- foxes to foothold traps. *Journal of Wildlife Management* 54: 147–160.
- POWELL, R. A. 2005. Evaluating welfare of American black bears (*Ursus americanus*) captured in foot snares and in winter dens. *Journal of Mammalogy* 86: 1171–1177.
- SINGH, D., V. CHANDER, AND K. CHOPRA. 2005. Rhabdomyolysis. *Methods and Findings in Experimental and Clinical Pharmacology* 27: 39–48.
- STENHOUSE, G. B., AND K. GRAHAM. 2005. *Foothills Model Forest grizzly bear research program 1999–2003 final report*, http://www.fmf.ca/GB/GB_report7.pdf. Accessed January 2006.
- STONEBERG, R. P., AND C. J. JONKEL. 1966. Age determination in black bears by cementum layers. *Journal of Wildlife Management* 30: 411–414.
- TEARE, J. A. (ed.). Reference ranges for physiological values in captive wildlife. International Species Information System, Apple Valley, Minnesota.
- WILLIAMS, E. S., AND E. T. THORNE. 1996. Exertional myopathy. *In* *Noninfectious diseases of wildlife*. 2nd Edition, A. Fairbrother, L. N. Locke and G. L. Hoff (eds.). Iowa State University Press, Ames, Iowa. pp. 181–193.
- WOLFE, L. L., AND M. W. MILLER. 2005. Suspected secondary thiafentanil intoxication in a captive mountain lion (*Puma concolor*). *Journal of Wildlife Diseases* 41: 829–833.

Received for publication 30 July 2007.