

Armillifer Larvae in a Ferret-badger (*Melogale personata*) from South Vietnam

Authors: MURRELL, LT K. DARWIN, CROSS, JOHN H., and JONES, LT GWILYM S.

Source: Bulletin of the Wildlife Disease Association, 5(3) : 144-145

Published By: Wildlife Disease Association

URL: <https://doi.org/10.7589/0090-3558-5.3.144>

The BioOne Digital Library (<https://bioone.org/>) provides worldwide distribution for more than 580 journals and eBooks from BioOne's community of over 150 nonprofit societies, research institutions, and university presses in the biological, ecological, and environmental sciences. The BioOne Digital Library encompasses the flagship aggregation BioOne Complete (<https://bioone.org/subscribe>), the BioOne Complete Archive (<https://bioone.org/archive>), and the BioOne eBooks program offerings ESA eBook Collection (<https://bioone.org/esa-ebooks>) and CSIRO Publishing BioSelect Collection (<https://bioone.org/csiro-ebooks>).

Your use of this PDF, the BioOne Digital Library, and all posted and associated content indicates your acceptance of BioOne's Terms of Use, available at www.bioone.org/terms-of-use.

Usage of BioOne Digital Library content is strictly limited to personal, educational, and non-commercial use. Commercial inquiries or rights and permissions requests should be directed to the individual publisher as copyright holder.

BioOne is an innovative nonprofit that sees sustainable scholarly publishing as an inherently collaborative enterprise connecting authors, nonprofit publishers, academic institutions, research libraries, and research funders in the common goal of maximizing access to critical research.

CASE REPORT

Armillifer Larvae in a Ferret-badger (*Melogale personata*) from South Vietnam

During a study of anthroponosis in the Presquille de Tien Sha area of DaNang, South Vietnam, larvae of *Armillifer* sp. were found in the viscera of a ferret-badger, *Melogale personata*. The host, an adult female, was caught in scrub vegetation approximately 1.8 km west and 0.4 km north of Mt. Sontra at an elevation of 600 meters.

Hundreds of the small whitish larvae (9-12 mm x 1-2 mm) were found coiled in cysts in the mesenteries and in nearly every organ in the abdominal cavity (Fig. 1). Although the infestation was massive and the organisms had penetrated more than superficially into some organs (Fig. 2), no inflammatory reaction was found in the tissues surround-

ing the larvae. This observation further supports the contention of Self and Kuntz (1969, J. Parasitol., 53: 202-206) that in the natural host pentastomids elicit little, if any, pathological tissue response.

The parasites, too immature for species identification, were identified by Dr. J. Teague Self as members of the genus *Armillifer*. *Armillifer moniliformis* as a larva or nymph has been recorded for a number of various mammals (Stabler and Self, 1967, J. Parasitol. 52: 923). The larva of this genus, however, has not been reported previously from the ferret-badger and, therefore, the present report constitutes a new host record. The reason for such a massive infection

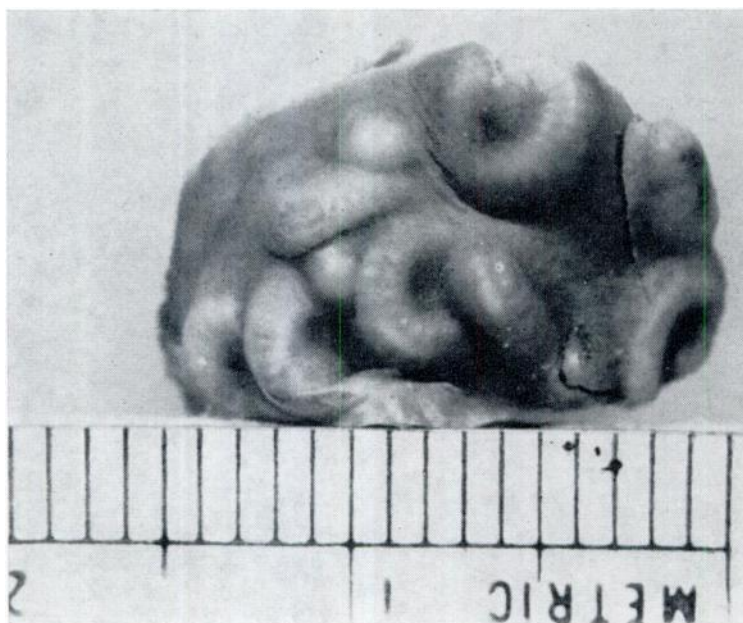

FIGURE 1. Portion of ferret-badger liver with encysted larvae of *Armillifer* sp.

is not known but was probably due to the animal's eating a gravid female pentastome either passed by a stressed snake, or by eating an infected snake. A tremendous number of eggs would be obtained either way (Self, personal communication).

The authors wish to thank Doctors J. Teague Self of the University of

Oklahoma, H. Huizinga, Western Illinois State University, and G. Cosgrove of the Oak Ridge National Laboratory, Tennessee, for assistance in the identification of the parasite, and Commander J. W. Fresh, MC, USN of NAMRU-2 for the preparation and interpretation of the histological sections.

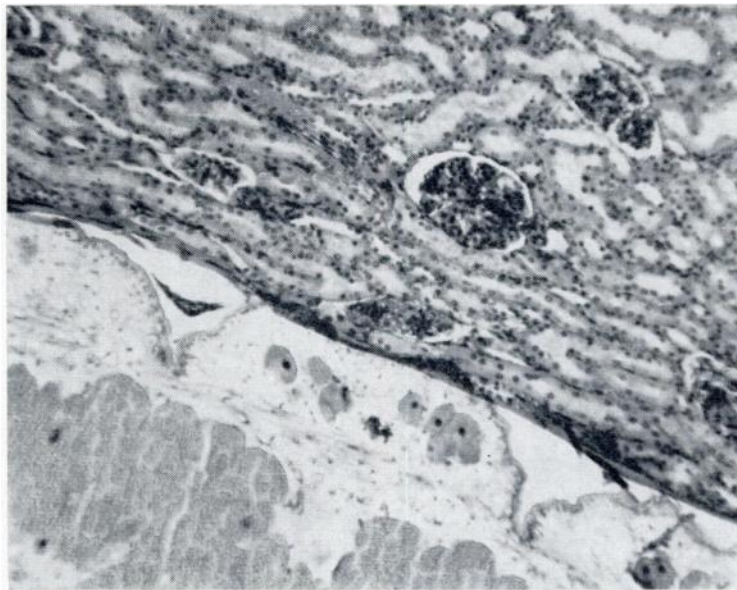


FIGURE 2. Section of ferret-badger kidney showing *Armillifer* sp. larva in the cortex (x 100). Note absence of tissue reaction.

This study was supported in part through funds provided by the Bureau of Medicine and Surgery, Navy Department, for Work Unit MR4305. 12-3003. The opinions and assertions contained herein are those of the authors and are not to be construed as official or as reflecting the views of the Navy Department or the Naval Service at large.

LT K. DARWIN MURRELL, MSC, USNR, JOHN H. CROSS, and LT GWILYM S. JONES, MSC, USNR, U.S. Naval Medical Research Unit No. 2, Box 14, APO San Francisco 96263. April 28, 1969.