

## VENTRAL HERNIA IN A WHITE-TAILED DEER

Authors: WOBESER, G., and MacLENNAN, R.

Source: Journal of Wildlife Diseases, 7(1) : 1-2

Published By: Wildlife Disease Association

URL: <https://doi.org/10.7589/0090-3558-7.1.1>

---

The BioOne Digital Library (<https://bioone.org/>) provides worldwide distribution for more than 580 journals and eBooks from BioOne's community of over 150 nonprofit societies, research institutions, and university presses in the biological, ecological, and environmental sciences. The BioOne Digital Library encompasses the flagship aggregation BioOne Complete (<https://bioone.org/subscribe>), the BioOne Complete Archive (<https://bioone.org/archive>), and the BioOne eBooks program offerings ESA eBook Collection (<https://bioone.org/esa-ebooks>) and CSIRO Publishing BioSelect Collection (<https://bioone.org/csiro-ebooks>).

Your use of this PDF, the BioOne Digital Library, and all posted and associated content indicates your acceptance of BioOne's Terms of Use, available at [www.bioone.org/terms-of-use](http://www.bioone.org/terms-of-use).

Usage of BioOne Digital Library content is strictly limited to personal, educational, and non-commercial use. Commercial inquiries or rights and permissions requests should be directed to the individual publisher as copyright holder.

---

BioOne is an innovative nonprofit that sees sustainable scholarly publishing as an inherently collaborative enterprise connecting authors, nonprofit publishers, academic institutions, research libraries, and research funders in the common goal of maximizing access to critical research.

Brown, J., D. L. Dawe and R. B. Davis, BOBWHITES ( <i>Colinus virginianus</i> ) FAILURE AS VECTORS OF FOWL CHOLERA IN TURKEYS .....	63
Murphy, B. D. and R. E. Clugston, BILATERAL TESTICULAR DEGENERATION IN A WILD MULE DEER ( <i>Odocoileus hemionus</i> ) .....	67
Lund, E. E. and A. M. Chute, BOBWHITE, <i>Colinus virginianus</i> , AS HOST FOR <i>Heterakis</i> and <i>Histomonas</i> .....	70
Wolke, R. E. and F. R. Trainor, GRANULOMATOUS ENTERITIS IN <i>Catostomus commersoni</i> ASSOCIATED WITH DIATOMS .....	76
LETTER TO THE EDITOR .....	80
ANNOUNCEMENTS .....	81

### VENTRAL HERNIA IN A WHITE-TAILED DEER

During March, 1970, a white-tailed deer (*Odocoileus virginianus*) with a large pendulous mass on the ventral abdominal wall was observed near Redvers, Saskatchewan. The deer moved slowly and was incapacitated to such a degree that it was easily approached and shot with a handgun by a local police officer.

The animal was submitted for necropsy to the Department of Pathology, Western College of Veterinary Medicine. The deer was a female, slightly in excess of 1½ years of age, in poor body condition with serous atrophy of all fat depots. The uterus contained twin fetuses. A soft, fluctuating globular mass 28 cm in dia-

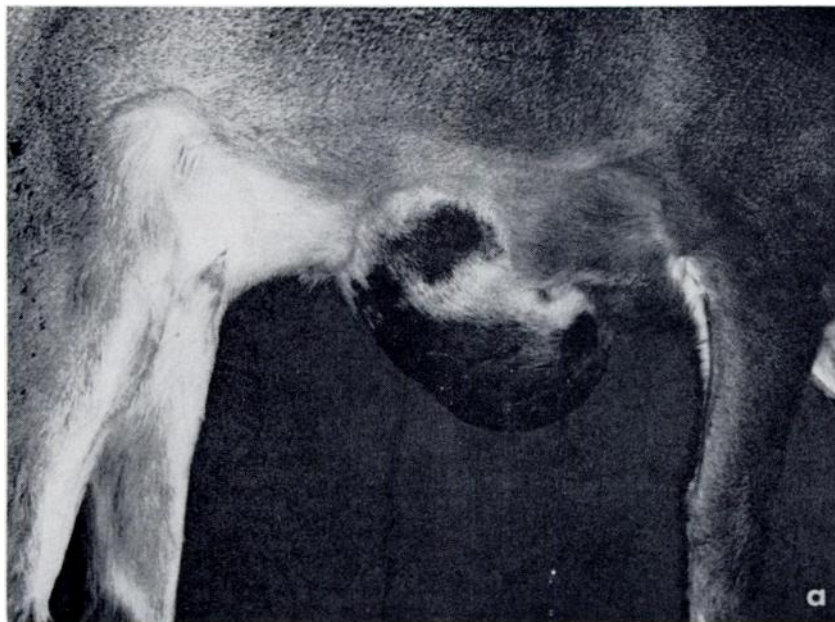


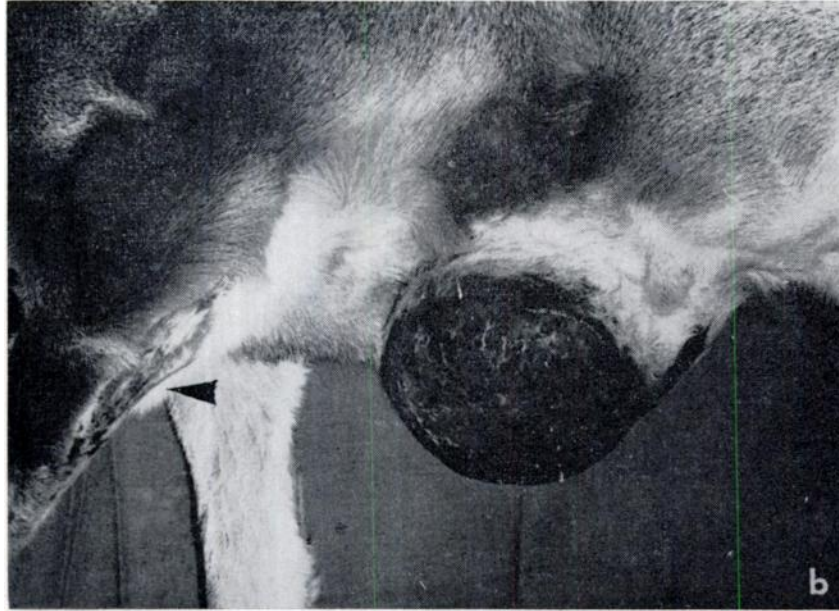
FIGURE 1. Ventral hernia

(a) right view

This One



AKOW-QSQ-RB42



(b) left view, note loss of hair on left foreleg (arrow).

meter was present on the ventral abdominal wall immediately posterior to the sternum (Figure 1). The skin covering this growth was abraded and denuded of hair. The hair on the caudal surface of the left foreleg was worn in the area which would contact the mass during movement.

Reflection of the skin revealed a hernial sac which contained the entire abomasum, over half of the jejunum, the entire spiral colon, and an 8 cm portion of the ventral sac of the rumen. The 7.5 cm diameter hernial ring was smooth walled, and was located in the angle between the xiphoid cartilage and the last sternal rib on the left side. All structures in the hernial sac were freely moveable and reducible with the exception of the abomasum, the proximal and distal portions of which were tightly adherent to the hernial ring. The ingesta in all regions of the alimentary tract appeared normal. Histologically, the major portion of the wall of the hernial sac was composed of mature fibrous tissue.

Ventral hernias are relatively common in domestic animals, and are usually the

result of mechanical injury to the abdominal wall, (Jubb and Kennedy, 1963, *Pathology of Domestic Animals*, Vol. 2, Academic Press, New York and London), (Runnells *et al.*, 1965, *Principles of Veterinary Pathology*, Iowa State University Press, Ames, Iowa). In this case the presence of adhesions between the abomasal serosa and the hernial ring might support a traumatic origin for this hernia. There was no evidence that the hernia interfered materially with digestion; the poor condition of the animal may have been due to the physical presence of the hernia interfering with normal locomotion.

G. WOBESER

*Department of Pathology  
Western College of Veterinary Medicine  
University of Saskatchewan  
Saskatoon, Saskatchewan*

R. MacLENNAN

*Wildlife Branch  
Department of Natural Resources  
Province of Saskatchewan  
Saskatoon, Saskatchewan*

June 2, 1970