

Use of sildenafil citrate in a cat with Eisenmenger's syndrome and an atrial septal defect

Authors: Chow, Ke Shuan, Beijerink, Niek J, Ettinger, Stephen, Fliegner, Reuben, Beatty, Julia A, et al.

Source: Journal of Feline Medicine and Surgery Open Reports, 1(1)

Published By: SAGE Publishing

URL: <https://doi.org/10.1177/2055116915579680>

BioOne Complete ([complete.BioOne.org](https://complete.bioone.org)) is a full-text database of 200 subscribed and open-access titles in the biological, ecological, and environmental sciences published by nonprofit societies, associations, museums, institutions, and presses.

Your use of this PDF, the BioOne Complete website, and all posted and associated content indicates your acceptance of BioOne's Terms of Use, available at www.bioone.org/terms-of-use.

Usage of BioOne Complete content is strictly limited to personal, educational, and non - commercial use. Commercial inquiries or rights and permissions requests should be directed to the individual publisher as copyright holder.

BioOne sees sustainable scholarly publishing as an inherently collaborative enterprise connecting authors, nonprofit publishers, academic institutions, research libraries, and research funders in the common goal of maximizing access to critical research.



Use of sildenafil citrate in a cat with Eisenmenger's syndrome and an atrial septal defect

Journal of Feline Medicine and Surgery
Open Reports
 1–5

© The Author(s) 2015
 Reprints and permissions:
sagepub.co.uk/journalsPermissions.nav
 DOI: 10.1177/2055116915579680
jfmsopenreports.com



Ke Shuan Chow¹, Niek J Beijerink¹, Stephen Ettinger²,
 Reuben Fliegner¹, Julia A Beatty¹ and Vanessa R Barrs¹

Abstract

A 2-year-old male neutered Siamese cat presenting with weakness and dyspnoea was diagnosed with an atrial septal defect and pulmonary hypertension, which resulted in right-to-left shunting (Eisenmenger's syndrome). The cat was treated with sildenafil (0.25–0.6 mg/kg) for 10 months. There were no apparent treatment-related adverse effects. Improvement in clinical signs was noted, although increasing doses of sildenafil were required. After 10 months the cat significantly deteriorated and was euthanased.

Accepted: 22 July 2014

A 2-year-old male neutered Siamese cat, weighing 4.0 kg, was referred to the Valentine Charlton Cat Centre with a 2 day history of weakness, open-mouth breathing and inappetence. Since the age of 8 months, the cat had been treated by the primary veterinarian for suspected anxiety with fluoxetine (Reconcile, 4 mg PO q24h; Elanco).

On examination, the cat had a poor body condition (body condition score 4/9), cyanotic oral mucous membranes and a grade II/VI systolic heart murmur with sternal peak murmur intensity. Open-mouth breathing was intermittent, and was exacerbated by stress and handling. Blood oxygen saturation (SpO₂) was 85–88% and did not improve after nasal catheter oxygen supplementation (0.5 l/min). The packed cell volume (PCV) was 48 (reference range 30–45 l/l) and total plasma protein (TPP) was 90 (reference range 59–78 g/l). On three-view thoracic radiographs, the vertebral heart size (VHS) was 7.9 (upper limit of reference range 8.0), and the pulmonary lobar arteries were dilated and tortuous (Figures 1 and 2). An electrocardiogram showed narrow QRS complexes with deep S-waves and right axis deviation suggestive of right-sided cardiac enlargement. Echocardiography revealed severe right ventricular (RV) concentric hypertrophy (RV diastolic free wall measurement 6.4 mm, left ventricular diastolic free wall measurement 5.8 mm), with paradoxical interventricular septum motion. The right atrium was subjectively severely enlarged, and there was severe dilation of the

main pulmonary artery (PA) and right PA branch (PA:aorta ratio 1.9) (Figures 3 and 4). An insufficiency jet between the dilated PA and RV measured across the pulmonary valve was 4.1 m/s (estimated peak instantaneous diastolic pressure gradient of 68 mmHg), consistent with moderate-to-severe pulmonary hypertension (PH) (Figures 5 and 6). A 5.7 mm atrial septal defect (ASD) was identified with right-to-left shunting on colour Doppler, with a maximum velocity of approximately 0.45 m/s (estimated peak instantaneous pressure gradient of 0.81 mmHg) (Figure 4). An agitated saline microbubble contrast study performed via the left cephalic vein confirmed a right-to-left shunt across the interatrial septum.

The cat was diagnosed with ASD and suspected pulmonary vascular obstructive disease leading to PH (Eisenmenger's syndrome). Symptomatic treatment for

¹Valentine Charlton Cat Hospital, Department of Veterinary Science, The University of Sydney, Sydney, Australia

²The Evelyn Williams Visiting Professor, Department of Veterinary Science, The University of Sydney, Sydney, Australia

Corresponding author:

Ke Shuan Chow BVSc, MVetClinStud, MANZCVS (Small Animal Medicine), Valentine Charlton Cat Centre, Evelyn Williams Building, B10 Faculty of Veterinary Science, The University of Sydney, Sydney, New South Wales 2006, Australia
 Email: keshuanchow@gmail.com



Creative Commons CC-BY-NC: This article is distributed under the terms of the Creative Commons Attribution-NonCommercial 3.0 License (<http://www.creativecommons.org/licenses/by-nc/3.0/>) which permits non-commercial use, reproduction and distribution of the work without further permission provided the original work is attributed as specified on the SAGE and Open Access page (<http://www.uk.sagepub.com/aboutus/openaccess.htm>).

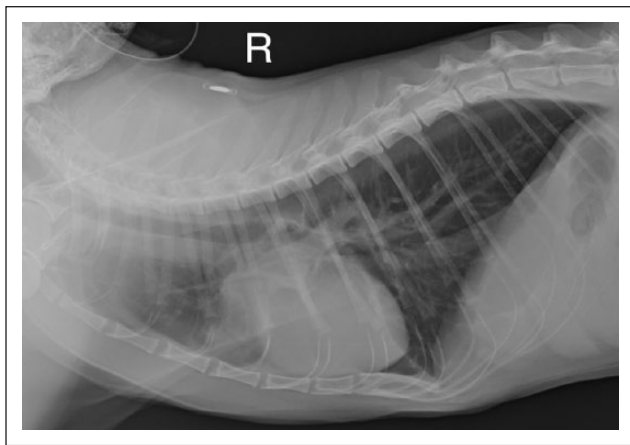


Figure 1 Right (R) lateral recumbent radiograph of the thorax, day 1. Note the cardiomegaly and dilated, tortuous pulmonary lobar arteries

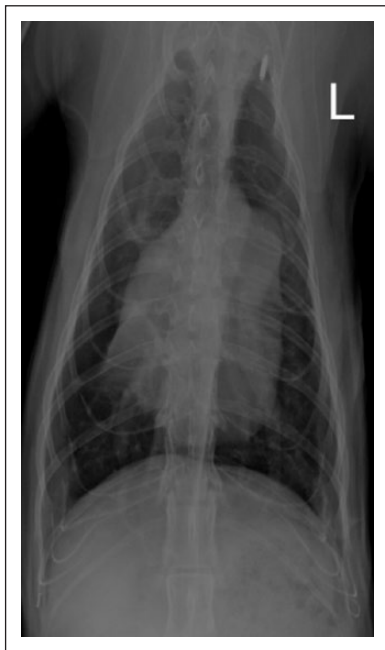

Figure 2 Ventrodorsal thoracic radiograph, day 1. L = left

PH to alleviate right-to-left shunting was commenced with sildenafil (0.25 mg/kg PO q12h). A low dose was chosen because of the unknown pharmacokinetics of sildenafil in cats with heart disease, especially considering that cats often vary in their ability to metabolise drugs when compared with other species.

After an initial increase in activity and resolution of dyspnoea lasting approximately 2 weeks, the cat became more lethargic with short episodes of open-mouth breathing when anxious or excited. The dose of sildenafil was increased to 0.5 mg/kg PO q12h. At re-evaluation 5 weeks after presentation, the cat was reported to have had fewer episodes of open-mouth breathing that lasted

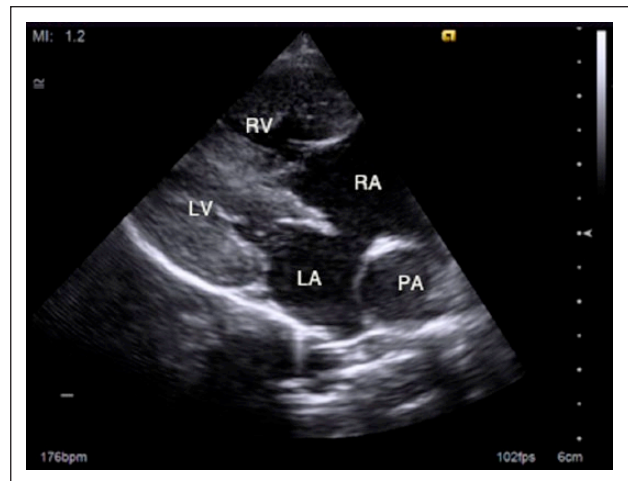


Figure 3 Right parasternal four-chamber view. Note the high-septal atrial septal defect, right ventricular (RV) concentric hypertrophy, right atrial (RA) enlargement, and severely dilated right pulmonary artery (PA). LV = left ventricle; LA = left atrium

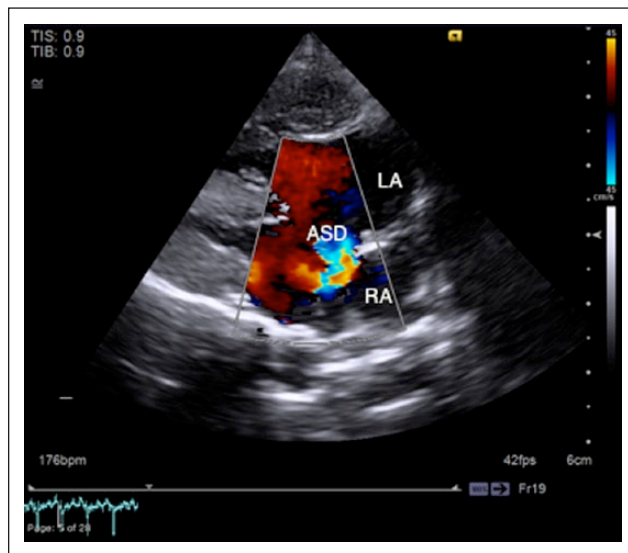


Figure 4 Right parasternal four-chamber view with colour Doppler interrogation of the atrial septum. Note the right-to-left shunting through the atrial septum defect (ASD) just before the onset of the QRS complex on the electrocardiogram. LA = left atrium; RA = right atrium

for shorter periods than before treatment. The owners also reported increased activity. PCV was 38 and TPP was 82 g/l. Pulse oximetry revealed an SpO₂ on room air of 80%. Repeat echocardiograph showed bidirectional shunting (with some left-to-right flow), and subjectively less right-to-left shunting.

Three and a half months after initial presentation, the cat developed recurrent respiratory distress following the introduction of a new kitten to the household. The episode consisted of a prolonged episode of open-mouth

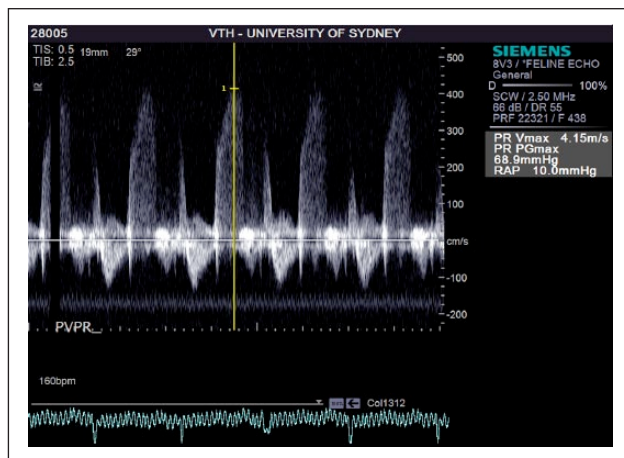


Figure 5 Right parasternal short axis view with continuous wave Doppler interrogation of the pulmonic valve. Note the signal associated with pulmonic insufficiency that is directed towards the probe

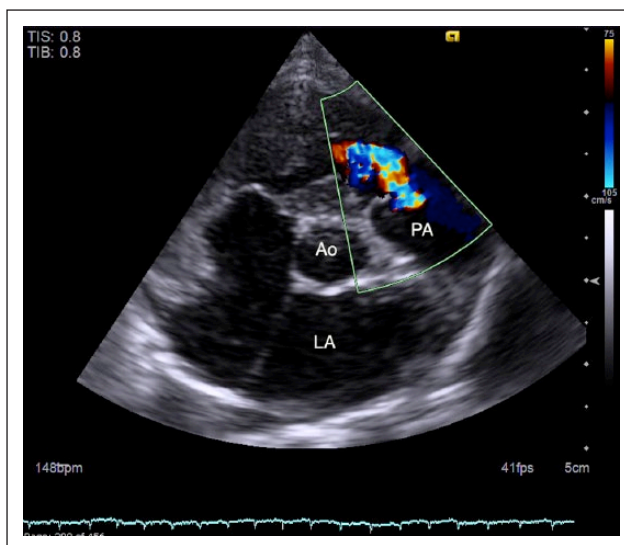


Figure 6 Right parasternal short axis view showing pulmonic valvular insufficiency. PA = pulmonary artery; Ao = aorta; LA = left atrium

breathing and weakness that lasted several minutes. The cat had also developed progressive intermittent coughing and wheezing prior to presentation. Repeat radiographs showed persistent dilated, tortuous pulmonary lobar arteries, and that cardiomegaly had progressed (VHS increased to 9.0). The cardiomegaly was considered to be most likely due to ongoing RV hypertrophy and right atrial dilation secondary to severe PH. In addition, there was a subtle bilateral bronchointerstitial pattern throughout the lung fields, suggestive of a component of airway disease contributing to the coughing and wheezing, such as allergic airway disease (considered the most likely given the signalment and history).

Less likely considerations included lungworm, neoplasia or mild primary bronchopneumonia. The patient's anaesthetic risk was considered significant, and the owners elected not to proceed with bronchoalveolar lavage to further investigate primary respiratory disease. Empirical treatment was commenced with doxycycline (6.5 mg/kg PO q12h) to treat potential secondary bacterial infection. An echocardiogram and agitated saline microbubble contrast study showed significant right-to-left shunting. The sildenafil dose was increased to 0.75 mg/kg PO q12h (2.8 mg PO q12h). The owners reported a reduction in both open-mouth breathing and coughing/wheezing.

The patient remained relatively stable for a further 4.5 months. At 8 months after initial presentation the cat deteriorated again, having several episodes of collapse and open-mouth breathing over the course of a week. These episodes occurred following exercise or play. Clinical examination revealed jugular pulses extending halfway up the neck. An echocardiographic study revealed further advancement of right-sided heart enlargement (RV diastolic free wall measurement 7.94 mm). The insufficiency jet measured across the tricuspid valve had a velocity of 3.34 m/s, which equated to a pressure gradient of 45 mmHg and an estimated RV diastolic pressure of 55 mmHg. Sildenafil was increased to 6.25 mg PO q12h (1.6 mg/kg PO q12h). However, 2 months after this re-evaluation (a total of 10 months after diagnosis), the cat became persistently lethargic and had multiple syncopal episodes, accompanied by loss of faecal and urinary continence, within a week. The owners elected euthanasia and declined necropsy.

Discussion

Eisenmenger's syndrome is a condition whereby pulmonary vascular obstructive disease causes PA pressures to approach systemic levels and blood is shunted right-to-left or bidirectional across a septal defect or patent vessel. Underlying congenital defects resulting in Eisenmenger's syndrome include ASD, ventricular septal defect and patent ductus arteriosus (PDA). This phenomenon has been well described in humans.^{1,2} It has also been described in a rabbit and in dogs.^{3,4} To our knowledge, there have been only three reports of feline Eisenmenger's syndrome, none of which utilised sildenafil as a treatment.⁵⁻⁷

In Eisenmenger's syndrome, shunting is initially left-to-right causing chronic pulmonary circulation overload and flow-related PH. Increased PA pressure occurs as a result of vasoconstriction and progressive PA wall thickening.⁸ The latter accounts for the dilated, tortuous pulmonary lobar arteries viewed on plain thoracic radiographs of our patient. Increased pulmonary vascular resistance leads to right-sided pressure overload and concentric hypertrophy, also evident in our patient.

Eventually, shunt reversal can occur secondary to PH, resulting in right-to-left shunting, hypoxia and reduced exercise tolerance.^{1,2} In our patient, exercise and stress (such as the introduction of a new kitten into the household) worsened the cat's signs. This may have been due to sympathetic nervous system-mediated decreases in systemic vascular resistance and acute increases in PA pressure, resulting in increased right-to-left shunting and possibly cardiovascular collapse. The resultant chronic hypoxia can also lead to absolute erythrocytosis and hyperviscosity syndrome,² although this was not the case in our patient. It is difficult to speculate on the reason for lack of erythrocytosis. Erythrocytosis was also not a feature of the other feline Eisenmenger's syndrome case for which haematocrit was measured.⁶ In our patient, the lack of erythrocytosis may have been due to relatively recent shunt reversal, which is consistent with the acute decompensation prior to presentation.

The presence in our patient of a high-velocity pulmonary insufficiency jet with an estimated pressure gradient of 68 mmHg was suggestive of severe PH. The gold standard for PH diagnosis is cardiac catheterisation.^{2,9} Evidence of PH can be demonstrated using Doppler echocardiography and the use of the modified Bernoulli equation to calculate PA pressure gradients.⁹ The latter method has limitations, including inaccuracy due to operator factors and a failure to account for flow velocity acceleration and viscous friction. However, it provides a reasonable estimation of pressure gradients across the tricuspid valve and PA in dogs.¹⁰ As it is non-invasive and performed without general anaesthesia, Doppler echocardiography was deemed the most appropriate modality for diagnosis of PH in our patient.

The use of sildenafil to treat PH has, to our knowledge, not been reported in the cat. Sildenafil is a highly selective phosphodiesterase type V inhibitor, acting preferentially to vasodilate arteries in the lungs and corpus cavernosum. In the cat, sildenafil has been used intravenously to evaluate oesophageal motility,¹¹ and via direct injection into the corpus cavernosum to evaluate erectile function.¹² Two other cases of PH in cats had spontaneous resolution following removal of the inciting cause (cessation of the chemotherapeutic agent carboplatin in one case and treatment of *Aelurostrongylus abstrusus* infection in the other).^{13,14} However, in our case, correction of the underlying cause (ASD) was not feasible.

Of three other reported cats with Eisenmenger's syndrome, one was treated with furosemide, nitroglycerine, dobutamine and oxygen supplementation but showed a poor response;⁶ one case received oxygen only;⁷ and no treatment was described for the other case.⁵

In contrast, the use of sildenafil is well described in humans with PH secondary to underlying congenital defects, with evidence demonstrating improved functional

class, haemodynamics, quality of life and survival rates.^{15–19} In dogs, sildenafil has demonstrated benefit in dogs with PH of various aetiologies.^{4,20–22} Despite the lack of evidence for use in sildenafil for treatment of PH in cats, the potential benefit outweighed the risk of doing nothing. The cat tolerated the sildenafil at dose rates of 0.25–1.6 mg/kg with no apparent adverse effects.

Phlebotomy is employed in humans with Eisenmenger's syndrome to treat erythrocytosis in patients showing clinical signs of hyperviscosity syndrome.^{1,2} In some cases, reduced peripheral vascular resistance or systemic arterial pressure (eg, via stress and increased sympathetic drive, dehydration or hypovolaemia) can worsen right-to-left shunting and hypoxaemia. Additionally, repeated phlebotomy can result in iron deficiency and reduction of oxygen-carrying capacity.^{1,2} Phlebotomy has also been advocated as a mainstay of management of reverse PDA in dogs.²³ We elected not to perform phlebotomy in our patient as the cat was never markedly erythrocytic and did not show overt signs of hyperviscosity.

In humans, complete heart–lung transplants (or lung transplants and concomitant repair of the cardiac defect) are sometimes performed in patients with Eisenmenger's syndrome;² however, this is an impractical consideration in small animal medicine.

The causes of deterioration and death in our patient are unknown but may include progression of suspected bronchopulmonary disease, or cardiac complications. In a study evaluating causes of mortality in human patients with Eisenmenger's syndrome, 22.9% died of right-sided congestive heart failure, 3.2% of cerebral abscesses and 1.6% from endocarditis. Negative prognostic factors include RV dysfunction and young-onset clinical signs, both of which apply to our patient.^{24,25}

Expected survival times in cats with Eisenmenger's syndrome remain unknown. Another cat treated with furosemide, nitroglycerine, dobutamine and supplemental oxygen died of cardiac arrest 48 h after commencement of treatment.⁶ In contrast, our cat survived 10 months after diagnosis, with a good quality of life and reasonable functional capacity. In humans, survival in patients with Eisenmenger's syndrome can be relatively long, with a reported median survival time of 53 years.²⁶ Use of sildenafil has been shown to result in a lower risk of death, as well as improved quality of life.^{17,18}

Conclusions

The clinical improvement of our case suggests that sildenafil may be useful in the management of cats with Eisenmenger's syndrome. No apparent adverse effects were noted at dose rates of 0.25–1.6 mg/kg.

Funding The authors received no specific grant from any funding agency in the public, commercial or not-for-profit sectors for the preparation of this case report.

Conflict of interest The authors declare no conflicts of interest.

References

- Beghetti M and Galie N. **Eisenmenger's syndrome: a clinical perspective in a new therapeutic era of pulmonary arterial hypertension.** *J Am Coll Cardiol* 2009; 53: 733–740.
- Diller GP and Gatzoulis MA. **Pulmonary vascular disease in adults with congenital heart disease.** *Circulation* 2007; 115: 1039–1050.
- Li X, Murphy JC and Lipman NS. **Eisenmenger's syndrome in a New Zealand white rabbit.** *Lab Anim Sci* 1995; 45: 618–620.
- Namakura K, Yamasaki M, Ohta H, et al. **Effects of sildenafil citrate of five dogs with Eisenmenger's syndrome.** *J Small Anim Pract* 2011; 52: 595–598.
- Church DB and Allan GS. **Atrial septal defect and Eisenmenger's syndrome in a mature cat [abstract].** *Aust Vet J* 1990; 67: 380.
- Lee SG, Moon HS, Choi R, et al. **Ventricular septal defect in an Abyssinian cat.** *Korean J Vet Res* 2008; 48: 99–103.
- Chuzel T, Bublot I, Couturier L, et al. **Persistent truncus arteriosus in a cat.** *J Vet Cardiol* 2007; 9: 43–46.
- Berman E and Barst RJ. **Eisenmenger's syndrome: current management.** *Prog Cardiovasc Dis* 2002; 48: 129–138.
- Johnson L. **Diagnosis of pulmonary hypertension.** *Clin Tech Small Anim Pract* 1999; 14: 231–236.
- Johnson L, Boon J and Orton EC. **Clinical characteristics of 53 dogs with Doppler-derived evidence of pulmonary hypertension: 1992–1996.** *J Vet Intern Med* 1999; 13: 440–447.
- Zhang X, Tack J, Janssens J, et al. **Effect of sildenafil, a phosphodiesterase-5 inhibitor, on oesophageal peristalsis and lower oesophageal sphincter function in cats.** *Neurogastroenterol Motil* 2001; 13: 325–331.
- Doherty PC, Bivalacqua TJ, Champion HC, et al. **Direct effects of selective type 5 phosphodiesterase inhibitors alone or with other vasodilators on the erectile response in cats.** *J Urol* 2001; 165: 1004–1009.
- Toaldo MB, Guglielmini C, Diana A, et al. **Reversible pulmonary hypertension in a cat.** *J Small Anim Pract* 2011; 52: 271–277.
- Dirven M, Szatmári, van den Ingh T, et al. **Reversible pulmonary hypertension associated with lungworm infection in a young cat.** *J Vet Cardiol* 2012; 14: 465–474.
- Lim ZS, Salmon AP, Vettukattil JJ, et al. **Sildenafil therapy for pulmonary arterial hypertension associated with atrial septal defects.** *Int J Cardiol* 2007; 118: 178–182.
- Chau EMC, Fan KYY and Chow WH. **Effects of chronic sildenafil in patients with Eisenmenger's syndrome versus idiopathic pulmonary arterial hypertension.** *Int J Cardiol* 2007; 120: 301–305.
- Dimopoulos K, Inuzuka R, Goletto S, et al. **Improved survival among patients with Eisenmenger's syndrome receiving advanced therapy for pulmonary arterial hypertension.** *Circulation* 2010; 121: 20–25.
- Tay EL, Papaphylactou M, Diller GP, et al. **Quality of life and functional capacity can be improved in patients with Eisenmenger's syndrome with oral sildenafil therapy.** *Int J Cardiol* 2011; 149: 372–376.
- Garg N, Tipathy N and Sinha N. **Comparative efficacy of sildenafil in Eisenmenger's syndrome secondary to atrial septal defect versus ventricular septal defect: a cardiac catheterization follow-up study.** *Cardiol Young* 2011; 21: 631–638.
- Bach JF, Rozanski EA, MacGregor J, et al. **Retrospective evaluation of sildenafil citrate as a therapy for pulmonary hypertension in dogs.** *J Vet Intern Med* 2006; 20: 1132–1135.
- Kellum HB and Stepien RL. **Sildenafil citrate therapy in 22 dogs with pulmonary hypertension.** *J Vet Intern Med* 2007; 21: 1258–1264.
- Brown AJ, Davison E and Sleeper MM. **Clinical efficacy of sildenafil in treatment of pulmonary arterial hypertension in dogs.** *J Vet Intern Med* 2010; 24: 850–854.
- Côté E and Ettinger SJ. **Long-term clinical management of right-to-left ("reversed") patent ductus arteriosus in 3 dogs.** *J Vet Intern Med* 2001; 15: 39–42.
- Daliento L, Somerville J, Presbitero P, et al. **Eisenmenger's syndrome. Factors relating to deterioration and death.** *Eur Heart J* 1998; 12: 1845–1955.
- Diller GP, Dimopoulos K, Broberg CS, et al. **Presentation, survival prospects, and predictors of death in Eisenmenger's syndrome: a combined retrospective and case-control study.** *Eur Heart J* 2006; 27: 1737–1742.
- Cantor WJ, Harrison DA, Moussadji, et al. **Determinants of survival and length of survival in adults with Eisenmenger's syndrome.** *Am J Cardiol* 1999; 84: 677–681.