



Glenoidectomy for treatment of a comminuted scapular fracture in a cat

Authors: Preston, Timothy J, and Hosgood, Giselle

Source: Journal of Feline Medicine and Surgery Open Reports, 1(2)

Published By: SAGE Publishing

URL: <https://doi.org/10.1177/2055116915613816>

BioOne Complete (complete.BioOne.org) is a full-text database of 200 subscribed and open-access titles in the biological, ecological, and environmental sciences published by nonprofit societies, associations, museums, institutions, and presses.

Your use of this PDF, the BioOne Complete website, and all posted and associated content indicates your acceptance of BioOne's Terms of Use, available at www.bioone.org/terms-of-use.

Usage of BioOne Complete content is strictly limited to personal, educational, and non - commercial use. Commercial inquiries or rights and permissions requests should be directed to the individual publisher as copyright holder.

BioOne sees sustainable scholarly publishing as an inherently collaborative enterprise connecting authors, nonprofit publishers, academic institutions, research libraries, and research funders in the common goal of maximizing access to critical research.



Glenoidectomy for treatment of a comminuted scapular fracture in a cat

Journal of Feline Medicine and Surgery
 Open Reports
 1–6

© The Author(s) 2015
 Reprints and permissions:
sagepub.co.uk/journalsPermissions.nav
 DOI: 10.1177/2055116915613816
jfmsopenreports.com



Timothy J Preston and Giselle Hosgood

Abstract

Case summary This case report describes the surgical technique used and clinical outcome of a 15-year-old neutered female cat that had a comminuted fracture of the right glenoid and scapular neck secondary to a gunshot injury that was treated with glenoidectomy.

Relevance and novel information Good clinical outcomes are possible with removal of the glenoid for treatment of comminuted fractures of the scapulohumeral joint. Glenoidectomy is a viable alternative to amputation in cats with normal neurovascular supply to the affected limb. Persistent functional, pain-free lameness, muscle hypertrophy and changes in shoulder range of motion are to be expected.

Accepted: 18 September 2015

Introduction

Partial and complete scapulectomy are salvage procedures described in cats and dogs with variable clinical outcomes.^{1–4} The reported indications for complete or partial excision of the scapula are fracture of the glenoid,¹ chronic medial glenohumeral luxation⁵ or, more frequently, scapular neoplasia.^{2–4} This report describes a 15-year-old neutered female domestic shorthair cat with a comminuted fracture of the right glenoid and scapular neck secondary to a gunshot injury, which was treated with glenoidectomy with preservation of the humeral head. Lameness in the right forelimb was 3/5, 4/5 and 1/5 preoperatively, 24 h postoperatively and 6 months postoperatively, respectively.

Case description

A 15-year-old neutered female domestic shorthair cat was presented to the primary care veterinarian for acute onset of right forelimb lameness. The cat had been missing for the previous 24 h and was normally an indoor/outdoor cat with free access to the owner's residence. Prior to this presentation, the cat was reportedly healthy.

On presentation to the primary care veterinarian, the cat had a toe-touching to non-weight bearing right forelimb lameness and a scab of dried blood located cranial to the point of the right shoulder. Manipulation of the right shoulder elicited pain and crepitus. Neurological

function of the right forelimb was considered normal. The scabbed region over the cranial aspect of the point of the right shoulder was clipped, and a small puncture wound approximately 5 mm in diameter was noted. Complete blood count revealed a normocytic, normochromic, mildly regenerative anaemia (haematocrit 11.5, reference interval [RI] 30–45%). The leukogram was normal. Serum biochemistry abnormalities included hypoproteinaemia (51 g/l; RI 57–89 g/l), hypoalbuminaemia (17 g/l; RI 23–39 g/l), decreased alkaline phosphatase enzyme activity (13 U/l; RI 14–111 U/l) and decreased amylase enzyme activity (440 U/l; RI 500–1500 U/l). Blood electrolyte concentrations were within the normal RIs. Given the forelimb lameness, puncture wound and marked anaemia, hypoproteinaemia and fracture of the forelimb, anaemia secondary to haemorrhage was considered most likely.

School of Veterinary and Life Sciences, College of Veterinary Medicine, Murdoch University, Murdoch, Western Australia, Australia

Corresponding author:

Giselle Hosgood BVSc (Hons), MS, PhD, School of Veterinary and Life Sciences, College of Veterinary Medicine, Murdoch University, 90 South Street, Murdoch, Western Australia, 6150, Australia
 Email: g.hosgood@murdoch.edu.au



Creative Commons CC-BY-NC: This article is distributed under the terms of the Creative Commons Attribution-NonCommercial 3.0 License (<http://www.creativecommons.org/licenses/by-nc/3.0/>) which permits non-commercial use, reproduction and distribution of the work without further permission provided the original work is attributed as specified on the SAGE and Open Access page (<https://us.sagepub.com/en-us/nam/open-access-at-sage>).

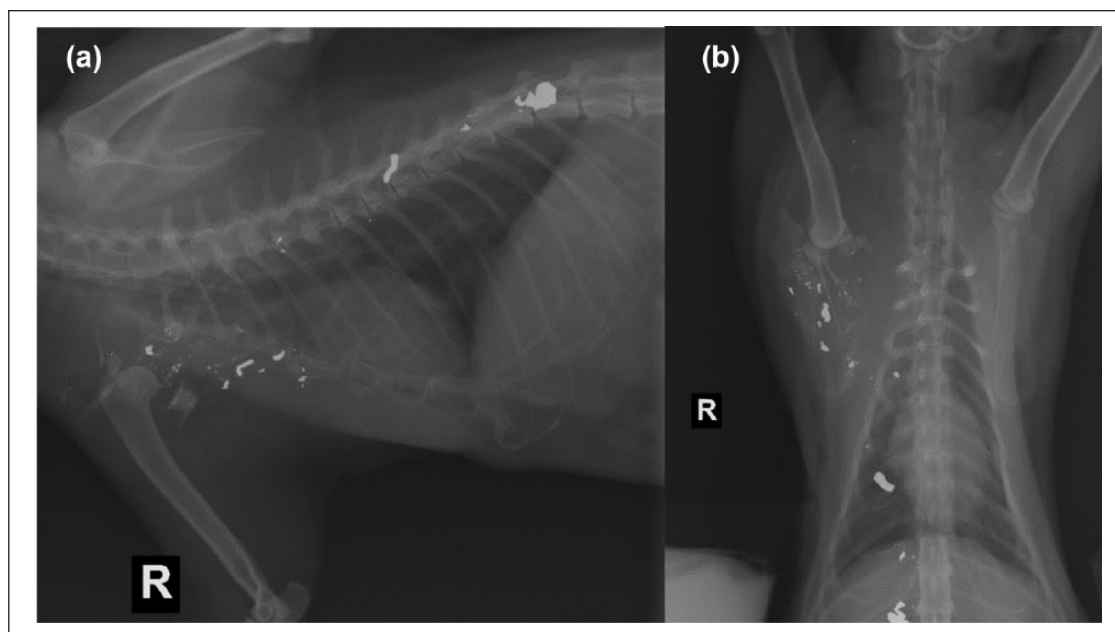


Figure 1 (a) Right mediolateral and (b) dorsoventral referral radiographic views of the scapula and thorax. Note the comminuted fracture of the right distal scapula, medial displacement of the humerus, axillary subcutaneous emphysema with associated increase in soft tissue opacification and bullet fragmentation extending from the shoulder to just lateral to the T12–T13 intervertebral space

The cat was sedated with butorphanol (0.2 mg/kg) and midazolam (0.2 mg/kg) intramuscularly prior to establishing intravenous (IV) access. The cat was intubated and general anaesthesia was maintained with isoflurane in oxygen while radiographs were taken.

Referral radiographs revealed a severely comminuted fracture of the scapular neck and glenoid with lateral displacement (Figure 1). No fractures of the humeral head were identified. There were fragmented metallic opacities lodged within the fractured segments of the right scapula, which extended medially and dorsally in a linear trajectory. The largest, most irregular metallic fragment was observed ipsilateral and adjacent to the twelfth and thirteenth thoracic (T12 and T13, respectively) vertebrae. There was marked increase in soft tissue opacity within the right axilla and subscapular space with mild subcutaneous emphysema cranial to the right shoulder. The intrathoracic structures were normal. Radiographic changes observed supported the source of the lameness and anaemia to a single bullet that had penetrated the skin ventral to the right mandibular ramus, tracked through the subcutaneous tissue, fractured the scapular neck and glenoid, and subsequently fragmented within the axilla without penetrating the thorax.

General physical examination performed at the time of admission was similar to that reported by the primary care veterinarian earlier that day. The cat was

ambulatory with toe-touching to non-weight-bearing lameness in the right forelimb (see video 1 in Supplementary material). Neurological examination of the right thoracic limb was normal. Withdrawal reflexes, proprioception and pain sensation was present in all other limbs. Cranial nerve examination was also normal.

The packed cell volume (PCV)/total protein (TP) was 18 l/l and 66 g/l, respectively, which was improved compared with the results 8 h previously. Given the anaemia and inadequate analgesia, further in-hospital supportive care with packed red blood cell transfusion if the PCV continued to decline and analgesia was planned. IV crystalloid fluids and methadone (0.3 mg/kg IM; Troy Laboratories) were given overnight, and a transdermal fentanyl patch (12 µg/h; Janssen-Cilag) was applied. The PCV/TP were monitored and remained stable, so transfusion was not performed. The cat was discharged for the weekend the next day with re-presentation scheduled for the start of the following week.

Computed tomography (CT) with and without IV contrast (450 mg/kg iohexol 300; GE Healthcare) under general anaesthesia was performed 3 days after initial referral to better characterise the scapular fracture, axillary vasculature and thorax. The preanaesthetic PCV/TP was improved at 26 l/l and 78 g/l, respectively. The CT revealed multiple metallic attenuating fragments and gas-attenuating pockets consistent with a bullet track within the right subcutaneous tissues, muscles and

scapula on the right forelimb and thoracic wall (Figure 2). There was a severely comminuted fracture of the right distal scapula (Figure 3), with fragmentation of the glenoid and adjacent increased soft tissue attenuation without iodohexol extravastion, suggesting fluid accumulation consistent with prior haemorrhage. The humeral head was luxated and displaced proximomedially relative to

the glenoid. There were multiple metal fragments lodged within the bone and adjacent tissues along the articular processes from T11 to T13, with the largest fragment lodged at the right of the T13 spinous process and articular facet (Figure 2). The thoracic cavity was otherwise within normal limits. There was no evidence of thrombosis or vascular compromise to the axillary vessels in the right brachial plexus after IV contrast administration.

Owing to the degree of comminution, reconstruction of the glenoid, scapular neck and the glenohumeral joint was considered unattainable. Amputation of the limb was considered; however, this was deemed to be an extreme option given the neurological function of the limb was normal and the humeral head and the scapula proximal to the neck were intact. A partial distal scapulectomy (glenoidectomy) was recommended.

The following day the cat underwent glenoidectomy. The cat was premedicated with methadone (0.3 mg/kg IM; Troy Laboratories). General anaesthesia was induced with diazepam (0.25 mg/kg; Ceva Pharmaceuticals) and ketamine (5 mg/kg; Troy Laboratories). Anaesthesia was maintained using isoflurane to effect. Hypotension (mean arterial pressure <60 mmHg) determined by oscillometric non-invasive blood pressure was observed during patient preparation. Two initial boluses of Hartmann's solution (10 mg/kg) failed to improve hypotension, so fentanyl (3–10 µg/kg/h; AstraZeneca) and ketamine (10 µg/kg/min) constant rate infusion (CRI) were initiated and maintained throughout surgery in order to reduce the end-tidal isoflurane concentration to 1%. Despite this, hypotension only resolved (mean arterial pressure >60 mmHg) with administration of a dopamine CRI at 5–10 µg/kg/min. Cefazolin (22 mg/kg IV; Sandoz) was administered at induction and every 90 mins throughout surgery. The cat was positioned in left lateral recumbency and a 15 cm lateral incision was

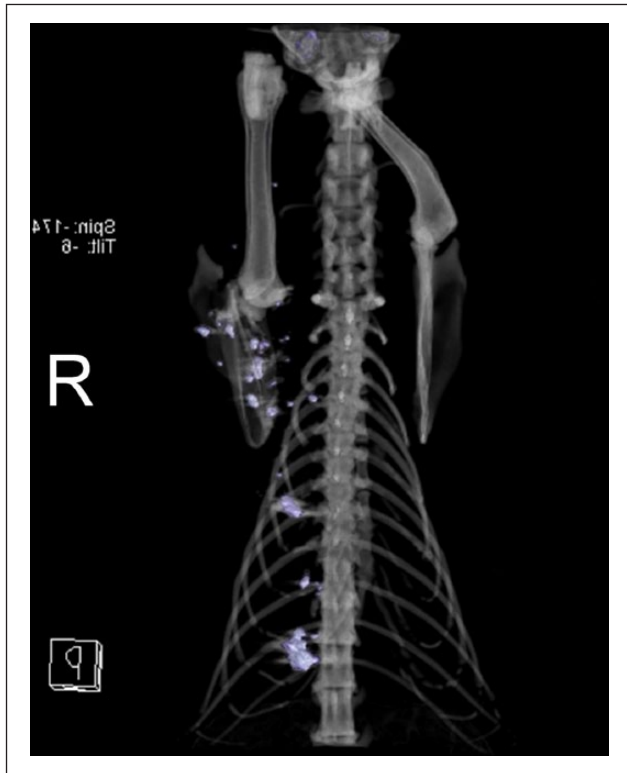


Figure 2 Preoperative dorsal three-dimensional reconstruction of the cranial half of the cat. Light purple-coloured irregularities to the right represent bullet fragments

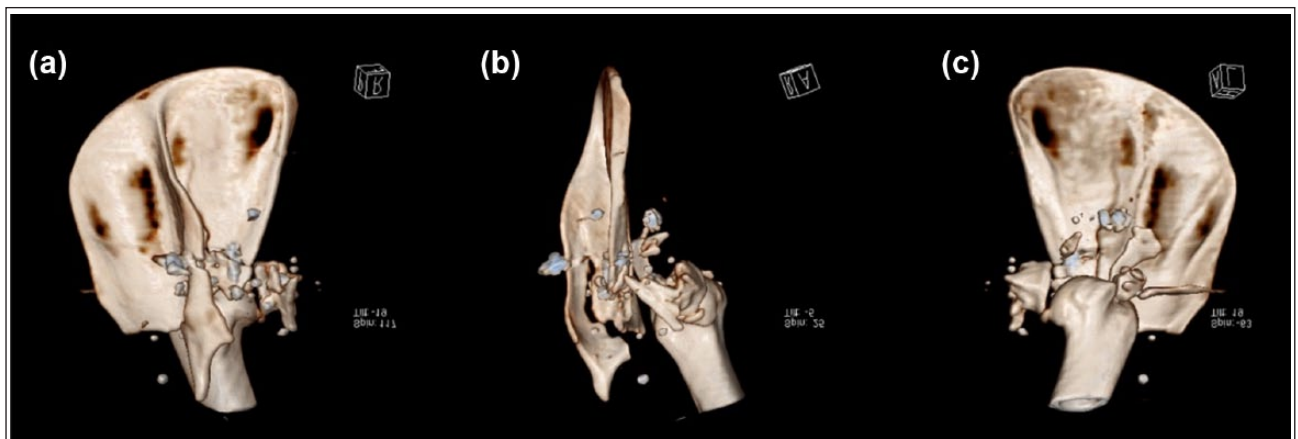


Figure 3 Three-dimensional reconstruction of the right glenohumeral joint. (a) Lateral, (b) caudocranial and (c) medial views. Note the comminuted fracture of the distal right scapula, medial displacement of the humerus and bullet fragmentation. The humeral head is intact. There is fracture of the scapula spine proximal to the suprahamate process

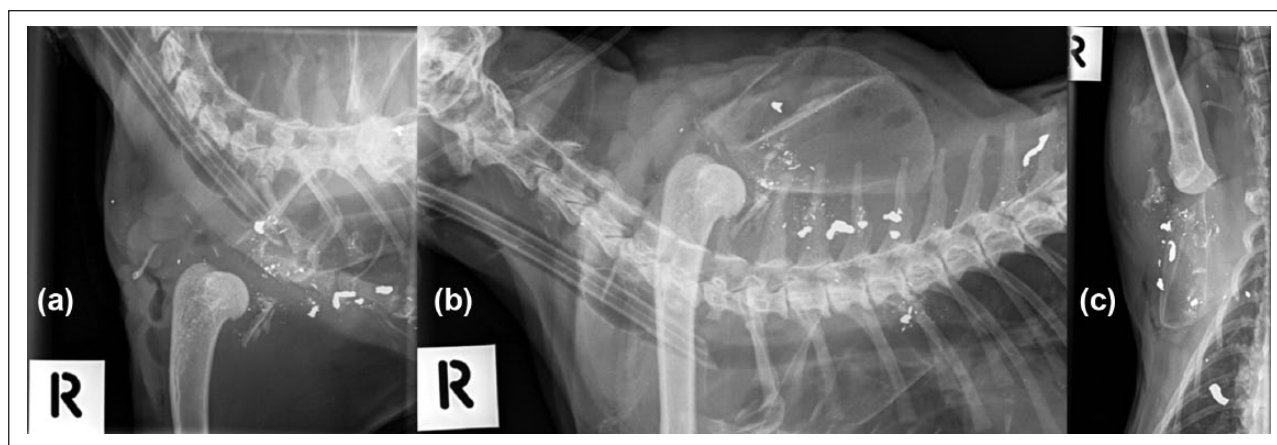


Figure 4 Postoperative (a,b) right mediolateral and (c) dorsoventral radiographs. Note relative dorsal displacement of the scapula and humerus in (b) during simulated weightbearing

made over the right scapula spine and then distal over the glenohumeral joint over the proximolateral humerus. The suprascapular and axillary nerve could not be visualised, owing to extensive soft tissue damage around the scapular neck, acromion and glenoid. Gelpi retractors were placed into the supraspinatus and infraspinatus fossae to retract these muscles from the scapular spine and expose the scapular neck. The hamate and suprahamate processes of the acromion (origins of the deltoid muscles) were attached to the scapular spine with a fine fibrous adhesion, but had otherwise fractured as a single piece that had not displaced. The humeral head was displaced medially and ventrally, and was manipulated back into a normal position with bone-holding forceps.

A longitudinal fracture of the infraspinatus fossa was observed to extend from the scapular neck to the level of the suprahamate process. Extra-articular fragments of the glenoid and scapular neck were removed manually. The supraglenoid tubercle with the origin of the biceps brachii and coracobrachialis was fragmented and displaced medial to the joint, so biceps and coracobrachialis tenotomy was performed and the supraglenoid tubercle excised. The joint capsule was incised close to the glenoid rim, which facilitated intra-articular removal of the fragmented glenoid. The origins of the medial and lateral glenohumeral ligament were resected at the glenoid to help preserve as much joint capsule as possible. A transverse osteotomy was performed with a sagittal saw across the remaining scapula approximately 1 cm proximal to the suprahamate process. The subscapularis, teres minor, supra and infraspinatus tendon origins remained intact. The remaining joint capsule was sutured over the humeral head with 2-0 polydioxanone (PDS; Ethicon).

A 2 cm × 4 cm muscle flap was created from the caudal aspect of the supraspinatus muscle by incising it parallel to its fibres, and then rotating the pedicle caudally between the osteotomised surface of the scapula and the

joint capsule covering the humeral head. The muscle flap was sutured in place to the scapular head of the deltoid, the lateral head of the triceps and the joint capsule with locking loop sutures of 2-0 PDS. The infraspinatus fascia was apposed to the supraspinatus fascia with 2-0 PDS. The trapezius and omotransversarius muscles were then apposed to the scapular head of the deltoid with 3-0 PDS. The subcutaneous tissue and skin were closed. There was a smooth range of motion palpable in the right shoulder, without abnormal abduction, rotation or crepitus. A 2 cm incision was then made along the epaxial longissimus thoracic muscles over right side of T13. Blunt dissection was made through the muscle to retrieve a metallic fragment of bullet; this was submitted for culture and sensitivity, and was negative. The wound region was lavaged prior to closure of the muscle fascia, subcutaneous tissue and skin.

Postoperative radiographs confirmed the removal of the majority of the fragmented glenoid and scapula (Figure 4). A single sliver of bone was observed caudolateral to the humeral head on postoperative radiographs; however, this was appreciated to be extra-articular and embedded in soft tissues and did not pose any obstruction to shoulder range of motion. Metallic fragments of the bullet remained in situ. Relative dorsal translation of the humeral head was appreciated compared to the contralateral limb.

The cat recovered from anaesthesia with a CRI of fentanyl (1–3 µg/kg/h) without complication and was eating and drinking several hours after surgery. Anticipating a 12 h onset of action, a transdermal buprenorphine patch (10 µg/h; Mundipharma) was applied. Fentanyl CRI was continued until the transdermal buprenorphine patch became active. Non-steroidal anti-inflammatories were considered but, owing to the cat's anaemia and hypotension under general anaesthesia, not administered. Twelve hours after surgery there was a persistent weight-bearing

right forelimb lameness at a walk (see video 2 in Supplementary material); however, the cat would hold the right forelimb off the ground when not ambulating. The day after surgery the cat was discharged with a transdermal buprenorphine patch providing a week of analgesia.

Three weeks postoperatively, the cat was re-presented for examination. The skin incision had healed and the skin sutures were removed. A mild persistent weight-bearing right forelimb lameness was appreciated at a walk (see video 3 in Supplementary material). The cat was able to jump up and down from a height of several steps. Subjectively, the right forelimb looked shorter than the contralateral forelimb, and the scapula was more dorsally displaced. The range of motion was considered normal and no pain or crepitus could be elicited. The triceps, biceps and deltoid muscles of the right forelimb appeared moderately hypertrophied compared with the contralateral limb. At this time, the supra- and infraspinatus muscles were not atrophied. Instructions were provided to the owner to continue to restrict the cat to small indoor areas and to prevent it from running and jumping. At the 6 month recheck, there was marked atrophy of the supra- and infraspinatus muscles in contrast to the 3 week recheck, suggesting that suprascapular nerve function had been compromised. The triceps, biceps and deltoid muscles remained moderately hypertrophied compared with the contralateral limb. As before, no pain could be elicited with movement of the pseudoarthrosis, and range of motion was subjectively comparable to the contralateral shoulder. The cat's mechanical lameness at 6 months was observed as a very slightly shortened stance phase when walking (see video 4 in Supplementary material). The client's impression was that the cat's right forelimb had returned to normal function and the cat was capable of performing all the activities it had previously carried out without overt pain; however, it had become reluctant to jump down from heights. Overall, the case was considered to have an excellent functional outcome.

Discussion

This report describes the surgical technique and clinical outcome of a cat that had a complete glenoidectomy performed to treat a comminuted fracture secondary to a gunshot injury of the distal scapula. This case is the first known report describing the successful use of a complete glenoidectomy with preservation of the humeral head for management of a comminuted distal scapular fracture. Several feline and orthopaedic textbooks describe glenoidectomy with and without humeral head excision as a salvage procedure for diseases of the shoulder joint in cats;^{6–10} however, all of these sources reference case reports in dogs.

There are reports in toy breed dogs of glenohumeral excisional arthroplasty being performed for treatment of chronic shoulder luxation and comminuted glenoid

fractures.^{5,11,12} In all of these reports where glenohumeral excisional arthroplasty was performed, the humeral head and the glenoid were both removed. In the cat of this case report, total glenoidectomy was performed with preservation the humeral head. The literature suggests that expected limb use after partial scapulectomy in cats and dogs should be good to excellent when there is preservation of neurological function, preservation of the glenoid and the glenohumeral joint, and reconstruction of the joint's soft tissues in lightweight animals.^{1,3,12,13} Despite these suggested restrictions to ensure a favourable outcome, good-to-excellent clinical outcomes have been reported in cats and mid-to-large breed dogs undergoing partial and total scapulectomy,^{1–4,12,13} and in dogs undergoing glenohumeral excisional arthroplasty.^{5,11} These reports would support that animal size should not preclude glenoidectomy or scapulectomy as limb salvage procedures. Furthermore, retention of the glenoid or glenohumeral collateral ligaments may not be essential to afford a good clinical outcome.

Passive glenohumeral joint stability is primarily provided by the joint capsule and collateral ligaments in dogs;^{14–17} however, the relative contribution of these to glenohumeral stability in the cat has not been demonstrated. The transarticular tendons (specifically the supraspinatus, infraspinatus, biceps brachii and subscapularis, and, less so, the coracobrachialis, teres minor and teres major) are active stabilisers of the glenohumeral joint and require energy to contract and relax to maintain joint conformation.^{16,17} As described in this case, we were able to reconstruct or maintain some of the supporting soft tissues of the glenohumeral joint, specifically the joint capsule, supraspinatus, infraspinatus, teres minor and subscapularis tendons, which provided some medial-lateral stability to the scapulohumeral pseudoarthrosis. Furthermore, the moderate hypertrophy of the triceps, biceps and deltoids of the affected limb noted on examination 3 weeks postoperatively suggests that stability to the pseudoarthrosis may be actively provided by these muscles. Examination of the cat prior to discharge and again at the 3 week recheck revealed a palpable increase in proximodistal and flexion/extension shoulder range of motion compared with the contralateral shoulder. No crepitus or pain was appreciated in the right shoulder at the 3 week recheck, and limb use was considered to be good, despite a persistent mechanical lameness, which is likely related to the effective shortening of the limb and alteration in the shoulder range of motion. We suspect that if part of the scapula is to be retained after glenoidectomy, then closing the joint capsule,^{14–17} reconstructing or maintaining the supraspinatus, infraspinatus and subscapularis tendons, and interposing soft tissue between cut bone ends may be important to affording a good functional outcome in the cat.¹² While the use of a muscle sling in excisional arthroplasties remains controversial,¹²

in this case it was deemed necessary owing to the expected pistoning during weight bearing between the juxtaposed cut edge of the distal scapula and the humeral head. The technique described here may not be applicable to cases with concurrent neurological dysfunction or fracture of the humeral head.

Conclusions

A good clinical outcome is possible with removal of the glenoid for treatment of comminuted fractures of the scapulo-humeral joint. The surgical technique of glenoidectomy is a viable alternative to amputation in cats with normal neurovascular supply to the affected limb. A persistent functional, pain-free lameness, muscle hypertrophy and abnormalities in shoulder range of motion are to be expected.

Funding The authors received no financial support for the research, authorship, and/or publication of this article.

Conflict of interest The authors declared no potential conflicts of interest with respect to the research, authorship, and/or publication of this article.

Supplementary material

The following files are available:

Video 1: Preoperative video of the cat. Note the moderate weightbearing (3/5) lameness of the right forelimb
 Video 2: Cat 24 h postsurgery. Note the marked weightbearing (4/5) lameness of the right forelimb. The incision is covered by a self-adhesive dressing
 Video 3: Cat 3 weeks postsurgery. Sutures have been removed from the incision. Note the mild weightbearing (2/5) lameness of the right forelimb and relative hypertrophy of the triceps and brachial muscles
 Video 4: Cat 6 months postsurgery. Note the excellent right forelimb use and very mild (1/5) lameness

References

- 1 Plesman RL, French S, Nykamp S, et al. **Partial scapulectomy for treatment of an articular fracture of the scapula in a cat.** *Vet Comp Orthop Traumatol* 2011; 24: 468–473.
- 2 Norton C, Drenen C and Emms S. **Subtotal scapulectomy as the treatment for scapular tumour in the dog: a report of six cases.** *Aust Vet J* 2006; 84: 364–366.
- 3 Montinaro V, Boston SE, Buracco P, et al. **Clinical outcome of 42 dogs with scapular tumors treated by scapulectomy: A Veterinary Society of Surgical Oncology (VSSO) retrospective study (1995–2010).** *Vet Surg* 2013; 42: 943–950.
- 4 Clarke BS and Findji L. **Total scapulectomy for the treatment of chondrosarcoma in a cat.** *J Am Vet Med Assoc* 2012; 241: 364–367.
- 5 Hodik V, Golovanov A and Ranen E. **Excision arthroplasty for treatment of a chronic traumatic medial scapulo-humeral joint luxation in a dog.** *Isr J Vet Med* 2013; 68: 65–68.
- 6 Scott HW and McLaughlin RM. **Fractures and disorders of the forelimb, part 1: scapula and shoulder joint.** In: Scott HW and McLaughlin RM (eds). *Feline orthopedics*. London: Manson Publishing/The Veterinary Press, 2007, p 113.
- 7 Voss K and Langley-Hobbs SJ. **Shoulder joint.** In: Montavon PM, Voss K and Langley-Hobbs SJ (eds). *Feline orthopedic surgery and musculoskeletal disease*. Edinburgh, New York: Mosby, 2009, pp 337–342.
- 8 Piermattei DL, Flo GL, Brinker WO, et al. Brinker, Piermattei, and Flo's handbook of small animal orthopedics and fracture repair. St Louis, MO: Saunders Elsevier, 2006, pp 262–296.
- 9 Rochat M. **The shoulder.** In: Tobias KM and Johnston SA (eds). *Veterinary surgery: small animal*. St Louis, MO: Elsevier, 2012, p 696.
- 10 Newton CD and Nunamaker DM. *Textbook of small animal orthopaedics*. Philadelphia, PA: Lippincott, 1985.
- 11 Franczuszki D and Parkes LJ. **Glenoid excision as a treatment in chronic shoulder disabilities: surgical technique and clinical results.** *J Am Anim Hosp Assoc USA* 1988; 24: 637–643.
- 12 Bruecker KA and Piermattei DL. **Excision arthroplasty of the canine scapulo-humeral joint: report of three cases.** *Vet Comp Orthop Traumatol* 1988; 3: 134–140.
- 13 Trout NJ, Pavletic MM and Kraus KH. **Partial scapulectomy for management of sarcomas in three dogs and two cats.** *J Am Vet Med Assoc* 1995; 207: 585–587.
- 14 Kirpensteijn J, Straw RC, Pardo AD, et al. **Partial and total scapulectomy in the dog.** *J Am Anim Hosp Assoc* 1994; 30: 313–319.
- 15 Vasseur PB, Moore D and Brown SA. **Stability of the canine shoulder joint: an in vitro analysis.** *Am J Vet Res* 1982; 43: 352–355.
- 16 Bardet JF. **Diagnosis of shoulder instability in dogs and cats: a retrospective study.** *J Am Anim Hosp Assoc* 1998; 34: 42–54.
- 17 Sidaway BK, McLaughlin RM, Elder SH, et al. **Role of the tendons of the biceps brachii and infraspinatus muscles and the medial glenohumeral ligament in the maintenance of passive shoulder joint stability in dogs.** *Am J Vet Res* 2004; 65: 1216–1222.