



Hyperinsulinaemic, hypoglycaemic syndrome due to acquired nesidioblastosis in a cat

Authors: Hambrook, Lydia E, Ciavarella, Amanda A, Nimmo, Judith S, and Wayne, Julie

Source: Journal of Feline Medicine and Surgery Open Reports, 2(2)

Published By: SAGE Publishing

URL: <https://doi.org/10.1177/2055116916657846>

BioOne Complete (complete.BioOne.org) is a full-text database of 200 subscribed and open-access titles in the biological, ecological, and environmental sciences published by nonprofit societies, associations, museums, institutions, and presses.

Your use of this PDF, the BioOne Complete website, and all posted and associated content indicates your acceptance of BioOne's Terms of Use, available at www.bioone.org/terms-of-use.

Usage of BioOne Complete content is strictly limited to personal, educational, and non - commercial use. Commercial inquiries or rights and permissions requests should be directed to the individual publisher as copyright holder.

BioOne sees sustainable scholarly publishing as an inherently collaborative enterprise connecting authors, nonprofit publishers, academic institutions, research libraries, and research funders in the common goal of maximizing access to critical research.



Hyperinsulinaemic, hypoglycaemic syndrome due to acquired nesidioblastosis in a cat

Lydia E Hambrook¹, Amanda A Ciavarella¹, Judith S Nimmo² and Julie Wayne²

Journal of Feline Medicine and Surgery
Open Reports
1–5

© The Author(s) 2016
Reprints and permissions:
sagepub.co.uk/journalsPermissions.nav
DOI: 10.1177/2055116916657846
jfmsoopenreports.com

This paper was handled and processed
by the European Editorial Office (ISFM)
for publication in JFMS Open Reports



Abstract

Case summary A 6-year-old, neutered female British Shorthair cat presented with acute-onset weakness and mental dullness. Initially the cat was mildly hyperglycaemic (9.9 mmol/l; reference interval [RI] 3.3–6.7 mmol/l). Over the following 12 h the cat developed central blindness, tremors, intermittent seizures and opisthotonus. Repeat blood sampling revealed a marked hypoglycaemia (0.8 mmol/l). Insulin level (performed on a serum sample collected while the cat was hypoglycaemic) was inappropriately elevated (1575 mIU/l; RI 10–80 mIU/l). An abdominal ultrasound was unremarkable. An exploratory laparotomy revealed a firm and erythematous left limb of the pancreas. Following surgical resection of the left limb of the pancreas, the cat returned to a euglycaemic state after a brief rebound hyperglycaemia. Histopathology revealed pancreatic fibrosis with marked multifocal micronodular hyperplasia of exocrine and endocrine cells. Synaptophysin immunohistochemistry confirmed nodular β -cell hyperplasia.

Relevance and novel information Nesidioblastosis describes a syndrome of acquired hyperinsulinaemia and associated hypoglycaemia secondary to focal or diffuse (non-neoplastic) β -cell hyperplasia within the pancreas. Acquired nesidioblastosis has been reported in humans, where β -cell dysregulation is thought to occur in response to pancreatic injury. This is the first reported case of clinically significant hypoglycaemia due to acquired nesidioblastosis in an adult domestic cat. While this condition is rare, nesidioblastosis is being increasingly recognised in humans and it is an important differential diagnosis to consider when investigating hypoglycaemia as it cannot be distinguished from insulinoma without histopathological evaluation. While recurrence has been occasionally reported in humans, the prognosis is considered good.

Accepted: 6 June 2016

Case description

A 6-year-old, neutered female British Shorthair cat presented with acute-onset weakness and mental dullness. The cat had previously been regarded as healthy apart from a transient myopathy (suspected toxoplasmosis) which resolved with clindamycin and supportive care 3 months earlier. A serum biochemistry panel and complete blood count were unremarkable apart from mild hyperglycaemia (9.9 mmol/l; 3.3–6.7 mmol/l) which was thought to reflect stress hyperglycaemia (catecholamine antagonism of insulin). Creatine kinase (CK) was within the reference interval (59 U/l; reference interval [RI] 0–314). Over the following 12 h the cat developed central blindness, tremors, intermittent seizures and opisthotonus. Repeat blood sampling (while the cat was

symptomatic) revealed a marked hypoglycaemia (0.8 mmol/l). A concurrent insulin level (performed on a serum sample collected while the cat was hypoglycaemic) was inappropriately elevated (1575 mIU/l; RI 10–80

¹Small Animal Medicine Department, Advanced Vetcare, Melbourne, VIC, Australia

²Australian Specialised Animal Pathology Laboratory, Melbourne, VIC, Australia

Corresponding author:

Lydia Evelyn Hambrook BVSc (Hons), FANZCVS (Small Animal Medicine), Medicine Department, Advanced Vetcare, Level 1, 26 Robertson St, Kensington, 3031, Victoria, Australia
Email: smithbrook711@gmail.com



Creative Commons Non Commercial CC-BY-NC: This article is distributed under the terms of the Creative Commons Attribution-NonCommercial 3.0 License (<http://www.creativecommons.org/licenses/by-nc/3.0/>) which permits non-commercial use, reproduction and distribution of the work without further permission provided the original work is attributed as specified on the SAGE and Open Access pages (<https://us.sagepub.com/en-us/nam/open-access-at-sage>).

mIU/l). Pre- and post-prandial bile acids and a resting cortisol level were within the reference interval. An intravenous bolus of 5% glucose (0.5 g/kg diluted 1:3 in 0.9% sodium chloride solution) resulted in rapid resolution of all clinical signs and mild transient hyperglycaemia (12.5 mmol/l). Despite frequent feeding, the hypoglycaemia (2.0 mmol/l) rapidly recurred. An intravenous 2.5% glucose continuous-rate infusion (sodium chloride 0.45% w/v and glucose 2.5% w/v solution for injection [BP; Baxter Healthcare]) was commenced.

An abdominal ultrasound was unremarkable, although three cranial mesenteric lymph nodes were noted to be prominent (3 mm in width). Given the concurrent hypoglycaemia, hyperinsulinaemia and resolution of clinical signs following glucose supplementation, an insulinoma was suspected. An exploratory laparotomy revealed a firm and erythematous left limb of the pancreas. The body and right limb of the pancreas appeared grossly normal. Following surgical resection of the left limb of the pancreas, the cat returned to a euglycaemic state after a brief rebound hyperglycaemia. Histopathology revealed pancreatic fibrosis with marked multifocal micronodular hyperplasia of exocrine and endocrine cells, mild lymphoplasmacytic inflammation and ductular ectasia (Figures 1 and 2). Synaptophysin immunohistochemistry confirmed micronodular β -cell hyperplasia (Figure 3). Mild granulomatous lymphadenitis and hydropic change within hepatocytes was also noted in biopsies acquired from the cranial mesenteric lymph node and liver, respectively. The histopathological findings were consistent with a diagnosis of acquired non-neoplastic hyperinsulinaemic hypoglycaemic syndrome (also known as nesidioblastosis) and underlying, chronic pancreatic inflammation with possible partial ductular obstruction.

The cat recovered uneventfully without any further intervention. Over the following 12 months, the cat remained clinically well and euglycaemic. A random insulin level performed 6 months after partial pancreatectomy was normal (20 mU/l). Thirteen months after diagnosis, the cat represented with acute onset lethargy and anorexia. A biochemistry panel revealed mild hyperglycaemia (10.8 mmol/l) with a moderate myopathy (CK 6942 U/l) and mild cholestasis (total bilirubin 22; RI 0–15). The cat died acutely in hospital before further diagnostic tests could be undertaken. No post mortem was performed. A recrudescence of toxoplasmosis was suspected. While an ante-mortem serum toxoplasma IgG titre was subsequently found to be positive (1:64), the IgM titre was negative (<1:16).

Discussion

Acquired non-neoplastic hyperinsulinaemic hypoglycaemia syndrome has not previously been described in the veterinary literature, although it is a well-known

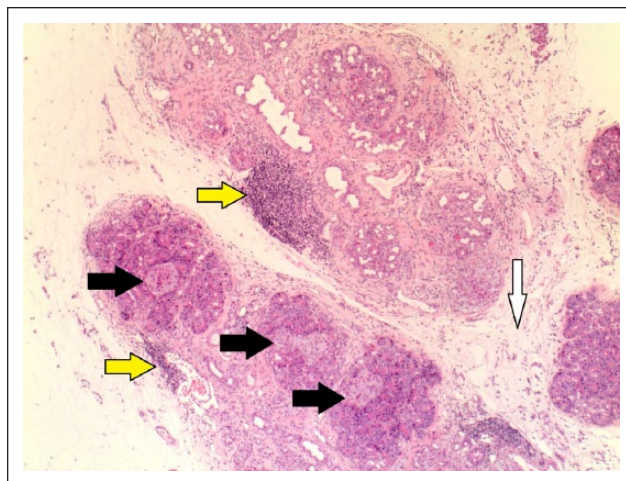


Figure 1 Low power ($\times 40$ magnification) of the affected pancreas. There are multiple regions of hyperplastic and hypertrophied islet cells forming micronodules (indicated by the black arrows) which observe the normal lobar architecture. There are also regions of lymphocytic infiltration (yellow arrows) and fibrosis (white arrow) and ductular proliferation

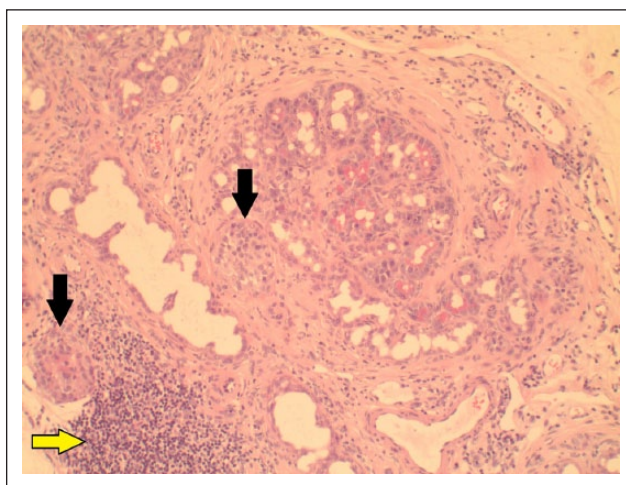


Figure 2 Medium power ($\times 100$ magnification) of the affected pancreas. There are multiple regions of hyperplastic and hypertrophied islet cells forming micronodules (indicated by the black arrows). There is also a region of lymphocytic infiltration (yellow arrow)

syndrome in people, where it is often referred to as nesidioblastosis. This syndrome has been increasingly identified in the human field since 1980, where it is now documented as the cause in up to 7% of adults who present with hyperinsulinaemic hypoglycaemia.^{1,2}

Nesidioblastosis describes a syndrome of hyperinsulinaemia and associated hypoglycaemia secondary to focal or diffuse non-neoplastic β -cell hypertrophy and/or hyperplasia within the pancreas.³ In humans, two distinct forms occur: the congenital and adult (acquired)

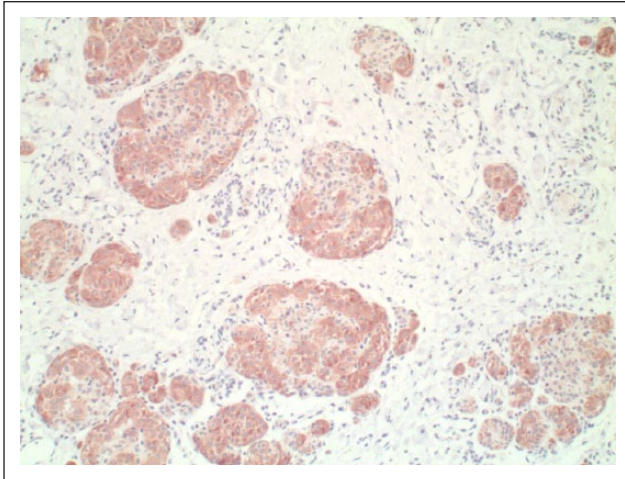


Figure 3 Medium power ($\times 100$ magnification) view of the pancreas after immunohistochemical staining. The positive (red-brown) staining represents synaptophysin on the neuroendocrine pancreatic cells. This confirms that the micronodules reflect nodules of hyperplastic and hypertrophied β -cells. The acinar cells are negatively staining

forms.²⁻⁴ While the clinical signs and biochemical findings are similar, the two forms differ in terms of the distribution of lesions within the pancreas and the aetiology.

The congenital form is more commonly associated with focal β -cell hypertrophy and tends to be associated with genetic defects resulting in dysfunction of the adenosine triphosphate-sensitive potassium channel present in the plasma membrane of pancreatic β -cells.^{3,4} The closure of these channels initiates the depolarisation of the β -cell membrane, opening of calcium channels and subsequent insulin hypersecretion.⁴ Clinical hypoglycaemia generally becomes apparent within the first 2 years of a child's life.⁴

In contrast, the adult form tends to reflect focal to diffuse β -cell hypertrophy with or without hyperplasia.³ No genetic link has been identified.³ The cause of the acquired form remains uncertain, but there is some evidence to suggest that it is a regenerative response following pancreatic injury.^{3,5} In this case, the concurrent pancreatic fibrosis and leukocytic infiltrate suggests a degree of chronic inflammation and injury which could have acted as a stimulus for nesidioblastosis.

This cat was originally suspected of having toxoplasmosis based on a high likelihood of exposure (outdoor access, fed a raw lamb diet) and a clindamycin-responsive myopathy, but this was never confirmed. The initial serum toxoplasma immunoglobulin (IgG and IgM) titres were negative and convalescent titres were not performed until 18 months later (samples collected just prior to death). At that stage the cat was IgG positive

(1:64) but IgM negative. While the IgG titre was low, seroconversion suggests exposure and possibly infection over the intervening period. If this cat were infected with toxoplasma, this could explain the chronic pancreatic injury as toxoplasma has been shown to have a high affinity for the pancreas (16–64% of cats with clinical toxoplasmosis had histopathological evidence of pancreatic involvement at post mortem) and this could have been a potential trigger for the acquired nesidioblastosis.^{6,7} Recrudescence of toxoplasmosis could also explain the recurrent myopathy and sudden death. It is unfortunate that a post mortem was not performed to investigate this possibility. To the author's knowledge there has been no prior correlation between a myopathy and nesidioblastosis in the human literature.

A diagnosis of nesidioblastosis is difficult to achieve without invasive diagnostic tests.⁸ Clinical signs reflect hypoglycaemia and are generally non-specific. While a high rate (>90%) of postprandial hypoglycaemia has been noted in people with nesidioblastosis, postprandial hypoglycaemia has occasionally been reported with insulinoma (although with the latter, fasting or exercise-induced hypoglycaemia is more common).⁹ The age of onset may have provided a clue to this non-neoplastic disease, as this cat was much younger than all previously reported cases of feline insulinoma (all were >12 years of age at diagnosis).^{10,11}

It is interesting to note that this cat was mildly hyperglycaemic at the time of presentation. This was likely to reflect the release of insulin antagonists (eg, catecholamines, corticosteroids and glucagon) in response to stress or a Somogyi effect. The hypoglycaemia did not become biochemically apparent until the signs of neuroglycopenia worsened. This situation has been documented in dogs with insulinoma, where up to 8% were normoglycaemic at the time of initial presentation.^{12,14} Consequently, a single normal blood glucose reading does not exclude hypoglycaemic disorders and repeated measurement of a fasting sample is advisable if clinical signs progress.

In this case, the insulin level was initially determined using a canine insulin chemiluminescent immunoassay (owing to the lack of local availability of a feline validated assay) and the reference interval was extrapolated from previous feline studies.¹⁰ A portion of the initial serum sample was frozen with the intention of repeating the insulin level using a feline-validated insulin assay, but the sample was lost in transit. Given that it is important to use an insulin assay that has been validated in the target species, a correlation study between the canine chemiluminescent immunoassay and a feline-validated insulin radioimmunoassay (NationWide Specialist Laboratories) was subsequently performed to validate the result and RI using feline control and test serum samples (unpublished data).

In human cases of nesidioblastosis, the pancreas is often grossly normal and the microscopic changes are difficult to discern with standard forms of preoperative pancreatic imaging.^{3,8,15} Positron emission CT targeting glucagon-like peptide 1 receptors may aid localisation but cannot distinguish between neoplastic and non-neoplastic causes.⁸ Intraoperative selective arterial stimulation tests may also aid localisation and possibly aid differentiation between an insulinoma and nesidioblastosis, but in most cases differentiation relies on histopathological analysis of the pancreas.^{2,9}

Histopathological findings in nesidioblastosis can be variable, but the most consistent finding is hypertrophy of the islet cells.³ These hypertrophied cells are often recognisable even at medium magnification as they have abundant clear cytoplasm (often twice the diameter of normal islet cells) and prominent, hyperchromatic nuclei.^{1,3} Other findings such as islet-cell hyperplasia, lobulated arrangement within the islets and an increase in β -cell mass are less common.³ In contrast to insulinoma, the lobular architecture of the exocrine pancreas is preserved and there is an absence of Ki-67 antigen activity (marker of proliferation).³ This cat satisfied these diagnostic features, although Ki-67 antigen levels were not assessed.

In one study assessing the histopathological detection of nesidioblastosis by human pathologists, the interobserver analysis revealed 100% specificity and 87.7% sensitivity.¹ False negatives were encountered when islet-cell hypertrophy was subtle.^{1,3}

Islet-cell hyperplasia has been reported as an incidental finding in post-mortem studies of research Beagles (after use in toxicology studies), aged horses and aged rats.^{5,16} None of these animals had any prior history of clinically significant hypoglycaemia. Vacuolar hyperplasia of islet-cells has also been documented as an incidental finding in diabetic dogs where it is thought to reflect a regenerative response.¹⁷ There has been no clinical or biochemical evidence of hyperinsulinism or hypoglycaemic in any of these cases.

In 2014, a hyperinsulinaemic hypoglycaemia syndrome was reported in two juvenile (6- and 9-month-old) dogs.¹⁸ Both dogs presented with neurological signs, marked hypoglycaemia, concurrent hyperinsulinaemia and a range of other haematological and biochemical abnormalities. Hypoglycaemia persisted despite glucose supplementation and frequent feeding. No further treatment was attempted, but post-mortem evaluations were performed. The pancreas appeared normal in one dog, but concurrent severe cholangitis and hepatic fibrosis were noted. Mild-to-moderate islet cell hyperplasia (without hypertrophy) was noted in the second dog along with encephalitis, arteritis and pneumonia. Both dogs returned positive PCR results for *Bartonella* species

(from the liver and blood, respectively). It is possible that these two cases represent congenital nesidioblastosis, but the role of *Bartonella* species in their hypoglycaemic, hyperinsulinaemic syndrome is unknown.

Traditionally, in humans, partial pancreatectomy has been the favoured method of both diagnosis and treatment of nesidioblastosis, but high recurrence rates have sparked more interest in medical forms of management,⁹ including diazoxide, long-acting octreotide, glucagon and calcium-channel blockers (eg, nifedipine and amlodipine).^{2,19} Medical management was not attempted in this case, but partial pancreatectomy appeared an effective form of treatment as the hypoglycaemia did not recur.

This the first time successful treatment of clinically significant, acquired nesidioblastosis has been reported in the veterinary field and the first time nesidioblastosis has been reported in the cat. While it is difficult to prognosticate based on one feline case, the prognosis of people diagnosed with nesidioblastosis is considered good.¹⁹

Conclusions

While this condition is rare, nesidioblastosis is an important differential to consider when investigating hypoglycaemia as it cannot be differentiated from insulinoma without histopathological evaluation. Given that the pancreas can appear grossly normal in humans with this condition, histopathological analysis of the pancreas should be undertaken in hyperinsulinaemic, hypoglycaemic patients even if focal pathology cannot be identified. Postprandial hypoglycaemia in a young-to-middle-aged patient with normal pancreatic imaging may give rise to a clinical suspicion of nesidioblastosis. In contrast with insulinoma, the prognosis of patients diagnosed with nesidioblastosis may be more favourable.

Acknowledgements Colleagues at Advanced Vetcare and ASAP laboratories.

Funding The authors received no financial support for the research, authorship, and/or publication of this article.

Conflict of interest The authors declared no potential conflicts of interest with respect to the research, authorship, and/or publication of this article.

References

- 1 Anlauf M, Wieben D, Perren A, et al. **Persistent hyperinsulinemic hypoglycemia in 15 adults with diffuse nesidioblastosis: diagnostic criteria, incidence, and characterization of beta-cell changes.** *Am J Surg Pathol* 2005; 29: 524–533.
- 2 Kaczirek K and Niederle B. **Nesidioblastosis: an old term and a new understanding.** *World J Surg* 2004; 28: 1227–1230.

- 3 Klöppel G, Anlauf M, Raffel A, et al. **Adult diffuse nesidioblastosis: genetically or environmentally induced?** *Hum Pathol* 2008; 39: 3–8.
- 4 Arnoux JB, de Lonlay P, Ribeiro MJ, et al. **Congenital hyperinsulinism.** *Early Hum Dev* 2010; 86: 287–294.
- 5 Furuoka H, Shirakawa T, Taniyama H, et al. **Histogenesis of neof ormation in the endocrine pancreas of ageing horses.** *Vet Pathol* 1989; 26: 40–46.
- 6 Dubey JP and Carpenter JL. **Histologically confirmed clinical toxoplasmosis in cats: 100 cases (1952–1990).** *J Am Vet Med Assoc* 1993; 203: 1556–1566.
- 7 Jokelainen P, Simola O, Rantanen E, et al. **Feline toxoplasmosis in Finland: cross-sectional epidemiological study and case series study.** *J Vet Diagn Invest* 2012; 24: 1115–1124.
- 8 Christ E, Wild D, Antwi K, et al. **Preoperative localization of adult nesidioblastosis using (68)Ga-DOTA-exendin-4-PET/CT.** *Endocrine* 2015; 50: 821–823.
- 9 Thompson SM, Vella A, Thompson GB, et al. **Selective arterial calcium stimulation with hepatic venous sampling differentiates insulinoma from nesidioblastosis.** *J Clin Endocrinol Metab* 2015; 100: 4189–4197.
- 10 Greene SN and Bright RM. **Insulinoma in a cat.** *J Small Anim Pract* 2008; 49: 38–40.
- 11 Schaub S and Wigger A. **Ultrasound-aided diagnosis of an insulinoma in a cat.** *Tierarztl Prax Ausg K Kleintiere Heimtiere* 2013; 41: 338–342.
- 12 Kruth SA, Feldman EC and Kennedy PC. **Insulin-secreting islet cell tumors: establishing a diagnosis and the clinical course for 25 dogs.** *J Am Vet Med Assoc* 1982; 181: 54–58.
- 13 Leifer CE, Peterson ME and Matus RE. **Insulin-secreting tumor: diagnosis and medical and surgical management in 55 dogs.** *J Am Vet Med Assoc* 1986; 188: 60–64.
- 14 Caywood DD, Klausner JS, O’Leary TP, et al. **Pancreatic insulin-secreting neoplasms: clinical, diagnostic and prognostic features in 73 dogs.** *J Am Anim Hosp Assoc* 1988; 24: 577–584.
- 15 Martens P and Tits J. **Approach to the patient with spontaneous hypoglycemia.** *Eur J Intern Med* 2014; 25: 415–421.
- 16 Sato J, Doi T, Wako Y, et al. **Histopathology of incidental findings in beagles used in toxicity studies.** *J Toxicol Pathol* 2012; 25: 103–134.
- 17 Minkus G, Breuer W, Arun S, et al. **Ductuloendocrine cell proliferation in the pancreas of two young dogs with diabetes mellitus.** *Vet Pathol* 1997; 34: 164–167.
- 18 Breitschwerdt EB, Goldkamp C, Castleman WL, et al. **Hyperinsulinemic hypoglycemia syndrome in 2 dogs with bartonellosis.** *J Vet Intern Med* 2014; 28: 1331–1335.
- 19 Martin-Grace J, O’Tuathail M, Hannon MJ, et al. **Amlodipine for the medical treatment of adult-onset diffuse nesidioblastosis.** *Pancreas* 2015; 44: 1162–1164.