



## **Feline cutaneous nodular and ocular *Cryptococcus neoformans* in Belgium**

Authors: Nunes Rodrigues, Tania C, Stroobants, Laura R, and Vandenabeele, Sophie I

Source: Journal of Feline Medicine and Surgery Open Reports, 6(1)

Published By: SAGE Publishing

URL: <https://doi.org/10.1177/2055116920912560>

---

BioOne Complete ([complete.BioOne.org](https://complete.BioOne.org)) is a full-text database of 200 subscribed and open-access titles in the biological, ecological, and environmental sciences published by nonprofit societies, associations, museums, institutions, and presses.

Your use of this PDF, the BioOne Complete website, and all posted and associated content indicates your acceptance of BioOne's Terms of Use, available at [www.bioone.org/terms-of-use](https://www.bioone.org/terms-of-use).

Usage of BioOne Complete content is strictly limited to personal, educational, and non - commercial use. Commercial inquiries or rights and permissions requests should be directed to the individual publisher as copyright holder.

---

BioOne sees sustainable scholarly publishing as an inherently collaborative enterprise connecting authors, nonprofit publishers, academic institutions, research libraries, and research funders in the common goal of maximizing access to critical research.



# Feline cutaneous nodular and ocular *Cryptococcus neoformans* in Belgium

Tania C Nunes Rodrigues , Laura R Stroobants and Sophie I Vandenabeele

*Journal of Feline Medicine and Surgery Open Reports*  
1–7

© The Author(s) 2020

Article reuse guidelines:

sagepub.com/journals-permissions

DOI: 10.1177/2055116920912560

journals.sagepub.com/home/jfmsopenreports

This paper was handled and processed by the European Editorial Office (ISFM) for publication in *JFMS Open Reports*



## Abstract

**Case summary** An 11-year-old spayed female cat presented with a 6-month history of a progressive nodular skin disease with concurrent, ocular lesions, intermittent vomiting, halitosis and weight loss. The cat had received different topical treatments without success prior to referral to the Dermatology Department of Faculty of Veterinary Medicine, Ghent University. Several fine-needle aspirations of the lesions showed a vast number of macrophages with intra-cytoplasmic inclusions compatible with *Cryptococcus* species. Histopathological examination revealed pyogranulomatous inflammation with capsulated yeast. Periodic acid–Schiff stain was positive. Latex cryptococcal antigen agglutination test on serum was positive with a titre of >1/524,288. PCR and fungal culture identified *Cryptococcus neoformans*. The cat was treated with itraconazole 10 mg/kg PO q24h. After 10 months of therapy, there was a complete resolution of the lesions except for a small nodule on the ventral aspect of the tongue.

**Relevance and novel information** As far as we are aware, this is the first feline case reported of cutaneous nodular cryptococcosis without nasal involvement in Belgium. Oral itraconazole therapy was well tolerated and appeared to give a good result and prognosis.

**Keywords:** *Cryptococcus*; nodules; skin; systemic; deep mycoses; disseminated

**Accepted:** 20 February 2020

## Case description

An 11-year-old spayed female cat presented with a 6-month history of a progressive skin disease consisting of asymmetric eroded nodules on the head, right paw pad, shoulder and caudal dorsum. The owner reported intermittent vomiting and weight loss. Lethargy and partial anorexia had been present for 2 weeks. Vaccination and deworming were not up to date. The cat had access to the outdoors by walks on a leash, and had never left the country. Several topical treatments with polyvidone iodine (Iso-betadine; Meda Pharma), fusidic acid cream (Affusine; Will Pharma) and betamethasone cream (Betnelan; GSK) were ineffective. Fine-needle aspirate (FNA) cytology of the nodules at the primary veterinarian were inconclusive.

The cat was sedated with dexmedetomidine (Dexdomitor; Zoetis) 10 µg/kg and methadone (Insistor; Eucuphar) 0.2 mg/kg IM for examination and

investigation due to behaviour. A mask with oxygen was provided during the sedation.

The cat weighed 3.15 kg and its body condition score was 3/9.<sup>1</sup> The physical examination was unremarkable except for the presence of halitosis and a weight loss of 400 g since the last visit to the primary veterinarian. Dermatological examination revealed several eroded nodules on the top of the head, pinna, chin, and on the margin and ventral aspect of the tongue, as well as on the footpad of the right forelimb (Figures 1–3). The dermal nodules were well circumscribed, erythematous and

Small Animal Department, Faculty of Veterinary Medicine, Ghent University, Merelbeke, Belgium

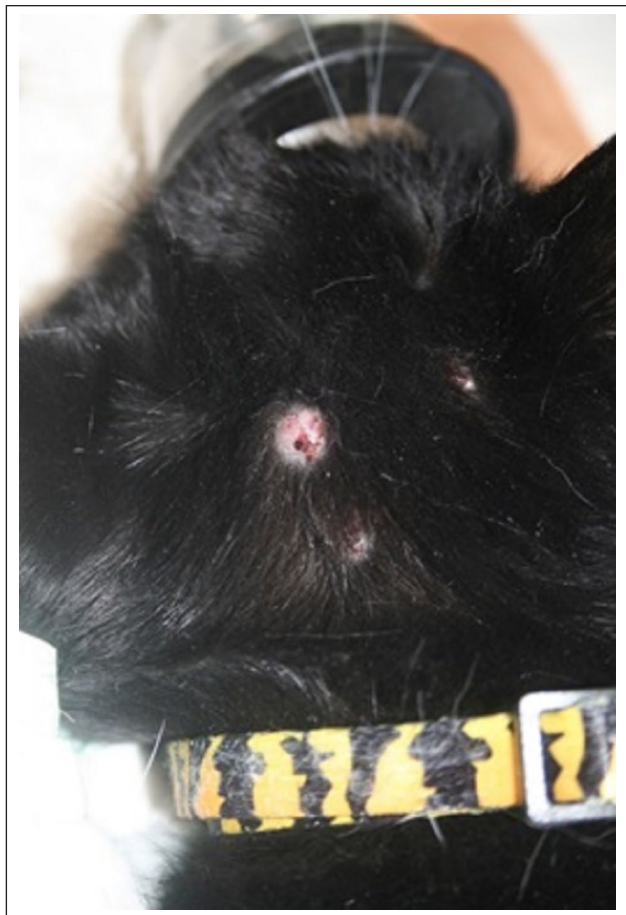### Corresponding author:

Tania C Nunes Rodrigues CertAVP (VD), PgCert (VPS), MRCVS, Small Animal Department, Faculty of Veterinary Medicine, Ghent University, Salisburylaan 133, Merelbeke 9820, Belgium  
Email: tania.rodrigues@ugent.be



Creative Commons Non Commercial CC BY-NC: This article is distributed under the terms of the Creative Commons

Attribution-NonCommercial 4.0 License (<https://creativecommons.org/licenses/by-nc/4.0/>) which permits non-commercial use, reproduction and distribution of the work without further permission provided the original work is attributed as specified on the SAGE and Open Access pages (<https://us.sagepub.com/en-us/nam/open-access-at-sage>).



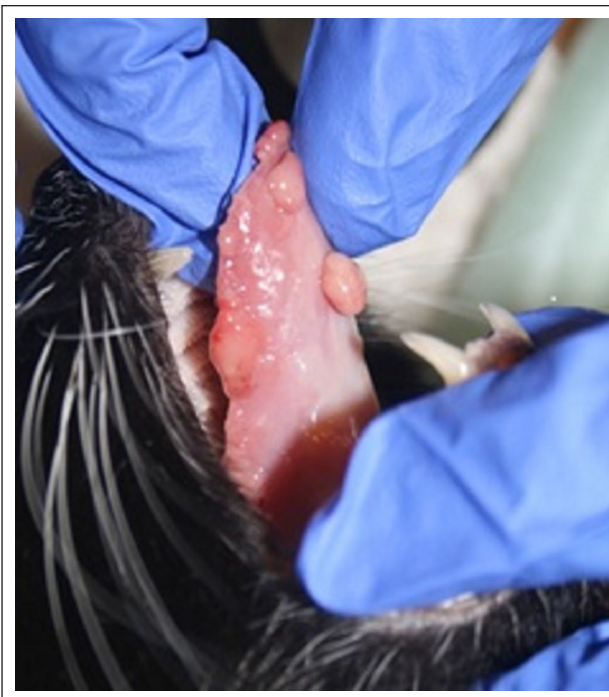**Figure 1** Three alopecic nodules on the top of the head with a mild amount of crusts present centrally

alopecic, and some had central erosions. The right eye presented with anterior uveitis with keratic precipitates (Figure 4). The differential diagnoses for feline anterior uveitis comprised trauma, infections (viral, bacterial, mycotic or parasitic), neoplastic, lens-induced (cataract, lens luxation) or idiopathic causes.<sup>2</sup>

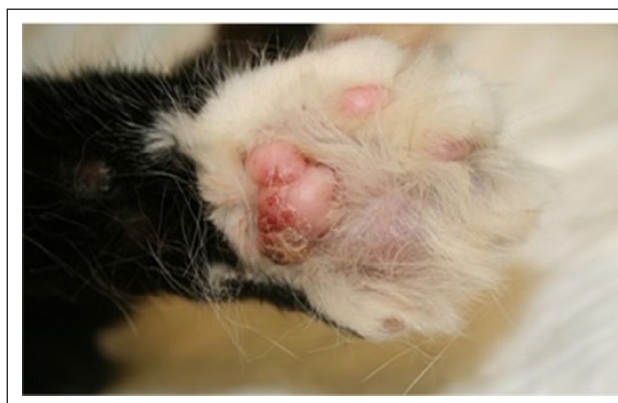Considering the history and clinical presentation, the differential diagnoses included infectious causes such as systemic mycoses (eg, sporotrichosis, cryptococcosis), feline leprosy syndrome, nocardiosis, neoplasia (eg, squamous cell carcinoma) or immune-mediated diseases such as eosinophilic granuloma complex.

A venous blood sample was collected from the jugular vein for complete blood count and biochemistry profile to assess leukogram, assess organ function and electrolyte balance. The blood result was unremarkable. A SNAP test (IDEXX SNAP FeLV/FIV) was performed to assess the presence of feline immunodeficiency virus (FIV) and feline leukemia virus (FeLV). The cat was negative for FIV and FeLV.

Several FNAs of the lesions were taken. Samples were stained with Diff-Quick (RAL Diff-Quik; RAL Diagnostics) and cytology showed histiocytes, giant cells, neutrophils and vast numbers of spherical yeasts

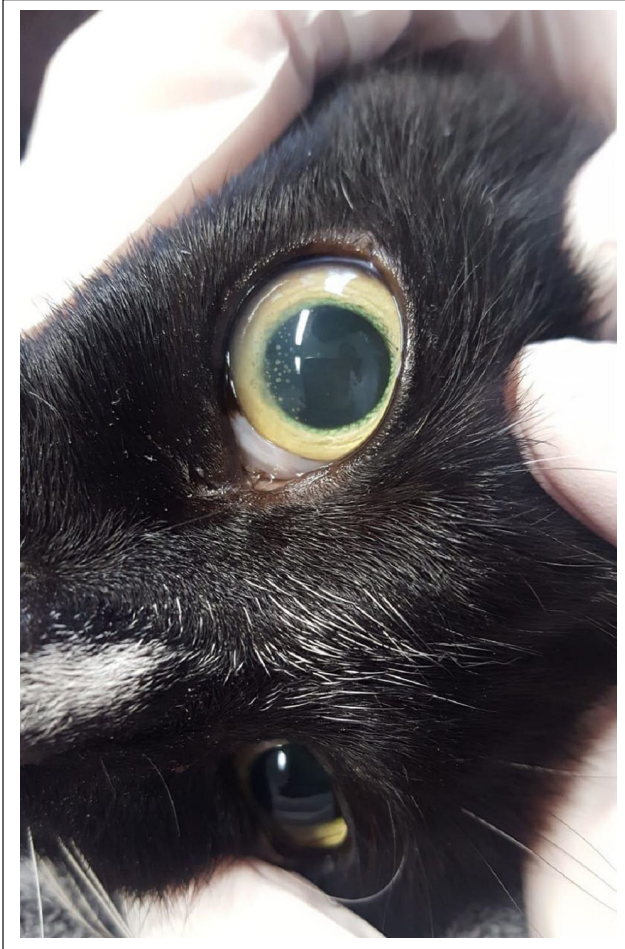


**Figure 2** Tongue with three nodules on the ventral aspect and ulceration on the margin



**Figure 3** Right thoracic limb showing papular lesions and crusts on the carpal paw pad and an interdigital nodule

with large, non-staining refractile capsules resembling cryptococcosis (Figure 5). An additional blood sample was sent for a latex cryptococcal antigen agglutination test (LCAAT) to an external laboratory (Algemeen Medisch Laboratorium, Antwerp, Belgium). The serology result revealed a marked increase in antigen titres ( $>1/524,288$ ). Biopsies were taken from the head and shoulder for histopathology, fungal culture and PCR. The histopathology showed ulcerated epidermis, nodular encapsulated inflammatory infiltrates with histiocytes, giant cells and neutrophils (Figure 6). Moreover, periodic acid-Schiff (PAS) staining was positive (Figure 7), and fungal culture and PCR test confirmed the diagnosis of *Cryptococcus neoformans*.



**Figure 4** Right eye with anterior uveitis with ventral keratic precipitates

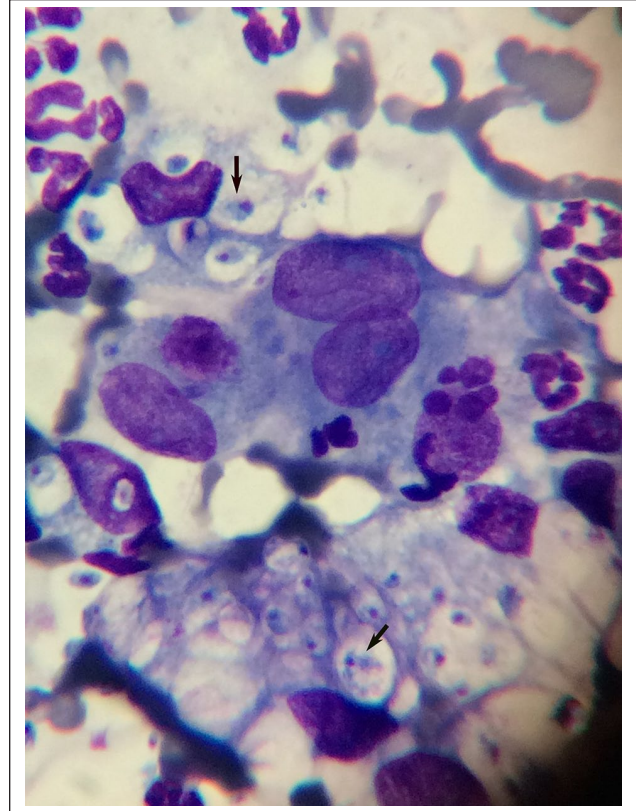
Radiographs of the thorax (two views) and head (two views) were taken to exclude chest, nasal cavity, sinuses and brain involvement. The radiographs were unremarkable.

Upon diagnosis of cryptococcosis, the cat was treated with oral itraconazole (Itrafungol; Elanco) 10mg/kg q24h.

After 6 weeks of therapy, there was a complete resolution of uveitis and a clear improvement of the skin lesions resulting in the absence of abnormalities on clinical examination. An oral examination was not performed owing to the aggressive nature of the cat. A blood sample was taken for LCAAT and the result was positive with reduction of the antigen titre by 32-fold.

The cat was sedated 4 months after starting treatment for a blood sample and dermatological examination. LCAAT was positive, with an antigen titre of 1/16,384. Dermatological examination revealed a small nodule on the tongue (Figure 8), and there were no other abnormalities.

Ten months after initial treatment, complete blood count and serum biochemical analysis were

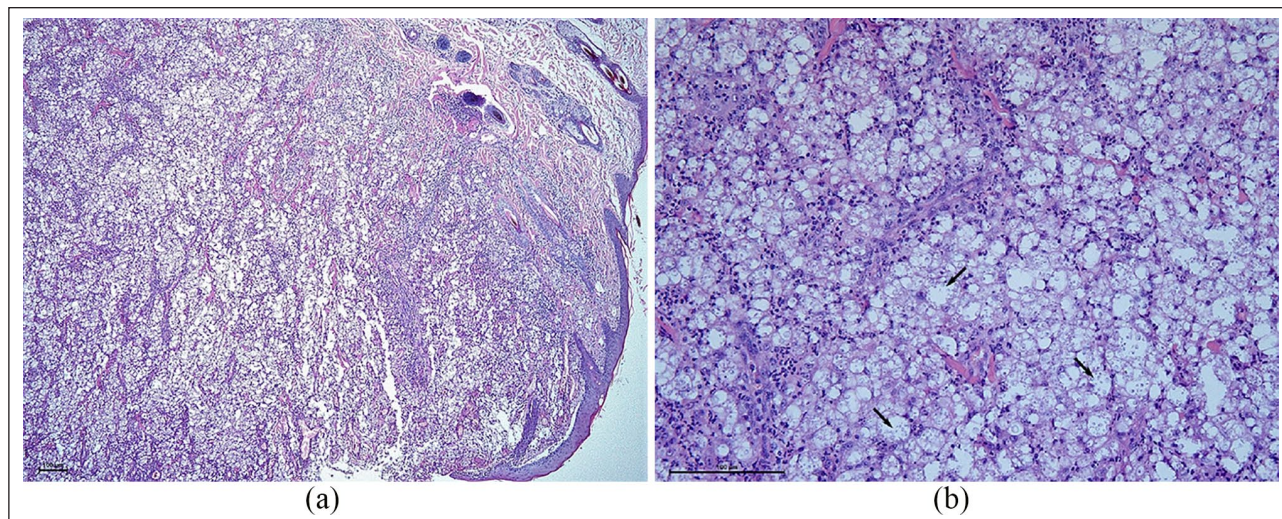


**Figure 5** Microscopic examination of fine-needle aspirate cytology: histiocytes with *Cryptococcus neoformans*. Note the spherical yeasts surrounded by unstained capsules giving the appearance of 'soap bubbles' (arrows) (Diff-Quik, 1000× magnification).

unremarkable. The nodule present on the tongue was smaller and LCAAT was markedly reduced to 1/1024. The patient had gained 410g since the first visit and no side effects were reported during therapy.

## Discussion

Feline cryptococcosis is the most common systemic fungal pathogen and can infect immunocompetent animals.<sup>3,4</sup> Feline cryptococcosis is caused by *C neoformans*–*Cryptococcus gattii* species complex with eight genotypes and various subtypes (strains).<sup>5</sup> Pathogenicity, geographical distribution and antimicrobial susceptibility varies with the genotypes.<sup>5</sup> Cryptococcosis is a rare condition and has a worldwide distribution with a higher prevalence in warm regions. However, a few cases have been reported in moderate climates such as Austria, the UK, the Netherlands and in Belgium.<sup>6–9</sup> Cryptococcosis can affect other animals and humans. Cats are the most common domestic species affected by cryptococcosis and might represent a sentinel for human infection.<sup>4</sup> It is a non-contagious disease,<sup>10</sup> and it has been associated with decaying trees and vegetation.<sup>11,12</sup> Moreover, *C neoformans* is usually carried by pigeon droppings.<sup>11,12</sup> The



**Figure 6** (a) Haematoxylin and eosin photomicrograph ( $\times 5$  magnification) revealing diffuse nodular non-encapsulated infiltrates affecting the dermis. Note the presence of multiple clear spaces in the dermis. (b) Same biopsy specimen ( $\times 20$  magnification) showing abundant yeast-like organisms with an unstained capsule (arrows). Pyogranulomatous infiltrate evident on biopsy sample.

infection is normally acquired by inhalation of basidiomycetous yeasts from the contaminated environment to the respiratory system,<sup>5</sup> although cutaneous inoculation has been reported.<sup>4,5,13</sup> Commonly, the source of infection is unknown, with an incubation time varying from months to years.<sup>4,5,13</sup> In this case, the cat never left the country and had walked in a city park where lots of pigeons were present. There is no age, breed or sex predisposition for this condition.<sup>14,15</sup> However, it appears to affect more males,<sup>15</sup> which is not consistent with the presented case.

Duncan et al<sup>16</sup> stated that asymptotically infected animals might resolve the infection, remain subclinically affected or develop clinical disease.

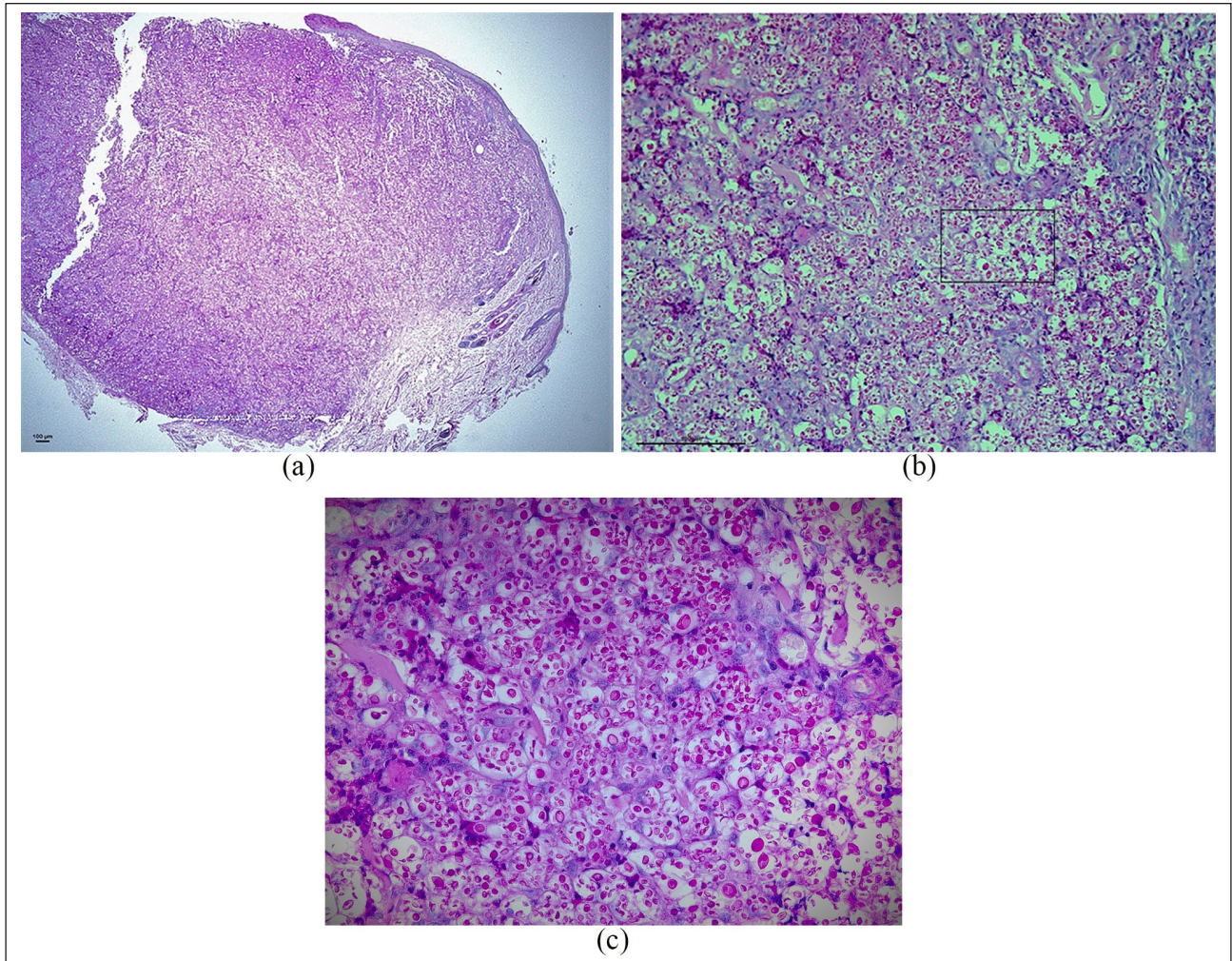
Cryptococcosis can present with dermatological, ophthalmological, respiratory and/or neurological signs.<sup>14</sup> Deformation of the nasal region is a classic characteristic clinical sign of cutaneous cryptococcosis.<sup>17</sup> Cutaneous lesions are occasionally reported as an extension of the sinonasal pathology or can be present without nasal disease.<sup>17</sup> In both dogs and cats, cutaneous lesions present as dermal or subcutaneous well-circumscribed, firm nodules that can ulcerate.<sup>17</sup> One cat in Belgium showed disseminated disease with respiratory signs.<sup>9</sup> In this case, the cat did not manifest involvement of the nasal cavity. In the USA, Myers et al<sup>18</sup> reported a cat with a similar location of the lesions (head, trunk and limbs) as the presented case. The cutaneous lesions, the nodules on the tongue and uveitis in the present case suggest haematogenous dissemination from a subclinical respiratory infection or a primary cutaneous lesion.<sup>18</sup> The organisms can be disseminated to other tissues within macrophages.<sup>4</sup> Other ocular lesions reported in

the literature include chorioretinitis, optic neuritis, endophthalmitis, panophthalmitis, retinal detachment<sup>19</sup> and blepharitis.<sup>20</sup> Fundoscopic examination and other ophthalmological investigations were not performed and therefore other ocular lesions cannot be excluded. Ocular involvement can be indicative of concomitant involvement of the central nervous system (CNS).<sup>4</sup> However, there were no other clinical signs in the present case that could suggest neurological involvement. Cryptococcus infection usually manifests on the nasal cavity, skin, lymph nodes, brain, meninges and eyes.<sup>4</sup> It has been identified with lower incidence in the mediastinum, oral mucosa, tongue, spleen, myocardium, liver, thyroid and bone.<sup>21</sup>

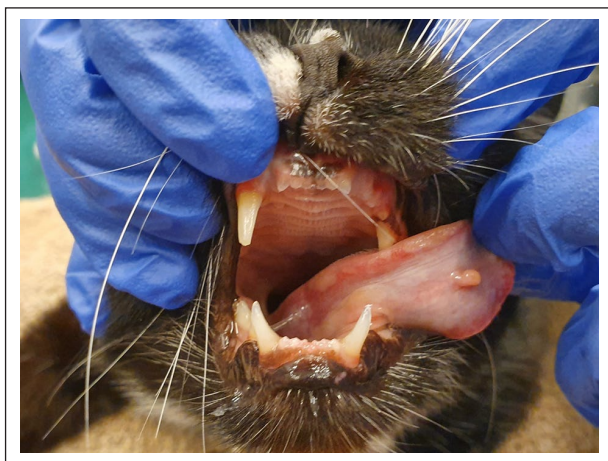Other systemic signs, including lethargy, anorexia and weight loss, might be present in chronic cases due to severe dissemination.<sup>4</sup> In this case report, there were lesions present in the tongue that could contribute to the halitosis, lethargy and anorexia.

The diagnosis of cryptococcosis can be established by cytological examination of the skin lesions or histopathology, LCAAT, fungal culture or PCR.<sup>4,5</sup> In the present case, we discussed collecting all samples at one time owing to the cat's behaviour. Haematology and biochemistry results can demonstrate mild to non-specific abnormalities.<sup>4</sup> In the presented case no abnormalities were detected. Thoracic radiographs are usually unremarkable, as seen in this reported case, although small thoracic nodules or interstitial to alveolar infiltrates can be identified in some cases.<sup>4</sup>

Cytology can be an affordable and easy tool to diagnose cryptococcosis using samples from impression smears of ulcerated lesions or biopsies samples, FNAs of



**Figure 7** (a) Periodic acid–Schiff (PAS) stain photomicrograph ( $\times 2.5$  magnification) tissue sample specimen showing ulcerated epidermis, and well-demarcated and non-encapsulated inflammatory infiltrate affecting the dermis. (b) PAS stain photomicrograph ( $\times 20$  magnification) with numerous spherical yeast-like organisms with prominent unstained capsule (examples on selected area). (c) PAS stain photomicrograph ( $\times 40$  magnification) with countless *Cryptococcus neoformans*



**Figure 8** Small nodule on the ventral aspect of the tongue

nodular lesions or bronchoalveolar lavage fluid or cerebrospinal fluid (CSF) taps.<sup>5</sup> The presence of the numerous organisms surrounded by an unstained capsule with pyogranulomatous inflammation is characteristic of cryptococcosis.<sup>5</sup> In the present case, the cytology of the nodular lesions was diagnostic with numerous organisms present in all samples.

Antigen detection in body fluids is a straightforward and reliable diagnostic test.<sup>5</sup> LCAAT can be performed on serum, CSF and urine.<sup>5</sup> LCAAT in serum has a high sensitivity, ranging between 90% and 100%, and a specificity ranging between 97% and 100%.<sup>15,21,22</sup> Serum titres of feline cryptococcosis are usually markedly increased; however, false negatives can occur in localised disease.<sup>21,22</sup> In cats with lower antigen titres ( $\leq 1:200$ ), it is recommended to perform other diagnostic tests to

confirm the diagnosis.<sup>4</sup> LCAAT can be used to monitor the response to therapy; therefore, a higher titre can be related to more severe disease.<sup>14</sup> O'Brien et al<sup>23</sup> reported a case where after clinical resolution and stopping treatment, the serum titre was still positive; however, it continued decreasing. In the reported case, the antigen titre decreased but was still positive, even with almost complete resolution of clinical signs.

Biopsy samples from skin lesions in the present case were taken for histopathology, PCR and fungal culture. Impression smear for cytology may give additional information.<sup>5</sup> Haematoxylin and eosin-stained sections show pyogranulomatous inflammation with eosinophilic organisms surrounded by an unstained halo.<sup>5</sup> PAS stain demonstrates numerous intra histiocytic positive fungi. The presented case showed the same features in both stained samples. The capsule can be stained rose-red with Mayer's mucicarmine method.<sup>5</sup>

PCR and isolation allow the identification of the species involved and the genotype can be found by PCR.<sup>5</sup> A fungal culture is not a hazard to laboratory personnel and allows differentiation between *C neoformans* and *C gattii*, and can determine antifungal susceptibility.<sup>4</sup> Culture should be performed if the LCAAT result is low or negative.<sup>5</sup> In the present case, fungal culture and PCR were consistent with *C neoformans*. Positive cultures and histological changes are considered diagnostic.<sup>5</sup>

Treatment for cryptococcosis has not been implemented immediately owing to potential comorbidities that can affect drug choice.<sup>5</sup> The case reported was treated with itraconazole owing to financial constraints because it showed good results with disseminated disease.<sup>23</sup> Side effects of the treatment include anorexia, vomiting and hepatotoxicity.<sup>24</sup> Mild elevations of alanine aminotransferase<sup>25,26</sup> and anorexia can occur, and are usually dose-dependent.<sup>27</sup> One study cited by Hodges and colleagues<sup>26</sup> showed no serious side effects in 17/18 cats treated for 5–9 months with 50–100 mg of itraconazole daily.<sup>28</sup> Long-term itraconazole therapy was well tolerated and no side effects were reported in two studies.<sup>29,30</sup> The cat was treated with 10 mg/kg itraconazole, although the advice is to reduce this to 3 mg/kg if using the oral suspension.<sup>4</sup> Ideally, liver parameters should be monitored monthly during treatment.<sup>5</sup> In this case, it was performed prior to medication and before discontinuation of therapy, owing to the financial constraints of the owner and the required sedation for a blood draw in this cat. On reflection, supplementation with hepatoprotectants could have been added.<sup>31</sup> However, the cat's behaviour while taking medication did not allow the implementation of other therapy.

Other treatments include fluconazole, ketoconazole, amphotericin B and flucytosine.<sup>5,24,32</sup> Fluconazole is usually indicated for localised disease,<sup>5</sup> but some cryptococcal isolates have shown resistance with this

drug.<sup>33–35</sup> Ketoconazole is a good choice for localised disease; however, it has more adverse effects than itraconazole.<sup>4</sup> Anorexia and weight loss have been reported in cats treated with ketoconazole after inoculation with *C neoformans*.<sup>36</sup> However, there were no abnormalities in those treated with itraconazole in the same study.<sup>36</sup> Amphotericin B and flucytosine have been prescribed for cats with cryptococcosis involving the CNS with or without systemic disease.<sup>4,5</sup> The treatment is recommended until 2–4 months after complete resolution of clinical signs and antigen testing is negative.<sup>5</sup>

The prognosis is good if the diagnosis is achieved in early stages,<sup>12,19</sup> the patient does not present neurological signs<sup>32</sup> and prolonged treatment is maintained.

## Conclusions

To our knowledge, this is the first case of cryptococcosis reported in Belgium and represents a cutaneous and systemic manifestation of *C neoformans* without the nasal disease. Cryptococcosis should be considered a differential diagnosis for cutaneous nodular diseases in moderate climates. Long-term therapy with oral itraconazole resulted in almost complete resolution of the disease without side effects.

**Conflict of interest** The authors declared no potential conflicts of interest with respect to the research, authorship, and/or publication of this article.

**Funding** The authors received no financial support for the research, authorship, and/or publication of this article.

**Ethical approval** This work involved the use of non-experimental animals only (including owned or unowned animals and data from prospective or retrospective studies). Established internationally recognised high standards ('best practice') of individual veterinary clinical patient care were followed. Ethical approval from a committee was therefore not necessarily required.

**Informed consent** Informed consent (either verbal or written) was obtained from the owner or legal custodian of all animal(s) described in this work (either experimental or non-experimental animals) for the procedure(s) undertaken (either prospective or retrospective studies). For any animals or humans individually identifiable within this publication, informed consent (either verbal or written) for their use in the publication was obtained from the people involved.

**ORCID ID** Tania C Nunes Rodrigues  <https://orcid.org/0000-0002-5464-5280>

## References

- WSAVA. **Body condition score.** [https://www.wsava.org/WSAVA/media/PDF\\_old/Body-condition-score-chart-cats.pdf](https://www.wsava.org/WSAVA/media/PDF_old/Body-condition-score-chart-cats.pdf) (2013, accessed August 2, 2019).

- 2 Gough A. Differential diagnosis in small animal medicine. Oxford: Blackwell Publishing, 2007, pp 175–177.
- 3 Sykes JE and Malik R. **Cryptococcosis**. In: Sykes JE (ed). Canine and feline infectious diseases. St Louis, MO: Elsevier, 2014, pp. 599–612.
- 4 Trivedi SR, Malik R, Meyer W, et al. **Feline cryptococcosis: impact of current research on clinical management**. *J Feline Med Surg* 2011; 13: 163–172.
- 5 Pennisi MG, Hartmann K, Lloret A, et al. **Cryptococcosis in cats: ABCD guidelines on prevention and management**. *J Feline Med Surg* 2013; 15: 611–618.
- 6 Gionfriddo JR. **Feline systemic fungal infections**. *Vet Clin North Am Small Anim Pract* 2000; 30: 1029–1050.
- 7 Köhler H, Gialamas J and Kuttin ES. **Cryptococcosis in a cat in Austria**. *Dtsch Tierarztl Wochenschr* 1976; 83: 492–495.
- 8 Tjalsma EJ. **Two cases of cryptococcosis in cats**. *Tijdschr Diergeneeskd* 1997; 122: 128–132.
- 9 Junius G and Schrauwen E. **Disseminated cryptococcosis in a cat in a moderate climate region**. *Vlaams Diergeneeskd Tijdschr* 2003; 72: 299–301.
- 10 Benenson A. **Manual para el control de las enfermedades transmisibles**. *Rev Esp Salud Publica* 1997; 71: 5.
- 11 Fortes ST, Lazéra MS, Nishikawa MM, et al. **First isolation of *Cryptococcus neoformans* var. *gattii* from a native jungle tree in the Brazilian Amazon rainforest**. *Mycoses* 2001; 44: 137–140.
- 12 Castellá G, Abarca ML and Cabañes FJ. **Criptococosis y animales de compañía**. *Rev Iberoam Micol* 2008; 25: S19–S24.
- 13 Malik R, Vogelnest L, O'Brien CR, et al. **Infections and some other conditions affecting the skin and subcutis of the naso-ocular region of cats – clinical experience 1987–2003**. *J Feline Med Surg* 2004; 6: 383–390.
- 14 Wolf A. **Fungal diseases of the nasal cavity of the dog and the cat**. *Vet Clin North Am Small Anim Pract* 1992; 222: 1124–1132.
- 15 Malik R, Wigney D and Muir D. **Cryptococcosis in cats: clinical and mycological assessment of 29 cases and evaluation of treatment using orally administered fluconazole**. *J Med Vet Mycol* 1992; 30: 133–144.
- 16 Duncan C, Stephen C, Lester S, et al. **Follow-up study of dogs and cats with asymptomatic *Cryptococcus gattii* infection or nasal colonization**. *Med Mycol* 2005; 43: 663–666.
- 17 Gross TL, Ihrke PJ, Walder EJ, et al. **Skin diseases of the dog and cat: clinical and histopathological diagnosis**. 2nd ed. Ames, IA: Blackwell Publishing, 2005.
- 18 Myers A, Meason-Smith C, Mansell J, et al. **Atypical cutaneous cryptococcosis in four cats in the USA**. *Vet Dermatol* 2017; 28: 405–e497.
- 19 Sykes JE and Malik R. **Cryptococcosis**. In: Sykes JE (ed). Canine and feline infectious diseases. St Louis, MO: WB Saunders, 2014, pp 599–612.
- 20 Pimenta P, Alves-Pimenta S, Barros J, et al. **Blepharitis due to *Cryptococcus neoformans* in a cat from northern Portugal**. *JFMS Open Rep* 2015; 1. DOI: 10.1177/20551169155939630.
- 21 Trivedi SR, Sykes JE, Cannon MS, et al. **Clinical features and epidemiology of cryptococcosis in cats and dogs in California: 93 cases (1988–2010)**. *J Am Vet Med Assoc* 2011; 239: 357–369.
- 22 Malik R, McPetrie R, Wigney D, et al. **A latex cryptococcal antigen agglutination test for diagnosis and monitoring of therapy for cryptococcosis**. *Aust Vet J* 1996; 74: 358–364.
- 23 O'Brien C, Krockenberger M, Martin P, et al. **Long-term outcome of therapy for 59 cats and 11 dogs with cryptococcosis**. *Aust Vet J* 2006; 84: 384–392.
- 24 Grooters A and Taboada J. **Update on antifungal therapy**. *Vet Clin North Am Small Anim Pract* 2003; 33: 749–758.
- 25 Greene CE and Watson ADJ. **Antifungal chemotherapy**. In: Greene CE (ed.). Infectious diseases of the dog and cat. 2nd ed. Philadelphia, PA: WB Saunders, 1998, pp 357–362.
- 26 Hodges RD, Legendre AM, Adams LG, et al. **Itraconazole for the treatment of histoplasmosis in cats**. *J Vet Intern Med* 1994; 8: 409–413.
- 27 Greene CE and Sykes JE. **Antimicrobial drug formulary**. In: Louis S (ed). Infectious diseases of the dog and cat. 4th ed. St Louis, MO: Elsevier Saunders, 2012, pp 1268–1270.
- 28 Medleau L. **Treatment of feline cryptococcus with itraconazole**. Annual Conference of the American Academy of Veterinary Dermatology; 1989; St Louis, MO, USA, pp 228–229.
- 29 Brömel C and Sykes J. **Histoplasmosis in dogs and cats**. *Clin Tech Small Anim Pract* 2005; 20: 227–232.
- 30 Mikawa M, Mikawa K, Itoh T, et al. **Itraconazole used to treat disseminated cryptococcosis in a cat seropositive for feline leukemia virus**. *J Jpn Vet Med Assoc* 2004; 57: 583–586.
- 31 Boothe DM. **Treatment of fungal infections**. In: Boothe DM (ed). Small animal clinical pharmacology and therapeutics e-book. 2nd ed. St Louis, MO: Elsevier Health Sciences, 2011, pp 364–397.
- 32 Montoya M and Zamora V. **Aislamiento de *cryptococcus neoformans* var. *Crubii* en un felino doméstico. Reporte de caso**. *Rev Med Vet* 2009; 18: 53–61.
- 33 Chong HS, Dagg R, Malik R, et al. **In vitro susceptibility of the yeast pathogen *Cryptococcus* to fluconazole and other azoles varies with molecular genotype**. *J Clin Microbiol* 2010; 48: 4115–4120.
- 34 Sykes JE, Hodge G, Singapuri A, et al. **In vivo development of fluconazole resistance in serial *Cryptococcus gattii* isolates from a cat**. *Med Mycol* 2016; 55: 396–401.
- 35 Kano R, Okubo M, Yanai T, et al. **First isolation of azole-resistant *Cryptococcus neoformans* from feline cryptococcosis**. *Mycopathologia* 2015; 180: 427–433.
- 36 Medleau L, Greene C and Rakich P. **Evaluation of ketoconazole and itraconazole for treatment of disseminated cryptococcosis in cats**. *Am J Vet Res* 1990; 51: 1454–1458.