



Rostral mandibulectomy for the management of trismus in a cat

Authors: Parsons, Kevin, Langley-Hobbs, Sorrel, Warren-Smith, Christopher, Southerden, Peter, Granger, Nicolas, et al.

Source: Journal of Feline Medicine and Surgery Open Reports, 8(1)

Published By: SAGE Publishing

URL: <https://doi.org/10.1177/20551169221074948>

BioOne Complete (complete.BioOne.org) is a full-text database of 200 subscribed and open-access titles in the biological, ecological, and environmental sciences published by nonprofit societies, associations, museums, institutions, and presses.

Your use of this PDF, the BioOne Complete website, and all posted and associated content indicates your acceptance of BioOne's Terms of Use, available at www.bioone.org/terms-of-use.

Usage of BioOne Complete content is strictly limited to personal, educational, and non - commercial use. Commercial inquiries or rights and permissions requests should be directed to the individual publisher as copyright holder.

BioOne sees sustainable scholarly publishing as an inherently collaborative enterprise connecting authors, nonprofit publishers, academic institutions, research libraries, and research funders in the common goal of maximizing access to critical research.



Rostral mandibulectomy for the management of trismus in a cat

Kevin Parsons¹, Sorrel Langley-Hobbs¹ , Christopher Warren-Smith¹, Peter Southerden², Nicolas Granger³ and Lee Meakin¹

Journal of Feline Medicine and Surgery Open Reports
1–5

© The Author(s) 2022

Article reuse guidelines:

sagepub.com/journals-permissions

DOI: 10.1177/20551169221074948

journals.sagepub.com/home/jfmsopenreports

This paper was handled and processed by the European Editorial Office (ISFM) for publication in *JFMS Open Reports*



Abstract

Case summary A 5-year-old domestic shorthair cat was evaluated for weight loss and poor coat condition due to an inability to open its mouth (trismus) following head trauma 2 months previously. Contrast CT, electromyography and temporal muscle biopsy identified findings consistent with muscle atrophy, denervation and degeneration. Conservative treatment failed to improve the trismus so a rostral mandibulectomy was performed. Following surgery, the patient resumed normal grooming behaviour and was able to eat soft food unaided. The cat re-presented 5 months postoperatively at which time its body condition had improved; however, episodes of sneezing had been noted. An oronasal fistula was diagnosed and treated successfully with a silicon nasal septum button. Follow-up at 30 months reported an excellent outcome.

Relevance and novel information Management of trismus with rostral mandibulectomy may be associated with a good return to function, including prehension and ingestion of food, and restoration of normal grooming activity. Rostral mandibulectomy could be considered for animals with trismus for other aetiologies such as masticatory myositis where other management options are not available.

Keywords: Trismus; rostral mandibulectomy; temporomandibular joint; masticatory myositis

Accepted: 4 January 2022

Introduction

An inability to open the mouth, also known as lockjaw or trismus, can be a devastating disease. If left untreated, patients will be unable to groom and consume adequate nutrition. The aetiology of trismus is variable and can include trauma (resulting in temporomandibular joint [TMJ] disease), end-stage masticatory muscle myositis (MMM) and trigeminal neuropathy. Treatment is dependent on the inciting cause. If the condition becomes irreversible, for example once masticatory muscle fibrosis has occurred, treatment options are limited.¹ Management options at this stage include either the provision of an alternative means of nutrition such as permanent enteral feeding tubes or muscle transection. However, the long-term prognosis is guarded and the majority of animals are euthanased. Here, we describe a novel treatment for trismus using a rostral mandibulectomy.

Case description

A 5-year-old male neutered domestic shorthair cat presented with a 1-month history of weight loss and an inability to groom or eat.

Two months previously the cat was involved in a suspected road traffic accident (RTA) resulting in a traumatic palatal separation. The hard palate was separated along the length of the palate, with communication

¹Langford Vets, Bristol Veterinary School, University of Bristol, Bristol, UK

²Eastcott Veterinary Hospital, Hindle Way, Swindon, UK

³Highcroft Veterinary Referrals, Witchurch, Bristol, UK

Corresponding author:

Kevin Parsons BVSc, PhD, DECVS, FHEA, MRCVS, Langford Vets, Bristol Veterinary School, University of Bristol, Stock Lane, Langford, Bristol BS40 5DU, UK
Email: kevin.parsons@bristol.ac.uk



Creative Commons Non Commercial CC BY-NC: This article is distributed under the terms of the Creative Commons

Attribution-NonCommercial 4.0 License (<https://creativecommons.org/licenses/by-nc/4.0/>) which permits non-commercial use, reproduction and distribution of the work without further permission provided the original work is attributed as specified on the SAGE and Open Access pages (<https://us.sagepub.com/en-us/nam/open-access-at-sage>).

between the nasopharynx and oropharynx visible, especially caudally, where there was 3 mm gap. There were multiple skull fractures, including marginally displaced fractures of the right nasal bone, nasal septum, orbits (bilaterally), a fracture of the right zygomatic arch, an oblique fracture of the left zygomatic arch with minimal displacement and a parasagittal fracture of the left mandible involving the root of the canine. The TMJs appeared normal. The patient was treated conservatively without any surgical intervention.

Four weeks after discharge the cat began to exhibit difficulty with grooming behaviour, followed by progressive difficulty with feeding.

On presentation, the cat was bright, alert and responsive, with a body weight of 4.9 kg and a body condition score (BCS) of 2/9. Body weight and BCS at the time of admission following the RTA were 6.4 kg and 5/9, respectively. The coat had an unkempt appearance, consistent with a lack of grooming. Physical examination revealed pale mucous membranes. Palpation revealed atrophy of the masseter and temporal muscles, particularly on the left, and an inability to open the mouth. When offered food the cat demonstrated a ravenous appetite and tried to ingest the meal; however, it was only able to protrude its tongue by a few millimetres, making food ingestion impossible.

Serum biochemistry revealed significantly elevated serum creatine kinase concentration (1830 IU/l; reference interval [RI] <150 IU/l) but was otherwise unremarkable. Complete blood cell count revealed a regenerative microcytic, hypochromic anaemia (haematocrit 12% [RI 25.0–45.0]; mean cell volume 36.4 fl [RI 40.0–55.0]; mean cell haemoglobin concentration [MCHC] 29.1 g/dl [RI 30.0–35.0]). Iron was low (7.2 $\mu\text{mol/l}$ [RI 12–39]) with low transferrin saturation (15.0% [RI >25]), consistent with chronic haemorrhage and iron-deficiency anaemia.

Oral examination was performed with the cat heavily sedated and revealed that with firm manual distraction

it was only possible to open the mouth by 4 mm. Multiple ulcerative lesions were identified associated with the tongue where they contacted the molar teeth.

Repeat CT revealed findings consistent with those reported previously; however, there was radiographic healing of the palate. There was a small amount of mineralisation associated with the left TMJ, with no other evidence of temporomandibular disease. Marked atrophy of the left masseter muscle was noted (Figure 1).

Electromyography (EMG) of both masseter muscles, performed under general anaesthesia, showed spontaneous electrical muscle activity (fibrillation potentials ++ and positive sharp waves ++), indicative of denervation or myopathy disease processes. No other EMG abnormalities were detected in other muscles of the head (Figure 2).

Biopsy of the temporalis muscles revealed a histological appearance consistent with myofibril degeneration.

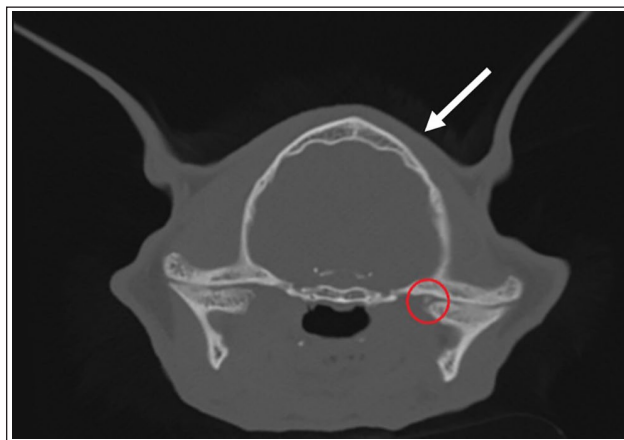


Figure 1 Transverse CT image of the head demonstrating a small amount of mineralisation associated with the left temporomandibular joint (red circle) with no other evidence of temporomandibular disease. There is marked atrophy of the left masseter muscle (white arrow)

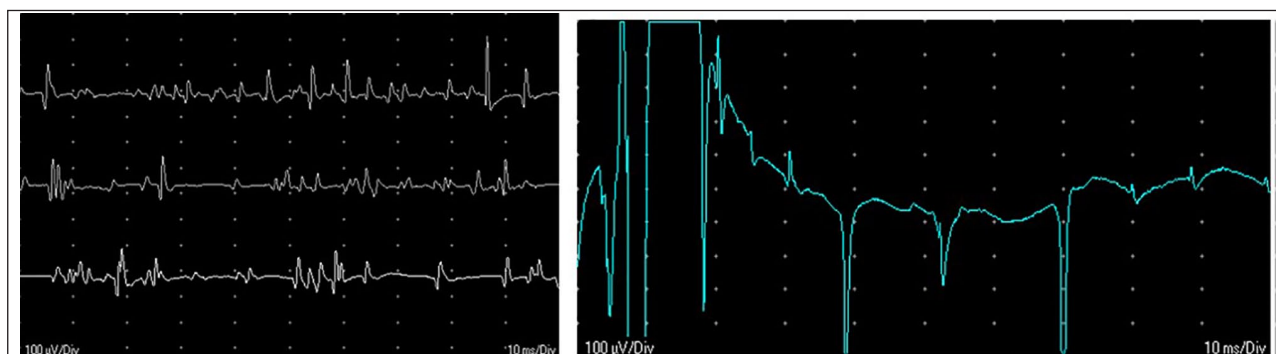


Figure 2 Electromyography (EMG) of both masseter muscles showed spontaneous electrical muscle activity (fibrillation potentials ++ and positive sharp waves ++), indicative of denervation or myopathy disease processes. No other EMG abnormalities were detected in other muscles of the head

There was no evidence of ongoing inflammation. Immunofluorescent antibody assays revealed an increased *Toxoplasma* IgG titre (400 [RI <50]), although *Toxoplasma* IgM antibody titre was within normal limits (<20 [RI <20]).

Attempts were made over the following 2 days to manually distract the mouth to increase aperture width with the cat sedated. This was unsuccessful. Therefore, the decision was made to perform a rostral mandibulectomy.

Preoperative haematology documented a moderate hypochromic microcytic regenerative anaemia with blood type AB. Cross-matching identified a suitable donor and 40 ml of fresh whole blood was administered. Packed cell volume increased from 12.2% to 23%.

The cat was premedicated with methadone (0.4 mg/kg IV), and anaesthesia was induced with propofol (6 mg/kg IV) and midazolam (0.4 mg/kg IV). Endotracheal intubation was achieved using endoscopic guidance. A rostral mandibulectomy was performed caudal to the mandibular canine teeth. The gingiva was sharply incised onto the underlying bone 0.5 cm rostral to the third premolar. The gingiva was elevated from the mandible and the oral mucosa was dissected off the mandible. The mandible was transected with an oscillating saw and the mandibular artery cauterised. The mucosa was apposed over the mandible using absorbable sutures (Polyglactin 910, USP 4/0). An oesophagostomy tube was then placed. Following surgery, the patient was administered 50 mg of iron dextran by deep intramuscular injection (CosmoFer; Pharmacosmos). A buster collar was applied.

The cat made an uneventful recovery from surgery and was administered analgesia (buprenorphine [Vetergesic; Ceva Animal Health]) and meloxicam (Metacam oral suspension for cats [Boehringer Ingelheim]). Nutrition was provided by the oesophagostomy postoperatively for 4 days. Soft food was offered on the third postoperative day (Hills a/d). The cat promptly started to eat without difficulty and the oesophagostomy tube was subsequently removed.

The cat was discharged 6 days postoperatively with a 3-day course of meloxicam and a 5-day course of cephalexin (75 mg q12h PO [Rilexine; Virbac]). Pâté-style food, along with mashed meat-and-jelly-based food, was recommended. Follow-up at 2 months revealed the patient's body weight and BCS had returned to that reported prior to the onset of clinical signs. Anaemia resolved following surgery, with haematocrit and MCHC returning to normal limits (haematocrit 29.3% [RI 25.0]; MCHC 33.2 g/dl [RI 30.0–35.0]).

Five months after rostral mandibulectomy, the patient re-presented owing to the development of sneezing and right-sided nasal discharge. Examination and repeat CT

revealed an oronasal fistula affecting the caudal hard palate to the right of the midline. A 30 mm silicone nasal septal button was used to obturate the oronasal fistula. The nasal portion of the button was trimmed to fit the right inferior nasal meatus and the oral side trimmed to fit the palate. The obturator was well tolerated and effective, producing a consequent reduction in sneezing and nasal discharge.

Follow-up at 2 months revealed that the nasal septum button was in place and there was no evidence of palatal inflammation. Clinical signs had improved considerably. There was some accumulation of calculus on the premolars with associated gingivitis. At the follow-up at 30 months after the rostral mandibulectomy, the owner reported that the cat had maintained body weight and BCS, and was continuing to eat a modified diet, as detailed earlier. The owner was very satisfied with the outcome.

Discussion

Trismus is an uncommon presenting condition in the cat, and is more commonly observed in the dog. A history of cranial fracture, as in this case, has been shown to be a common clinical feature of cats presenting with trismus. Trismus can have a severe impact on both longevity, if untreated, and quality of life, as it interferes with normal drinking, feeding and grooming behaviours.

Many different disease processes may be involved in the development of trismus, either centred on the individual components of the opening/closing mechanism of the mandible (eg, TMJ ankylosis, luxation of the TMJ and MMM), or acting elsewhere, such as disease of the central nervous system, retrobulbar abscesses and trigeminal nerve disorders.² Although the most common of these differential diagnoses is TMJ ankylosis, MMM is also a common cause of this presenting complaint. In this case, no evidence of inflammation was found on haematology or muscle biopsy, although MMM can present with no inflammatory infiltrate of the temporalis muscle on histopathological examination.^{3,4} Involvement of *Toxoplasma gondii* is also unlikely in this case: the elevated serum *Toxoplasma* IgG titre and normal IgM indicates historical infection, which is commonly observed in cats. Myositis can be a clinical sign associated with toxoplasmosis;⁵ however, no other clinical signs associated with toxoplasmosis were observed in this cat and so this diagnosis was not pursued.

Conditions, including head trauma, culminating in paralysis of the trigeminal nerve may cause atrophy of the muscles of mastication and trismus,^{2,6,7} although it should be noted that they may also prevent closing of the mouth by inhibiting the contraction of masticatory muscles.^{8,9} With trigeminal neuropathies, masticatory muscle atrophy is typically unilateral. In this case, on CT,

the muscle atrophy was more marked on the left side. Trigeminal disease was therefore a possibility. EMG findings from this patient were compatible with denervation (lesion of the motor components of the trigeminal nerve) or myopathy. The presence of the palpebral and corneal reflexes in this patient indicated that the sensory branch of the trigeminal nerve was intact and that therefore the motor branches were affected outside the skull

The exact underlying aetiology of trismus is uncertain in this case, but was likely a result of trauma experienced during the RTA the patient was involved in. The CT changes in the TMJ did not appear significant and could not account for the muscle pathology on EMG and histological findings. For this reason, excision arthroplasty of the TMJ was not recommended, as persistence of the trismus would be expected.

In the case described in this report the left and right temporalis muscles were biopsied, owing to the superficial location and ease of access. It would have been interesting to biopsy the masseter muscle in this case; however, owing to the degree of atrophy, we were concerned the histopathology would demonstrate end-stage muscle changes rather than active inflammatory disease. A further option would have been to perform a 2M antibody titre. Owing to the degree of trismus and the marked atrophy of the masseter muscle in this case, we decided not to perform a 2M antibody titre as it was felt the results would not change the treatment options and outcome, and the costs associated with the test were therefore not warranted.

The use of rostral mandibulectomy to treat trismus is a novel and unconventional use of this surgical procedure which, to our knowledge, is unreported in the veterinary literature. A previous incident of severe trismus was observed in a 2-year-old Pug undergoing general anaesthesia for investigation of MMM in which the patient required emergency treatment to return the tongue to the mouth due to dyspnoea and damage to the tongue. Although rostral mandibulectomy was considered, mandibular symphysiotomy was successful and conventional immunosuppressive treatment resolved the trismus.¹⁰

An alternative option for management in this case would have been the placement of a permanent feeding tube. This option is not without risks and requires significant lifestyle changes (for both the owner and the cat), does not return the ability to express natural feeding and grooming behaviours, and may result in continued trauma to the tongue with ongoing haemorrhage and iron deficiency. Further complications of permanent feeding tubes include stoma site discharge and infection, vomiting, tube removal by patient and aspiration pneumonia.¹¹ While owner compliance and satisfaction with, and patient tolerance for, tube feeding are often very good, non-compliance by the patient and owner is always possible.

It is likely that the oronasal fistula occurred because of abrasion to the palatal mucosa associated with increased contact between the tongue and palate over unsupported palatal mucosa due to the underlying defect in the palatal bone, secondary to the initial head trauma. Surgical access was difficult because of the position of the fistula and limited jaw opening. The risk of failure of a surgical repair was considered to be high because wound dehiscence following repair of acquired palatal defects is the most common complication,¹² and the underlying cause of the original fistula (increased abrasion of unsupported mucosa) would still be present; therefore, the alternative of using a palatal obturator was considered. Palatal obturators are often used as temporary solutions to palatal clefts and fistulas. Silicone obturators have been designed for the repair of nasal septal perforations in people, and one has been used successfully for long-term management of a large oronasal fistula in a cat.¹³

Conclusions

Given the positive outcome, high level of owner satisfaction and postoperative quality of life for the patient in this case, rostral mandibulectomy offers a novel method for managing trismus.

Conflict of interest The authors declared no potential conflicts of interest with respect to the research, authorship, and/or publication of this article.

Funding The authors received no financial support for the research, authorship, and/or publication of this article.

Ethical approval The work described in this manuscript involved the use of non-experimental (owned or unowned) animals. Established internationally recognised high standards ('best practice') of veterinary clinical care for the individual patient were always followed and/or this work involved the use of cadavers. Ethical approval from a committee was therefore not specifically required for publication in *JFMS Open Reports*.

Informed consent Informed consent (verbal or written) was obtained from the owner or legal custodian of all animal(s) described in this work (experimental or non-experimental animals, including cadavers) for all procedure(s) undertaken (prospective or retrospective studies). No animals or people are identifiable within this publication, and therefore additional informed consent for publication was not required.

ORCID iD Sorrel Langley-Hobbs  <https://orcid.org/0000-0003-4397-5150>

References

- 1 Nutt AE, Anderson T, Gracis M, et al. **Open-mouth jaw locking in cats: a literature review and use of computed tomography in three cases.** *J Feline Med Surg* 2018; 12: 1180–1191.

- 2 Gatineau M, El-Warrak AO, Marretta SM, et al. **Locked jaw syndrome in dogs and cats: 37 cases (1998–2005).** *J Vet Dent* 2008; 25: 16–22.
- 3 Gilmour MA, Morgan RV and Moore FM. **Masticatory myopathy in the dog: a retrospective study of 18 cases.** *J Am Anim Hosp Assoc* 1993; 28: 300–306.
- 4 Melmed C, Shelton GD, Bergman R, et al. **Masticatory muscle myositis: pathogenesis, diagnosis, and treatment.** *Compendium* 2004; 8: 590–605.
- 5 Troxel MT. **Infectious neuromuscular diseases of dogs and cats.** *Top Comp Anim Med* 2009; 24: 209–220.
- 6 Panciera RJ, Ritchey JW, Baker JE, et al. **Trigeminal and polyradiculoneuritis in a dog presenting with masticatory muscle atrophy and Horner's syndrome.** *Vet Pathol* 2002; 39: 146–149.
- 7 Palmer AC. **Pontine infarction in a dog with unilateral involvement of the trigeminal motor nucleus and pyramidal tract.** *J Small Anim Pract* 2007; 48: 49–52.
- 8 Mayhew PD, Bush WW and Glass EN. **Trigeminal neuropathy in dogs: a retrospective study of 29 cases (1991–2000).** *J Am Anim Hosp Assoc* 2002; 38: 262–270.
- 9 Robins GM. **Dropped jaw-mandibular neurapraxia in the dog.** *J Small Anim Pract* 1976; 17: 753–758.
- 10 Nanai B, Phillips L, Christiansen J, et al. **Life threatening complication associated with anesthesia in a dog with masticatory muscle myositis.** *Vet Surg* 2009; 38: 645–649.
- 11 Yoshimoto SK, Marks SL, Struble AL, et al. **Owner experiences and complications with home use of a replacement low profile gastrostomy device for long-term enteral feeding in dogs.** *Can Vet J* 2006; 47: 144–150.
- 12 Marretta SM. **Repair of acquired palatal defects.** In: Verstraete FJM and Lommer M (eds). *Oral and maxillofacial surgery in dogs and cats.* St Louis, MO: Elsevier Health Sciences, 2012, p 363.
- 13 De Souza HJM, Amorim FV, Corgozinho KB, et al. **Management of the traumatic oronasal fistula in the cat with a conical silastic prosthetic device.** *J Feline Med Surg* 2005; 7: 129–133.