



## **Coxofemoral luxation as a complication of localised tetanus in a cat**

Authors: Danciu, Cecilia-Gabriella, Milgram, Joshua, Ober, Ciprian Andrei, Tăbăran, Flaviu Alexandru, Demény, Helga, et al.

Source: Journal of Feline Medicine and Surgery Open Reports, 8(1)

Published By: SAGE Publishing

URL: <https://doi.org/10.1177/20551169221090889>

---

BioOne Complete ([complete.BioOne.org](https://complete.BioOne.org)) is a full-text database of 200 subscribed and open-access titles in the biological, ecological, and environmental sciences published by nonprofit societies, associations, museums, institutions, and presses.

Your use of this PDF, the BioOne Complete website, and all posted and associated content indicates your acceptance of BioOne's Terms of Use, available at [www.bioone.org/terms-of-use](https://www.bioone.org/terms-of-use).

Usage of BioOne Complete content is strictly limited to personal, educational, and non - commercial use. Commercial inquiries or rights and permissions requests should be directed to the individual publisher as copyright holder.

---

BioOne sees sustainable scholarly publishing as an inherently collaborative enterprise connecting authors, nonprofit publishers, academic institutions, research libraries, and research funders in the common goal of maximizing access to critical research.



# Coxofemoral luxation as a complication of localised tetanus in a cat

Cecilia-Gabriella Danciu<sup>1,2</sup> , Joshua Milgram<sup>3</sup> ,  
Ciprian Andrei Ober<sup>2</sup>, Flaviu Alexandru Tăbăran<sup>2</sup>,  
Helga Demény<sup>2</sup> and Orit Chai<sup>4</sup>

*Journal of Feline Medicine and Surgery Open Reports*  
1–6

© The Author(s) 2022

Article reuse guidelines:

sagepub.com/journals-permissions

DOI: 10.1177/20551169221090889

journals.sagepub.com/home/jfmsopenreports

This paper was handled and processed by the European Editorial Office (ISFM) for publication in *JFMS Open Reports*



## Abstract

**Case summary** A 9-month-old male neutered domestic shorthair cat presented 2 weeks after castration with a 48 h history of acute-onset lateral recumbency and severe hindlimb rigidity. Physical examination findings included hyperthermia, tachypnoea, hindlimb rigidity and a healed orchidectomy site. Neurological examination of the head and forelimbs was normal; however, there was a spastic, non-ambulatory paraparesis of the hindlimbs, which was more severe on the left. Abnormal findings included mildly elevated serum creatine kinase levels and on electromyography there was bilateral pathological spontaneous activity of the biceps femoris muscles. A tentative diagnosis of tetanus was made based on clinical presentation. Treatment was initiated with tetanus antitoxin, diazepam, metronidazole, buprenorphine and physiotherapy of the hindlimbs. There was an improvement over the following 20 days. Twenty-five days later the cat presented with acute, painful, non-weightbearing lameness of the left hindlimb. Physical examination was suggestive of craniodorsal coxofemoral joint luxation, which was confirmed radiographically. This was treated with analgesia and rest. A marked clinical improvement was observed at the 3-month follow-up.

**Relevance and novel information** To our knowledge, there have been no previously published reports of spontaneous coxofemoral joint luxation as a complication of hindlimb localised tetanus infection in cats. This report suggests that coxofemoral luxation should be considered as a possible complication in young cats with hindlimb localised tetanus.

**Keywords:** Tetanus infection; castration; hip joint luxation

**Accepted:** 1 March 2022

## Introduction

Tetanus is a neurological disease caused by *Clostridium tetani*, which affects humans, domestic animals and birds.<sup>1,2</sup> *Clostridium tetani* is a motile, Gram-negative, obligate anaerobic, non-encapsulated, spore-forming bacillus. Tetanus spores are found worldwide in the environment, mainly in the soil.<sup>3</sup> Spores generally enter through a break in the skin and convert into the vegetative exotoxin-producing form (tetanospasmin) in an anaerobic environment.<sup>1,3</sup> The toxin, tetanospasmin, enters axons in close proximity at the neuromuscular endplate and reaches the central nervous system (CNS) by retrograde axonal transport. In the CNS, the tetanospasmin blocks the release of gamma-aminobutyric acid

<sup>1</sup>Department of Veterinary Clinical Science and Services, Royal Veterinary College, University of London, Hatfield, UK

<sup>2</sup>Department of Veterinary Preclinical and Clinical Sciences, University of Agricultural Sciences and Veterinary Medicine, Cluj-Napoca, Romania

<sup>3</sup>Department of Small Animal Surgery, The Koret School of Veterinary Medicine, Rehovot, Israel

<sup>4</sup>Department of Veterinary Neurology and Neurosurgery, The Koret School of Veterinary Medicine, Rehovot, Israel

### Corresponding author:

Cecilia-Gabriella Danciu DVM, Department of Veterinary Clinical Science and Services, Royal Veterinary College, University of London, Hawkshead Ln, Brookmans Park, Hatfield AL9 7TA, UK

Email: cecilia\_danciu@yahoo.com



Creative Commons Non Commercial CC BY-NC: This article is distributed under the terms of the Creative Commons

Attribution-NonCommercial 4.0 License (<https://creativecommons.org/licenses/by-nc/4.0/>) which permits non-commercial use, reproduction and distribution of the work without further permission provided the original work is attributed as specified on the SAGE and Open Access pages (<https://us.sagepub.com/en-us/nam/open-access-at-sage>).

(GABA) and glycine from CNS inhibitory interneurons,<sup>4,5</sup> leading to muscle spasm within the affected motor unit.<sup>3</sup>

Following infection, clinical signs typically occur within 3–18 days.<sup>6</sup> Cats have an innate resistance to tetanospasmin and are up to 7500 times less susceptible to the development of clinical illness than horses. Therefore, the onset of disease in cats may be delayed for several weeks and they are more likely to develop the localised rather than the generalised form of tetanus.<sup>3,7,8</sup>

Localised tetanus in cats has been reported to affect the thoracic limbs, paraspinous musculature<sup>7,9–11</sup> and hindlimbs, the last being associated most commonly with postoperative complications of ovariohysterectomy.<sup>11</sup> The diagnosis of tetanus is based on history and clinical signs, and can be supported by electromyography (EMG) of affected muscles.<sup>3</sup> Tetanus infection-related complications have been reported in both dogs and cats, and include aspiration pneumonia, laryngeal spasm, ventricular tachycardia and third-degree atrioventricular block,<sup>12</sup> hiatal hernia and megaesophagus.<sup>13–15</sup> Limb fractures and coxofemoral luxation have been previously reported in people and dogs.<sup>16–18</sup>

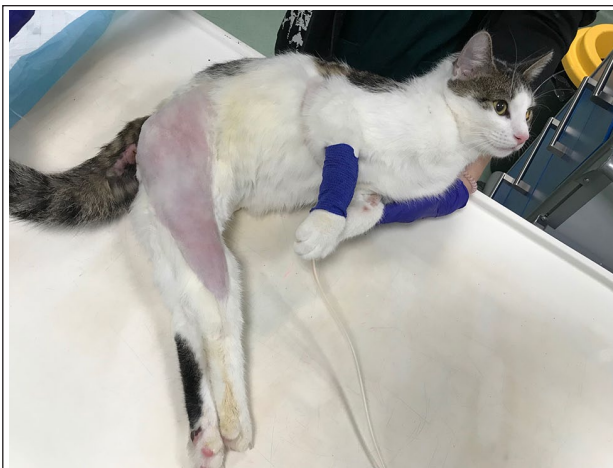This report describes the clinical course of localised tetanus in a cat that was complicated by spontaneous coxofemoral joint luxation. There have, to our knowledge, been no previous published reports of spontaneous coxofemoral luxation associated with *C tetani* infection in cats.

## Case description

A 9-month-old castrated male domestic shorthair cat weighing 4 kg was presented to the Veterinary Emergency Service of the Faculty of Veterinary Medicine Cluj-Napoca, Romania, with a 2-day history of lateral recumbency and severe rigidity of the hindlimbs (Figure 1). The cat had been castrated 2 weeks prior to presentation and showed no signs of lameness or paresis prior to the current episode.

On general physical examination, severe rigidity of the hindlimbs, hyperthermia (39.7°C), an increased respiratory rate (68 breaths/min) with no effort and no adventitious lung sounds were detected. The orchidectomy site was healed completely. The bladder was small on palpation and the cat had been urinating voluntarily. Neurological examination showed alert mental status and cranial nerve examination was unremarkable. Evaluation of gait revealed spastic, non-ambulatory paraparesis, which was more severe on the left hindlimb, while the head, neck, thoracic limbs and tail had appropriate tone. Evaluation of the thoracic limbs revealed unremarkable gait, postural reactions and spinal reflexes. Evaluation of postural reactions and spinal reflexes were not possible owing to excessive rigidity of the hindlimbs.

A complete blood count (CBC) and serum biochemistry were done. The CBC was unremarkable. Serum

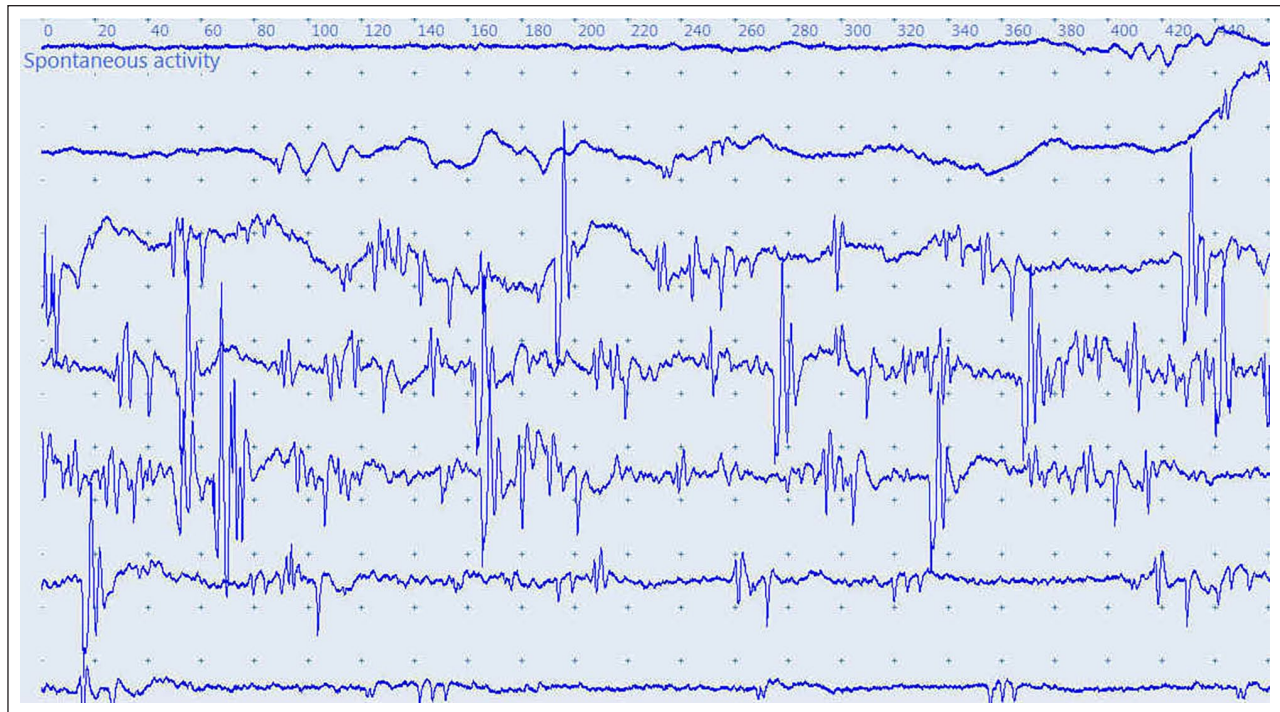


**Figure 1** Nine-month-old castrated male domestic shorthair cat on initial presentation with spastic, non-ambulatory paraparesis

biochemistry revealed a mildly elevated creatine kinase (374 IU/l; reference interval 30–100). Radiographic examination of thoracolumbar spinal column and pelvis did not demonstrate any abnormalities. Bilateral EMG of the biceps femoris and triceps brachii muscles was performed under general anaesthesia. Pathological spontaneous activity with positive sharp waves, fibrillation potentials and occasional motor unit action potentials were observed bilaterally in the biceps femoris muscles (Figure 2). Triceps brachii muscles remained electrically silent. Histological evaluation of muscle biopsy from the biceps femoris was unremarkable. A diagnosis of localised tetanus secondary to the surgical castration was made based on history, clinical findings and EMG results.

Treatment included exploration and debridement of the orchidectomy site, subcutaneous injection of 300 U/kg equine tetanus antitoxin (Ser Colestetan; Bioveta) followed by 700 U/kg equine tetanus antitoxin intravenously (IV) after monitoring for an anaphylactic reaction. Diazepam (0.2 mg/kg IV q6h [Diazepam; Terapia]) was administered as a muscle relaxant for 3 days. Metronidazole (10 mg/kg IV q12h [Metronidazole; B Braun]) was administered for 7 days, and analgesia was provided by buprenorphine (Buprecare; Animalcare) at an initial dose of 0.03 mg/kg IV q6h tapered to 0.02 mg/kg IV q6h for 4 days. Physiotherapy was started with twice-daily gentle massage for 2–3 mins, and repetitive gentle passive range of motion of the hindlimb joints for 15 mins. The cat was hospitalised on padded bedding in a quiet environment and was evaluated daily.

Twenty days after the initiation of treatment there was a marked reduction in the spasticity the right hindlimb while the left hindlimb showed mild improvement. Fourteen days later, the cat was ambulatory. The right



**Figure 2** Electromyography characteristics of persistent spontaneous activity of the biceps femoris muscle. Spontaneous activity with positive sharp waves, fibrillation potentials and motor unit action potentials of 12–15 ms were occasionally observed

hindlimb regained normal function; however, only a moderate improvement was noticed in the left hindlimb. There was a marked atrophy of the left quadriceps muscle, which had become contracted, resulting in hyperextension of the stifle. The cat was discharged and physiotherapy comprising massage and gentle passive range of motion exercises were recommended 2–3 times per week.

Eleven days after discharge the cat presented with acute non-weightbearing left hindlimb lameness; the stifle was moderately extended and the limb was slightly shorter than its counterpart. Physical examination of the right hindlimb was unremarkable; however, the left coxofemoral joint showed a decreased range of motion and was painful on manipulation. In addition, dorsal iliac spine, greater trochanter and tuber ischii were on the same line. The suspected diagnosis of left craniodorsal coxofemoral joint luxation was confirmed radiographically (Figure 3). Closed or open reduction was refused by the owners owing to financial concerns; thus, the coxofemoral luxation was left untreated. The cat was managed with 3 weeks of cage restriction and analgesia consisting of tramadol (2 mg/kg PO q8h [Tramadol; KRKA]) for 5 days and robenacoxib (1 mg/kg PO q24h [Onsior; Novartis]) for 2 days.

Three months after diagnosis of the coxofemoral luxation, the cat was ambulatory with a mild weightbearing lameness and mildly extended stifle of the left hindlimb.

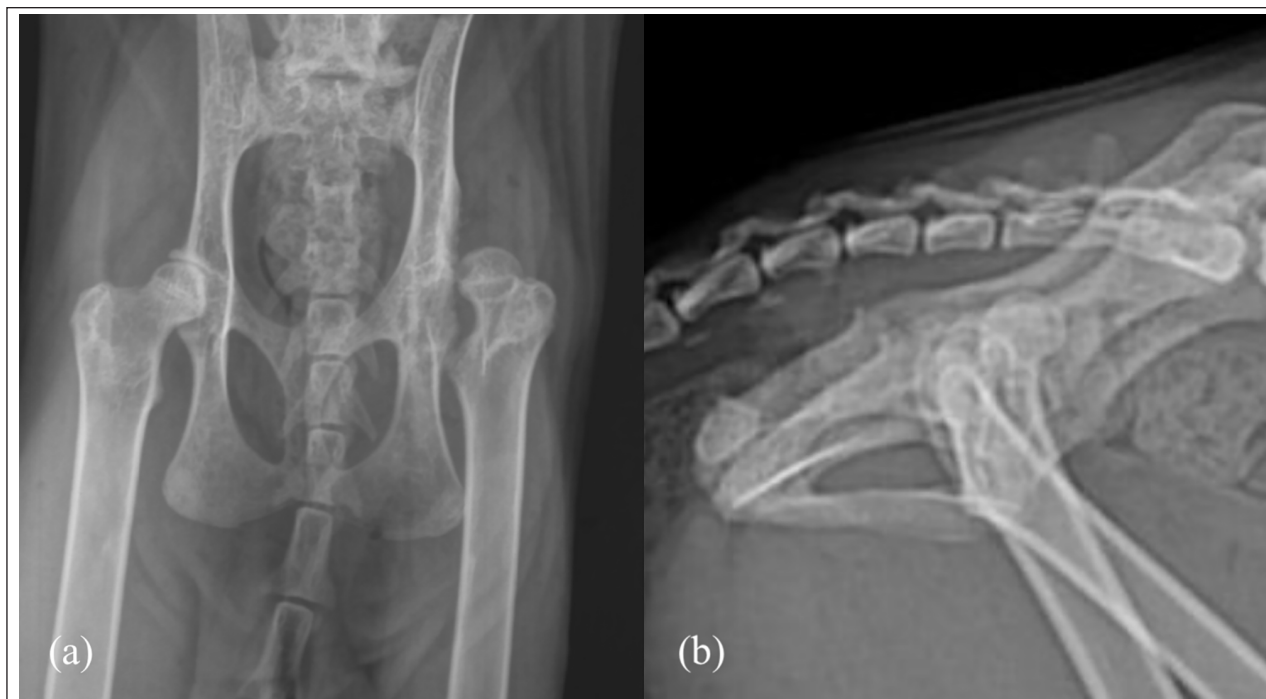
No muscle rigidity was observed on palpation of the left hindlimb; however, the left quadriceps muscle was moderately atrophied and the flexion of the stifle was moderately reduced. The range of motion was mildly reduced in extension of the coxofemoral joint but was not associated with pain or discomfort.

## Discussion

Clinically, in tetanus, increased rigidity of a muscle or an entire limb is first observed close to a wound.<sup>3</sup> The rigidity can gradually spread to the opposite limb and/or paraspinal musculature,<sup>10</sup> and eventually involve the entire body.<sup>10,19</sup> Tetanus affecting pelvic limbs in cats has been previously associated with ovariohysterectomy.<sup>11</sup>

Diagnosis of tetanus in cats is challenging, as owing to their innate resistance, they develop the localised rather than the generalised form.<sup>3,7,8</sup> In the present case, based on the severe hindlimb rigidity, hyperthermia, mildly elevated creatinine kinase and the recent history of surgical castration, a diagnosis of tetanus was deemed most likely.<sup>11</sup> The clinical diagnosis of tetanus was confirmed via EMG. Other differential diagnoses, including ischaemic neuromyopathy and myositis, were excluded by unremarkable cardiac auscultation, palpable peripheral pulses<sup>20,21</sup> and muscle biopsy. Hyperthermia is a common complication of constant muscle contraction.<sup>3</sup> Temperature normalised once treatment was initiated. Muscle enzyme elevation occurred as a result of the injury





**Figure 3** (a) Ventrodorsal radiograph showing craniodorsal luxation of the left coxofemoral joint, and (b) lateral radiograph showing craniodorsal luxation of the left coxofemoral joint

arising from the sustained rigidity of hindlimbs and recumbency.<sup>3</sup> EMG of the affected pelvic limb muscles displayed pathological spontaneous activity with positive sharp waves, fibrillation potentials and occasional motor unit action potentials.<sup>3,9,11,22–24</sup> These electrical findings are typical and are the result of spontaneous firing of hyperactive and disinhibited motor neurons under the influence of tetanospasmin.<sup>7,8,22,24</sup> Previously, isolation of *C tetani* with additional determination from antibody titres was used for the definitive diagnosis.<sup>24</sup> However, isolation was unrewarding owing to the very low concentration of the organism in wounds.<sup>3,24</sup> Additionally, serum values must be compared with control animals for interpretation,<sup>3</sup> which was not performed in the present case.<sup>7</sup>

Treatment of tetanus is complex and involves antitoxin administration, antimicrobial therapy, muscle relaxation and nursing care.<sup>7–12</sup> The administration of antitoxin aims to neutralise the circulating tetanospasmin that has not bound to the CNS or has not formed yet.<sup>3,22</sup> Arguably, tetanus antitoxin may not be necessary in cats with a localised form, given their innate resistance, or in chronic cases,<sup>3,7,11,22</sup> and, in this case, because surgical castration had been performed 14 days prior to presentation. However, as the cat was showing clinical manifestation of tetanus, the decision was made to administer equine antitoxin to neutralise the potentially unbound tetanospasmin to the CNS.<sup>3,10</sup> There is evidence that therapeutic blood concentrations of the antitoxin persist for 14 days

following administration in dogs.<sup>3</sup> In our case, an initial dose of 300 U/kg was administered subcutaneously.<sup>3</sup> As no anaphylactic reaction was observed, this was followed by a 700 U/kg dose IV.<sup>3</sup>

Antimicrobial therapy was initiated with metronidazole, as it has better penetration, even in anaerobic tissues.<sup>3</sup> While penicillin G was previously considered the drug of choice, metronidazole has recently proved to be superior in clinical and experimental cases of tetanus.<sup>25</sup> Additionally, penicillin G has GABA antagonistic properties and may potentiate the effect of tetanospasmin.<sup>3</sup>

Diazepam has been used as a potent skeletal muscle relaxant in tetanus treatment in cats.<sup>7,10,11,22</sup> Diazepam enhances the activity of GABA at the receptor site in the CNS, which leads to presynaptic inhibition in the spinal cord and subsequent decrease of skeletal muscle tone. This resulted relaxation helps in moving the joints and muscles in the recovery period.<sup>11,26</sup> Methocarbamol and dantrolene have been administered in a limited number of small animal cases, where their usefulness has been debated.<sup>11,15</sup> These treatments were not available and so diazepam therapy was instigated in this case.

Vertebral and femoral neck fractures and coxofemoral luxations have been reported as complications associated with tetanus in people and dogs.<sup>16,18,27–29</sup> This is the first report of joint luxation following tetanus infection in a cat. Joint luxation should be considered a potential complication of *C tetani* infection in cats with prolonged muscle contraction.

It is hypothesised that the force generated by the severe muscle spasm in both the rectus femoris and biceps femoris muscles during the disease process was sufficient to rupture the round ligament and joint capsule causing luxation of the hip joint. The rectus femoris muscle originates cranial to the acetabulum,<sup>30</sup> and increased force in this muscle due to the muscle spasm likely caused dorsal displacement of the femoral head. Similarly, the biceps femoris muscle also originates on the pelvis,<sup>30</sup> and spasm of this muscle would have a similar effect on the femoral head. The prolonged course would indicate that the soft tissues were gradually stretched until they failed, resulting in luxation. Previously, it has been reported in both people and dogs that prolonged muscle spasm caused by tetanus infection can cause spontaneous fractures or joint luxation.<sup>18,27–29</sup>

Another possibility for the coxofemoral luxation was the contracture of the quadriceps femoris muscle observed in the left hindlimb. It has been previously reported that femoral fracture repair in dogs treated with immobilisation led to quadriceps contracture.<sup>31</sup> Additionally, spontaneous coxofemoral luxation was reported as a sequel of prolonged immobilisation of the stifle in young rabbits.<sup>32</sup> Histological evaluation of the contracted quadriceps muscles showed irreversible adhesions and type I fibre atrophy.<sup>31</sup> The pathomechanism behind it was explained by the muscle changes<sup>31</sup> and prolonged tension of the hamstring muscles keeping the stifle in extension, and potentially causing the luxation of the coxofemoral joint.<sup>32</sup> Also, in our case, quadriceps contracture was observed following a prolonged period of muscle contracture and extended stifle due to *C tetani* infection.

The cat in this report was undergoing physiotherapy, which consisted of passive flexion and extension exercises.<sup>16,22,33,34</sup> It is feasible that overaggressive manipulation could have led to dislocation. However, the worsening of the lameness and diagnosis of coxofemoral luxation occurred 2 days after any manipulation, deeming it an unlikely cause.

In this report the coxofemoral luxation was not reduced by closed or open techniques, which provide better long-term outcome. However, cats can achieve a high level of function with a luxated joint. A pseudoarthrosis develops between the luxated femoral head and the caudal portion of the ilium, which allows pain-free movement,<sup>35,36</sup> as was seen in this case. At the 3-month follow-up, no pain or discomfort was noted, but the range of motion was slightly reduced in the left hindlimb.

It was speculated that contamination of the orchidectomy site was the cause of infection. Orchidectomy was performed 2 weeks prior to the onset of clinical signs, which is consistent with the reported incubation period.<sup>3</sup> There are no previous reports of tetanus infection

following orchidectomy in cats. However, it is a recognised complication of this surgery in horses.<sup>37</sup>

In our case, improvement of clinical signs was noted after 20 days and the cat made a complete recovery after 3 months. This prolonged period of time for full recovery was previously reported to be variable, ranging from 3 weeks up to 5 months.<sup>7,9,10,11,22</sup> Therefore, it is best to inform owners about the possibility of prolonged time for full recovery.

## Conclusions

To our knowledge, this is the first reported case of localised tetanus in a cat post-orchidectomy, as well as the first of coxofemoral luxation. This case highlights that tetanus can appear in cats not only after female reproductive tract surgery, but also after castration. Additionally, this case highlights that luxation can appear as a possible complication following tetanus infection in cats.

**Acknowledgements** The authors wish to acknowledge Dr Bogdan Florea for the outstanding electrodiagnostic support, as well as Adrien Albiger, Maria Vilcu, Octavia Tamas-Krumpe, Robert Purdoiu and Călin Repciuc for their time and effort put into caring for this cat.


**Conflict of interest** The authors received no financial support for the research, authorship, and/or publication of this article.

**Funding** The publication was supported by funds from the National Research Development Projects to finance excellence (PFE)-14 (ID 546) granted by the Romanian Ministry of Research, Innovation and Digitalization.

**Ethical approval** The work described in this manuscript involved the use of non-experimental (owned or unowned) animals. Established internationally recognised high standards ('best practice') of veterinary clinical care for the individual patient were always followed and/or this work involved the use of cadavers. Ethical approval from a committee was therefore not specifically required for publication in *JFMS*. Although not required, where ethical approval was still obtained, it is stated in the manuscript.

**Informed consent** Informed consent (verbal or written) was obtained from the owner or legal custodian of all animal(s) described in this work (experimental or non-experimental animals, including cadavers) for all procedure(s) undertaken (prospective or retrospective studies). For any animals or people individually identifiable within this publication, informed consent (verbal or written) for their use in the publication was obtained from the people involved.

**ORCID iD** Cecilia-Gabriella Danciu  <https://orcid.org/0000-0003-1394-920X>

Joshua Milgram  <https://orcid.org/0000-0002-5949-5939>

## References

- 1 Braund KG. **Tetanus**. In: Braund KG (ed). *Clinical syndromes in veterinary neurology*. 2nd ed. St Louis, MO: Mosby-Wolfe, 1994, pp 271–272.
- 2 Davenport DJ. **Bacterial and rickettsial diseases**. In: Sherding RG (ed). *The cat: diseases and clinical management*. 2nd ed. Churchill Livingstone: New York, 1994, pp 531–532 .
- 3 Greene CE. **Tetanus**. In: Greene CE (ed). *Infectious diseases of the dog and cat*. 3rd ed. St Louis, MO: Elsevier Saunders, 2006, pp 395–402.
- 4 Brooks VB, Curtis DR and Eccles JC. **The action of tetanus toxin on the inhibition of motoneurons**. *J Physiol* 1957; 135: 655–672.
- 5 Sanford JP. **Tetanus – forgotten but not gone**. *N Engl J Med* 1995; 332: 812–813.
- 6 Bandt C, Rozanski EA, Steinberg T, et al. **Retrospective study of tetanus in 20 dogs: 1988–2004**. *J Am Anim Hosp Assoc* 2007; 43: 143–148.
- 7 Malik R, Church DB, Maddison JE, et al. **Three cases of local tetanus**. *Vet Rec* 1989; 30: 469–473.
- 8 Jain S, Ashok PP and Maheshwari MC. **Local tetanus: a case report with electrophysiological studies**. *J Neurol* 1982; 228: 289–293.
- 9 Langner KF, Schenk HC, Leithaeuser C, et al. **Localised tetanus in a cat**. *Vet Rec* 2011; 169: 126.
- 10 De Risio L and Gelati A. **Tetanus in the cat – an unusual presentation**. *J Feline Med Surg* 2003; 5: 237–240.
- 11 Lee EA and Jones BR. **Localised tetanus in two cats after ovariohysterectomy**. *N Z Vet J* 1996; 44: 105–108.
- 12 Bandt C, Steinberg T and Shaw SP. **Clostridium tetanus infection in 13 dogs and one cat** [abstract]. *J Vet Emerg Crit Care* 2004; 14. DOI: 10.1186/2046-0481-57-10-593.
- 13 Van Bree H. **Esophageal hiatal hernia and eventration of the diaphragm as a complication in tetanus in three dogs**. *Vet Radiol* 1982; 23: 83.
- 14 Dieringer TM and Wolf AM. **Esophageal hiatal hernia and megaesophagus complicating tetanus in two dogs**. *J Am Vet Med Assoc* 1991; 199: 87–89.
- 15 Burkitt JM, Sturges BK, Jandrey KE, et al. **Risk factors associated with outcome in dogs with tetanus: 38 cases (1987–2005)**. *J Am Vet Med Assoc* 2007; 230: 76–83.
- 16 Goldhammer MA, Chapman PS and Grierson JM. **Coxofemoral luxation in a border collie as a complication of a Clostridium tetani infection**. *J Small Anim Pract* 2008; 49: 159–162.
- 17 Thachil RT, Philip B and Sridhar CB. **Temporomandibular dislocation: a complication of tetanus**. *J Trop Med Hyg* 1993; 96: 60–61.
- 18 Kalideen JM and Satyapal KS. **Fractures of the acromion in tetanus neonatorum**. *Clin Radiol* 1994; 49: 563–565.
- 19 Linnenbrink T and McMichael M. **Tetanus: pathophysiology, clinical signs, diagnosis, and update on new treatment modalities**. *J Vet Emerg Crit Care* 2006; 16: 199–207.
- 20 Gradner GM, Dogman-Rauberger L and Dupré G. **‘Bottom-hung window’ trauma in cats: neurological evaluation and outcome in 71 cats with bilateral hindlimb injury**. *Vet Rec Open* 2017; 29: e000175. DOI: 10.1136/vetreco-2016-000175.
- 21 Hogan DF. **Feline cardiogenic arterial thromboembolism: prevention and therapy**. *Vet Clin North Am Small Anim Pract* 2017; 47: 1065–1082.
- 22 Polizopoulou ZS, Kazakos G, Georgiadis G, et al. **Presumed localized tetanus in two cats**. *J Feline Med Surg* 2002; 4: 209–212.
- 23 Steinegger T, Wiederkehr M, Ludin HP, et al. **Electromyography as a diagnostic aid in tetanus** [article in German]. *Schweiz Med Wochenschr* 1996; 126: 379–385.
- 24 Tomek A, Kathmann I, Faissler D, et al. **Tetanus in cats: 3 case descriptions** [article in German]. *Schweiz Arch Tierheilkd* 2004; 146: 295–302.
- 25 Ahmadsyah I and Salim A. **Treatment of tetanus: an open study to compare the efficacy of procaine penicillin and metronidazole**. *Br Med J* 1985; 291: 648–650.
- 26 Davidoff RA. **Antispasticity drugs: mechanisms of action**. *Ann Neurol* 1985; 17: 107–116.
- 27 Adamantos S and Boag A. **Thirteen cases of tetanus in dogs**. *Vet Rec* 2007; 161: 298–302.
- 28 Bohrer SP. **Spinal fractures in tetanus**. *Radiology* 1965; 85: 1111–1116.
- 29 Schweitzer G and Naidoo KS. **Fracture of the femoral neck in a patient suffering from tetanus**. *S Afr Med J* 1972; 46: 503–504.
- 30 Hermanson JW. **The muscular system**. In: Evans EH and de Lahunta A (eds). *Miller’s anatomy of the dog*. 4th ed. St Louis, MO: Elsevier, 2013, pp 260–267.
- 31 Braund KJ, Shires PK and Mikeal RL. **Type I fiber atrophy in the vastus lateralis in dogs with femoral fractures treated by hyperextension**. *Vet Pathol* 1980; 17: 166–177.
- 32 Michelson JE and Langenskiold A. **Dislocation or subluxation of the hip. Regular sequels of immobilization of the knee in extension in young rabbits**. *J Bone Joint Surg* 1972; 54: 1177–1186.
- 33 Price H. **Feline physiotherapy: part 2**. *Companion Anim* 2014; 19: 474–478.
- 34 Mykkänen AK, Hyytiäinen HK and McGowan CM. **Generalised tetanus in a 2-week-old foal: use of physiotherapy to aid recovery**. *Aust Vet J* 2011; 89: 447–451.
- 35 Schrader SC. **Orthopedic surgery**. In: Sherding RG (ed). *The cat – diseases and clinical management*. 2nd ed. New York: Churchill Livingstone, 1994, pp 1649–1709.
- 36 Ablin LW and Gambardella PC. **Orthopedics of the feline hip**. *Compend Contin Educ Pract Vet* 1991; 13: 1379–1387.
- 37 Railton D. **Complications associated with castration in the horse**. *In Pract* 1999; 21: 298–307.