



## **Ultrasonographic and colour Doppler features of intrapancreatic splenic tissue in a cat**

Authors: Peschard, Anne-Lorraine, Jamont, Wiktoria, Shields, Claire, and Cronin, Anna

Source: Journal of Feline Medicine and Surgery Open Reports, 8(2)

Published By: SAGE Publishing

URL: <https://doi.org/10.1177/20551169221116869>

---

BioOne Complete ([complete.BioOne.org](https://complete.BioOne.org)) is a full-text database of 200 subscribed and open-access titles in the biological, ecological, and environmental sciences published by nonprofit societies, associations, museums, institutions, and presses.

Your use of this PDF, the BioOne Complete website, and all posted and associated content indicates your acceptance of BioOne's Terms of Use, available at [www.bioone.org/terms-of-use](https://www.bioone.org/terms-of-use).

Usage of BioOne Complete content is strictly limited to personal, educational, and non - commercial use. Commercial inquiries or rights and permissions requests should be directed to the individual publisher as copyright holder.

---

BioOne sees sustainable scholarly publishing as an inherently collaborative enterprise connecting authors, nonprofit publishers, academic institutions, research libraries, and research funders in the common goal of maximizing access to critical research.



# Ultrasonographic and colour Doppler features of intrapancreatic splenic tissue in a cat

Anne-Lorraine Peschard<sup>1</sup>, Wiktoria Jamont<sup>2</sup> ,  
Claire Shields<sup>2</sup> and Anna Cronin<sup>2</sup>

*Journal of Feline Medicine and Surgery Open Reports*  
1–5

© The Author(s) 2022

Article reuse guidelines:

sagepub.com/journals-permissions

DOI: 10.1177/20551169221116869

journals.sagepub.com/home/jfmsopenreports

This paper was handled and processed by the European Editorial Office (ISFM) for publication in *JFMS Open Reports*



## Abstract

**Case summary** A 2-year-old female neutered domestic longhair cat was referred for a 3-day history of lethargy and anorexia. Physical examination documented abdominal distension and pain, which, alongside marked electrolyte imbalances on blood biochemistry, was highly suspicious for a gastrointestinal obstruction. This was confirmed on diagnostic imaging, with abdominal ultrasonography also identifying an incidental, well-defined small lobular hypoechoic nodule adjacent to the tail of the spleen, with high vascularity on Doppler interrogation. This was identified as a focal nodule at the tip of the left limb of the pancreas at surgery, and resected via partial pancreatectomy. Histopathological examination confirmed intrapancreatic splenic tissue.

**Relevance and novel information** This case report presents the first available ultrasonographic description and images of intrapancreatic splenic tissue in a cat. It is thought to be a benign lesion of low clinical significance and therefore defining its imaging characteristics may allow for improvement in diagnostic suspicion without resorting to excisional surgery.

**Keywords:** Pancreas; spleen; imaging; nodule; congenital; hypoechoic; hypervascular

**Accepted:** 12 July 2022

## Introduction

Intrapancreatic splenic tissue (IPST) is sporadically reported in veterinary species, including dogs,<sup>1</sup> cats,<sup>1,2</sup> rabbits,<sup>3,4</sup> pigs,<sup>5,6</sup> cetaceans<sup>7</sup> and non-human primates.<sup>8,9</sup> IPST can have two possible origins, indistinguishable on histopathology: splenosis, which consists in autotransplantation of splenic tissue in a patient (ie, following trauma); or accessory spleen, which consists of aberrantly located splenic masses of congenital origin.<sup>10</sup>

In cats and dogs, IPST has been reported both focally<sup>1,2</sup> and multifocally,<sup>1</sup> with a possible predisposition in females.<sup>1</sup> Macroscopically at surgery, IPST is usually described as well-defined, dark brown-to-dark red round nodules, and has been found in both the right and left lobes of the pancreas.<sup>1,2</sup> In one cat, the IPST was located at the tip of the left lobe of the pancreas,<sup>2</sup> mimicking the location described in humans. Although one case report has detailed the attenuation and dynamic

contrast enhancement pattern of IPST relative to the spleen and pancreas on CT in a cat,<sup>2</sup> there are only two mentions of the ultrasonographic appearance of IPST in dogs, with no published ultrasound images, describing these as well-defined small nodules.<sup>1</sup> In one of these two canine cases, the pancreatic nodule was also noted to be hypoechoic to the surrounding pancreatic parenchyma. There are no documentations of the ultrasonographic aspect of IPST in cats, with one case report suggesting that it may be indistinguishable from the pancreatic

<sup>1</sup>The Queen's Veterinary School Hospital (QVSH), Cambridge, UK

<sup>2</sup>Wear Referrals Veterinary Specialist and Emergency Hospital, part of Linnaeus Veterinary Limited, Bradbury, UK

### Corresponding author:

Anne-Lorraine Peschard DVM, MSVM, MRCVS, The Queen's Veterinary School Hospital (QVSH), Madingley Road, Cambridge CB3 0ES, UK

Email: aldmp2@cam.ac.uk



Creative Commons Non Commercial CC BY-NC: This article is distributed under the terms of the Creative Commons

Attribution-NonCommercial 4.0 License (<https://creativecommons.org/licenses/by-nc/4.0/>) which permits non-commercial use, reproduction and distribution of the work without further permission provided the original work is attributed as specified on the SAGE and Open Access pages (<https://us.sagepub.com/en-us/nam/open-access-at-sage>).

parenchyma, with no mention of the vascularisation pattern on Doppler interrogation.

Therefore, ultrasonographic description, colour Doppler characteristics and available images are currently lacking for IPST in cats. To our knowledge, the present case report presents the first ultrasonographic description and images of IPST in a cat.

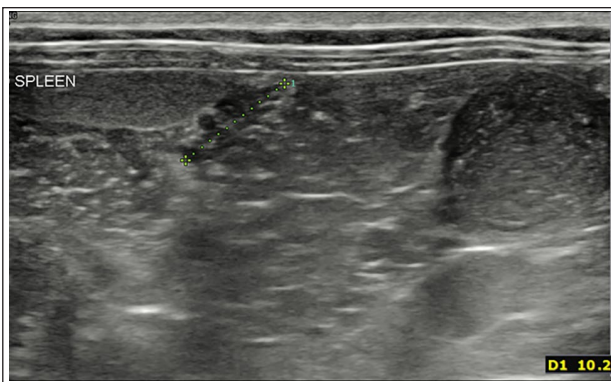
### Case description

A 2-year-old female spayed domestic longhair cat was presented to the medicine department at Wear Referrals Veterinary Specialist and Emergency Hospital for further investigation into a 3-day history of lethargy and anorexia. The cat had vomited pieces of a plastic toy 2 days earlier. The patient weighed 4.1 kg, with a body condition score of 4/9. The cat was quiet on presentation, and physical examination revealed a heart rate of 172 beats/min with a regular rhythm, and both heart and lung auscultation were within normal limits. The respiratory rate was fast at 60 breaths/min, which was considered to be stress-related. The cat's rectal temperature was 37.5°C. Mucous membranes were dry, with a capillary refill time of <2s. On abdominal palpation, distension of the abdomen and mid-abdominal pain were noted.

The haematology results were unremarkable. Serum biochemistry analysis revealed an increase in creatinine (211.0 µmol/l; reference interval [RI] 80.0–203.0), urea (21.3 mmol/l; RI 2.5–9.9) and total protein (82.9 g/l; RI 60.0–80.0). Electrolyte analysis showed hyponatraemia (137 mmol/l; RI 147–162), hypokalaemia (2.5 mmol/l; RI 2.9–4.2), hypocalcaemia (1.05 mmol/l; RI 1.2–1.32) and hypochloraemia (91 mmol/l; RI 112–129).

Following the administration of methadone (0.2 mg/kg IV [Comfortan; Dechra]) for analgesia, abdominal radiography and ultrasonography were performed. A single right lateral abdominal radiograph was acquired, documenting an obstructive pattern evidenced by the presence of two populations of small intestine (intestinal segments containing a small amount of fluid opacity content and markedly dilated fluid-filled segments, the diameter of which was approximately 16.3 mm). The stomach was also markedly distended by a large amount of fluid and a small amount of gas.

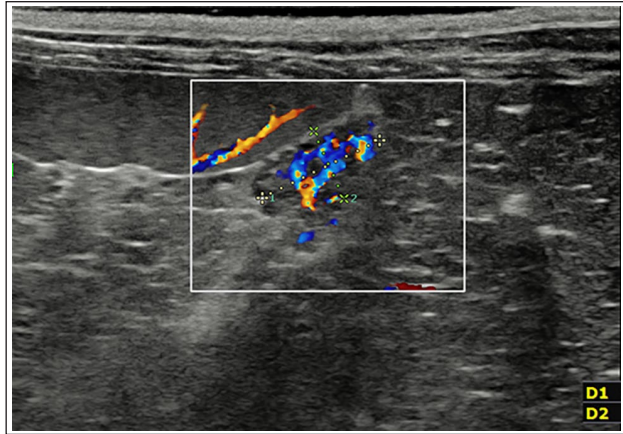
Owing to a lack of patient compliance, sedation was considered in order to obtain an orthogonal view; however, the patient was considered unstable and at high risk of sedation-related complications because of the previously described electrolyte abnormalities and suspected hypovolaemia. It was therefore decided to conduct a conscious abdominal ultrasound examination (performed by ALP and CS) using a Samsung RS85 ultrasound machine (Samsung Medison) and a high-frequency linear transducer (LM4-15B) set to 10 MHz frequency.



**Figure 1** Sagittal ultrasound image at the level of the spleen acquired with a 10 MHz linear transducer. The left of the screen is in the cranial direction. Note the focal hypoechoic nodule (calipers) adjacent to the splenic tail (left of the screen), which was later identified as intrapancreatic splenic tissue. Note on the far right of the screen the presence of a markedly dilated small intestinal loop seen in transverse

The ultrasonographic findings corroborated the obstructive small intestinal pattern, with markedly dilated and fluid-filled loops of small intestine alongside loops of jejunum containing very small amounts of fluid and gas. At the junction between these two small intestinal populations, a focal hyperechoic smoothly margined intraluminal structure was present, measuring 11.6 × 7.5 mm. This structure was casting an acoustic shadow, and the dilation of the intestinal lumen was located orad to it, whereas the jejunum aborad to this shadowing object reverted to a normal appearance with no luminal dilatation. The gastric lumen was also markedly distended by echogenic fluid. The wall layering of all gastrointestinal structures was considered unremarkable. A small amount of anechoic free peritoneal fluid was also noted, mostly between intestinal loops. Along the mesenteric surface of the spleen, at the level of the splenic tail and adjacent to an echographically normal pancreas, a small (approximately 10.7 × 6.1 mm) lobular hypoechoic nodule was noted (Figure 1). It was surrounded by an ill-defined halo of hyperechoic tissue. On colour Doppler interrogation, this nodule showed marked disorganised vascular arborisation (Figure 2). The splenic parenchyma itself was considered ultrasonographically to be within the normal limits, being of a normal shape and size with a homogeneous hyperechoic appearance and a smoothly margined, well-defined, hyperechoic capsule.

The diagnostic imaging procedures performed on the patient therefore allowed identification of a mid-jejunal obstructive foreign body as the likely cause for the patient's presenting clinical signs and electrolyte imbalances. The azotaemia noted on the bloodwork was suspected to be mainly of pre-renal origin. The nodule



**Figure 2** Sagittal ultrasound image at the level of the spleen acquired with a 10MHz linear transducer. The left of the screen is in the cranial direction. The focal hypoechoic nodule outlined in Figure 1 demonstrates marked vascularity on colour Doppler interrogation, with no clear visualisation of individual vessels

found adjacent to the spleen was suspected to be an incidental finding of low clinical relevance, and speculations about its aetiology included a congenital abnormality (eg, an arteriovenous malformation), neoplasia or a granuloma.

Although further diagnostics were considered to identify the nature and origin of this nodule, the decision was made not to perform fine-needle aspiration (FNA) of the structure as the patient was not stable enough for sedation and would not tolerate conscious sampling, and the high vascularity of the structure raised concern for post-sampling haemorrhage. As the patient also required exploratory laparotomy for the jejunal obstruction, intra-operative assessment of the lesion was preferred over additional advanced imaging.

Following diagnostic imaging, the patient was not deemed stable enough to undergo general anaesthesia and laparotomy immediately, and was therefore hospitalised overnight in the intensive care unit on supportive treatment. The electrolyte imbalances and azotaemia were corrected within 12h of initiating intravenous fluid therapy resuscitation. The next morning, the patient had a focused ultrasonographic recheck of both the jejunal foreign body and of the nodule of undetermined origin, which were both unchanged from the previous day. A midline coeliotomy was performed on the same day. During exploration of the abdomen an approximately 1 cm grooved, dark-red nodule was identified in the distal end of the left pancreatic limb. A partial pancreatectomy was performed with a 1 cm margin around the nodule. This was followed by a routine enterotomy of the mid-jejunum to remove the foreign body, which was identified as the shell of a plastic shotgun pellet.

Histopathological examination findings of the pancreatic nodule were consistent with splenic tissue within

the pancreas. This abnormal tissue was fully resected, with clear margins. No neoplastic or significant inflammatory cells were identified. The prognosis for the jejunal obstruction, once surgically resolved and the patient had recovered from surgery, was considered excellent. The prognosis for the IPST, extrapolated from the human literature, was also deemed to be excellent.

The patient recovered uneventfully from surgery, and was discharged 4 days postoperatively. The cat carried on improving at home, and on follow-up 2 months postoperatively the owners reported no concerns.

## Discussion

We report the ultrasonographic and colour Doppler features of IPST in a cat, which appeared as a well-defined, highly vascularised hypoechoic nodule. The nodule was surgically resected and a diagnosis of IPST was confirmed on histopathology. The aetiology of this IPST is unclear, but, in this case, was considered to be most likely of congenital origin. For this reason, in this report, the term 'intrapancreatic splenic tissue' was preferred to the term 'intrapancreatic accessory spleen' (IPAS), which is widely used in the human literature, as IPST includes splenosis, as well as accessory spleen, as the origin for the aberrantly located splenic tissue. Ectopic spleens are a relatively rare occurrence in companion animal medicine and, to our knowledge, there are no reports of prevalence values in cats. Only three cases of feline IPST have been reported in the recent veterinary literature,<sup>1,2</sup> of which only one mentions that the IPST identified on CT was not visible on ultrasound.<sup>2</sup> However, it is unclear from the latter case report what model of ultrasound machine was used, as well as the level of training of the ultrasonographer, and it is therefore difficult to estimate the likelihood of a subtle lesion being overlooked.

At the time of the ultrasound, IPST was not considered as a differential diagnosis as, although sporadically reported in cats, it is not described as an ultrasonographically visible, well-vascularised nodule. The necessity for the patient to undergo laparotomy for resolution of the small intestinal obstruction also prompted the clinicians to opt for excisional biopsy rather than additional advanced imaging such as contrast-enhanced CT, which could have helped characterise this nodule further and possibly identify it as splenic ectopic tissue.

One of the differentials for this nodule was an arteriovenous malformation, due to the dense network of vessels of variable direction and velocity identified within the nodule on colour Doppler interrogation. Although pulsed-wave Doppler could have helped to identify an arterial or venous velocity, it was not accurately applicable in this case due to the sub-millimetre size of the vessels and tachypnoea exhibited by the patient.

Owing to the scarcity of reports of IPST in the veterinary literature, this report adds to the feline literature. In



the human literature, it is estimated that approximately 2% of the human population possess an IPAS.<sup>11</sup> The tail of the pancreas is reported to be the second most common location for accessory spleens after the splenic hilus, representing approximately 16.8% of all cases in which accessory spleens are detected.<sup>11,12</sup> IPASs are usually well-circumscribed round or ovoid solitary masses of 1–2 cm diameter.<sup>11,13</sup> On ultrasound, they appear as homogeneously hypoechoic or isoechoic to the pancreatic parenchyma and isoechoic to the spleen. On all dynamic phases of contrast-enhanced ultrasound (vascular, arterial, portal and delayed hepatosplenic parenchymal phases), an IPAS demonstrates a similar echogenicity to the spleen and is consistently hyperechoic compared with the surrounding pancreatic parenchyma.<sup>14,15</sup> Most IPAS are hypervascular, with a characteristic vascular hilus.<sup>14</sup> On both CT and MRI, the pre- and postcontrast attenuation and intensity of the IPAS, respectively, should be in most cases identical to that of the spleen.<sup>16–19</sup> However, this does not always allow for differentiation from a pancreatic malignancy, regardless of the imaging modality, owing to the potential variability of the aspect of the IPAS according to its white-to-red pulp content<sup>17</sup> and the variability in imaging features of a pancreatic neoplastic lesion. Ultrasound-guided FNA has been used an adjunctive method to diagnose IPASs in humans;<sup>13,20–22</sup> however, there have been two reports of false-positive cases of pancreatic splenosis diagnosed as pancreatic neuroendocrine tumour based on cytology of fine-needle aspirates.<sup>13,23</sup>

Pancreatic malignancy is a differential diagnosis for IPST, as both share imaging features of hypervascular intraparenchymal masses. This stresses the importance of detailing the imaging characteristics of intrapancreatic masses of splenic tissue, as these may otherwise prompt unnecessary surgical resection. Indeed, although complications such as haemorrhage can be a rare complication of aberrantly located splenic tissue, the presence of IPST is not usually associated with clinical signs. A multimodal imaging approach and/or the use of contrast medium extrapolated from ultrasonographic, CT and MRI studies in people, may allow for an increase in the suspicion for IPST and, in the absence of clinical signs consistent with a pancreatic neoplasm, encourage the clinician to favour a conservative approach rather than partial pancreatectomy. Finally, even if the concurrent presence of locoregional lymphadenopathy may help raise the suspicion for pancreatic neoplasm over IPST, a possible differential for an abnormal coeliac lymph node on abdominal ultrasound is the concurrent presence of mesenteric accessory spleens.<sup>24</sup>

Various medical articles suggest that, where appropriate, regular ultrasonographic monitoring of such pancreatic lesions allows the diagnostic suspicion of IPST to be enforced without the need for invasive surgery.<sup>25,26</sup>

Although the use of FNA for contributing to a diagnosis of IPST is not yet reported in cats and dogs, it may prove useful, as in humans, and should be considered in animals that have lesions consistent with IPST on imaging, and a lack of clinical signs relating to a pancreatic malignancy. The authors suggest that, when appropriate, FNAs and ultrasonographic monitoring of focal pancreatic lesions consistent with IPST should be considered as an alternative to surgical resection.

## Conclusions

This case report demonstrates that IPST in cats can ultrasonographically mimic what is reported in humans — a well-defined rounded-to-lobulated mass at the tip of the left pancreatic lobe that is hypoechoic to the pancreatic parenchyma and hypervascular on Doppler interrogation. IPST is therefore an important differential for pancreatic masses characterised by such ultrasonographic features.

**Acknowledgements** The authors wish to thank the nursing team at Wear Referrals for their assistance with patient monitoring, anaesthesia and care, as well as Ben Harris for his help in reviewing this case report.

**Conflict of interest** The authors declared no potential conflicts of interest with respect to the research, authorship, and/or publication of this article.

**Funding** The authors received no financial support for the research, authorship, and/or publication of this article.

**Ethical approval** The work described in this manuscript involved the use of non-experimental (owned or unowned) animals. Established internationally recognised high standards ('best practice') of veterinary clinical care for the individual patient were always followed and/or this work involved the use of cadavers. Ethical approval from a committee was therefore not specifically required for publication in *JFMS Open Reports*. Although not required, where ethical approval was still obtained, it is stated in the manuscript.

**Informed consent** Informed consent (verbal or written) was obtained from the owner or legal custodian of all animal(s) described in this work (experimental or non-experimental animals, including cadavers) for all procedure(s) undertaken (prospective or retrospective studies). For any animals or people individually identifiable within this publication, informed consent (verbal or written) for their use in the publication was obtained from the people involved.

**ORCID iD** Wiktoria Jamont  <https://orcid.org/0000-0003-2329-7284>

## References

- 1 Ramírez GA, Altimira J, García-González B, et al. **Intra-pancreatic ectopic splenic tissue in dogs and cats.** *J Comp Pathol* 2013; 148: 361–364.

- 2 Tomura S, Toshima A, Nomura A, et al. **Intrapancreatic accessory spleen mimicking pancreatic insulinoma with intrapancreatic metastasis in a cat.** *J Vet Med Sci* 2022; 84: 439–444.
- 3 Adak A, Prasad MC, Lonkar PS, et al. **Ectopic spleen in the pancreas of New Zealand White rabbits.** *Vet World* 2013; 6: 360–362.
- 4 Harleman JH. **Ectopic spleen tissue in the pancreas of Himalayan rabbits.** *Lab Anim Sci* 1983; 33: 463–464.
- 5 Swarbrick O. **Ectopic splenic nodules in the pancreas of a sow.** *Br Vet J* 1968; 124: 16. DOI: 10.1016/S0007-1935(17)39603-3.
- 6 Koo OJ, Ha SK, Park SJ, et al. **Intrapancreatic ectopic splenic tissue found in a cloned miniature pig.** *J Vet Sci* 2015; 16: 241–244.
- 7 Nakagun S, Díaz-Delgado J, Groch KR, et al. **Intrapancreatic accessory spleen in a harbor porpoise (*Phocoena phocoena*).** *J Vet Med Sci* 2018; 80: 701–705.
- 8 Jeneby MM, Langoi D, Mwenda JM, et al. **Ectopic splenic nodules in the olive baboon (*Papio cynocephalus anubis*).** *J Med Primatol* 2003; 32: 120–122.
- 9 Lau DT. **Ectopic splenic nodules in the pancreas of a Capuchin monkey (*Cebus albifrons*).** *J Med Primatol* 1973; 2: 67–70.
- 10 Movitz D. **Accessory spleens and experimental splenosis. Principles of growth.** *Chic Med Sch Q* 1967; 26: 183–187.
- 11 Halpert B and Alden ZA. **Accessory spleens in or at the tail of the pancreas. A survey of 2,700 additional necropsies.** *Arch Pathol* 1964; 77: 652–654.
- 12 Halpert B and Gyorkey F. **Lesions observed in accessory spleens of 311 patients.** *Am J Clin Pathol* 1959; 32: 165–168.
- 13 Ardengh C, Lopes V, Kemp R, et al. **Pancreatic splenosis mimicking neuroendocrine tumors: endoscopic ultrasound guided fine needle aspiration.** *Arq Gastroenterol* 2013; 50: 10–14.
- 14 Subramanyam B, Balthazar E and Horii S. **Sonography of the accessory spleen.** *AJR Am J Roentgenol* 1984; 143: 47–49.
- 15 Kim S, Lee J, Lee J, et al. **Contrast-enhanced sonography of intrapancreatic accessory spleen in six patients.** *AJR Am J Roentgenol* 2007; 188: 422–428.
- 16 Paterson A, Frush D, Donnelly L, et al. **A pattern-oriented approach to splenic imaging in infants and children.** *Radiographics* 1999; 19: 1465–1485.
- 17 Kim S, Lee J, Han J, et al. **MDCT and superparamagnetic iron oxide (SPIO)-enhanced MR findings of intrapancreatic accessory spleen in seven patients.** *Eur Radiol* 2006; 16: 1887–1897.
- 18 Harris G, Kase D, Bradnock H, et al. **Accessory spleen causing a mass in the tail of the pancreas: MR imaging findings.** *AJR Am J Roentgenol* 1994; 163: 1120–1121.
- 19 Sica G and Reed M. **Case 27: intrapancreatic accessory spleen.** *Radiology* 2000; 217: 134–137.
- 20 Krishna S, Heif MM, Sharma SG, et al. **Intrapancreatic accessory spleen: investigative dilemmas and role of EUS-guided FNA for diagnostic confirmation.** *JOP* 2011; 12: 603–606.
- 21 Saunders TA, Miller TR and Khanafshar E. **Intrapancreatic accessory spleen: utilization of fine needle aspiration for diagnosis of a potential mimic of a pancreatic neoplasm.** *J Gastrointest Oncol* 2016; 7 Suppl 1: S62–S65.
- 22 Rodriguez E, Netto G and Kay Li Q. **Intrapancreatic accessory spleen: a case report and review of literature.** *Diagn Cytopathol* 2012; 41: 466–469.
- 23 Toussaint E, Flamen P, Demetter P, et al. **A rare case of a pancreatic mass due to accessory spleen; when EUS-FNA is not enough.** *Endoscopy* 2011; 43: 221–222.
- 24 Uchiyama S, Chijiwa K, Hiyoshi M, et al. **Intrapancreatic accessory spleen mimicking endocrine tumour of the pancreas: case report and review of the literature.** *J Gastrointest Surg* 2008; 12: 1471–1473.
- 25 Sothilingam N, Leedahl T, Kriegler S, et al. **Intrapancreatic accessory spleen: a case report and review of the literature.** *Int J Surg Case Rep* 2011; 2: 128–130.
- 26 Massani M, Maccatrozzo P, Morana G, et al. **Diagnostic difficulties and therapeutic choices in intrapancreatic accessory spleen: case reports.** *Open Access Surg* 2016; 9: 15–20.