



Tooth aspiration in two cats following maxillofacial trauma

Authors: Bar Giora, Yael, Weingram, Tomer, Altabet, Lior, Yair, Nadav, Kachtan, Ido, et al.

Source: Journal of Feline Medicine and Surgery Open Reports, 8(2)

Published By: SAGE Publishing

URL: <https://doi.org/10.1177/20551169221125403>

BioOne Complete (complete.BioOne.org) is a full-text database of 200 subscribed and open-access titles in the biological, ecological, and environmental sciences published by nonprofit societies, associations, museums, institutions, and presses.

Your use of this PDF, the BioOne Complete website, and all posted and associated content indicates your acceptance of BioOne's Terms of Use, available at www.bioone.org/terms-of-use.

Usage of BioOne Complete content is strictly limited to personal, educational, and non - commercial use. Commercial inquiries or rights and permissions requests should be directed to the individual publisher as copyright holder.

BioOne sees sustainable scholarly publishing as an inherently collaborative enterprise connecting authors, nonprofit publishers, academic institutions, research libraries, and research funders in the common goal of maximizing access to critical research.



Tooth aspiration in two cats following maxillofacial trauma

Yael Bar Giora¹, Tomer Weingram², Lior Altabet³, Nadav Yair¹, Ido Kachtan¹ and Yoav Bar Am¹

Journal of Feline Medicine and Surgery Open Reports
1–5

© The Author(s) 2022

Article reuse guidelines:

sagepub.com/journals-permissions

DOI: 10.1177/20551169221125403

journals.sagepub.com/home/jfmsopenreports

This paper was handled and processed by the European Editorial Office (ISFM) for publication in *JFMS Open Reports*



Abstract

Case series summary Tooth aspiration is a rare occurrence in human medicine, and even more so in veterinary medicine. This report describes two cats that aspirated a tooth (one canine tooth and one premolar tooth) following maxillofacial trauma. One cat presented with dyspnoea, while the other showed no respiratory clinical signs. In both cases diagnosis was reached by obtaining routine thoracic radiographs, and successful retrieval of the teeth was achieved by bronchoscopy. Both cats recovered uneventfully.

Relevance and novel information To our knowledge, this is the first report in the veterinary literature of tooth aspiration into the tracheobronchial tree following maxillofacial trauma. The scope of this case series is to raise awareness that tooth aspiration can occur following maxillofacial trauma and has the potential for serious complications if not diagnosed and treated promptly. Therefore, an oral examination must be performed in every maxillofacial trauma patient and missing teeth should be accounted for, even when respiratory clinical signs are not detected.

Keywords: Maxillofacial trauma; dentoalveolar injury; tooth aspiration; foreign body aspiration; bronchoscopy

Accepted: 25 August 2022

Introduction

Aspiration of a foreign body (FB) into the tracheobronchial tree is rarely reported in the veterinary literature.¹ Three reports in which a tooth was retrieved from the respiratory tract of cats were found, but the circumstances regarding the teeth being lodged there in the first place were not described.^{1,2,3}

In human medicine, tooth aspiration is a rare but known critical complication following maxillofacial trauma, dental procedures, oral surgeries or endotracheal intubations,^{4–9} representing 10% of all FBs aspirated in adults.¹⁰ These cases necessitate prompt diagnosis and treatment to minimise or prevent complications.^{4,7,8}

Clinical signs of FB aspiration in small animals include acute or chronic cough, haemoptysis and dyspnoea.¹ While some FBs remain in the respiratory tract, others migrate through the lung parenchyma and cause pneumonia, atelectasis, lobar consolidation, lung abscess, pneumothorax or pyothorax.^{1,4,11,12}

Diagnosis and localisation of an aspirated FB in cats can be achieved by clinical history, thoracic radiographs

(depending on the radiographic characteristics of the FB), CT and bronchoscopy.¹

Bronchoscopy is considered the gold standard procedure for retrieving FBs from the respiratory tract in humans,^{13,14} and is also commonly used in veterinary medicine,^{1,11} with an 83% success rate in cats.¹ With tracheal FBs, forceps removal under fluoroscopy was described in cats when bronchoscopy was unsuccessful.² When these procedures fail, or when complications such as pneumothorax or pyothorax are present, thoracotomy is usually required.^{1,11}

¹Koret School of Veterinary Medicine, Hebrew University of Jerusalem, Allone Abba, Israel

²Herzlia Veterinary Hospital, Herzlia, Israel

³Vetoscope – Mobile Veterinary Endoscopy, Rishon Lezion, Israel

Corresponding author:

Yoav Bar Am DVM, Dip AVDC, Dip EVDC, Koret School of Veterinary Medicine, Hebrew University of Jerusalem, Derech Hamaccabim 70, Rishon Lezion, Israel
Email: ybaram42@gmail.com



Creative Commons Non Commercial CC BY-NC: This article is distributed under the terms of the Creative Commons

Attribution-NonCommercial 4.0 License (<https://creativecommons.org/licenses/by-nc/4.0/>) which permits non-commercial use,

reproduction and distribution of the work without further permission provided the original work is attributed as specified on the SAGE and Open Access pages (<https://us.sagepub.com/en-us/nam/open-access-at-sage>).

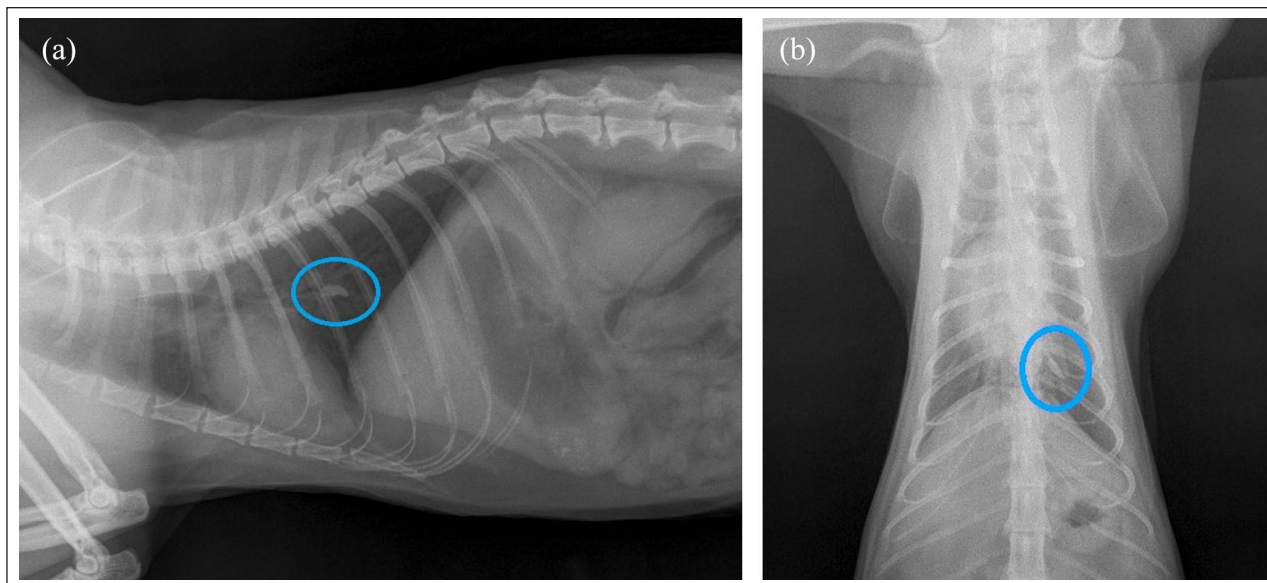


Figure 1 (a) Lateral and (b) dorsoventral thoracic radiographs of case 1, which both show a radiopaque structure, suspected to be a foreign body, in the left caudal bronchus

Case series description

Case 1

An adult spayed female domestic shorthair cat weighing 4 kg was presented to the veterinary hospital after a vehicular trauma. The chief complaint was ‘dragging the hind legs’.

Owing to fractious behaviour, a full physical examination and imaging were performed after the cat was sedated with medetomidine hydrochloride (20 µg/kg IM [Domitor; Orion Pharma]), ketamine (3 mg/kg IM [Ketamin; Bremer Pharma]) and butorphanol (0.4 mg/kg [Butomidor; Richter Pharma]). Several injuries were detected, but their description is beyond the scope of this report. The cat’s body temperature was 37°C, the heart rate was 100 beats per minute and the respiratory rate was 48 breaths per minute. On oral examination, both mandibular canine teeth were missing, with mild gingival bleeding in the area.

Blood count on arrival showed leukocytosis ($32 \times 10^9/l$; reference interval [RI] 5.5–19.5) with a normal haematocrit and platelet count. Blood chemistry showed mild hyperglycaemia (238 mg/dl; RI 70–150), hyponatraemia (134 mmol/l; RI 142–164) and mild hyperproteinaemia (8.5 g/dl; 5.4–8.2); albumin and globulins were within the normal limits.

The cat was treated with intravenous (IV) lactated Ringer’s solution (4 ml/kg/h [Teva Medical]), amoxicillin/clavulanic acid (15 mg/kg IV [Clavener; Reig Laboratory]) and buprenorphine (0.02 mg/kg IV [Bupaq; Richter Pharma]).

Thoracic radiographs revealed a distinct radiopaque structure in the left caudal bronchus consistent with a FB

(Figure 1). The assessment was that one of the mandibular canine teeth had fractured during the trauma and was aspirated.

Owing to the proximity to the trauma and lack of respiratory distress, bronchoscopy was not performed immediately. The next day the cat seemed comfortable, and was eating and breathing normally, with no abnormal respiratory sounds on auscultation. Its body temperature was elevated (39.7°C) but returned to normal limits following the administration of metamizole (25 mg/kg SC [Dypirone; HBM Pharma]). Twenty-four hours after arrival, a second set of thoracic radiographs was obtained to confirm the presence and location of the FB within the respiratory tract. No changes in appearance and location were noted.

Bronchoscopy was performed 48 h after arrival. The cat was premedicated with intravenous (IV) butorphanol (0.2 mg/kg) and midazolam (0.2 mg/kg [Midolam; Rafa]). Anaesthesia was induced with propofol (2 mg/kg IV [Propofol-Lipuro; Braun]). A number 4 endotracheal tube was placed. Maintenance of anaesthesia was done with isoflurane 1%. The cat was placed in sternal recumbency and a flexible bronchoscope (3 mm × 100 cm 60003 VBK1 Karl Storz fibreoptic endoscope) was inserted through the endotracheal tube. The tooth was located in the left caudal bronchus (Figure 2) and retrieved using grasping forceps inserted through the instrument working channel. Owing to a lack of secretions and signs of inflammation, a bronchoalveolar lavage (BAL) was not performed. Examination of the tooth after its retrieval (Figure 3) revealed a stage 4 resorptive lesion at the area of the cemento-enamel junction.

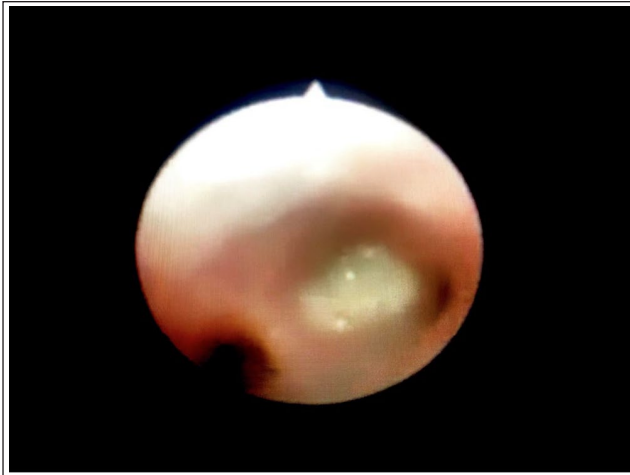


Figure 2 The tooth in the left caudal bronchus

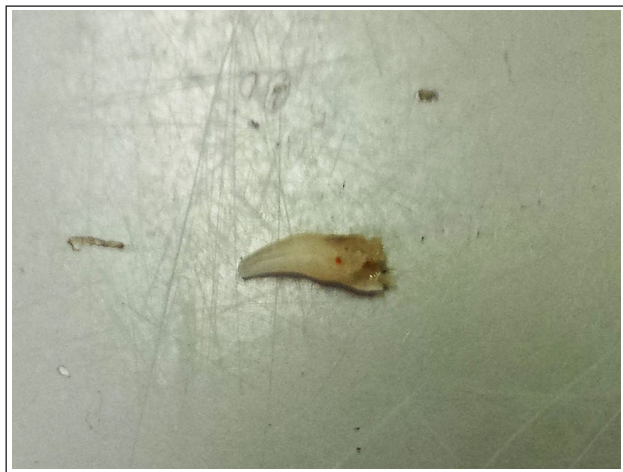

Figure 3 The tooth following its retrieval from the left caudal bronchus

The cat recovered uneventfully, and was discharged the next day. Amoxicillin/clavulanic acid (12.5 mg/kg q12h PO [Synulox; Zoetis]) was prescribed for 5 days. There were no respiratory clinical signs on recheck examination, 1 month after the procedure.

Case 2

An adult neutered male domestic shorthair cat weighing 4.8 kg was presented to the veterinary hospital with a chief complaint of acute respiratory distress following a cat fight the night before. A thoracic radiograph obtained by the referring veterinarian (Figure 4a) showed a radioopaque structure, suspicious for a FB, in the carina.

On arrival, a full physical examination was performed. The cat's body temperature was 37.2°C, its heart rate was 152 beats per minute and its respiratory rate was 52 breaths per minute. The cat was dyspnoeic, with cyanotic mucous membranes. On chest auscultation

wheezing was detected, but the heart sounds were normal. On oral examination a few teeth were missing, and a hyperaemic area was noted in the gingiva of the right mandible.

A ventrodorsal thoracic radiograph was obtained to complete a two-view thoracic survey in order to confirm the presence and location of the FB within the respiratory tract (Figure 4b). Based on the radiographs, the FB was presumed to be located in the middle plane of the thoracic cavity, most probably in the carina. The cat was anaesthetised (using the same protocol as for case 1), and bronchoscopy was performed immediately. A premolar tooth covered with mucous secretions was retrieved from the carina. The respiratory distress resolved immediately thereafter. BAL was declined by the owners owing to financial constraints. The cat recovered uneventfully, and was discharged on the following day. Amoxicillin/clavulanic acid (15 mg/kg q12h PO) was prescribed for 5 days. The owners reported the cat was doing well at the 2-week post-discharge phone recheck.

Discussion

Aspiration of FBs is uncommon in small animals. It is a potentially serious, sometimes fatal, condition, necessitating prompt diagnosis and early treatment to minimise the consequences.^{1,11,15} In the human literature, tooth aspiration is a rare complication of maxillofacial injuries or dental procedures.^{4,5,8} There are only three reports in the veterinary literature describing tooth retrieval from the respiratory tract of cats,^{1,2,3} but the circumstances leading to these tooth aspirations were not described.

A thorough oral examination is essential when evaluating a patient with maxillofacial trauma. A study evaluating high-rise syndrome showed a much higher rate of reported dental trauma when oral examination was performed by a specialist or resident in dentistry and oral surgery compared with other clinicians (71.4% vs 6.0%).¹⁶ According to another study, 72.1% of dogs and cats with maxillofacial fractures had concurrent dentoalveolar injuries.¹⁷ Some of these injuries result in free tooth fragments in the oral cavity, which can end up being aspirated.

In case 1 the aspirated tooth showed signs of stage 4 resorptive lesions. We assume that the tooth, weakened due to advanced resorption, was broken by the force of the trauma and was aspirated.

In human medicine, the clinical presentation of patients with aspirated FBs varies depending on the location of the FB in the airway, with more acute respiratory distress in proximal obstructions compared with distal obstructions.¹⁸ In case 1 the obstruction was distal, in the left caudal bronchus. This may be the reason why the cat showed no respiratory clinical signs. However,

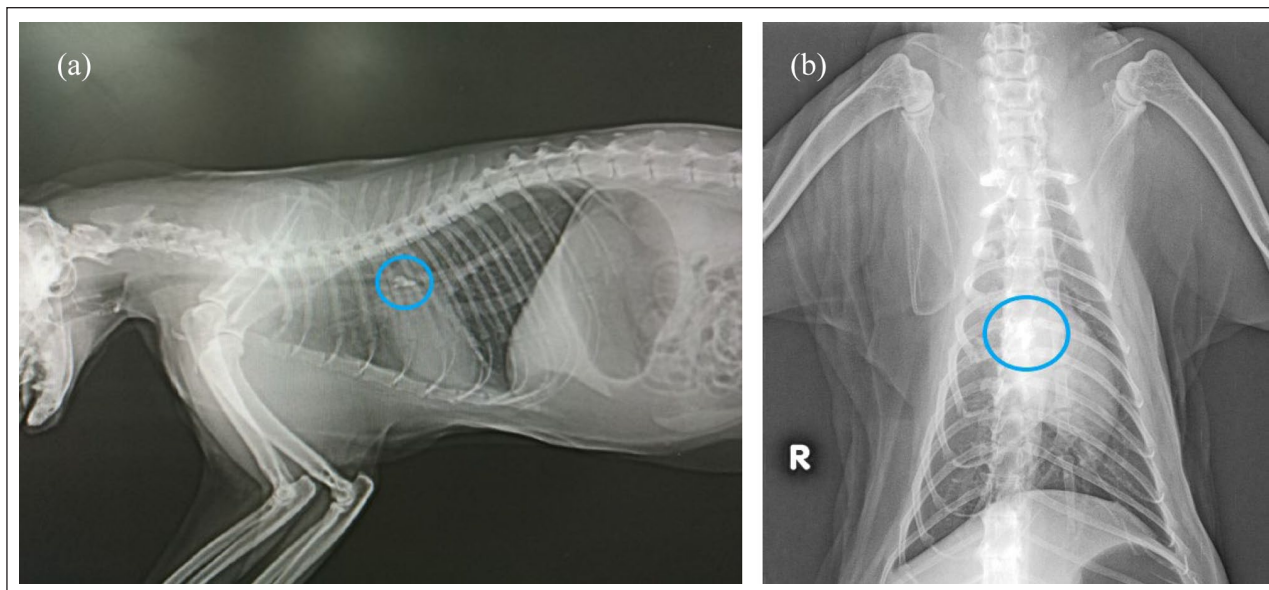


Figure 4 (a) Lateral and (b) ventrodorsal thoracic radiographs of case 2. Both show a radiopaque structure, suspected to be a foreign body, in the carina

case 2 had a proximal obstruction, in the carina, which led to respiratory distress.

There are three clinical phases following FB aspiration: the initial phase, the asymptomatic phase and the complications phase. The asymptomatic phase begins when the FB becomes lodged in the respiratory tract. At this point in time the reflexes fatigue, causing clinical signs to subside. This phase can last hours to weeks.¹⁹ Perhaps case 1 presented during the asymptomatic phase and therefore did not show respiratory clinical signs.

In both cases presented in this report, diagnosis was easily achieved by interpreting the thoracic radiographs correctly. A previous study described radiography as a useful modality for identifying and localising FBs in 92% of cats with confirmed tracheobronchial FBs.¹ Thoracic radiographs are performed routinely on patients with maxillofacial trauma to rule out critical conditions such as lung contusion, pneumothorax and diaphragmatic hernia. Owing to the tooth's radiopaque characteristics, a thoracic radiographic survey is probably the most efficient diagnostic modality in tooth aspirations.⁴ In some cases, diagnosis can be missed due to the superimposition of other radiopaque structures such as the spine, sternum or ribs.⁵ In these cases, CT may be a more accurate modality in detecting and localising aspirated FBs, including teeth.^{4,8,9}

In case 1 the tooth was lodged in the left caudal bronchus, and in case 2 it was lodged in the carina. These locations coincide with findings from a study conducted in cats, which showed that 50% of aspirated FBs were lodged in the trachea, while the other 50% were lodged in the bronchial tree.¹

Retrieval of aspirated FBs via bronchoscopy in cats has a success rate of 83%,¹ and was successful in both cases presented here. We therefore recommend bronchoscopy as the first-line treatment in such cases, similar to human medicine.

In the absence of respiratory clinical signs at presentation or in comatose patients, tooth aspiration following maxillofacial trauma can remain undetected and lead to acute or delayed complications such as pneumonia, atelectasis, pyothorax, pressure necrosis or migration of the tooth through the lung parenchyma into the thoracic cavity.^{4,6,9,11} The tooth may dislodge at any time, which could result in complete airway obstruction or lung collapse.⁹ Bronchiectatic changes in the airways (cartilage destruction and fibrosis) appear when a FB is present in the airways for a period of 30 days or longer.¹⁵

Spontaneous expulsion of an aspirated tooth by coughing it up has been reported in human medicine.⁴ However, as serious complications may occur, any case with suspected FB aspiration should be treated immediately.¹⁵ The prompt retrieval of the aspirated teeth in these cases probably prevented long-term complications.

Conclusions

Tooth aspiration following maxillofacial trauma in cats and dogs is rare. Nonetheless, if not diagnosed and treated promptly, it may lead to serious and possibly fatal complications. Oral examination must be performed in all patients with maxillofacial trauma, and missing teeth should be accounted for. Keeping an open mind as to where a missing tooth might be located will allow prompt diagnosis and treatment.

Acknowledgements The authors would like to thank Dr Liron D Oron DVM, DACVECC, DECVECC for her contribution in revising this report, and Dr David Silberberg, the referring veterinarian of case 2, for providing the initial radiograph.

Conflict of interest The authors declared no potential conflicts of interest with respect to the research, authorship, and/or publication of this article.

Funding The authors received no financial support for the research, authorship, and/or publication of this article.

Ethical approval The work described in this manuscript involved the use of non-experimental (owned or unowned) animals. Established internationally recognised high standards ('best practice') of veterinary clinical care for the individual patient were always followed and/or this work involved the use of cadavers. Ethical approval from a committee was therefore not specifically required for publication in *JFMS Open Reports*. Although not required, where ethical approval was still obtained, it is stated in the manuscript..

Informed consent Informed consent (verbal or written) was obtained from the owner or legal custodian of all animal(s) described in this work (experimental or non-experimental animals, including cadavers) for all procedure(s) undertaken (prospective or retrospective studies). No animals or people are identifiable within this publication, and therefore additional informed consent for publication was not required.

References

- 1 Leal RO, Bongrand Y, Lepoutre JG, et al. **Tracheobronchial foreign bodies in cats: a retrospective study of 12 cases.** *J Feline Med Surg* 2017; 19: 117–122.
- 2 Tivers MS and Moore AH. **Tracheal foreign bodies in the cat and the use of fluoroscopy for removal: 12 cases.** *J Small Anim Pract* 2006; 47: 155–159.
- 3 McGlennon NJ, Platt D, Dunn JK, et al. **Tracheal foreign body in a cat: a case report.** *J Small Anim Pract* 1986; 27: 457–461.
- 4 Xiao WL, Zhang DZ and Wang YH. **Aspiration of two permanent teeth during maxillofacial injuries.** *J Craniofac Surg* 2009; 20: 558–560.
- 5 Madan K, Aggarwal AN, Bhagat H, et al. **Acute respiratory failure following traumatic tooth aspiration.** *BMJ Case Rep* 2013; 2013: bcr2012008393. DOI: 10.1136/bcr-2012-008393.
- 6 Zhang M, Zhou GJ, Zhao S, et al. **Delayed diagnosis of tooth aspiration in three multiple trauma patients with mechanical ventilation.** *Crit Care* 2011; 15: 424. DOI: 10.1186/cc10148.
- 7 Alabidi A. **Aspiration of an incisor tooth after adenotonsillectomy in a 10-year-old Saudi boy.** *East Mediterr Health J* 2008; 14: 228–230.
- 8 Swain SK, Sahoo S and Sahu MC. **From tooth extraction to fatal airway complication in a child – a case report.** *Egypt J Ear Nose Throat Allied Sci* 2016; 17: 27–29.
- 9 Kumar N, Goyal H, Bindra A, et al. **Management of aspirated tooth in an adult head injury patient: report of two cases.** *Saudi J Anaesth* 2014; 8: 276–278.
- 10 Ramos MB, Botana-Rial M, Garcia-Fontan E, et al. **Update in the extraction of airway foreign bodies in adults.** *J Thorac Dis* 2016; 8: 3452–3456.
- 11 Tenwolde AC, Johnson LR, Hunt GB, et al. **The role of bronchoscopy in foreign body removal in dogs and cats: 37 cases (2000–2008).** *J Vet Intern Med* 2010; 24: 1063–1068.
- 12 Jillela S and Subrahmanyam R. **Inhaled tooth in the bronchus: importance of early intervention.** *Br J Anaesth* 2015; 115: 318–319.
- 13 Tang L, Xu Y, Wang Y, et al. **Airway foreign body removal by flexible bronchoscopy: experience with 1027 children during 2000–2008.** *World J Pediatr* 2009; 5: 191–195.
- 14 Divisi D, Di Tommaso S, Di Francescantonio, et al. **Foreign bodies aspirated in children: role of bronchoscopy.** *Thorac Cardiovasc Surg* 2007; 55: 249–252.
- 15 Yildizeli B, Zonüzi F, Yüksel M, et al. **Effects of intrabronchial foreign body retention.** *Pediatr Pulmonol* 2002; 33: 362–367.
- 16 Bonner SE, Reiter AM, et al. **Orofacial manifestations of high-rise syndrome in cats: a retrospective study of 84 cases.** *J Vet Dent* 2012; 29: 10–18.
- 17 Soukup JW, Mulherin BL and Snyder CJ. **Prevalence and nature of dentoalveolar injuries among patients with maxillofacial fractures.** *J Small Anim Pract* 2013; 54: 9–14.
- 18 Bajaj D., Sachdeva A and Deepak D. **Foreign body aspiration.** *J Thorac Dis* 2021; 13: 5159–5175.
- 19 Rodríguez H, Passali GC, Gregori D, et al. **Management of foreign bodies in the airway and oesophagus.** *Int J Pediatr Otorhinolaryngol* 2012; 76: S84–S91.