



Percutaneous transvenous coil embolization of an extrahepatic portosystemic shunt in a cat

Authors: Case, J Brad, Solari, Francesca P, and Vilaplana Grosso, Federico

Source: Journal of Feline Medicine and Surgery Open Reports, 8(2)

Published By: SAGE Publishing

URL: <https://doi.org/10.1177/20551169221126381>

BioOne Complete (complete.BioOne.org) is a full-text database of 200 subscribed and open-access titles in the biological, ecological, and environmental sciences published by nonprofit societies, associations, museums, institutions, and presses.

Your use of this PDF, the BioOne Complete website, and all posted and associated content indicates your acceptance of BioOne's Terms of Use, available at www.bioone.org/terms-of-use.

Usage of BioOne Complete content is strictly limited to personal, educational, and non - commercial use. Commercial inquiries or rights and permissions requests should be directed to the individual publisher as copyright holder.

BioOne sees sustainable scholarly publishing as an inherently collaborative enterprise connecting authors, nonprofit publishers, academic institutions, research libraries, and research funders in the common goal of maximizing access to critical research.



Percutaneous transvenous coil embolization of an extrahepatic portosystemic shunt in a cat

J Brad Case , Francesca P Solari 
and Federico Vilaplana Grosso

Journal of Feline Medicine and Surgery Open Reports
1–5

© The Author(s) 2022

Article reuse guidelines:

sagepub.com/journals-permissions

DOI: 10.1177/20551169221126381

journals.sagepub.com/home/jfmsopenreports

This paper was handled and processed by the American Editorial Office (AAFP) for publication in *JFMS Open Reports*



Abstract

Case summary A 10-month-old male domestic shorthair cat presented for surgical treatment of a congenital portosystemic shunt. The cat had a history of lethargy and ptyalism. Pre- and postprandial bile acids were markedly elevated. CT was performed, which revealed a single, congenital, left gastrophrenic, extrahepatic portosystemic shunt. A minimally invasive surgical approach was considered by transjugular percutaneous coil embolization of the venous shunt, which was performed without complications. Follow-up protein C and serum biochemical analyses were performed at 1, 2 and 5 months postoperatively, and were improved. The cat is alive and clinically normal 11 months postoperatively.

Relevance and novel information This is the first report of percutaneous transvenous coil embolization for the treatment of an extrahepatic portosystemic shunt in a cat. The outcome was excellent in this patient, with no complications and complete resolution of clinical signs.

Keywords: Portosystemic shunt; liver; embolization; interventional radiology

Accepted: 29 August 2022

Case description

A 5-month-old male domestic shorthair cat was initially found and adopted as a stray. At the time, the cat was lethargic and salivating excessively. The owner also reported intermittent bouts of aggression, hissing and suspected blindness. The cat was initially presented to the referring veterinarian for examination and vaccinations. It was noted to be aggressive, with marked ptyalism. Physical examination revealed normal vital parameters, a body weight of 2.9 kg and mild dehydration but no other physical abnormalities. A complete blood count was unremarkable, and serum biochemistry revealed a low blood urea nitrogen (BUN) (11 mg/dl; reference interval [RI] 16–33) and hyperglycemia (185 mg/dl; RI 77–153). Thoracic and abdominal radiographs were reported to have no significant abnormalities.

Given the reported neurologic signs and lack of vaccination history, the possibility of infectious disease was considered. The cat was vaccinated against rabies and was prescribed clindamycin (5 mg/kg PO q12h for 14 days) and prednisone (1 mg/kg PO q24h with gradual

taper over 2 weeks). The clinical signs improved significantly while on the medications but returned soon after discontinuation. The cat was seen by a private specialty hospital that performed serum bile acids testing, which revealed markedly elevated pre- (130 μ mol/l; RI 0–5) and postprandial (180 μ mol/l; no RI) serum bile acids. The specialty hospital performed contrast CT of the abdomen, given the suspicion of a portosystemic shunt. The tentative diagnosis was a single congenital left divisional intrahepatic portosystemic shunt. The cat was started on levetiracetam (20 mg/kg PO q8h), lactulose

Department of Small Animal Clinical Sciences, University of Florida College of Veterinary Medicine, Gainesville, FL, USA

Corresponding author:

J Brad Case DVM, MS, DACVS, Department of Small Animal Clinical Sciences, University of Florida College of Veterinary Medicine, PO Box 100126, 2015 SW 16th Ave, Gainesville, FL 32610-0126, USA
Email: caseb@ufl.edu



Creative Commons Non Commercial CC BY-NC: This article is distributed under the terms of the Creative Commons

Attribution-NonCommercial 4.0 License (<https://creativecommons.org/licenses/by-nc/4.0/>) which permits non-commercial use, reproduction and distribution of the work without further permission provided the original work is attributed as specified on the SAGE and Open Access pages (<https://us.sagepub.com/en-us/nam/open-access-at-sage>).

(1 ml PO q8h), metronidazole (8 mg/kg PO q12h) and famotidine (1 mg/kg PO q24h).

At 10 months of age, the cat was referred to the minimally invasive surgery service at the University of Florida. It was still receiving the medications previously prescribed by the specialty hospital, and the clinical signs had reportedly resolved with medical management. A triple-phase CT angiogram (160-slice [Aquilion Prime; Toshiba Medical Systems]) was performed to reassess the shunt and measure for procedural planning. CT revealed a single congenital extrahepatic, left gastrophrenic shunt measuring 7 mm in diameter with a diminutive main portal vein. Treatment options were discussed, including open surgery for the placement of a slow occlusion device (eg, cellophane band) or percutaneous transvenous coil embolization (PTCE). The owner was informed that open surgery is associated with a good prognosis in general, although neurologic complications can occur in up to 30% of cases and can lead to death. The owner was also informed that PTCE has recently been reported in four cats with intrahepatic portosystemic shunts with promising results. The owner elected for PTCE and the procedure was planned for the following day.

The cat was positioned in dorsal recumbency and the cervical region aseptically prepared. An 18G catheter was placed in the right external jugular vein to facilitate placement of a 4F micro-introducer, which was then replaced by a 6F introducer sheath. A 5F marker catheter (Infiniti Medical) was then positioned in the prehepatic vena cava and a bolus of a 4 ml 1:1 solution of iohexol (Omnipaque 300 mg I/ml; GE Healthcare) and 0.9% sterile saline solution was administered under subtraction angiography to create a venogram. An opacified image from this series was saved for calibration. The catheter was then connected to a calibrated pressure transducer and a central venous pressure of 11 mmHg was documented. The marker catheter was removed and a 4F Berenstein catheter (Infiniti Medical) was positioned into the portosystemic shunt via the left phrenic vein, and a subtraction angiogram was performed similar to the previous venogram. The presence of the shunt was confirmed, and portal pressure as measured through the shunting portal vein was measured to be 11 mmHg. The phrenic catheter was removed and a 12 × 60 mm self-expanding vascular stent (Zilver vascular self-expanding stent [Cook Medical]) was positioned in the hepatic caudal vena cava across the insertion of the phrenic vein into the caudal vena cava, ensuring that 2–3 cm of length existed on either side of the phrenic vein ostium (Figure 1). The 4F Berenstein catheter was then repositioned approximately 2 cm into the left phrenic vein and a 0.027" microcatheter (Renegade STC-18 microcatheter; Boston Scientific) over a 0.021" microwire (Terumo Medical) was placed via the Berenstein catheter

approximately 4 cm into the left phrenic vein (Figure 1). Portal pressure was again measured and found to be 11 mmHg. Both the Berenstein catheter and microcatheter were then repositioned in the left phrenic vein so that only 1 cm of the Berenstein and about 2 cm of the microcatheter tip was present within the vein. Next, a 4 mm diameter × 4 mm length, 0.018" microcoil (VortX Tornado Coil; Boston Scientific) was placed via the microcatheter into the left phrenic vein. The microcatheter was extended a few centimeters into the portosystemic shunt and portal pressure reassessed. The portal pressure increased to 12 mmHg. The procedure was repeated, this time with a smaller (3 mm diameter × 2.5 mm length) microcoil (Figure 1). Portal pressure was again measured and found to be 14 mmHg. A final portal-to-central venous pressure gradient of 3 mmHg was recorded, and the procedure was concluded. The introducer sheath and catheters were removed, and the skin over the jugular entry site was closed with a single interrupted suture. Strong digital pressure was applied to the jugular vein for 20 mins to achieve hemostasis. A final fluoroscopic image was obtained to document implant position (Figure 1). The total contrast dose administered was 2 ml/kg (8.6 ml total). Total procedure time was 120 mins.

The cat recovered without complications in the recovery wards and was discharged 1 day postoperatively. It was prescribed levetiracetam (20 mg/kg PO q8h), metronidazole (10 mg/kg PO q12h), famotidine (1 mg/kg PO q12h) and lactulose (1 ml PO q8h), and was started on a prescription protein-restricted diet (k/d; Hill's Pet Nutrition). The preoperative clinical signs never returned, and the cat never exhibited any other clinical signs attributable to a portosystemic shunt. Recheck bloodwork examinations at 1 month revealed the following: BUN 14 mg/dl (RI 19–35), albumin 3.9 mg/dl (RI 2.7–4.1), protein C 67% (RI 65–120). Bloodwork at 2 months revealed preprandial bile acids of 6.7 µmol/l (no RI) and postprandial bile acids of 67.4 µmol/l (RI 0–10.8). At 5 months the bloodwork revealed a protein C of 131% (RI 65–120). At 312 days post-PTCE, the cat was doing well with no clinical signs, and was receiving levetiracetam (20 mg/kg PO q8h) as well as a prescription protein-restricted diet (k/d; Hill's Pet Nutrition), despite recommendations to discontinue all medications and introduce a high-protein diet.

Discussion

This is the first report of PTCE of a single congenital extrahepatic portosystemic shunt (EHPSS) in a cat. Portosystemic shunts are rare in cats, and surgical treatment is most often accomplished via laparotomy to dissect and attenuate the aberrant vessel with an extravascular device (ie, suture, ameroid constrictor or cellophane band).^{1–4} Reported complication rates associated with open surgery for EHPSS correction in cats

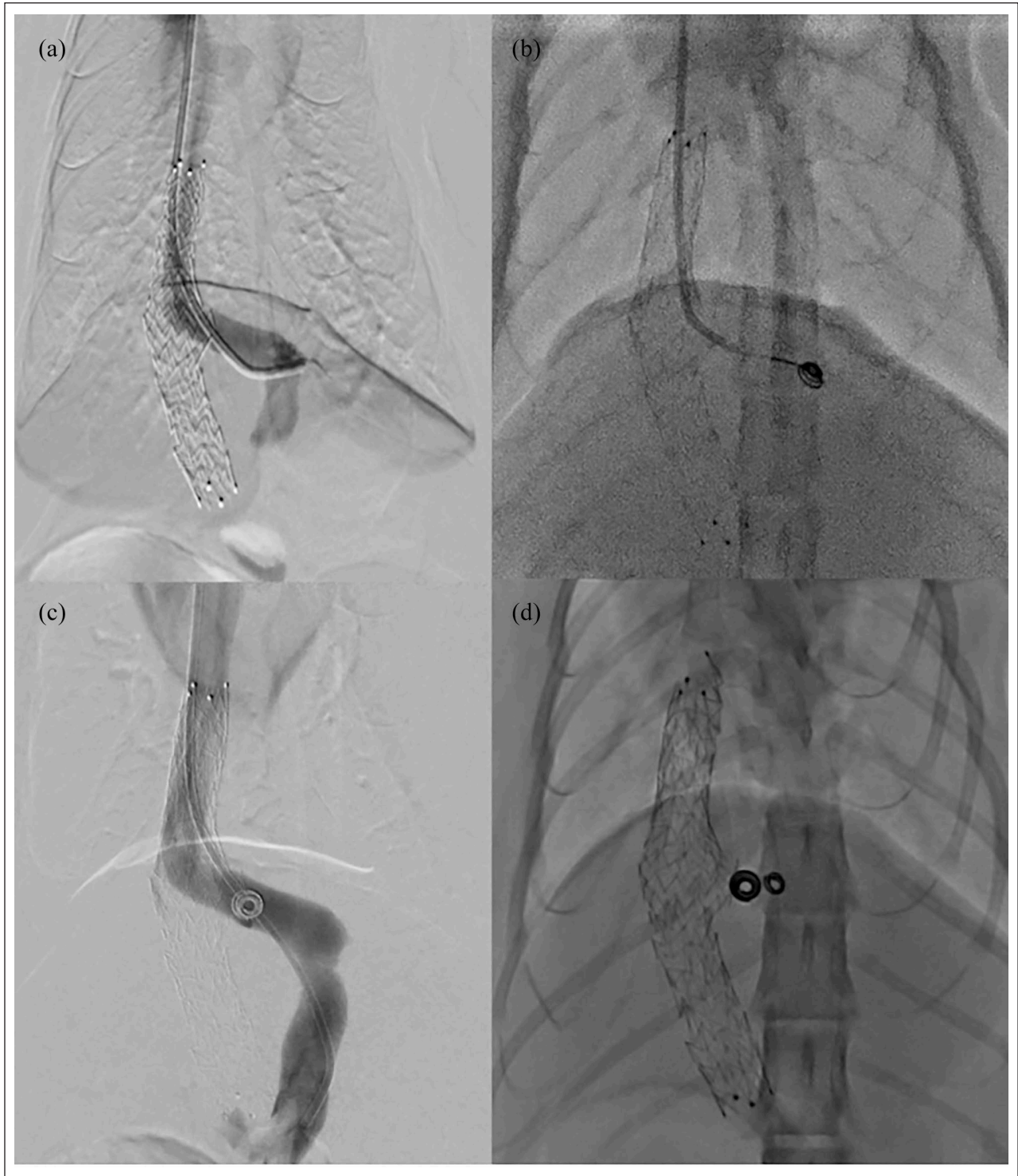


Figure 1 Series of ventrodorsal fluoroscopic images obtained during percutaneous transvenous coil embolization of the cat in this report. (a) A vascular stent is seen in the caudal vena cava along with a 4 F catheter that enters the left phrenic vein across the stent. A portovenogram was performed via injection of contrast, demonstrating the junction of the portal and left phrenic veins. (b) A microcatheter was advanced through the 4 F catheter and a microcoil was deployed at the junction of the left phrenic vein and vascular stent. (c) A portogram was performed following placement of the first microcoil. (d) Ventrodorsal radiograph documenting implant position

range from 32% to 77%, with the majority being neurologic (eg, blindness, seizures and encephalopathy) in nature.¹⁻⁵ Postattenuation neurologic syndrome is the most common cause of mortality in cats undergoing EHPSS attenuation, with mortality rates as high as 22%.^{2,3,5} Given the risk of complications and the technological advancements in surgery over the past few decades, interest in the transvenous embolization of portosystemic shunts has arisen in dogs and, more recently, in cats.^{6,7}

In a recent report, PTCE was successfully used to treat four cats with intrahepatic portosystemic shunts, with promising results.⁷ In 3/4 cats with preoperative neurologic signs, no complications occurred, and all neurologic abnormalities had resolved at the long-term follow-up.⁷ Given this recent success and similarity to the technique previously reported, we performed PTCE in the cat described herein. The procedure itself was nearly identical to that performed in cat 4 by Culp et al.⁷ The use of microcatheters, small vascular stents and microcoils facilitated the procedure. From a technical standpoint, there was minimal difference from previous experience with intrahepatic shunts in cats and toy-breed dogs. In fact, no significant operative complications occurred, and total procedure time was only 2h, which is consistent with that reported by Culp et al.⁷

One interesting consideration for our patient was the degree of portal-to-central venous pressure gradient to create. In dogs, a gradient of no greater than 5–7 mmHg has been proposed and is used commonly.⁸⁻¹⁰ However, given our experience with intrahepatic portosystemic shunts in cats and the relatively small diameter of the vessels being embolized, we elected to be more conservative for this patient, not exceeding a 3 mmHg gradient. In our case, the portal pressure increased significantly with each microcoil, which further influenced this decision. Interestingly, an early report in cats undergoing surgical ligation of EHPSSs revealed that only 2/49 cats died postoperatively, suggesting tolerance to complete attenuation.³ Given this finding, it might have been advisable to attempt further controlled embolization of the shunt in our case by placing additional coils. However, there is typically some degree of progressive attenuation of vessels following PTCE as the thrombus matures, but the degree and rate are unknown. Given the consequences of acute portal hypertension, we elected to be more conservative. In contrast, the final pressure gradient in the report by Culp et al.⁷ was more consistent with previously reported portal-to-central venous pressure gradients in dogs.⁸⁻¹⁰

Gastrophrenic EHPSS is the most common morphology in cats, with a reported incidence as high as 70%.^{11,12} In previous reports, it has been shown that these shunts consistently insert into the systemic circulation via the left phrenic vein at the level of the esophageal hiatus. Typically, for surgical attenuation, it is recommended

that the EHPSS be ligated at the site of connection with the systemic circulation owing to the possibility of additional tributary portal vessels that may insert distally from the attenuation site.^{13,14} For open attenuation techniques, this requires transection of the triangular ligament of the liver for caudal retraction, and adequate visualization and access to the vessel can be challenging, especially in small patients. In our case, rather than attenuating the shunt insertion on the left phrenic vein, we elected to attenuate the insertion of the left phrenic vein on the caudal vena cava as the left phrenic vein length was too short to facilitate placement of a stent. Furthermore, the shape and location of this shunt type is very similar to a left divisional intrahepatic portosystemic shunt inserting on the phrenic vein, which has been reported to occur in 12% of intrahepatic shunt cases, making the technique and approach in this case very similar to what has already been reported.^{11,15}

Additionally, the use of microcoils and microcatheters facilitated placement of thrombogenic coils into the left phrenic vein of our cat. Microcoils were used owing to the concern that placement of larger-diameter coils may result in complete rather than partial attenuation of the shunt, leading to acute portal hypertension. This was based on the authors' personal experience, as well as two previous reports of PTCE for intrahepatic portosystemic shunts in which three individual dogs weighing <10 kg developed acute portal hypertension with the placement of a single 8 mm diameter coil.^{9,10} This resulted in a good outcome, with no residual clinical signs or evidence of persistent shunting.

Conclusions

PTCE was safe and effective for the treatment of an EHPSS in this cat and offers a minimally invasive alternative to traditional, open attenuation techniques. No intra- or postoperative complications occurred, and the cat remained non-clinical for its EHPSS 312 days post-PTCE. Further studies are needed to determine whether PTCE of EHPSS in cats results in improved clinical outcomes when compared with open surgical attenuation.

Conflict of interest The authors declared no potential conflicts of interest with respect to the research, authorship, and/or publication of this article.


Funding The authors received no financial support for the research, authorship, and/or publication of this article.

Ethical approval The work described in this manuscript involved the use of non-experimental (owned or unowned) animals. Established internationally recognised high standards ('best practice') of veterinary clinical care for the individual patient were always followed and/or this work involved the use of cadavers. Ethical approval from a committee was therefore not specifically required for publication in *JFMS Open*

Reports. Although not required, where ethical approval was still obtained, it is stated in the manuscript.

Informed consent Informed consent (verbal or written) was obtained from the owner or legal custodian of all animal(s) described in this work (experimental or non-experimental animals, including cadavers) for all procedure(s) undertaken (prospective or retrospective studies). No animals or people are identifiable within this publication, and therefore additional informed consent for publication was not required.

ORCID iD J Brad Case  <https://orcid.org/0000-0002-3507-7644>

Francesca P Solari  <https://orcid.org/0000-0002-4202-8701>

References

- Valiente P, Trehy M, White R, et al. **Complications and outcome of cats with congenital extrahepatic portosystemic shunts treated with thin film: thirty-four cases (2008–2017).** *J Vet Intern Med* 2020; 34: 117–124.
- Cabassu J, Seim HB, MacPhail CM, et al. **Outcomes of cats undergoing surgical attenuation of congenital extrahepatic portosystemic shunts through cellophane banding: 9 cases (2000–2007).** *J Am Vet Med Assoc* 2011; 238: 89–93.
- Lipscomb VJ, Jones HJ and Brockman DJ. **Complications and long-term outcomes of the ligation of congenital portosystemic shunts in 49 cats.** *Vet Rec* 2007; 160: 465–470.
- Kyles AE, Hardie EM, Mehl M, et al. **Evaluation of ameroid ring constrictors for the management of single extrahepatic portosystemic shunts in cats: 23 cases (1996–2001).** *J Am Vet Med Assoc* 2002; 220: 1341–1347.
- Strickland R, Tivers MS, Fowkes RC, et al. **Incidence and risk factors for neurological signs after attenuation of a single congenital portosystemic shunt in 50 cats.** *Vet Surg* 2021; 50: 303–311.
- Weisse C, Schwartz K, Stronger R, et al. **Transjugular coil embolization of an intrahepatic portosystemic shunt in a cat.** *J Am Vet Med Assoc* 2002; 221: 1287–1291.
- Culp WTN, Griffin MA, Case JB, et al. **Use of percutaneous transvenous coil embolization in the treatment of intrahepatic portosystemic shunts in four cats.** *J Am Vet Med Assoc* 2020; 257: 70–79.
- Weisse C, Berent AC, Todd K, et al. **Endovascular evaluation and treatment of intrahepatic portosystemic shunts in dogs: 100 cases (2001–2011).** *J Am Vet Med Assoc* 2014; 244: 78–94.
- Culp WTN, Zwingenberger AL, Giuffrida MA, et al. **Prospective evaluation of outcome of dogs with intrahepatic portosystemic shunts treated via percutaneous transvenous coil embolization.** *Vet Surg* 2018; 47: 74–85.
- Case JB, Marvel SJ, Stiles MC, et al. **Outcomes of cellophane banding or percutaneous transvenous coil embolization of canine intrahepatic portosystemic shunts.** *Vet Surg* 2018; 47: O59–O66.
- White RN and Parry AT. **Morphology of congenital portosystemic shunts emanating from the left gastric vein in dogs and cats.** *J Small Anim Pract* 2013; 54: 459–467.
- White RN, Shales C and Parry AT. **New perspectives on the development of extrahepatic portosystemic shunts.** *J Small Anim Pract* 2017; 58: 669–677.
- Nelson NC and Nelson LL. **Imaging and clinical outcomes in 20 dogs treated with thin film banding for extrahepatic portosystemic shunts.** *Vet Surg* 2016; 45: 736–745.
- Hunt GB, Culp WTN, Mayhew KN, et al. **Evaluation of *in vivo* behavior of ameroid ring constrictors in dogs with congenital extrahepatic portosystemic shunts using computed tomography.** *Vet Surg* 2014; 43: 834–842.
- Plested MJ, Zwingenberger AL, Brockman DJ, et al. **Canine intrahepatic portosystemic shunt insertion into the systemic circulation is commonly through primary hepatic veins as assessed with CT angiography.** *Vet Radiol Ultrasound* 2020; 61: 519–530.