

CTSK variant implicated in suspected pyknodysostosis in a domestic cat

Authors: Lyraki, Maria, Hibbert, Angie, Langley-Hobbs, Sorrel, Lait, Philippa, Buckley, Reuben M, et al.

Source: Journal of Feline Medicine and Surgery Open Reports, 8(2)

Published By: SAGE Publishing

URL: <https://doi.org/10.1177/20551169221137536>

The BioOne Digital Library (<https://bioone.org/>) provides worldwide distribution for more than 580 journals and eBooks from BioOne's community of over 150 nonprofit societies, research institutions, and university presses in the biological, ecological, and environmental sciences. The BioOne Digital Library encompasses the flagship aggregation BioOne Complete (<https://bioone.org/subscribe>), the BioOne Complete Archive (<https://bioone.org/archive>), and the BioOne eBooks program offerings ESA eBook Collection (<https://bioone.org/esa-ebooks>) and CSIRO Publishing BioSelect Collection (<https://bioone.org/csiro-ebooks>).

Your use of this PDF, the BioOne Digital Library, and all posted and associated content indicates your acceptance of BioOne's Terms of Use, available at www.bioone.org/terms-of-use.

Usage of BioOne Digital Library content is strictly limited to personal, educational, and non-commercial use. Commercial inquiries or rights and permissions requests should be directed to the individual publisher as copyright holder.

BioOne is an innovative nonprofit that sees sustainable scholarly publishing as an inherently collaborative enterprise connecting authors, nonprofit publishers, academic institutions, research libraries, and research funders in the common goal of maximizing access to critical research.



CTSK variant implicated in suspected pyknodysostosis in a domestic cat

Maria Lyraki¹ , Angie Hibbert¹ ,
 Sorrel Langley-Hobbs² , Philippa Lait³,
 Reuben M Buckley⁴, Wesley C Warren⁵
 and Leslie A Lyons⁴ , 99 Lives Consortium*

Journal of Feline Medicine and Surgery Open Reports
 1–9

© The Author(s) 2022

Article reuse guidelines:

sagepub.com/journals-permissions

DOI: 10.1177/20551169221137536

journals.sagepub.com/home/jfmsopenreports

This paper was handled and processed
 by the European Editorial Office (ISFM)
 for publication in *JFMS Open Reports*



Abstract

Case summary A 9-month-old entire male domestic longhair cat presented with a history of pathological fractures, chronic musculoskeletal pain and poor growth. Multiple facial and skeletal abnormalities were identified on physical examination and advanced imaging (CT and radiographs). A variant in *CTSK* was identified in the affected cat following whole-exome sequencing (WES). The cat was managed symptomatically with diet, environmental modifications and analgesia.

Relevance and novel information This is the first report of a cat with a similar clinical presentation and genetic variant to the hereditary human genetic disorder pyknodysostosis. In this case, WES was performed, which often facilitates the diagnosis of various hereditary disorders (ie, a conceptual framework for practicing feline genomic medicine). Despite the severe skeletal and appendicular abnormalities described, the cat was alive more than 2 years after its initial presentation.

Keywords: Whole-exome sequencing; hereditary; pyknodysostosis; pyknodysostosis; cathepsin K

Accepted: 20 October 2022

Case description

A 9-month-old entire male domestic longhair cat was referred with a lifelong history of poor growth, dysphagia, lameness and pathological fractures, and a 3-month history of stertor and bilateral serous ocular discharge. The cat had three episodes of acute pain and lameness after jumping from furniture. A left radioulnar fracture was suspected clinically following the first episode, while a complete right radioulnar fracture was confirmed radiographically following the second episode. The third episode occurred 2 weeks prior to presentation but was not investigated. All episodes were managed conservatively with cage rest and analgesia with meloxicam (0.05 mg/kg PO q24h [Metacam: Boehringer Ingelheim]) and buprenorphine hydrochloride (0.02 mg/kg trans-mucosally q12h [Temgesic; Indivior UK]). The cat was up to date with vaccinations, including feline leukaemia virus (FeLV), was indoor-only, had no travel history outside of the UK and had been fed a home-cooked, fish-based liquid diet due to the dysphagia reported. Prior

to referral, measurement of serum thyroxine (50.8 mmol/l; reference interval [RI] 10–60) and insulin-like growth factor 1 (IGF-1; 747 ng/ml; RI >50) excluded congenital hypothyroidism and juvenile hypsomatotropicism, respectively.

¹The Feline Centre, Langford Vets, Langford, Bristol, UK

²Bristol Veterinary School, University of Bristol, Langford, Bristol, UK

³Molecular Diagnostic Unit, Diagnostic Laboratories, Langford Vets, Langford, Bristol, UK

⁴Department of Veterinary Medicine and Surgery, University of Missouri, Columbia, MO, USA

⁵Department of Animal Sciences, Department of Surgery, Institute of Data Science and Informatics, University of Missouri, Columbia, MO, USA

*See 'Author note' for a full list of members

Corresponding author:

Maria Lyraki DVM, MSc, DipECVIM-CA, MRCVS, Bristol Veterinary School, University of Bristol, Langford House, Langford, Bristol BS40 5DU, UK

Email: maria.lyraki@bristol.ac.uk



Creative Commons Non Commercial CC BY-NC: This article is distributed under the terms of the Creative Commons

Attribution-NonCommercial 4.0 License (<https://creativecommons.org/licenses/by-nc/4.0/>) which permits non-commercial use, reproduction and distribution of the work without further permission provided the original work is attributed as specified on the SAGE and Open Access pages (<https://us.sagepub.com/en-us/nam/open-access-at-sage>).

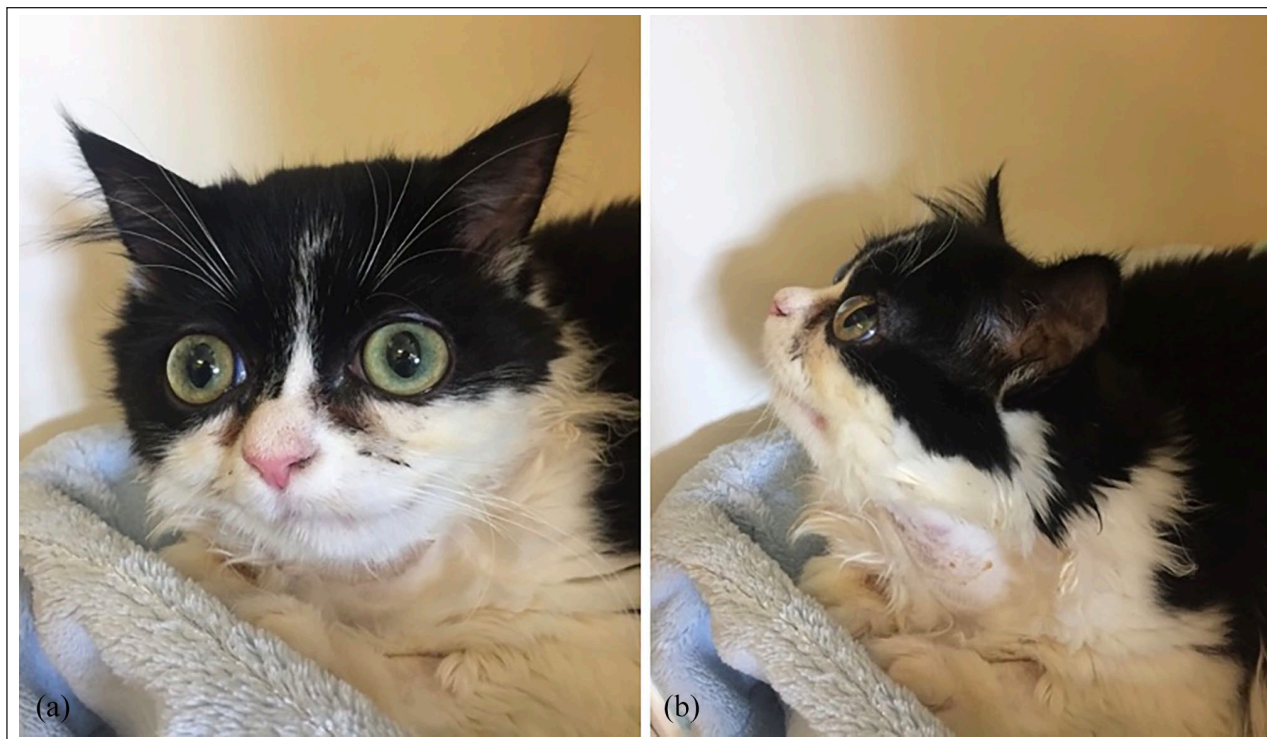

Figure 1 Cat with suspected pyknodysostosis and cathepsin K mutation. (a) Front and (b) side views show the face is asymmetrical with distortion of the nasal bone and brachycephaly, hypertelorism and shallow orbits

On presentation, the cat was bright and alert but was lean (body condition score [BCS] 3/9),¹ with poor muscle development, a kyphotic posture, lameness affecting all four limbs and an asymmetrical face with distortion of the nasal bone and hypertelorism (wide spaced eyes) and shallow orbits (Figure 1). Pain was elicitable in the thoracolumbar area and on hindlimb manipulation. Patellar luxation was present in the right hindlimb (grade IV).² Oral examination revealed multiple persistent deciduous teeth and a cleft palate affecting only the soft palate. Complete ophthalmological examination revealed megalocornea and excessively deep anterior chambers bilaterally but was otherwise unremarkable. Further investigations were performed under general anaesthesia to limit restraint of the cat and the risk of further pathological fractures.

A complete blood count at Langford Vets Diagnostic Laboratories (LVDL) documented abnormalities likely associated with the anaesthesia, including a normocytic, normochromic non-regenerative anaemia (24.4%; RI 27.7–46.8), an absolute reticulocyte count of $0 \times 10^{12}/l$ (RI <50)³ and a mature neutropenia ($2.32 \times 10^9/l$; RI 3–13.4). Serum biochemistry (LVDL) revealed increased alanine aminotransferase (ALT) activity (66 U/l; RI 15–45), alkaline phosphatase (ALP) activity (273 U/l; RI 15–60) and hyperphosphataemia (2.16 mmol/l; RI 0.95–1.55). Ionised calcium (1.22 mmol/l; RI 1.1–1.5) and serum total calcium (2.36 mmol/l; RI 2.3–2.5) were within

normal limits. Serology for FeLV antigen, feline immunodeficiency virus antibodies in blood and feline herpesvirus-1 and feline calicivirus PCR from oropharyngeal samples were all negative. Serum 1,25-dihydroxyvitamin D (248 pmol/l; RI 90–342) and 25-hydroxycholecalciferol (155 nmol/l; RI 127–335) were normal, ruling out hypovitaminosis D. Radiographs of all four limbs revealed multiple severe skeletal abnormalities (Figures 2 and 3), including curvature of the long bones, short diaphyses and angular epiphyses of the metacarpal bones, delayed growth plate closure, right lateral patellar luxation and healed historical fracture sites. CT of the head and spine revealed persistently open skull suture lines and nasal cavity deviation (Figures 4 and 5), as well as retention of multiple deciduous teeth.

The cat was discharged with a plan to gradually transition it to a complete, highly digestible commercial cat food (Feline EN Gastrointestinal; Purina Pro Plan Veterinary Diets) mixed with water to facilitate mastication. Environmental modifications were applied to minimise injury risk, such as keeping the cat indoors and using low-seated furniture. Furthermore, lifelong eye lubrication was prescribed to reduce the risk of corneal injury (q12h [VitaPOS; Ursapharm]), alongside an analgesia plan, titrated based on the Feline Grimace Scale,⁴ consisting of meloxicam (0.05 mg/kg PO q24h [Metacam; Boehringer Ingelheim]) and gabapentin (5 mg/kg PO q12h [Gabapentin; Summit]). A dentistry referral for

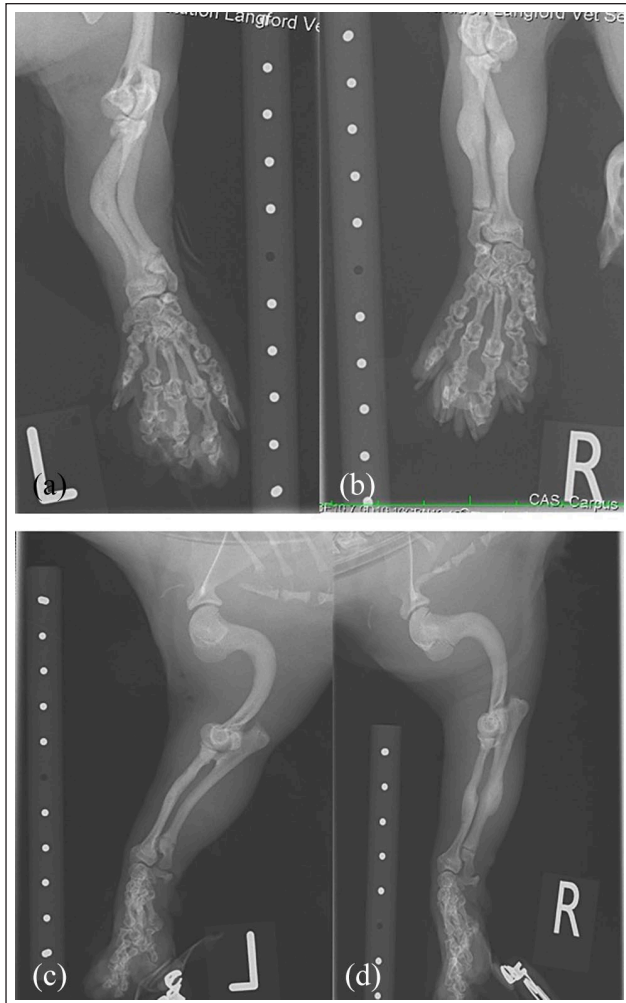


Figure 2 Radiographs of the forelimbs of a cat with suspected pyknodysostosis and cathepsin K mutation. (a) Left and (b) right forelimb anteroposterior images show mild cranial and moderate lateral curvature and thickening of the mid-diaphysis of the radius and ulna with a reduction in the normal medullary cavity. The distal radius and ulna physes appear open. The metacarpal bones and phalanges appear abnormal with very short diaphyses, more angular and wide flared epiphyses. (c,d) The humeri are markedly abnormal in shape with severe caudal curvature of the entire diaphysis, with increased medullary opacity similar to the cortical opacity

management of the deciduous teeth was offered but declined by the owners.

The cat was re-presented 1 month later for a scheduled recheck and was reported to have been well in the interim. No further episodes of pain or lameness were reported, and transition to the commercial cat food had been successful. The cat had gained 150g in weight, had an improved BCS (4/9) and appeared comfortable on limb manipulation. The remainder of the physical examination was unchanged. Repeat complete blood count

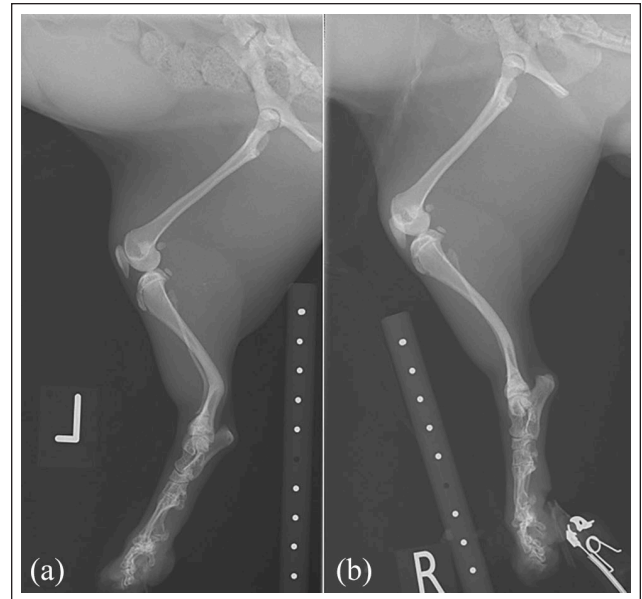


Figure 3 Hindlimb radiographs of a cat with suspected pyknodysostosis and cathepsin K mutation. (a) The left and (b) right hindlimbs have severe curvature in the distal diaphysis of the left tibia and fibula and moderate curvature in the distal diaphysis of the right tibia and fibula. The femoral diaphyses are abnormally thin. The right patella is positioned distally and is superimposed over the distal femur compatible with grade IV patella luxation

(LVDL) documented borderline leukocytosis ($20 \times 10^9/l$; RI 6.3–19.6) and associated lymphocytosis ($9.6 \times 10^9/l$; RI 2–7.2). Serum biochemistry (LVDL) was similar, with increased ALT activity (60 U/l; RI 15–45), ALP activity (240 U/l; RI 15–60), hyperphosphataemia (2.29 mmol/l; RI 0.95–1.55) and normal total calcium (2.51 mmol/l; RI 2.3–2.5). On the most recent communication with the owners, 2 years after the initial presentation, the cat was reported to be doing well, with no further episodes of fractures.

The cat's clinical picture, appearance and imaging abnormalities were clinically similar to pyknodysostosis, a rare human disease caused by variations in *CTSK*. Cat DNA samples were donated by the owner and archived in accordance with LVDL protocol and the University of Missouri Institutional Animal Care and Use Committee protocol (study protocols 9056, 9178 and 9642). DNA was isolated from the whole blood sample by organic extraction, and approximately 2.9 µg was submitted to whole-exome sequencing (WES), which was performed as previously described.⁵ *Felis catus* 9.0 reference alignment⁶ and Ensembl 94 gene annotation were used, as previously reported.⁵ The variant call file was combined with variants determined from 39 additional cats with WES data. Variant data were analysed using VarSeq software (GoldenHelix) by assuming the affected

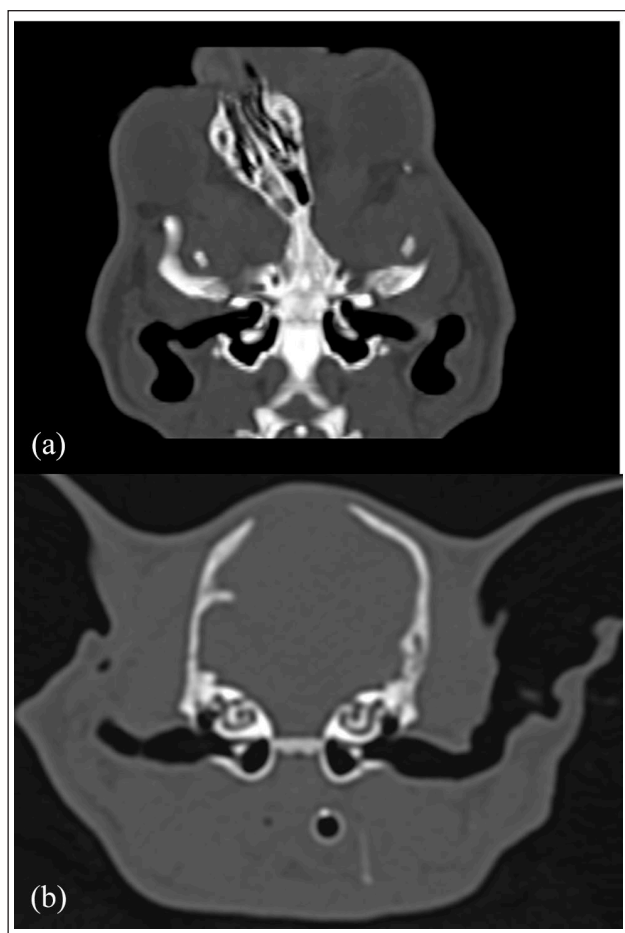


Figure 4 CT of a cat with suspected pyknodysostosis and cathepsin K mutation. (a) Dorsal plane of the cat's skull shows marked deviation of the nasal septum. (b) Transverse plane of the cat's skull shows a large defect at the level of the fontanelle, between the frontal and parietal bones

cat was homozygous for a causal variant and no other cat in the data set had the variant present. The cat WES data set contained over 1 million variants; 109,688 were homozygous in the case, of which 2344 were private variants. Thirty-six high-impact variants altering protein coding, including a stop gain (termination codon) variant in a candidate gene (*CTSK*), were identified. The *CTSK* variant at position C1:105945826 in the *Felis catus* cat genome assembly Version 9.0⁶ is a c.724C>T in transcript ENSFCAT00000003643, causing a p.Arg242Ter (see Figure 1 in the supplementary material). The depth of read for the variant was high ($n = 158$). The candidate variant was validated by direct Sanger sequencing conducted at the University of Missouri DNA Core Facility using an Applied Biosystems 3730xl DNA Analyzer with a BigDye Terminator v3.1 Cycle Sequencing Kit (Applied Biosystems). DNA sequences were visualised with Sequencer (GeneCodes).

The identified variant was also absent in the 99 Lives data set that includes whole-genome sequencing (WGS)

data from 195 cats.⁶ All of the sequence variants unique to the affected cat are included in the supplementary file, as well as all variants identified in *CTSK* in the data set.⁷ All *CTSK* variants following the Human Genome Variation Society nomenclature are summarised in Table 1. Exome sequencing data are available at the Sequence Read Archive under accession number PRJNA627536. The sequence for the 195 cat analysis of the 99 Lives Cat Genome Sequencing Project was submitted to the NCBI short-read archive under BioProject PRJNA627536; SAMN14675162; SRS6521458; with the accession for this case as SRX8159688.⁸ Protein-coding alignment of *CTSK* was produced using Protein Variation Effect Analyzer (PROVEAN)^{9,10} and cat *CTSK* has 93% identity to the human *CTSK* transcript (see Figure 2 in the supplementary material).

Discussion

In humans, pyknodysostosis is a rare autosomal recessive bone disorder (OMIM: 265800) caused by a variation in *CTSK*.¹¹ The disease is characterised by multiple musculoskeletal abnormalities, including short stature, osteosclerosis with increased bone fragility, facial dysmorphism, persistent deciduous teeth and large fontanels with delayed closure of sutures.¹² To our knowledge, this is the first report of a cat with very similar skeletal abnormalities and concurrent associated *CTSK* variation identified in genome sequencing.

Pyknodysostosis is a severely debilitating disease in humans, causing a variety of complications, including pathological fractures, craniosynostosis and respiratory, sleep and dental problems.¹³ Patients with a more severe phenotype may die at a very young age.¹⁴ The cat in this case report suffered from similar complications, including pathological fractures, chronic musculoskeletal and oral pain. The severe conformational abnormalities reported likely contributed to the additional ocular and upper respiratory signs seen in this cat. In addition, the serum biochemistry revealed increases in ALP and phosphate that may have been age related or due to the increased osteoblastic activity associated with healing fractures and the unbalanced home-cooked diet.

Based on the human literature, no specific treatment is available for pyknodysostosis and affected patients are managed symptomatically.¹³ In this case, the cat was managed with long-term analgesia and environmental modifications, to prevent further injury, and diet modifications, to combat dysphagia. Regular dental care and deciduous tooth extractions were recommended, but the owner declined these due to the risk of mandibular fracture and the post-extraction osteomyelitis reported in humans with the disease.¹⁵ Regular recheck appointments were scheduled to ensure that the cat's quality of life was maintained and to adjust treatment as necessary. Euthanasia should be considered in cases where chronic pain cannot be addressed effectively.

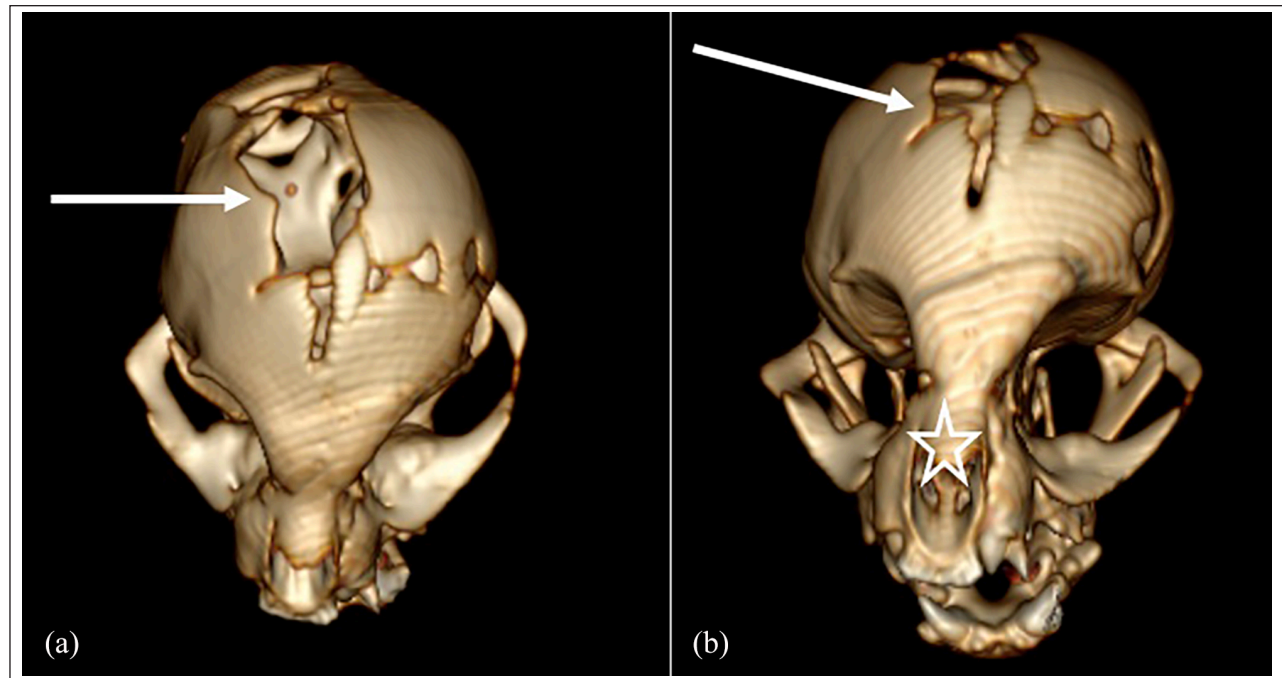


Figure 5 Three-dimensional CT reconstruction of the skull of a cat with suspected pyknodysostosis and cathepsin K mutation. (a) Dorsal plane of the cat's skull shows a large defect at the level of the fontanelle between the frontal and parietal bones (arrow). (b) Dorsal plane of the cat's skull shows a large defect at the level of the fontanelle (arrow) and marked deviation of the nasal septum (star)

IGF-1 was found to be low in eight paediatric patients with pyknodysostosis and short stature vs normal age-matched children with a constitutional short stature, likely owing to concurrent pituitary hypoplasia.¹⁶ In the same study, IGF-1 levels and the children's growth clinically improved significantly after treatment with growth hormone. In contrast, this cat had normal IGF-1 levels and therefore juvenile hyposomatotropism was considered unlikely, although a growth hormone stimulation test and MRI of the brain were not performed.

Cathepsin K (OMIM: 601105) is a member of the papain family of cysteine proteinases and has an important role in osteoclast function.¹⁷ Approximately 70 *CTSK* variants described in ClinVar are implicated in human pyknodysostosis, of which 41 are considered pathogenic, or likely pathogenic (Table 1).¹⁸ A knockout model for *CTSK* in mice has many of the phenotypic features of pyknodysostosis, including increased bone density and bone deformity.¹⁹ In an American Hispanic patient with pyknodysostosis and non-consanguineous parents, heteroallelism for the G146R mutation (NM_000396.4[*CTSK*]:c.436G>C [p.Gly146Arg]) and a C-to-T transition of a CpG dinucleotide at nucleotide 826 of the cDNA sequence was found (NM_000396.4[*CTSK*]:c.721C>T [p.Arg241Ter]), predicting an arginine at protein position 241 change to a termination codon (R241X) nonsense mutation, which is likely the same position as identified in the cat (see Figure 2 in the supplementary material).¹⁷

The long-read assembly of the domestic cat genome⁶ has been used to identify DNA sequence variants that might be associated with pyknodysostosis in the cat in this report.^{5,20} As with genome approaches in human medicine, the success of the WES approach for identifying disease-associated sequence variants is highly dependent on the heritability and frequency of the disease. In this case, WES was conducted on a solitary cat. The collaborative efforts of the cat genetics community have produced the WGS 99 Lives data set that complements exome data evaluations and has also facilitated identification of sequence variants associated with other feline hereditary disorders, supporting precision/genome medicine healthcare for domestic cats.^{21,22} At the time of writing this case report, both genome approaches are commercially available. Currently, WGS costs around US\$800–\$1000, while WES costs substantially less (around US\$200–\$300).

A few limitations apply to this case report. First, other congenital bone disorders reported in humans were not excluded in this case, including cleidocranial dysostosis, acro-osteolysis (also known as Hajdu–Cheney syndrome), osteogenesis imperfecta and osteopetrosis.²³ Nevertheless, these were considered unlikely based on the clinical findings. In cleidocranial dysostosis, for example, the clavicle is predominantly involved, while this bone is rarely affected in pyknodysostosis.²⁴ Furthermore, acro-osteolysis is not expected to involve facial bones,²⁵ and osteopetrosis is usually associated

Table 1 All private *CTSK* variants following Human Genome Variation Society (HGVS) nomenclature

Chromosome: position	Ref/alt	Allele counts	Allele frequencies	No. of alleles	No. of hetero	No. of homo	Sequence ontology	Effect	HGVS c (cDNA)	HGVS p (protein)	Exon	Distance of transcript (%)
C1:105944311	C/T	1	0.0125	80	1	0	Intron_variant	Other	ENSFCAT000000003643:c.894-49G>A		8	
C1:105945321	C/T	43	0.5375	80	19	12	Intron_variant	Other	ENSFCAT000000003643:c.893+73G>A		7	
C1:105945347	G/A	2	0.025	80	2	0	Intron_variant	Other	ENSFCAT000000003643:c.893+47C>T		7	
C1:105945453	T/C	1	0.0125	80	1	0	Synonymous_variant	Other	ENSFCAT000000003643:c.834A>G	p.Ala278=	7	83.8872
C1:105945516	C/T	1	0.0125	80	1	0	Intron_variant	Other	ENSFCAT000000003643:c.788-17G>A		7	
C1:105945532	G/-	1	0.0125	80	1	0	Intron_variant	Other	ENSFCAT000000003643:c.788-33delC		7	
C1:105945562	C/T	1	0.0125	80	1	0	Intron_variant	Other	ENSFCAT000000003643:c.788-63G>A		7	
C1:105945563	A/G	1	0.0125	80	1	0	Intron_variant	Other	ENSFCAT000000003643:c.788-64T>C		7	
C1:105945702	G/A	1	0.0125	80	1	0	Intron_variant	Other	ENSFCAT000000003643:c.787+61C>T		6	
C1:105945725	G/A	25	0.3125	80	15	5	Intron_variant	Other	ENSFCAT000000003643:c.787+38C>T		6	
C1:105945734	C/G	1	0.0125	80	1	0	Intron_variant	Other	ENSFCAT000000003643:c.787+29G>C		6	
C1:105945746	A/C	1	0.0125	80	1	0	Intron_variant	Other	ENSFCAT000000003643:c.787+17T>G		6	
C1:105945826	G/A	2	0.025	80	0	1	Stop_gained	LoF	ENSFCAT000000003643:c.724C>T	p.Arg242Ter	6	72.8097
C1:105945848	T/-	80	1	80	0	40	Splice_acceptor_variant	LoF	ENSFCAT000000003643:c.702+1delA		5	
C1:105945876	A/G	1	0.0125	80	1	0	Synonymous_variant	Other	ENSFCAT000000003643:c.675T>C	p.Tyr225=	5	67.8751
C1:105949867	G/C	1	0.0125	80	1	0	Intron_variant	Other	ENSFCAT000000003643:c.621+38C>G		4	
C1:105949894	G/A	1	0.0125	80	1	0	Intron_variant	Other	ENSFCAT000000003643:c.621+11C>T		4	
C1:105950155	G/A	1	0.0125	80	1	0	Intron_variant	Other	ENSFCAT000000003643:c.403-32C>T		4	
C1:105951023	A/G	1	0.0125	80	1	0	Intron_variant	Other	ENSFCAT000000003643:c.402+90T>C		3	
C1:105951040	T/C	28	0.35	80	18	5	Intron_variant	Other	ENSFCAT000000003643:c.402+73A>G		3	
C1:105951045	G/A	1	0.0125	80	1	0	Intron_variant	Other	ENSFCAT000000003643:c.402+68G>T		3	
C1:105951061	A/C	1	0.0125	80	1	0	Intron_variant	Other	ENSFCAT000000003643:c.402+52T>G		3	
C1:105951157	T/C	1	0.0125	80	1	0	Missense_variant	Missense	ENSFCAT000000003643:c.358A>G	p.Ile120Val	3	35.9517
C1:105951484	G/T	2	0.025	80	2	0	Splice_region_variant	Other	ENSFCAT000000003643:c.124-8C>A		2	
C1:105951516	-/TACA	1	0.0125	80	1	0	Intron_variant	Other	ENSFCAT000000003643:c.124-43_124-40dupTGTA		2	
C1:105951529	A/-	1	0.0125	80	1	0	Intron_variant	Other	ENSFCAT000000003643:c.124-53delT		2	
C1:105951875	G/A	1	0.0125	80	1	0	Intron_variant	Other	ENSFCAT000000003643:c.123+71C>T		1	
C1:105951898	C/G	1	0.0125	80	1	0	Intron_variant	Other	ENSFCAT000000003643:c.123+48G>C		1	
C1:105951908	G/A	1	0.0125	80	1	0	Intron_variant	Other	ENSFCAT000000003643:c.123+38C>T		1	
C1:105951921	C/T	1	0.0125	80	1	0	Intron_variant	Other	ENSFCAT000000003643:c.123+25G>A		1	
C1:105951923	-/CTT	1	0.0125	80	1	0	Intron_variant	Other	ENSFCAT000000003643:c.123+21_123+23dupAAG		1	
C1:105951951	T/C	1	0.0125	80	1	0	Missense_variant	Missense	ENSFCAT000000003643:c.118A>G	p.Asn40Asp	1	11.7825
C1:105951964	C/T	1	0.0125	80	1	0	Synonymous_variant	Other	ENSFCAT000000003643:c.105G>A	p.Gly35=	1	10.4733
C1:105951982	T/A	1	0.0125	80	1	0	Synonymous_variant	Other	ENSFCAT000000003643:c.87A>T	p.Leu29=	1	8.66062
C1:105952007	A/G	1	0.0125	80	1	0	Missense_variant	Missense	ENSFCAT000000003643:c.62T>C	p.Val21Ala	1	6.143
C1:105952050	G/T	1	0.0125	80	1	0	Missense_variant	Missense	ENSFCAT000000003643:c.19C>A	p.Leu7Ile	1	1.81269
C1:105945848	T/-	388	1	388	0	194	Splice_acceptor_variant	LoF	ENSFCAT000000003643:c.702+1delA		5	
C1:105952056	T/G	2	0.00518135	386	0	1	Missense_variant	Missense	ENSFCAT000000003643:c.13A>C	p.Lys5Gln	1	1.20846
C1:105951157	T/C	1	0.00259067	386	1	0	Missense_variant	Missense	ENSFCAT000000003643:c.358A>G	p.Ile120Val	3	35.9517
C1:105951210	C/T	1	0.0025641	390	1	0	Missense_variant	Missense	ENSFCAT000000003643:c.305G>A	p.Arg102His	3	30.6143
C1:105951951	T/C	1	0.00257732	388	1	0	Missense_variant	Missense	ENSFCAT000000003643:c.118A>G	p.Asn40Asp	1	11.7825
C1:105952050	G/T	1	0.00259067	386	1	0	Missense_variant	Missense	ENSFCAT000000003643:c.19C>A	p.Leu7Ile	1	1.81269
C1:105952007	A/G	2	0.00515464	388	2	0	Missense_variant	Missense	ENSFCAT000000003643:c.62T>C	p.Val21Ala	1	6.143
C1:105951484	G/T	9	0.0230769	390	5	2	Splice_region_variant	Other	ENSFCAT000000003643:c.124-8C>A		2	

Ref = reference (the allele in the reference genome); alt = alternative (any other allele found at that locus); hetero = heterozygous; homo = homozygous; LoF = loss of function

with severe anaemia and hepatosplenomegaly, which were absent in this case.²⁶ A further limitation is that genome sequencing of the cat's parents was not available to confirm the significance of the *CTSK* variant identified (the owner did not consent to them being tested). In addition, the remaining private DNA variants of the case could be valid causal mutations. Nevertheless, the relevant variant was not present in any other WGS of the 99 Lives data set and, alongside the compatible clinical signs, was strongly suggestive of the disease. Finally, the home-cooked diet may have also contributed to the clinicopathological abnormalities identified, for example due to phosphate imbalance or nutritional hyperparathyroidism, although the phosphate did not improve after the diet change and the clinical signs predated the start of this diet. Nevertheless, measurement of parathyroid hormone levels would have been useful to exclude nutritional hyperparathyroidism in this case.

Conclusions

To our knowledge, this is the first report of suspected pyknodysostosis in a cat. The diagnosis was reached by WGS identification of a *CTSK* variant, a technique that is able to facilitate the diagnosis of various hereditary disorders and support precision medicine healthcare in domestic cats. Although pyknodysostosis is a severely debilitating disease, a reasonable quality of life may be achieved with appropriate symptomatic management.

Acknowledgements We appreciate the laboratory assistance of Thomas R Juba, Juan A Valencia and the 99 Lives Cat Genome Consortium (felinegenetics.missouri.edu) for sharing domestic cat variant frequency information, and the assistance of Chris Warren Smith (Langford Vets) for the creation of the CT images. Our thanks to the owners of the cat that was the subject of this study for allowing us to collect samples from their pet, and the primary veterinarian for referring the case.

Author note The 99 Lives Consortium consists of the following members: Danielle Aberdein (School of Veterinary Science, Massey University, New Zealand); Paulo C Alves (CIBIO/InBIO, Centro de Investigação em Biodiversidade e Recursos Genéticos/InBIO Associate Lab and Faculdade de Ciências, Universidade do Porto, Portugal); Wildlife Biology Program, University of Montana, USA); Asa Ohlsson Andersson (Department of Clinical Sciences, Faculty of Veterinary Medicine and Animal Science, Swedish University of Agricultural Sciences, Sweden); Gregory S Barsh (HudsonAlpha Institute for Biotechnology, USA; Department of Genetics, Stanford University, USA); Rebecca R Bellone (Veterinary Genetics Laboratory, University of California – Davis, USA; Department of Population Health and Reproduction, University of California – Davis, USA); Tomas F Bergström (Department of Animal Breeding and Genetics, Swedish University of Agricultural Sciences, Sweden); Adam R Boyko (Department of Biomedical Sciences, College of Veterinary Medicine,

Cornell University, USA); Jeffrey A Brockman (Hill's Pet Nutrition, USA); Margret L Casal (Reproduction and Pediatrics, School of Veterinary Medicine, University of Pennsylvania, USA); Marta G Castelhana (Department of Clinical Sciences, College of Veterinary Medicine, Cornell University, USA); Ottmar Distl (Institute for Animal Breeding and Genetics, University of Veterinary Medicine Hannover, Germany); Nicholas H Dodman (Department of Clinical Sciences, Cummings School of Veterinary Medicine, Tufts University, USA); N Matthew Ellinwood (National MPS Society, USA); Jonathan E Fogle (Department of Population Health and Pathobiology, College of Veterinary Medicine, North Carolina State University, USA); Oliver P Forman (Waltham Centre for Pet Nutrition, UK); Dorian J Garrick (Al Rae Centre of Genetics and Breeding, Massey University, New Zealand); Edward I Ginns (Department of Psychiatry, University of Massachusetts Medical School, USA); Bianca Haase (Sydney School of Veterinary Science, Faculty of Science, University of Sydney, Australia); Jens Häggström (Department of Clinical Sciences, Faculty of Veterinary Medicine and Animal Science, Swedish University of Agricultural Sciences, Sweden); Robert J Harvey (School of Health and Behavioural Sciences, University of the Sunshine Coast, Australia); Daisuke Hasegawa (Laboratory of Veterinary Radiology, Nippon Veterinary and Life Science University, Japan); Isabel Hernandez (Pediatrics and Medical Genetics Service, College of Veterinary Medicine, Cornell University, USA); Marjo K Hytönen (Department of Veterinary Biosciences and Department of Medical and Clinical Genetics, University of Helsinki and Folkhälsan Research Center, Finland); Christopher B Kaelin (HudsonAlpha Institute for Biotechnology, USA; Department of Genetics, Stanford University, USA); Maria Kaukonen (Department of Veterinary Biosciences and Department of Medical and Clinical Genetics, University of Helsinki and Folkhälsan Research Center, Finland); Tomoki Kosho (Department of Medical Genetics, Shinshu University School of Medicine, Japan); Teri L Lear (Department of Veterinary Science, University of Kentucky, USA [in memoriam]); Emilie Leclerc (SPF, Diana Pet Food, Symrise Group, France); Tosso Leeb (Vetsuisse Faculty, Institute of Genetics, University of Bern, Switzerland); Ronald HL Li (Department of Surgical and Radiological Sciences, School of Veterinary Medicine, University of California Davis, USA); Hannes Lohi (Department of Veterinary Biosciences and Department of Medical and Clinical Genetics, University of Helsinki and Folkhälsan Research Center, Finland); Maria Longeri (Dipartimento di Medicina Veterinaria, University of Milan, Italy); Mark A Magnuson (Departments of Molecular Physiology and Biophysics, Cell and Developmental Biology, and Medicine, Vanderbilt University School of Medicine, USA); Richard Malik (Centre for Veterinary Education, University of Sydney, Australia); Shrinivasrao P Mane (Elanco Animal Health, USA); John S Munday (School of Veterinary Science, Massey University, New Zealand); William J Murphy (Department of Veterinary Integrative Biosciences, College of Veterinary Medicine, Texas A&M University, USA); Alexandra N Myers (Department of Veterinary Integrative Biosciences, College of Veterinary Medicine, Texas A&M University, USA); Niels C Pedersen (Department of Medicine and Epidemiology, School of Veterinary Medicine, University of California at Davis, USA); Simon M Peterson-Jones (Small

Animal Clinical Sciences, College of Veterinary Medicine, Michigan State University, USA); Max F Rothschild (Department of Animal Science, College of Agriculture and Life Sciences, Iowa State University, USA); Clare Rusbridge (School of Veterinary Medicine, Faculty of Health & Medical Sciences, University of Surrey, UK); Beth Shapiro (Department of Ecology and Evolutionary Biology, University of California, USA); Joshua A Stern (Department of Medicine and Epidemiology, School of Veterinary Medicine, University of California at Davis, USA); William F Swanson (Center for Conservation and Research of Endangered Wildlife [CREW], Cincinnati Zoo & Botanical Garden, USA); Karen A Terio (Zoological Pathology Program, University of Illinois, USA); Rory J Todhunter (Department of Clinical Sciences, College of Veterinary Medicine, Cornell University, USA); Wesley C Warren (Division of Animal Sciences, College of Agriculture, Food and Natural Resources, School of Medicine, University of Missouri, USA); Elizabeth A Wilcox (Department of Clinical Sciences, College of Veterinary Medicine, Cornell University, USA); Julia H Wildschutte (Department of Biological Sciences, Bowling Green State University, USA); Yoshihiko Yu (Laboratory of Veterinary Radiology, Nippon Veterinary and Life Science University, Japan).

Conflict of interest The authors declared no potential conflicts of interest with respect to the research, authorship, and/or publication of this article.

Funding Funding for the whole-genome sequencing was provided by the Gilbreath McLorn Endowment and donations to the 99 Lives project, EveryCat Health Foundation (formerly the Winn Feline Foundation), the Miller Trust (MT18-009; MTW18-009) (LAL) and Mars Wisdom Health (RMB).

Ethical approval The work described in this manuscript involved the use of non-experimental (owned or unowned) animals. Established internationally recognised high standards ('best practice') of veterinary clinical care for the individual patient were always followed and/or this work involved the use of cadavers. Ethical approval from a committee was therefore not specifically required for publication in *JFMS Open Reports*. Although not required, where ethical approval was still obtained, it is stated in the manuscript.

Informed consent Informed consent (verbal or written) was obtained from the owner or legal custodian of all animal(s) described in this work (experimental or non-experimental animals, including cadavers) for all procedure(s) undertaken (prospective or retrospective studies). For any animals or people individually identifiable within this publication, informed consent for their use in the publication (verbal or written) was obtained from the people involved.

ORCID iD Maria Lyraki  <https://orcid.org/0000-0003-3566-1477>

Angie Hibbert  <https://orcid.org/0000-0003-4752-9246>

Sorrel Langley-Hobbs  <https://orcid.org/0000-0003-4397-5150>

Leslie A Lyons  <https://orcid.org/0000-0002-1628-7726>

Supplemental material The following files are available online:

Supplementary Figure 1: *CTSK* variants in cat whole-genome sequences.

Supplementary Figure 2: Protein alignment of human and cat *CTSK*.

Supplementary file: All sequence variants unique to the affected cat, as well as all variants identified in *CTSK* in the data set.

References

- 1 Bjornvad CR, Nielsen DH, Jane Armstrong P, et al. **Evaluation of a nine-point body condition scoring system in physically inactive pet cats.** *Am J Vet Res* 2011; 72: 433–437.
- 2 Loughin CA, Kerwin SC, Hosgood G, et al. **Clinical signs and results of treatment in cats with patellar luxation: 42 cases (1992–2002).** *J Am Vet Med Assoc* 2006; 228: 1370–1375.
- 3 Weiss DJ and Wardrop KJ. *Schalm's veterinary hematology*. 6th ed. Chichester: Wiley-Blackwell, 2010, p 153.
- 4 Evangelista MC, Watanabe R, Leung VSY, et al. **Facial expressions of pain in cats: the development and validation of a Feline Grimace Scale.** *Sci Rep* 2019; 9: 19128. DOI: 10.1038/s41598-019-55693-8.
- 5 Rodney AR, Buckley RM, Fulton RS, et al. **A domestic cat whole exome sequencing resource for trait discovery.** *Sci Rep* 2021; 11. DOI: 10.1038/s41598-021-86200-7.
- 6 Buckley RM, Davis BW, Brashear WA, et al. **A new domestic cat genome assembly based on long sequence reads empowers feline genomic medicine and identifies a novel gene for dwarfism.** *PLoS Genet* 2020; 16. DOI: 10.1371/journal.pgen.1008926.
- 7 Jaffey JA, Reading NS, Giger U, et al. **Clinical, metabolic, and genetic characterization of hereditary methemoglobinemia caused by cytochrome b5 reductase deficiency in cats.** *J Vet Intern Med* 2019; 33: 2725–2731.
- 8 Du C, Pusey BN, Adams CJ, et al. **Explorations to improve the completeness of exome sequencing.** *BMC Med Genomics* 2016; 9: 56. DOI: 10.1186/s12920-016-0216-3.
- 9 Choi Y, Sims GE, Murphy S, et al. **Predicting the functional effect of amino acid substitutions and indels.** *PLoS One* 2012; 7. DOI: 10.1371/journal.pone.0046688.
- 10 Choi Y. **A fast computation of pairwise sequence alignment scores between a protein and a set of single-locus variants of another protein.** <https://dl.acm.org/doi/10.1145/2382936.2382989> (2012, accessed 3 November 2022).
- 11 Online Mendelian Inheritance in Man. **Pycnodysostosis.** <https://www.omim.org/entry/265800#15> (2019, accessed 2 April 2021).
- 12 Xue Y, Cai T, Shi S, et al. **Clinical and animal research findings in pycnodysostosis and gene mutations of cathepsin K from 1996 to 2011.** *Orphanet J Rare Dis* 2011; 6: 20. DOI: 10.1186/1750-1172-6-20.
- 13 Turan S. **Current research on pycnodysostosis.** *Intractable Rare Dis Res* 2014; 3: 91–93.
- 14 Caracas HP, Figueiredo PS, Mestrinho HD, et al. **Pycnodysostosis with craniosynostosis: case report of the craniofacial and oral features.** *Clin Dysmorphol* 2012; 21: 19–21.

- 15 Van Merkesteyn JP, Bras J, Vermeeren JI, et al. **Osteomyelitis of the jaws in pycnodysostosis.** *Int J Oral Maxillofac Surg* 1987; 16: 615–519.
- 16 Soliman AT, Ramadan MA, Sherif A, et al. **Pycnodysostosis: clinical, radiologic and endocrine evaluation and linear growth after growth hormone therapy.** *Metabolism* 2001; 50: 905–911.
- 17 Gelb BD, Shi GP, Chapman HA, et al. **Pycnodysostosis, a lysosomal disease caused by cathepsin K deficiency.** *Science* 1996; 273: 1236–1238.
- 18 The ClinVar database at NCBI archives. **Pyknodysostosis.** <https://www.ncbi.nlm.nih.gov/clinvar/?term=pyknodysostosis> (accessed 2 April 2021).
- 19 Lazner F, Gowen M, Pavasovic D, et al. **Osteopetrosis and osteoporosis: two sides of the same coin.** *Hum Mol Genet* 1999; 8: 1839–1846.
- 20 Katz ML, Buckley RM, Biegen V, et al. **Neuronal ceroid lipofuscinosis in a domestic cat associated with a DNA sequence variant that creates a premature stop codon in CLN6.** *G3 (Bethesda)* 2020; 10: 2741–2751.
- 21 Buckley RM, Gandolfi B, Creighton EK, et al. **Werewolf, there wolf: variants in *Hairless* associated with hypotrichia and roaning in the Lykoi cat breed.** *Genes* 2020; 11: 682. DOI: 10.3390/genes11060682.
- 22 Yu Y, Creighton EK, Buckley RM, et al. **A deletion in *GDF7* is associated with a heritable forebrain commissural malformation concurrent with ventriculomegaly and interhemispheric cysts in cats.** *Genes* 2020; 11: 672. DOI: 10.3390/genes11060672.
- 23 Sedano HD, Gorlin RJ and Anderson VE. **Pycnodysostosis: clinical and genetic considerations.** *Am J Dis Child* 1968; 116: 70–77.
- 24 Dhiman NK, Singh AK, Sharma NK, et al. **Cleidocranial dysplasia.** *Natl J Maxillofac Surg* 2014; 5: 206–208.
- 25 Samuel SS, Shetty S, Arunachal G, et al. **Hajdu Cheney syndrome.** *J Clin Diagn Res* 2016; 10: OD07–OD09. DOI: 10.7860/JCDR/2016/15782.7203.
- 26 Wilson CJ and Vellodi A. **Autosomal recessive osteopetrosis: diagnosis, management, and outcome.** *Arch Dis Child* 2000; 83: 449–445.