



A case of feline gastrointestinal eosinophilic sclerosing fibroplasia associated with fungal colonisation: endoscopic features, treatment and follow-up

Authors: Martineau, Michael, Tilmant, Cyril, Risco Castillo, Veronica, Guillot, Jacques, Reyes-Gomez, Edouard, et al.

Source: Journal of Feline Medicine and Surgery Open Reports, 9(1)

Published By: SAGE Publishing

URL: <https://doi.org/10.1177/20551169231165246>

BioOne Complete (complete.BioOne.org) is a full-text database of 200 subscribed and open-access titles in the biological, ecological, and environmental sciences published by nonprofit societies, associations, museums, institutions, and presses.

Your use of this PDF, the BioOne Complete website, and all posted and associated content indicates your acceptance of BioOne's Terms of Use, available at www.bioone.org/terms-of-use.

Usage of BioOne Complete content is strictly limited to personal, educational, and non - commercial use. Commercial inquiries or rights and permissions requests should be directed to the individual publisher as copyright holder.

BioOne sees sustainable scholarly publishing as an inherently collaborative enterprise connecting authors, nonprofit publishers, academic institutions, research libraries, and research funders in the common goal of maximizing access to critical research.



A case of feline gastrointestinal eosinophilic sclerosing fibroplasia associated with fungal colonisation: endoscopic features, treatment and follow-up

Journal of Feline Medicine and Surgery Open Reports
1–7

© The Author(s) 2023

Article reuse guidelines:

sagepub.com/journals-permissions

DOI: 10.1177/20551169231165246

journals.sagepub.com/home/jfmsopenreports

This paper was handled and processed by the European Editorial Office (ISFM) for publication in *JFMS Open Reports*



Michael Martineau^{1,2}, Cyril Tilmant^{1,3}, Veronica Risco Castillo⁴, Jacques Guillot⁵, Edouard Reyes-Gomez⁶, Ghita Benchekroun¹ and Valerie Freiche¹

Abstract

Case summary A 5-year-old castrated male domestic shorthair cat presented with a 3-month history of weight loss, chronic diarrhoea and vomiting. Examination revealed a large proximal duodenal lesion eventually diagnosed as feline gastrointestinal eosinophilic sclerosing fibroplasia (FGESF) associated with fungal filaments. Histological examination was performed following endoscopic biopsy. Direct examination and mycological culture of the duodenal biopsies revealed the presence of a siphomycetous fungus, which was further identified as *Rhizopus microsporus*. Treatment with prednisolone and ciclosporin for 3 months led to complete resolution of the clinical signs and marked improvement of the endoscopic lesions. Specific fungal treatment with amphotericin B was poorly tolerated.

Relevance and novel information To the best of our knowledge, this is the first report of the characterisation of a siphomycetous fungus associated with FGESF lesions, and the first endoscopic description and diagnosis of FGESF without surgical biopsies. We hypothesise that the presence of *R. microsporus* occurred because of disrupted mucosal integrity.

Keywords: Feline gastrointestinal eosinophilic sclerosing fibroplasia; mucormycosis; duodenal mass; endoscopy; abdominal ultrasonography

Accepted: 2 March 2023

Introduction

Feline gastrointestinal eosinophilic sclerosing fibroplasia (FGESF), first identified in the early 2000s, is an emerging clinical entity in feline medicine.^{1–8} This uncommon

inflammatory condition is mostly characterised by the presence of an intramural ulcerated mass, most frequently located in the gastrointestinal tract, particularly at the pyloroduodenal or ileocolic junctions.^{1–5} Histopathology

¹National Veterinary School of Alfort, CHUVA, Internal Medicine Unit, Maisons-Alfort, France

²Department of Internal Medicine, Frégis Veterinary Hospital Centre, Arcueil, France

³Department of Internal Medicine, Olliolis Veterinary Clinic, Ollioules, France

⁴Department of Parasitology and Mycology, National Veterinary School of Alfort, BioPôle Alfort, Maisons-Alfort, France

⁵Department of Dermatology, Parasitology, and Mycology, Oniris, Nantes, France

⁶Department of Anatomical Pathology, National Veterinary School of Alfort, BioPôle Alfort, Maisons-Alfort, France

Corresponding author:

Valerie Freiche DVM, DESV-IM, PhD, Ecole Nationale Vétérinaire d'Alfort, CHUVA, Unité de Médecine Interne, 7 avenue du Général de Gaulle, Maisons-Alfort 94704, France
Email: valerie.freiche@vet-alfort.fr



Creative Commons Non Commercial CC BY-NC: This article is distributed under the terms of the Creative Commons

Attribution-NonCommercial 4.0 License (<https://creativecommons.org/licenses/by-nc/4.0/>) which permits non-commercial use, reproduction and distribution of the work without further permission provided the original work is attributed as specified on the SAGE and Open Access pages (<https://us.sagepub.com/en-us/nam/open-access-at-sage>).

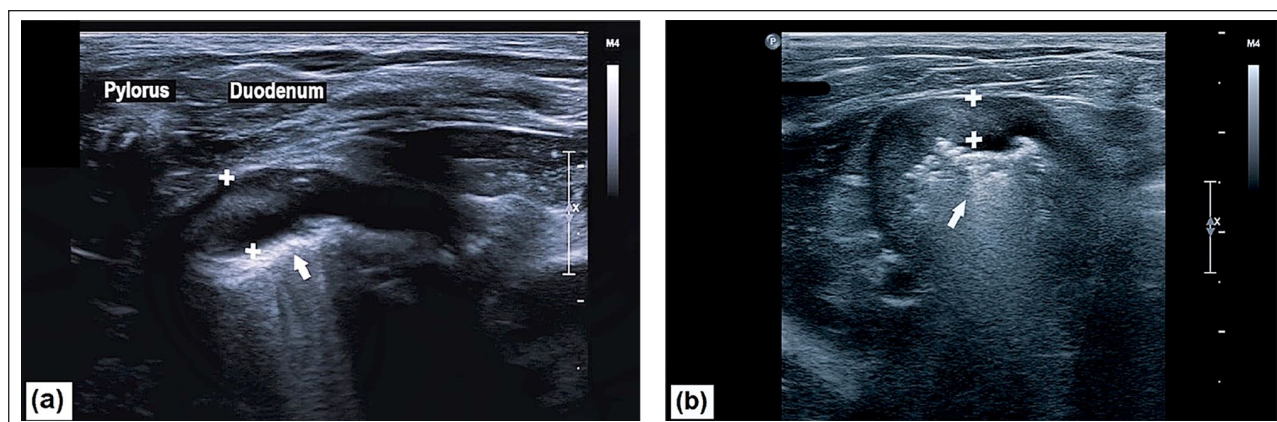


Figure 1 (a) Ultrasonographic illustrations of the focal thickening of the proximal duodenum (sagittal plane view) and (b) ultrasonographic picture of the lesion (transversal plane view). White arrow indicates the lumen of duodenum, and the crosses indicate focal thickening of the duodenal wall with loss of layering

is required for a definitive diagnosis. Herein, we describe the endoscopic appearance of FGESF in a case of secondary fungal colonisation and discuss the related aetiopathogenesis.

Case description

A 5-year-old castrated male domestic shorthair cat was referred to our institution for a 3-month history of weight loss, chronic food content vomiting and diarrhoea. Several examinations had been performed before admission by the referring veterinarian, including complete blood count (CBC) and biochemistry panel which showed mild eosinophilia ($1.75 \times 10^9/l$; reference interval [RI] 0.160–1.810) and a slight increase in alanine aminotransferase (ALT) activity (195 IU/l; RI 15–123); and an abdominal ultrasound examination that showed a marked and diffuse proximal duodenum thickening (up to 6.2 mm) without loss of layering, associated with a pancreaticoduodenal lymphadenopathy (thickness 8.1 mm) and slight thickening (up to 2.3 mm) of the colon without loss of layering. Previous therapeutic trials with fenbendazole (50 mg/kg PO for 5 days), marbofloxacin (3 mg/kg PO for 10 days), maropitant (2 mg/kg PO for 4 days) and a hypoallergenic diet were unsuccessful. Treatment with prednisolone (0.4 mg/kg/day PO for 1 month) resulted in partial improvement of the clinical signs.

On admission, physical examination revealed a slightly decreased body condition score (3/9) and tensed cranial abdominal palpation. CBC and biochemistry panel abnormalities included marked eosinophilia ($2.908 \times 10^9/l$; RI 0.160–1.810), a mild increase in ALT (207 IU/l; RI 15–123) and slight hypercreatininaemia (creatinine 159 $\mu\text{mol/l}$; RI 46–157). Abdominal ultrasound revealed severe focal thickening (up to 5.8 mm) of the proximal duodenum, displaying a loss of intestinal layering (Figure 1), in association with discrete pancreaticoduodenal lymphadenopathy (thickness

3.4 mm). The combination of peripheral eosinophilia and the proximal duodenal mass was suggestive of high-grade lymphoma or mast cell tumour associated with paraneoplastic eosinophilia, FGESF, inflammatory granuloma or parasitic lesions.

Gastroduodenoscopy was performed to better characterise the nature of the duodenal lesion. In addition, previous ultrasound signs of non-specific colitis justified colonoscopy. Endoscopically, the pyloric antrum was partly obstructed by grass fibres. Foreign material was removed prior to further examination. The proximal duodenal mucosa showed a proliferative and marked lesion associated with multiple ulcerative areas, exhibiting yellow–green discoloration (Figure 2a,b). Colonoscopy revealed diffuse oedematous mucosa in the distal colon and numerous white-to-grey circumscribed regions embedded in the mucosa (Figure 2c). Endoscopic biopsies were obtained from both sides for histological analysis.

Histological analysis of the duodenal mass confirmed the diagnosis of FGSEF. Histological examination of the duodenal tissue revealed branching and anastomosing trabeculae of dense sclerotic collagen fibres, interspersed with moderately pleomorphic fibroblasts and a mixed population of inflammatory cells predominantly composed of eosinophils (Figure 3a). Eosinophilic inflammation was confirmed by Congo red staining.⁹ Many non-pigmented, non-septate and non-dichotomously branched fungal filaments were detected within the tissue and on the surface. Periodic acid–Schiff (PAS) and Gomori–Grocott stains confirmed the presence of fungal filaments in the FGESF lesions (Figure 3b). Histological examination of the colonic tissue revealed slight, heterogeneously distributed eosinophilic infiltration. Eosinophil aggregates with necrosis were also identified. Some lesions were ulcerative and spilled over the mucosal surface (Figure 3a,b). These results evoked eosinophilic

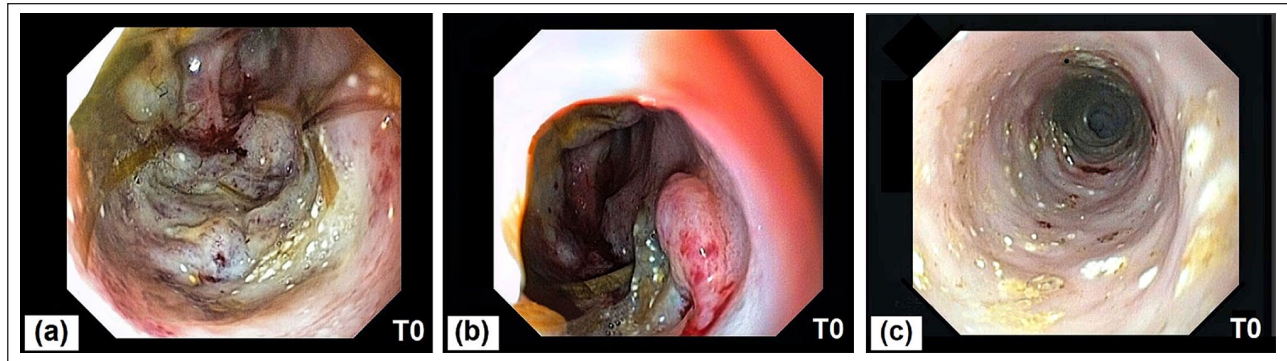


Figure 2 (a,b) Gastroduodenoscopy showed an abnormal and proliferative aspect of the proximal duodenal mucosa associated with ulcerated areas exhibiting a yellow–green discoloration. (c) Colonoscopy revealed a diffuse oedematous mucosa and many circumscribed white-to-grey areas embedded in the mucosa

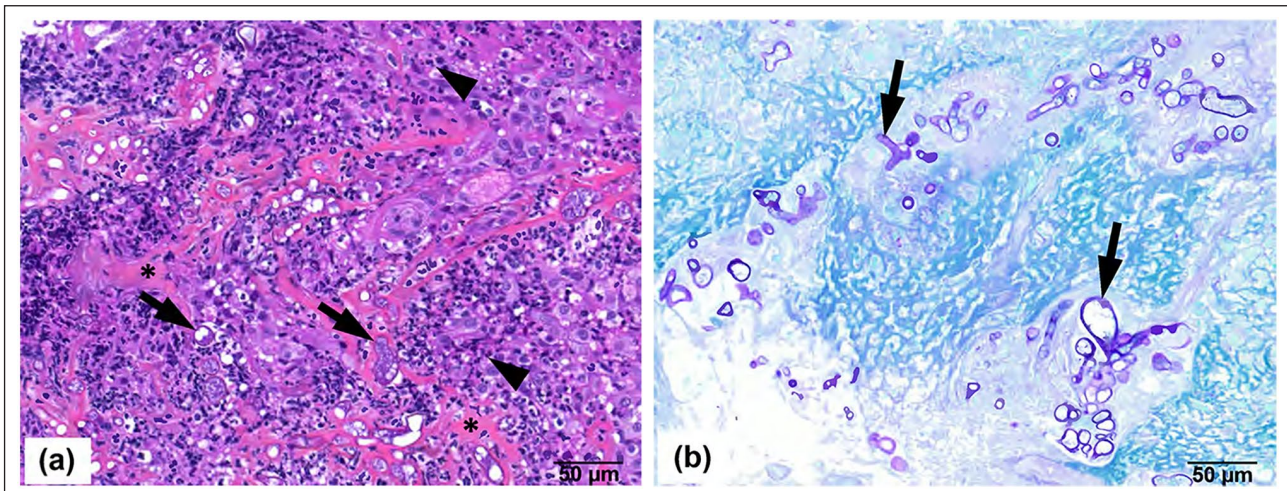


Figure 3 (a) Histopathology showed the infiltration of eosinophils (arrowheads) into duodenal tissue with intralesional fungi (arrows) and branching and anastomosing trabecular pattern of dense sclerotic collagen (asterisk; haematoxylin–eosin–safran). (b) Confirmation of the presence of fungi in duodenal lesions (arrows; periodic acid–Schiff, $\times 400$)

colitis, and foci of eosinophilic degranulation matching the white-to-grey circumscribed areas detected during colonoscopy were observed. PAS and Gomori–Grocott stains on the colonic tissue were negative for fungi.

Oral treatment with prednisolone 0.8mg/kg/day (Dermipred; CEVA) and ciclosporin 7.5mg/kg/day (Atopica; ELANCO) was prescribed for 3 months, achieving weight gain (+16% of body weight) and resolution of diarrhoea and vomiting. Gastroduodenoscopy was performed 71 days after the FGESF diagnosis, showing marked improvement in the lesions (Figure 4). Nevertheless, persistent lesions required further biopsies. We aimed to identify the persistence of fungal organisms that caused these residual lesions.

The subsequent endoscopic biopsies were submitted for direct examination and mycological culture on Sabouraud dextrose agar plates supplemented with chloramphenicol (0.5g) for 10 days at 37°C. Fungal

identification was performed by macroscopic and microscopic observation of morphological features, and further confirmed by mass spectrometry (matrix-assisted laser desorption ionisation time-of-flight mass spectrometry). Proteins from hyphae of a 3-day culture were formic acid–acetonitrile extracted, and protein spectra were measured in a Microflex LT/HS (MBT SMART; Bruker Daltonics) and matched against a mass spectrophotometry identification online database application.¹⁰ Fungal culture yielded a fast-growing mould with woolly colonies that were initially white and became grey-to-brown later. Microscopically, broad aseptate hyphae produced rhizoids and sporangio-phores, with dark sporangia and globose columellae (Figure 5). *Rhizopus microsporus* was also identified.

Assuming the presence of a fungal infection, antifungal treatment was initiated. Ciclosporin administration was interrupted, and prednisolone was progressively

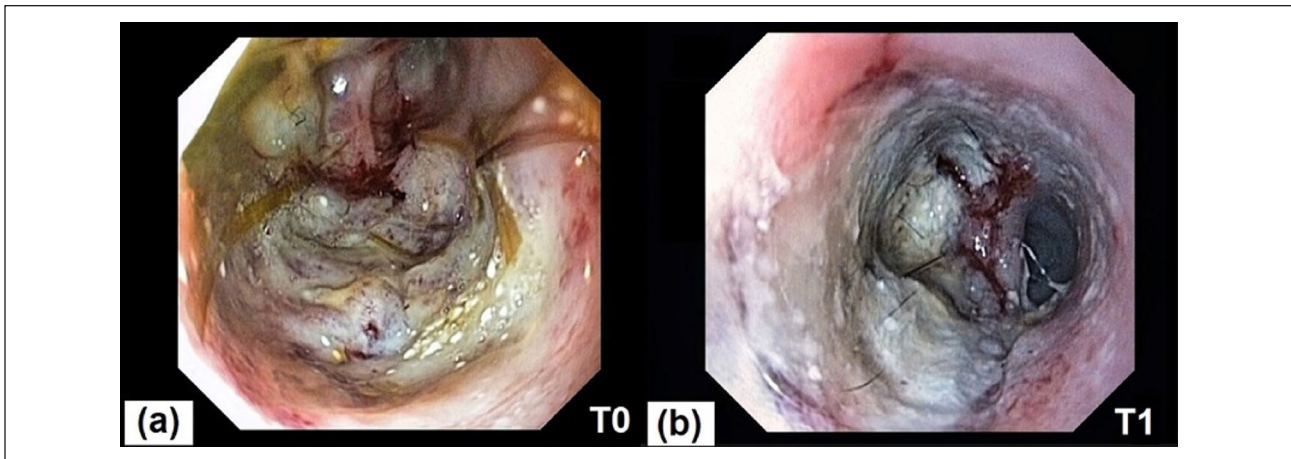


Figure 4 (a) Gastroduodenoscopy before immunomodulatory treatments (T0) and (b) gastroduodenoscopy after 71 days of immunomodulatory treatments (T1: T0 + 71 days). A marked improvement of the lesions is identified, but yellow–green discoloration areas are persistent

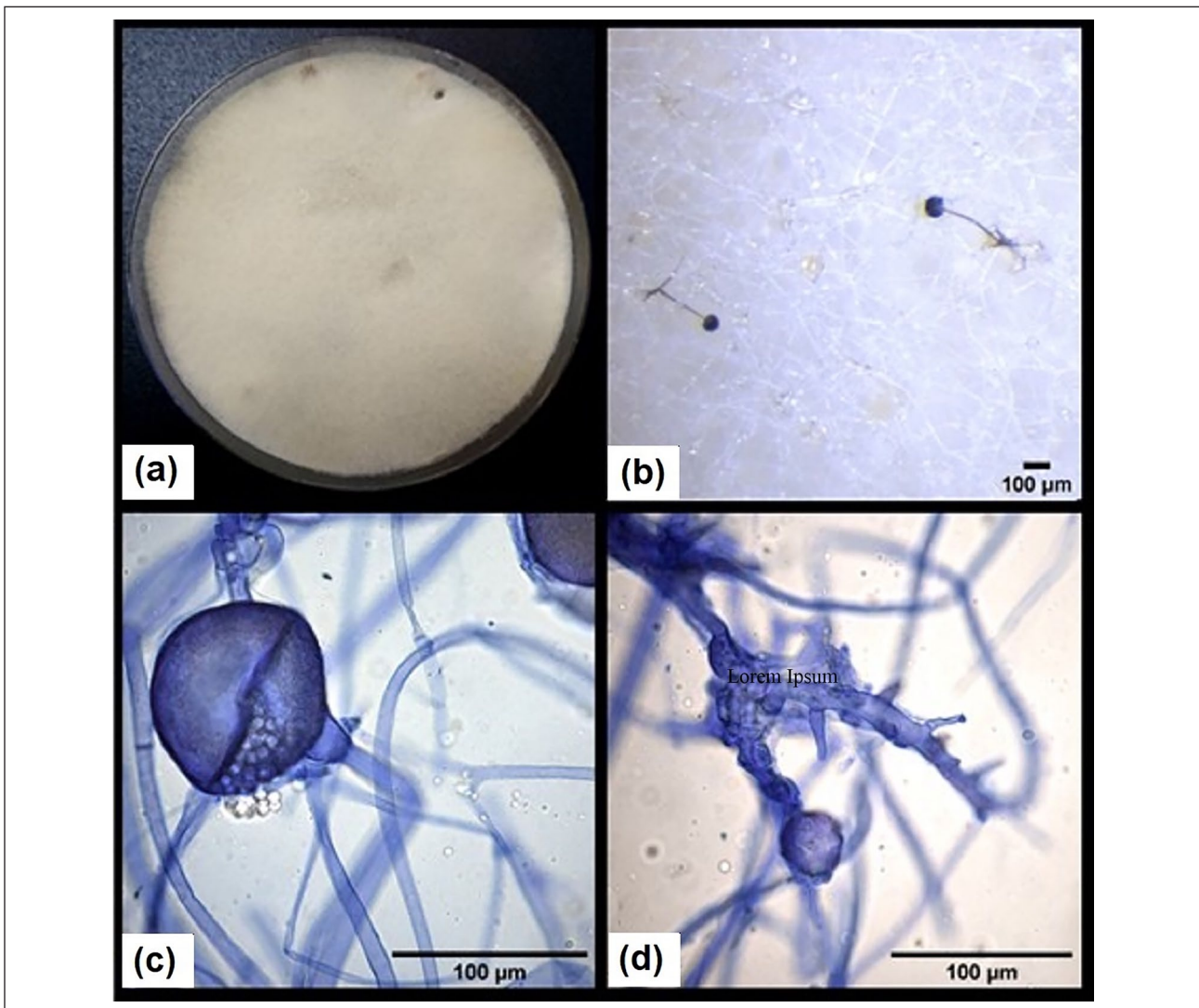


Figure 5 *Rhizopus microsporus* identified in duodenal endoscopic biopsies: (a) macroscopic aspect of the colonies; (b) binocular image of sporangiophores, rhizoids and pigmented filaments ($\times 10$ magnification); (c) germinating sporangium and columella ($\times 100$ magnification); and (d) growing stolons ($\times 100$ magnification)

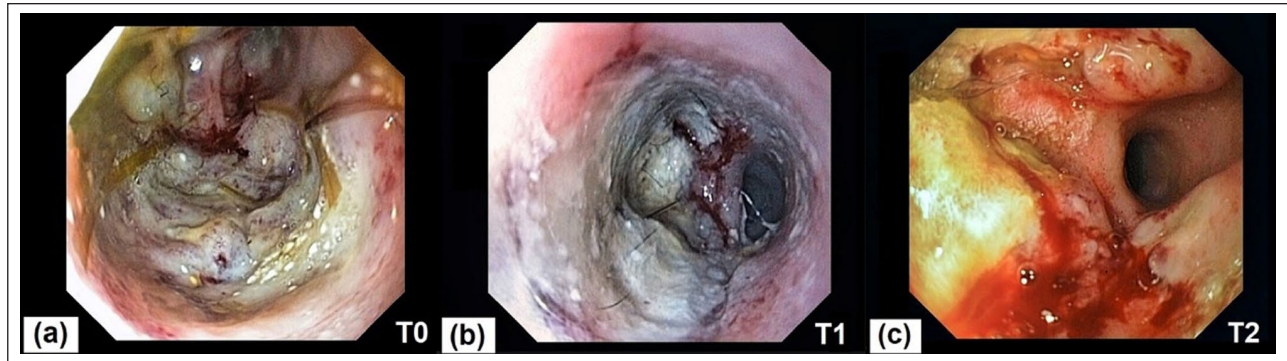


Figure 6 (a) Gastroduodenoscopy before immunomodulatory treatment (T0), (b) gastroduodenoscopy after immunomodulatory treatment and before antifungal treatment (T1: T0 + 71 days) and (c) gastroduodenoscopy after antifungal treatment and ciclosporin withdrawal (T2: T0 + 159 days)

reduced prior to the initiation of amphotericin B (30 mg/kg PO q24h) that was administered for 1 month. However, the antifungal treatment was poorly tolerated; an increase in creatinine (after 12 days creatinine = 212 μ mol/l; RI 46–157) and the recurrence of clinical signs were noted. Treatment compliance was only possible for 18 days; nevertheless, 2 months after ciclosporin withdrawal, endoscopic examination showed a relapse of the lesions (Figure 6).

Further histological examination of per-endoscopic biopsies revealed the presence of many fungal filaments and bacteria, as well as a recurrence of FGESF. *Escherichia coli*, *Clostridium perfringens* and *Fusobacterium varium* were identified in the bacteriological cultures of the biopsies. A mycological control culture was used to detect the presence of *R. microsporus*, as previously described. In this context, ciclosporin 7 mg/kg/day and prednisolone 0.6 mg/kg/day PO were administered for 3 months, and, according to the antibiogram, cefovecin 8 mg/kg PO was prescribed orally for 2 months. The cat was still alive and did not show any signs of vomiting at the time of writing (1.5 years after initial diagnosis).

Discussion

FGESF should be considered as a differential diagnosis for gastrointestinal masses in cats, especially at the pyloroduodenal or ileocolic junctions. However, histological analysis is required for diagnosis, as the gross appearance of the lesion can mimic neoplasia.¹ If gastrointestinal lesions are not obstructive in nature, endoscopic biopsies could be a less invasive method to diagnose FGESF than the surgical approach. The endoscopic procedure is less expensive for the owner, and recovery is optimised and quicker than the surgical procedure. This case report represents the first description of endoscopic FGESF lesions, which showed a proliferative and severely abnormal lesion of the proximal duodenal mucosa associated with ulcerative areas with

yellow–green discoloration. Nevertheless, further investigations are needed to describe the endoscopic patterns of FGESF lesions and to confirm the usefulness of endoscopic examination in diagnosing FGESF, compared with surgical biopsies. Endoscopic investigation encompasses limiting factors: pyloric intubation may be difficult in some cases and could limit the duodenal examination. Moreover, endoscopic biopsies can be too superficial to characterise the lesions. As differentials include T-cell lymphoma or a mast cell tumour, multiple mucosal biopsies of adequate quality are needed.

The aetiopathogenesis of FGESF remains poorly understood. Cats with FGESF may suffer from a genetic predisposition, leading to immunological dysregulation maintained by one or more factors.¹ Food intolerance, pica, dysbiosis and various types of infectious agents (bacteria, fungi, viruses or parasites) can all trigger uncontrolled eosinophilic inflammation, promoting the disruption of mucosal integrity. Although bacteria are isolated from lesions in many cases, their role remains unclear.¹¹ Phycomycetes were previously found to be associated with FGESF lesions in a young Persian cat,⁵ while nematodes were histologically identified in gastrointestinal nodules, similar to FGESF in a puma.¹² Feline herpesvirus 1, a virus associated with eosinophilic inflammation, was not detected by immunohistochemistry in FGESF lesions.³ Some authors suggest that pyloric and/or ileocolic localisation of the lesions may be more often considered because of the transit of sharp foreign bodies within the digestive tract.¹

The fungus *R. microsporus*, isolated in the present case, belongs to the group *Mucorales*, which comprises opportunistic pathogens present in soil, water, plants and decaying organic material.^{13–16} In humans, gastrointestinal mucormycoses are associated with the ingestion of contaminated food or drugs, and the use of contaminated wood tongue depressors in medical practice.^{15–17} The cat presented in this report had an outdoor lifestyle

and ingested grass plants, which may have contributed to the inoculation of fungi into the gastrointestinal tract. In humans, the most frequent manifestations of mucormycosis are rhinocerebral, pulmonary, cutaneous and disseminated. In contrast, gastrointestinal cases are rare, with a prevalence of only 5–13% of all human mucormycoses.^{13,15,16} Infections most commonly occur in immunocompromised patients. Risk factors include diabetes (especially ketoacidosis complications), haematological malignancies, organ transplantation and long-term use of corticoids.^{13,16} Mucormycosis is an acute disease with a poor outcome. A mortality rate of 60.5% was reported for adult gastrointestinal infection.¹⁵ In veterinary medicine, a few cases of mucormycosis have been associated with an extremely poor prognosis.^{18–28} In the present case, the clinical course was less aggressive than expected. In a study by Cheng et al,¹⁷ cases of mucorale colonisation in the gastrointestinal tract showed a good prognosis. However, these patients were asymptomatic and did not exhibit any histological lesions in the gastrointestinal tract.¹⁷ Thus, it is unlikely that the digestive lesions reported in the present case were primarily caused by *R. microsporus* infection. *Mucorales* infections show a typical angio-invasive pathway²⁹ on histological examination. In the case of gastrointestinal mucormycosis in a cat, this pattern was also recognised,²⁸ but not in the present case or in another case of fungi associated with FGESF lesions.⁵ Thus, dysregulation of interactions between the mucosa, mucosal immune system and digestive microbiota is most likely the primary cause of integrity disruption of the digestive mucosa, thereby facilitating secondary colonisation by *R. microsporus*. Histopathological evidence of eosinophilic enteritis and colitis reinforced the hypothesis of pre-existing chronic enteropathy in this cat. Nevertheless, the association between FGESF and chronic enteropathy has been poorly documented.³

Conclusions

This case report revealed that the *Mucorales* species *R. microsporus* may be associated with FGESF lesions, and that endoscopic examination and biopsies can lead to the diagnosis of FGESF. The fungus was probably introduced because of digestive barrier dysfunction and may eventually represent a perpetuating agent of this dysregulated inflammation that causes FGESF lesions.

Acknowledgements The authors wish to thank Agnès Champeix for histotechny and special stains, the referring veterinarian

for his confidence and the Medical Imaging Department at the Centre Hospitalier Universitaire Vétérinaire d'Alfort.

Conflict of interest The authors declared no potential conflicts of interest with respect to the research, authorship, and/or publication of this article.

Funding The authors received no financial support for the research, authorship, and/or publication of this article.

Ethical approval The work described in this manuscript involved the use of non-experimental (owned or unowned) animals. Established internationally recognised high standards ('best practice') of veterinary clinical care for the individual patient were always followed and/or this work involved the use of cadavers. Ethical approval from a committee was therefore not specifically required for publication in *JFMS Open Reports*. Although not required, where ethical approval was still obtained, it is stated in the manuscript.

Informed consent Informed consent (verbal or written) was obtained from the owner or legal custodian of all animal(s) described in this study (experimental or non-experimental animals, including cadavers) for all procedure(s) undertaken (prospective or retrospective studies). For any animals or people individually identifiable within this publication, informed consent (verbal or written) for their use was obtained from the people involved.

ORCID iD Valerie Freiche  <https://orcid.org/0000-0003-2041-078X>

References

- 1 Craig LE, Hardam EE, Hertzke DM, et al. **Feline gastrointestinal eosinophilic sclerosing fibroplasia.** *Vet Pathol* 2009; 46: 63–70.
- 2 Weissman A, Penninck D, Webster C, et al. **Ultrasonographic and clinicopathological features of feline gastrointestinal eosinophilic sclerosing fibroplasia in four cats.** *J Feline Med Surg* 2012; 15: 148–154.
- 3 Linton M, Nimmo JS, Norris JM, et al. **Feline gastrointestinal eosinophilic sclerosing fibroplasia: 13 cases and review of an emerging clinical entity.** *J Feline Med Surg* 2015; 17: 392–404.
- 4 Suzuki M, Onchi M and Ozaki M. **A case of feline gastrointestinal eosinophilic sclerosing fibroplasia.** *J Toxicol Pathol* 2013; 26: 51–53.
- 5 Grau-Roma L, Galindo-Cardiel I, Isidoro-Ayza M, et al. **A case of feline gastrointestinal eosinophilic sclerosing fibroplasia associated with phycomycetes.** *J Comp Pathol* 2014; 151: 318–321.
- 6 Thieme ME, Olsen AM, Woolcock AD, et al. **Diagnosis and management of a case of retroperitoneal eosinophilic sclerosing fibroplasia in a cat.** *JFMS Open Rep* 2019; 5. DOI: 10.1177/2055116919867178.

- 7 Kambe N, Okabe R, Osada H, et al. **A case of feline gastrointestinal eosinophilic sclerosing fibroplasia limited to the mesentery.** *J Small Anim Pract* 2020; 61: 64–67.
- 8 Sihvo HK, Simola OTM, Vainionpää MH, et al. **Pathology in practice. Severe chronic multifocal intramural fibrosing and eosinophilic enteritis, with occasional intra-lesional bacteria, consistent with feline gastrointestinal eosinophilic sclerosing fibroplasia (FIESF).** *J Am Vet Med Assoc* 2011; 238: 585–587.
- 9 Grouls V and Helpap B. **Selective staining of eosinophils and their immature precursors in tissue sections and autoradiographs with congo red.** *Stain Technol* 1981; 56: 323–325.
- 10 Normand AC, Becker P, Gabriel F, et al. **Validation of a new web application for identification of fungi by use of matrix-assisted laser desorption ionization–time of flight mass spectrometry.** *J Clin Microbiol* 2017; 55: 2661–2670.
- 11 Ozaki K, Yamagami T, Nomura K, et al. **Abscess-forming inflammatory granulation tissue with Gram-positive cocci and prominent eosinophil infiltration in cats: possible infection of methicillin-resistant *Staphylococcus*.** *Vet Pathol* 2003; 40: 283–287.
- 12 Eckstrand CD, Barr BC, Woods LW, et al. **Nematode-associated intramural alimentary nodules in pumas are histologically similar to gastrointestinal eosinophilic sclerosing fibroplasia of domestic cats.** *J Comp Pathol* 2013; 148: 405–409.
- 13 Roden M, Zaoutis T, Buchanan W, et al. **Epidemiology and outcome of zygomycosis: a review of 929 reported cases.** *Clin Infect Dis* 2005; 5: 634–653.
- 14 Grooters A and Foil C. **Miscellaneous fungal infections.** In: Sykes J and Green C (eds). *Infectious diseases in the dog and cat*. 4th ed. St Louis, MO: Elsevier-Saunders, 2012, pp 706–707.
- 15 Kaur H, Ghosh A, Rudramurthy S, et al. **Gastrointestinal mucormycosis in apparently immunocompetent hosts – a review.** *Mycoses* 2018; 61: 898–908.
- 16 Jeong W, Keighley C, Wolfe R, et al. **The epidemiology and clinical manifestation of mucormycosis: a systematic review and meta-analysis of case reports.** *Clin Microbiol Infect* 2019; 25: 26–34.
- 17 Cheng V, Chan J, Ngan A, et al. **Outbreak of intestinal infection due to *Rhizopus microsporus*.** *J Clin Microbiol* 2009; 47: 2834–2843.
- 18 Schonmann M, Thoma R and Braun U. **A case of acute disseminated mucor encephalitis in a heifer.** *Schweiz Arch Tierheilkd* 1997; 139: 490–497.
- 19 Thirion-Delalande C, Guillot J, Jensen HE, et al. **Disseminated acute concomitant aspergillosis and mucormycosis in a pony.** *J Vet Med A Physiol Pathol Clin Med* 2005; 52: 121–124.
- 20 Tanaka Y, Toyotome T, Inokuma H, et al. **Rhinocerebral zygomycosis due to a *Lichtheimia ramosa* infection in a calf: neural spread through the olfactory nerves.** *Mycopathologia* 2019; 184: 141–146.
- 21 More S, Hernandez O and Castleman W. **Mycotic rhinitis and sinusitis in Florida horses.** *Vet Pathol* 2019; 56:586–598.
- 22 Slaviero M, Vargas T, Bianchi M, et al. ***Rhizopus microsporus* segmental enteritis in a cow.** *Med Mycol Case Rep* 2020; 28: 20–22.
- 23 Connolly JH, Canfield PJ and Obendorf DL. **Gross, histological and immunohistochemical features of mucormycosis in the platypus.** *J Comp Pathol* 2000; 123: 36–46.
- 24 Abdo W, Kakizoe Y, Ryono M, et al. **Pulmonary zygomycosis with *Cunninghamella bertholletiae* in a killer whale (*Orcinus orca*).** *J Comp Pathol* 2012; 147: 94–99.
- 25 Alves RC, Ferreira JS, Alves AS, et al. **Systemic and gastrohepatic mucormycosis in dogs.** *J Comp Pathol* 2020; 175: 90–94.
- 26 Ravisce P, Fromentin H, Destombes P, et al. **Cerebral mucormycosis in the cat caused by *Mucor pusillus*.** *Sabouraudia* 1978; 16: 291–298.
- 27 Wray JD, Sparkes AH and Johnson EM. **Infection of the subcutis of the nose in a cat caused by *Mucor* species: successful treatment using posaconazole.** *J Feline Med Surg* 2008; 10: 523–527.
- 28 Cunha S, Aguero C, Damico C, et al. **Duodenal perforation caused by *Rhizomucor* species in a cat.** *J Feline Med Surg* 2011; 13: 205–207.
- 29 Pettrikos G and Tsioutis C. **Recent advances in the pathogenesis of mucormycoses.** *Clin Ther* 2018; 8. DOI: 10.1016/j.clinthera.2018.03.009.