



Combination of TPLO, medial and lateral augmentation techniques for the treatment of traumatic stifle luxation in a cat

Authors: Bartolomé i Gadea, Paula, and Coppola, Mario

Source: Journal of Feline Medicine and Surgery Open Reports, 10(1)

Published By: SAGE Publishing

URL: <https://doi.org/10.1177/20551169241247439>

BioOne Complete (complete.BioOne.org) is a full-text database of 200 subscribed and open-access titles in the biological, ecological, and environmental sciences published by nonprofit societies, associations, museums, institutions, and presses.

Your use of this PDF, the BioOne Complete website, and all posted and associated content indicates your acceptance of BioOne's Terms of Use, available at www.bioone.org/terms-of-use.

Usage of BioOne Complete content is strictly limited to personal, educational, and non - commercial use. Commercial inquiries or rights and permissions requests should be directed to the individual publisher as copyright holder.

BioOne sees sustainable scholarly publishing as an inherently collaborative enterprise connecting authors, nonprofit publishers, academic institutions, research libraries, and research funders in the common goal of maximizing access to critical research.



Combination of TPLO, medial and lateral augmentation techniques for the treatment of traumatic stifle luxation in a cat

Journal of Feline Medicine and Surgery Open Reports
1–8

© The Author(s) 2024

Article reuse guidelines:

sagepub.com/journals-permissions

DOI: 10.1177/20551169241247439

journals.sagepub.com/home/jfmsopenreports

This paper was handled and processed by the European Editorial Office (ISFM) for publication in *JFMS Open Reports*



Paula Bartolomé i Gadea and Mario Coppola

Abstract

Case summary An 11-year-old female neutered domestic shorthair cat was referred for surgical management of a traumatic right stifle luxation. Orthopaedic examination of the affected stifle under general anaesthesia revealed joint effusion and craniocaudal and rotational instability. Cranial displacement of the tibia with respect to the femur and infrapatellar pad sign were identified on radiography. Intraoperatively, complete rupture of both cruciate ligaments and marked disruption of the mid and caudal poles of the medial and lateral menisci were observed. Both collateral ligaments appeared intact. The remnants of the injured cruciate ligaments were removed, and medial and lateral caudal hemimeniscectomies were performed. A tibial plateau levelling osteotomy (TPLO) was performed to address the craniocaudal stifle instability. Intraoperative assessment of the stifle revealed persistent instability with cranial tibial translation, internal and external rotation, and a positive caudal draw test. A lateral augmentation suture was employed to address the persistent cranial tibial translation and internal rotation. To successfully neutralise caudocranial and external rotational instability secondary to the caudal cruciate ligament deficiency, a medial augmentation suture was placed with the aid of three interference screws. Stifle stability was achieved. A modified Robert-Jones bandage was kept on for 24 h postoperatively. An excellent outcome was achieved, with successful limb function restoration.

Relevance and novel information This case report represents the first documented instance of feline traumatic stifle luxation repair by combining a corrective tibial osteotomy and extra-articular augmentation. Notably, it introduces the novel technique of implementing a TPLO with medial and lateral augmentation sutures to address multidirectional stifle instability.

Keywords: Stifle; luxation; disruption; tibial plateau levelling osteotomy; TPLO; augmentation suture

Accepted: 28 March 2024

Introduction

Stifle luxation is a severe injury involving the dislocation of the tibiofemoral joint.¹ The stabilising structures of the normal stifle joint include primary (cruciate and collateral ligaments) and secondary structures such as the joint capsule, meniscus, tendons and muscle.^{2,3} Trauma typically triggers this condition in cats, with varying ligament injuries leading to luxation.^{2–6} Palpation of the stifle joint when the cat is under sedation or general anaesthesia will allow a more thorough understanding of what primary joint restraints are compromised.⁵

Treatment aims at restoring joint stability and alignment, preventing further damage to the cartilage and

preserving a normal range of motion.^{2,5,7} The treatment usually involves primary surgical repair or replacement of ligaments and/or postoperative temporary joint immobilisation.³

In cats, the cranial cruciate ligament (CrCL) rupture aetiology tends to be traumatic and, in fewer instances, degenerative.^{8–10} Neutralisation of the cranial tibial thrust

Fitzpatrick Referrals, Godalming, UK

Corresponding author:

Paula Bartolomé i Gadea DVM, MRCVS, Fitzpatrick Referrals, Halfway Lane, Godalming GU7 2QQ, UK
Email: paula.bg1995@gmail.com



Creative Commons Non Commercial CC BY-NC: This article is distributed under the terms of the Creative Commons

Attribution-NonCommercial 4.0 License (<https://creativecommons.org/licenses/by-nc/4.0/>) which permits non-commercial use, reproduction and distribution of the work without further permission provided the original work is attributed as specified on the SAGE and Open Access pages (<https://us.sagepub.com/en-us/nam/open-access-at-sage>).

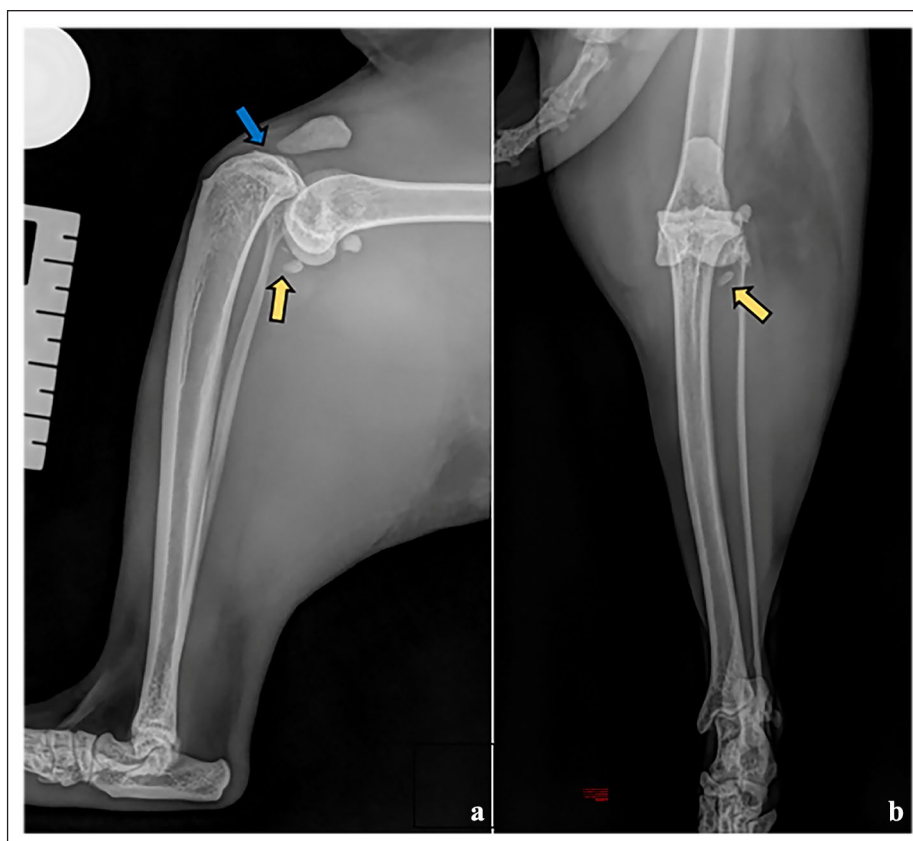


Figure 1 Preoperative right stifle radiographs. (a) Mediolateral view revealing proximal displacement of the tibia towards the femur and infrapatellar pad sign. (b) Posteroanterior view revealing proximal displacement of the tibia towards the femur. Yellow arrows in (a) and (b) point to the popliteal sesamoid bone, which was displaced caudodistally. Cranially to it, a small bone fragment could be identified. The blue arrow in (a) points to the suspected joint effusion and/or oedema of the fat pad

with a tibial plateau levelling osteotomy (TPLO) in cats remains controversial, achieving different results between *ex vivo* and *in vivo* studies.^{11–13} Typically, its stabilisation involves a lateral fabellotibial suture, while a fibula-patellar suture treats caudal cruciate ligament (CaCL) rupture.^{1,6} Joint immobilisation methods range from external coaptation to rigid transarticular external fixation, though controversy exists due to associated complications.^{3,7} Despite debates on postoperative immobilisation, recent studies question its necessity and caution against certain methods, such as transarticular pins, due to higher complication rates and poorer outcomes.¹⁴

This case introduces a novel approach and is the first reported instance of feline stifle luxation treated with a combination of TPLO with medial and lateral augmentation techniques.

Case description

An 11-year-old female neutered domestic shorthair cat, weighing 4 kg, was referred due to a suspected traumatic right stifle luxation. The patient was initially assessed by the referring veterinary surgeon due to an acute high-grade right pelvic limb lameness, with suspected traumatic origin. Clinical examination was normal, and a

high-grade right pelvic limb lameness was present.¹⁵ Blood tests, including haematology and biochemistry, were within normal limits. Radiographs (performed under sedation) of the thorax and pelvis were normal, and a right stifle luxation was diagnosed on stifle radiographs. Analgesia was provided, and the cat was referred the same day.

The cat presented with a high-grade lameness of the right pelvic limb.¹⁵ Effusion of the right stifle was present and discomfort was elicited upon flexion and extension of the joint; therefore, stifle stability tests were not performed until the patient was anaesthetised. The remainder of the clinical examination was unremarkable.

Orthopaedic examination under general anaesthesia revealed craniocaudal instability of the tibia in relation to the femur, with additional internal and external rotational instability. Orthogonal radiographs confirmed cranioproximal displacement of the tibia with respect to the femur and effacement of the infrapatellar fat pad shadow, consistent with joint effusion and/or oedema of the fat pad, caudodistal displacement of the popliteal sesamoid bone and a small bone fragment located cranially to it, whose origin was uncertain (Figure 1).

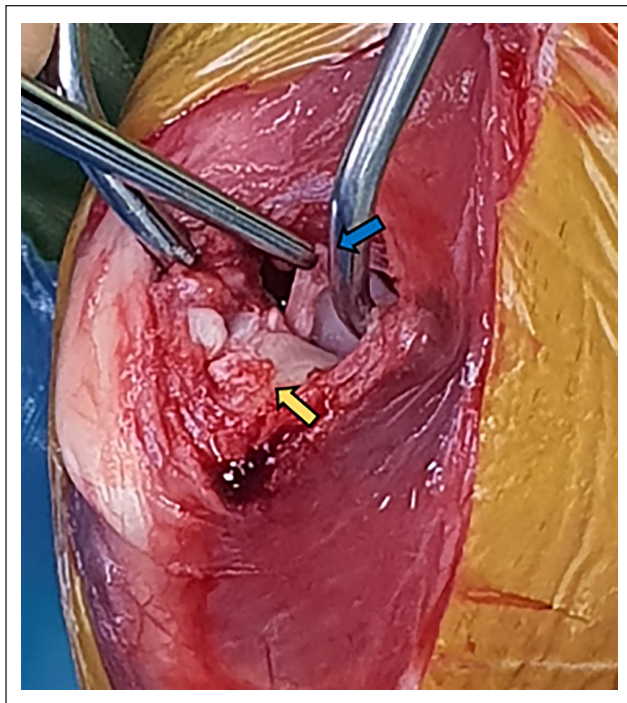


Figure 2 Intraoperative assessment of the stifle joint. Yellow arrow pointing to the cranial cruciate ligament's (CrCL) origin in the cranial intercondyloid area of the tibia. Note that the remnants of the CrCL were removed. The blue arrow indicates the complete rupture of the caudal cruciate ligament

Surgical intervention involved a medial and lateral approach to the right stifle, followed by a medial parapatellar mini arthrotomy. Cartilage erosion of the medial aspect of the femoral condyle, complete rupture of both CrCL and CaCL, as well as marked disruption of the caudal poles of both menisci were identified intraoperatively (Figure 2). Both medial and lateral collateral ligaments appeared intact. The remnants of the CrCL and CaCL were removed, and medial and lateral caudal hemimeniscectomies were performed.

To address the craniocaudal stifle instability, a right TPLO procedure was executed, as described by Slocum and Slocum.¹⁶ A 12mm bi-radial saw blade was used to perform the osteotomy and a pin was temporarily placed in the proximal fragment to aid its rotation. Then, a K-wire was placed from the tibial tuberosity in a craniocaudal direction to temporarily reduce the bone fragments after achieving the planned rotation. The osteotomy was stabilised with a 2mm locking TPLO plate (Arthrex), and the K-wire was removed (Figure 3). The tibial plateau angle (TPA) was rotated from 23° to 6°. Intraoperative assessment revealed persistent instability with cranial tibial translation, internal and external rotation, and a positive

caudal draw test. A lateral augmentation suture using a 1.3mm multistrand, long chain, ultra-high molecular weight polyethylene suture (FiberTape; Arthrex) was then employed to address the persistent cranial tibial translation and internal rotation.¹⁷ The suture was inserted through the TPLO plate's suture hole, through a pre-drilled 2mm tibial tunnel, and then secured to a distal lateral femoral condylar 2.5mm interference screw (Pushlock; Arthrex). Stifle stability was reassessed, revealing persistence of craniocaudal and external rotational instability. To address this, another suture with the same characteristics as the previous one was applied with the aid of two 2.5mm size interference screws placed on the proximocaudal aspect of the medial tibia and the caudodistal aspect of the medial femoral condyle, respectively; the suture was not cut. This resolved the caudocranial instability, but it did not fully address the external rotation. Therefore, the remaining suture from the femoral interference screw was brought to the cranial aspect of the proximomedial tibia (cranial to the second most distal TPLO plate screw) and fixed with a 2.5mm size interference screw (Figure 3). Stifle stability was finally achieved. The patella was assessed to be tracking well within the trochlear groove. Moderate reduction of the range of motion of the stifle joint during flexion was present. Soft tissue closure was routine. The muscle fascia was sutured in a simple continuous pattern with 2-metric polydioxanone (PDS; Ethicon), the subcutaneous layer was sutured in a simple continuous pattern with 2-metric poliglecaprone (Monocryl; Ethicon) and the skin was sutured in an intradermal pattern with 1.5-metric poliglecaprone (Monocryl; Ethicon). Postoperative radiographs revealed adequate apposition and implant positioning. A mild caudal tibial subluxation was observed, presumably as a secondary effect of the CaCL injury. Despite this, postoperative assessment of the stifle demonstrated satisfactory joint stability. The TPA was reduced to 6° (Figure 4). A modified Robert-Jones bandage was kept on for 24h to prevent soft tissue swelling.

The patient was hospitalised for 6 days, receiving opioid-based analgesia (methadone 0.2mg/kg q4h [Comfortan; Dechra]), which was progressively reduced until stopped 48h after surgery. The cat was prescribed a 3-week course of meloxicam (0.05mg/kg PO q24h [Metacam; Boehringer Ingelheim]), a 7-day course of cefalexin (25mg/kg PO q12h [Therios; Ceva]) and a 10-day course of gabapentin (12.5mg/kg PO q12h [Neurontin; Pfizer]) to provide additional analgesia. Two daily 20mins sessions of physiotherapy were conducted, starting on postoperative day 2 until discharge. Passive range-of-motion exercises were performed by a qualified physiotherapist during these sessions.

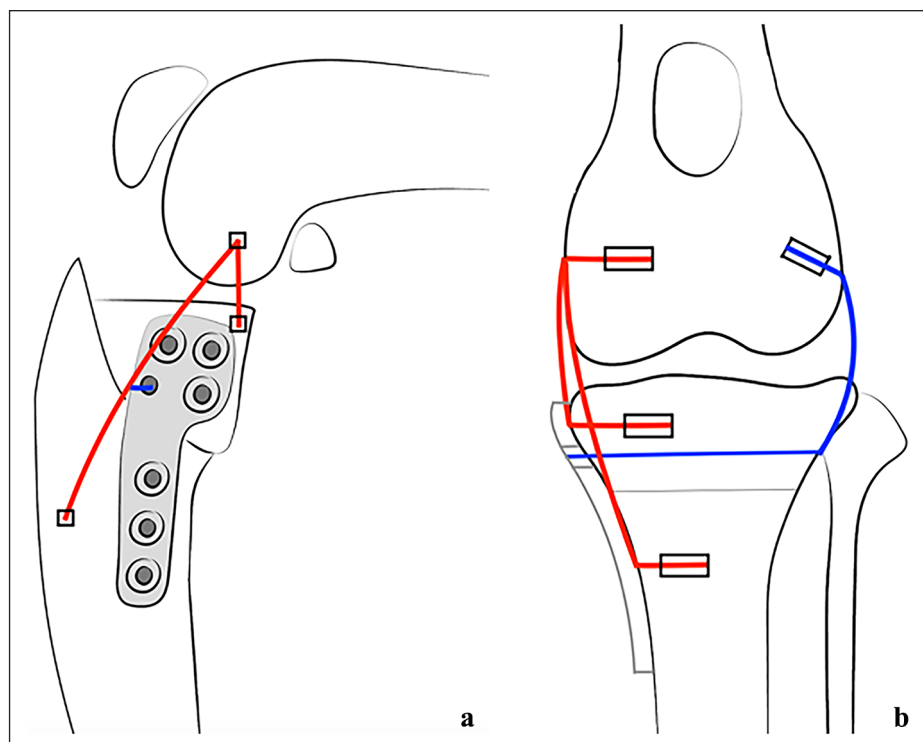


Figure 3 Orthogonal stifle diagrams show the medial and lateral augmentation sutures placement. (a) Medial aspect of the stifle diagram, showing the relationship between the tibial plateau levelling osteotomy (TPLO) plate and the medial augmentation suture. (b) Anteroposterior stifle diagram. The blue line represents the lateral augmentation suture, which was inserted through the TPLO plate's suture hole, through a predrilled tibial tunnel, and then secured to a distal lateral femoral condylar interference screw. The red line represents the medial augmentation suture, anchored with three interference screws. One femoral screw in the caudodistal area of its medial condyle and two tibial screws in its medial aspect: one proximocaudally and the other cranially to the second most distal TPLO plate screw. Note that the TPLO plate screws have been removed to allow a better visualisation of the suture placements

At the time of discharge, the cat exhibited a medium-grade lameness of the right pelvic limb.⁹ Strict cage rest was implemented for 6 weeks, and gradual reintroduction of exercise was instructed over the following 6 weeks.

Reassessments at 6 and 12 weeks postoperatively showed a low-grade lameness of the right pelvic limb.¹⁵ At 6 weeks, there was a full range of motion of the right stifle and a mild positive caudal draw test. At 12 weeks, no changes were observed in the cat's lameness and stifle range of motion compared with the previous recheck; however, all stifle stability tests were negative at this point. Orthogonal radiographs showed adequate apposition and activity, with bone healing signs at the osteotomy site. The previously identified mild tibial caudal subluxation persisted radiographically (Figure 5).

Eight months after surgery, a follow-up using the Feline Musculoskeletal Pain Index (FMPI)¹⁸ indicated an excellent outcome, with a score of 60/68. The owners also provided videos of the cat, with absence of right

hindlimb lameness at stance, walk or trot (see Videos 1 and 2 in the supplementary material).

Discussion

Meticulous exploration of the joint is the first step in surgical management, focusing on the evaluation of both cruciate ligaments, menisci and meniscal attachment should be carried out. If meniscal damage is present, a meniscectomy is advised to prevent its entrapment within the joint.^{2,19} In addition, medial meniscal injury has been related to poorer outcomes in cats with stifle luxation due to the development of osteoarthritis.¹⁴ An ex vivo study performed in dogs' stifles with meniscal tears showed meniscal repair to decrease the occurrence of osteoarthritis compared with partial meniscectomy;²⁰ however, it has not been described in cats. Our case presented with severe damage to both menisci so medial and lateral hemi-meniscectomies were performed.¹⁹

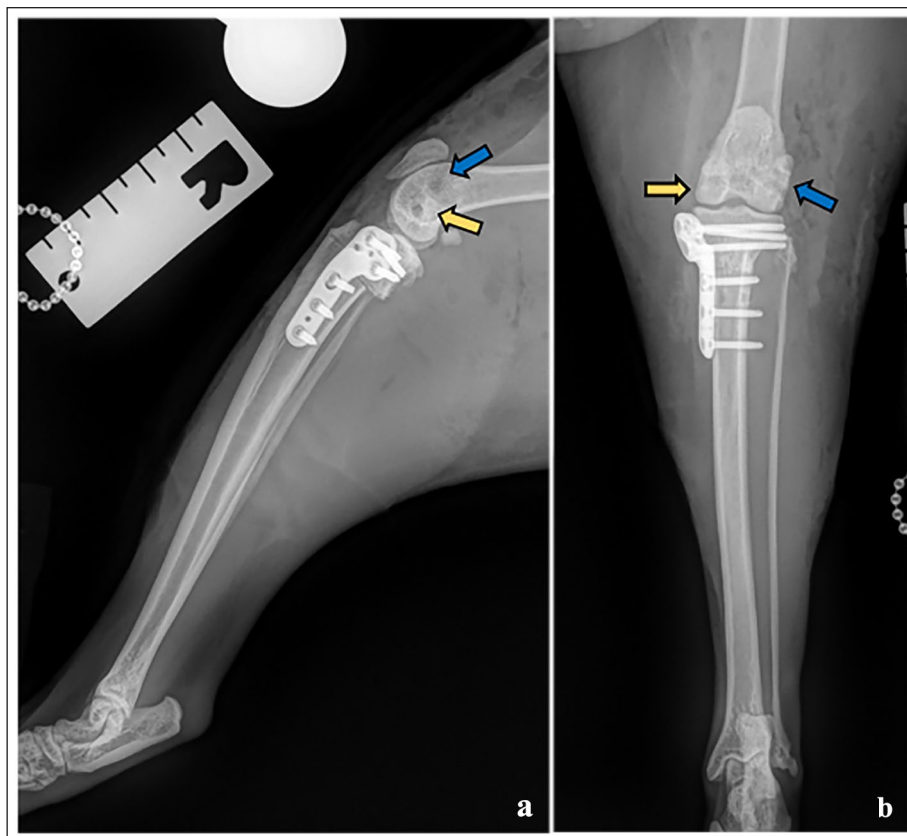


Figure 4 Immediate postoperative orthogonal stifle radiographs: (a) mediolateral view; and (b) posteroanterior view. The blue arrows indicate the position of the lateral augmentation suture femoral interference screw. The yellow arrows point to the position of the medial augmentation suture femoral interference screw

CrCL rupture is one of the most common causes of pelvic limb lameness in dogs, but despite being less frequent in cats, its report is on the rise.^{6,21–24} Traditionally, conservative management or extracapsular techniques were the most common choices for feline CrCL disruption.^{6,24} In dogs, these methods have been associated with suboptimal long-term results, as they do not consistently preserve stability, slow the progression of osteoarthritis or avoid late meniscal damage.^{25–27} In contrast, TPLO, a method more commonly used in dogs, has demonstrated better outcomes.¹⁶ Recent studies suggest that TPLO can be a viable option for the treatment of feline CrCL rupture.^{11,12}

However, TPLO primarily addresses cranial draw instability but does not effectively address internal rotation.²⁸ In this particular case, both the CrCL and CaCL were disrupted, resulting in persistent internal and external rotation after TPLO. An *ex vivo* study introduced the tibial compression test with external and internal moments, revealing cranial instability, despite TPLO in CrCL-deficient dog stifles. The study suggested that adding an extra-articular lateral augmentation

might be more successful in re-establishing stifle kinematics than TPLO alone.²⁹ In the present case, a lateral augmentation suture was applied successfully to neutralise residual cranial tibial translation and internal tibial rotational instability.

The CaCL, crucial for preventing caudal tibial subluxation, limiting internal rotation and controlling stifle hyperextension alongside the CrCL, was also disrupted.^{30,31}

The largest retrospective study on feline traumatic stifle luxation showed that 66.6% of the cases where the CaCL was affected but not surgically addressed had persistent caudal draw test, which is suggestive of joint instability and therefore could be related to poorer outcomes.¹⁴ There is a lack of evidence regarding the most successful treatment for CaCL rupture as is it rare to present as an isolated injury.¹⁹

The authors used a prosthetic suture, placed in the medial aspect of the stifle and fixed in a three-point construct to counteract the caudal displacement of the tibia towards the femur and the external tibial rotational instability. The decision on the points of screw

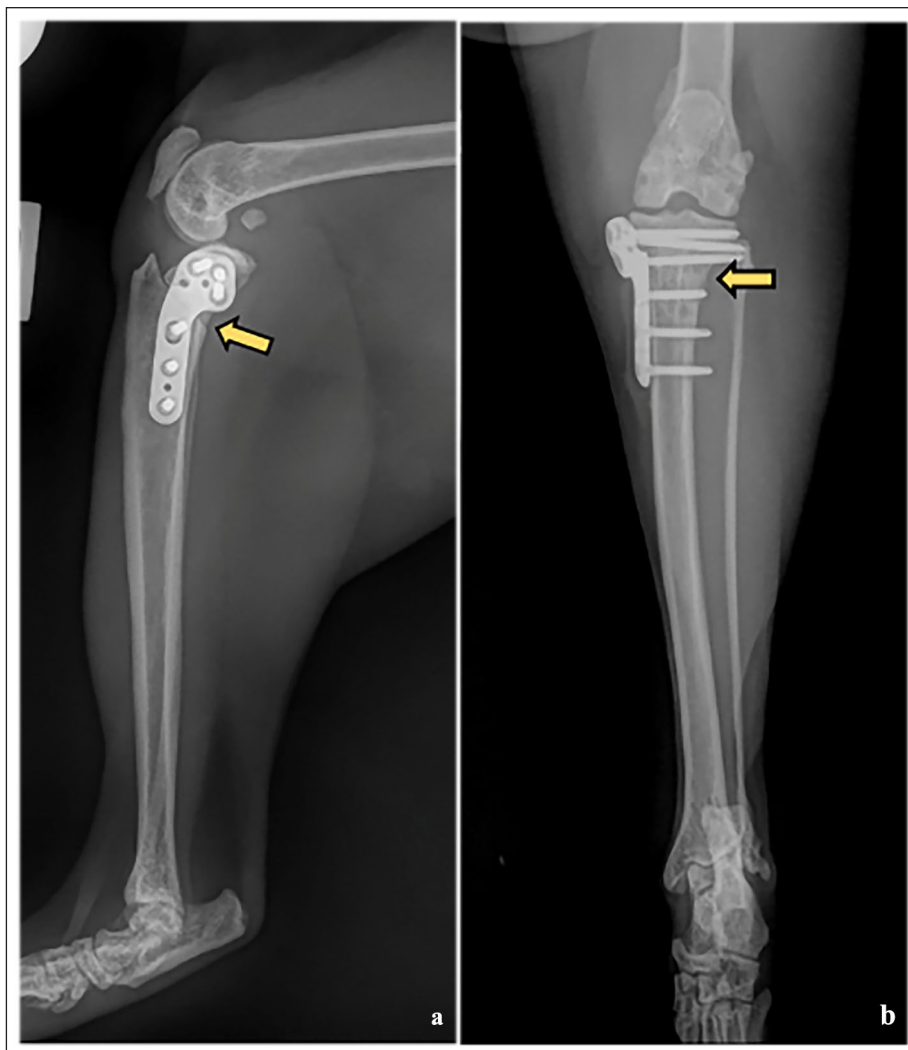


Figure 5 Orthogonal stifle radiographs 12 weeks postoperatively: (a) mediolateral view; and (b) posteroanterior view. The yellow arrows point to the presence of periosteal reaction, indicative of bone healing

placement was made strategically to address the identified instabilities effectively. For instance, in addressing caudal instability, screws were placed on the proximo-caudal aspect of the medial tibia and the caudodistal aspect of the medial femoral condyle. These locations were selected to target the specific vectors of instability and provide support in the appropriate directions. Similarly, when addressing external rotational instability, the decision to bring the remaining suture from the femoral interference screw to the cranial aspect of the tibia was made with the aim of counteracting the rotational forces acting on the joint. To our knowledge, this technique has not been previously described.

While the stifle exhibited external rotational instability, its cause remained unclear. It could be attributed to a stretched medial collateral ligament during the traumatic event or due to the combination of injuries

present in our case. The current literature states the CaCL is not involved in limiting external rotation; however, this is based on an old experimental study in which dogs' CaCLs were transected, and the CaCL's function was determined by measuring stifle instability after the procedure.³² Nevertheless, external rotation instability was not evaluated in that study. In humans, it has been demonstrated that the CaCL can withstand some degree of external rotation.³³ We hypothesise that similar biomechanical proprieties may be applicable to feline anatomy.

Postoperative immobilisation after surgical repair of traumatic stifle disruption in cats is controversial, with traditional approaches involving transarticular pins or skeletal fixators.^{6,7,24,34-36} Those methods provide a protective effect in the short term, but their associated complications, such as reduced synovial fluid formation, cartilage stiffness and thickness, limited range of motion,

cartilage fibrillation, cleft formation, intra-articular adhesions, periarticular contracture and development of osteoarthritis, must be considered.⁷ Coppola et al¹⁴ did not find a significant correlation between a lack of post-operative coaptation and a poorer outcome. The authors opted for a modified Robert-Jones bandage for 24h to control soft tissue swelling, followed by 6 weeks of strict exercise restriction, and no complications were encountered.

A significant limitation of the present case report is a lack of objective and long-term follow-up. Evaluating the lameness with a force plate analysis would have provided a better assessment of the clinical progression. In addition, it was not possible to repeat an orthopaedic examination and radiographs 8 months after surgery, leading to the use of the FMPI instead.

Conclusions

The present case suggests the combination of a TPLO and medial and lateral augmentation sutures as a successful treatment for traumatic feline stifle luxation with disruption of the CrCL, CaCL and both menisci. In this case, an excellent outcome was achieved, with no complications associated. This technique appears to warrant further investigation and larger clinical studies.

Acknowledgements The authors would like to acknowledge Anna Carbonell Bernadó for her assistance with the diagram design.

Supplementary material The following files are available as supplementary material, showing the absence of right hindlimb at stance, walk and trot:

Video 1

Video 2

Conflict of interest The authors declared no potential conflicts of interest with respect to the research, authorship, and/or publication of this article.

Funding The authors received no financial support for the research, authorship, and/or publication of this article.

Ethical approval The work described in this manuscript involved the use of non-experimental (owned or unowned) animals. Established internationally recognised high standards ('best practice') of veterinary clinical care for the individual patient were always followed and/or this work involved the use of cadavers. Ethical approval from a committee was therefore not specifically required for publication in *JFMS Open Reports*. Although not required, where ethical approval was still obtained, it is stated in the manuscript.

Informed consent Informed consent (verbal or written) was obtained from the owner or legal custodian of all animal(s) described in this work (experimental or non-

experimental animals, including cadavers) for all procedure(s) undertaken (prospective or retrospective studies). No animals or people are identifiable within this publication, and therefore additional informed consent for publication was not required.

References

- Voss K, Langley-Hobbs SJ and Montavon PM. **Stifle joint**. In: Montavon PM, Voss K and Langley-Hobbs SJ (eds). *Feline orthopaedic surgery and musculoskeletal disease*. Edinburgh: Elsevier, 2009, pp 475–490.
- Keeley B, Glyde M, Guerin S, et al. **Stifle joint luxation in the dog and cat: the use of temporary intraoperative transarticular pinning to facilitate joint reconstruction**. *Vet Comp Orthop Traumatol* 2007; 20: 198–203.
- Bruce WJ. **Multiple ligamentous injuries of the canine stifle joint: a study of 12 cases**. *J Small Anim Pract* 1998; 39: 333–340.
- Bruce WJ. **Stifle joint luxation in the cat: treatment using transarticular external skeletal fixation**. *J Small Anim Pract* 1999; 40: 482–488.
- Addison E and Conte A. **Management of severe stifle trauma: 1. Stifle luxation**. *J Feline Med Surg* 2019; 21: 419–428.
- McLaughlin RM. **Surgical diseases of the feline stifle joint**. *Vet Clin North Am Small Anim Pract* 2002; 32: 963–982.
- Jaeger GH, Wosar MA, Marcellin-Little DJ, et al. **Use of hinged transarticular external fixation for adjunctive joint stabilization in dogs and cats: 14 cases (1999–2003)**. *J Am Vet Med Assoc* 2005; 227: 586–591.
- Wessely M, Reese S and Schnabl-Feichter E. **Aetiology and pathogenesis of cranial cruciate ligament rupture in cats by histological examination**. *J Feline Med Surg* 2017; 19: 631–637.
- Harasen GLG. **Feline cranial cruciate rupture**. *Vet Comp Orthop Traumatol* 2005; 18: 254–257.
- Boge GS, Engdahl K, Moldal ER, et al. **Cranial cruciate ligament disease in cats: an epidemiological study of 50 cats (2011–2016)**. *J Feline Med Surg* 2019; 22: 277–284.
- Mindner JK, Bielecki MJ, Scharvogel S, et al. **Tibial plateau levelling osteotomy in eleven cats with cranial cruciate ligament rupture**. *Vet Comp Orthop Traumatol* 2016; 29: 528–535.
- Tamburro R, Collivignarelli F, Falerno I, et al. **Clinical outcomes and stifle osteoarthritis assessment of nine cats before and after tibial plateau levelling osteotomy**. *Acta Vet* 2020; 70: 346–354.
- Bilmont A, Retournard M, Asimus E, et al. **Effect of tibial plateau levelling osteotomy on cranial tibial subluxation in the feline cranial cruciate deficient stifle joint: an *in vivo* experimental study**. *Vet Comp Orthop Traumatol* 2018; 31: 273–278.
- Coppola M, Das S, Matthews G, et al. **Traumatic stifle injury in 72 cats: a multicentre retrospective study**. *J Feline Med Surg* 2022; 24: 587–595.
- Voss K and Steffen F. **Patient assessment**. In: Montavon PM, Voss K and Langley-Hobbs SJ (eds). *Feline orthopaedic surgery and musculoskeletal disease*. Edinburgh: Elsevier, 2009, pp 3–19.
- Slocum B and Slocum TD. **Tibial plateau leveling osteotomy for repair of cranial cruciate ligament rupture in the canine**. *Vet Clin North Am Small Anim Pract* 1993; 23: 777–795.

- 17 Arthrex Vet Systems. **TPLO, InternalBrace™ ligament augmentation: theory and rationale.** <https://www.arthrexvetsystems.com/resources/presentation/d8TPX-hPs0G2iwFePmfgUg/tplo-internalbrace-ligament-augmentation-theory-and-rationale> (2017, accessed 11 June 2023).
- 18 Comparative Pain Research Laboratory, North Carolina State University. **Feline musculoskeletal pain index.** <https://stateavevet.com/wp-content/uploads/2023/01/ncsu-cat-musculoskeletal-pain-index-fillable.pdf> (2015, accessed 5 April 2023).
- 19 Kowaleski MP, Boudrieau RJ and Pozzi A. **Stifle joint.** In: Johnston SA and Tobias KM (eds). *Veterinary surgery: small animal expert consult*. 2nd ed. St Louis, MO: Elsevier, 2018, pp 1071–1168.
- 20 Thieman KM, Pozzi A, Ling H-Y, et al. **Comparison of contact mechanics of three meniscal repair techniques and partial meniscectomy in cadaveric dog stifles.** *Vet Surg* 2010; 39: 355–362.
- 21 Innes JF and Barr ARS. **Clinical natural history of the postsurgical cruciate deficient canine stifle joint: year 1.** *J Small Anim Pract* 1998; 39: 325–332.
- 22 Wilke V, Robinson D, Rothschild MF, et al. **Estimate of the annual economic impact of treatment of cranial cruciate ligament injury in dogs in the United States.** *J Am Vet Med Assoc* 2005; 227: 1604–1607.
- 23 Hayashi K, Manley PA and Muir P. **Cranial cruciate ligament patophysiology in dogs with cruciate disease: a review.** *J Am Anim Hosp Assoc* 2004; 40: 385–390.
- 24 Umphlet RC. **Feline stifle disease.** *Vet Clin North Am Small Anim Pract* 1993; 23: 897–913.
- 25 Chauvet AE, Johnson AL and Pijanowski GK. **Evaluation of fibular head transposition, lateral fabellar suture, and conservative treatment of cranial cruciate ligament rupture in large dogs: a retrospective study.** *J Am Anim Hosp Assoc* 1996; 32: 247–255.
- 26 Gambardella PC, Wallace LJ and Cassidy F. **Lateral suture technique for management of anterior cruciate ligament rupture in dogs: a retrospective study.** *J Am Anim Hosp Assoc* 1981; 17: 33–38.
- 27 Vasseur PB and Berry CR. **Progression of stifle osteoarthritis following reconstruction of the cranial cruciate ligament in 21 dogs.** *J Am Anim Hosp Assoc* 1992; 28: 129–136.
- 28 Kim SE, Pozzi A, Kowaleski MP, et al. **Tibial osteotomies for cranial cruciate ligament insufficiency in dogs.** *Vet Surg* 2008; 37: 111–125.
- 29 Husi B, Park B, Lampart M, et al. **Comparative kinetic and kinematic evaluation of TPLO and TPLO combined with extra-articular lateral augmentation: a biomechanical study.** *Vet Surg* 2023; 52: 686–696.
- 30 Arnoczky SP and Marshall JL. **The cruciate ligaments of the canine stifle: an anatomical and functional analysis.** *Am J Vet Res* 1977; 38: 1807–1814.
- 31 Hefron LE and Campbell JR. **Morphology, histology and functional anatomy of the canine cranial cruciate ligament.** *Vet Rec* 1978; 102: 280–283.
- 32 Harari J, Johnson L, Stein LE, et al. **Evaluation of experimental transection and partial excision of the caudal cruciate ligament in dogs.** *Vet Surg* 1987; 16: 151–154.
- 33 Raj MA, Mabrouck A and Varacallo M. **Posterior cruciate ligament knee injuries.** In: StatPearls. Treasure Island, FL: StatPearls Publishing, 2024.
- 34 Laing EJ. **Collateral ligament injury and stifle luxation.** *Vet Clin North Am Small Anim Pract* 1993; 23: 845–853.
- 35 Connery N and Rackard S. **The surgical treatment of traumatic stifle disruption in a cat.** *Vet Comp Orthop Traumatol* 2000; 13: 208–211.
- 36 Welches CD and Scavelli TD. **Transarticular pinning to repair luxation of the stifle joint in dogs and cats: a retrospective study of 10 cases.** *J Am Anim Hosp Assoc* 1990; 26: 207–214.