



Colonic duplication cyst with secondary septic peritonitis in a cat

Authors: Schrock, Kelly, and Spinner, Maureen

Source: Journal of Feline Medicine and Surgery Open Reports, 10(1)

Published By: SAGE Publishing

URL: <https://doi.org/10.1177/20551169241256555>

BioOne Complete (complete.BioOne.org) is a full-text database of 200 subscribed and open-access titles in the biological, ecological, and environmental sciences published by nonprofit societies, associations, museums, institutions, and presses.

Your use of this PDF, the BioOne Complete website, and all posted and associated content indicates your acceptance of BioOne's Terms of Use, available at www.bioone.org/terms-of-use.

Usage of BioOne Complete content is strictly limited to personal, educational, and non - commercial use. Commercial inquiries or rights and permissions requests should be directed to the individual publisher as copyright holder.

BioOne sees sustainable scholarly publishing as an inherently collaborative enterprise connecting authors, nonprofit publishers, academic institutions, research libraries, and research funders in the common goal of maximizing access to critical research.



Colonic duplication cyst with secondary septic peritonitis in a cat

Kelly Schrock and Maureen Spinner

Journal of Feline Medicine and Surgery Open Reports
1–4

© The Author(s) 2024

Article reuse guidelines:

sagepub.com/journals-permissions

DOI: 10.1177/20551169241256555

journals.sagepub.com/home/jfmsopenreports

This paper was handled and processed by the American Editorial Office (AAFP) for publication in *JFMS Open Reports*



Abstract

Case summary A 5-month-old male castrated domestic shorthair cat was evaluated for acute onset of emesis. Abdominal radiographs identified a suspected colonic foreign body and abdominal-focused assessment with sonography for trauma, triage and tracking (AFAST) evaluation revealed a large amount of peritoneal effusion. Cytology of the peritoneal effusion was consistent with a septic exudate. An exploratory celiotomy identified a ruptured ileoceocolic mass and a resection and anastomosis was performed. No foreign material was identified and histopathology confirmed that the ruptured mass was a colonic duplication cyst. Recurrent septic peritonitis was diagnosed based on cytologic evaluation of fluid from a silicone bulb reservoir of a closed suction drain. No abnormalities were surgically identified, the cat recovered without complication, was discharged at 7 days postoperatively and has continued to remain healthy 8 months after surgical intervention.

Relevance and novel information To our knowledge, this is the first known instance of a histopathologically confirmed non-communicating colonic duplication cyst causing septic peritonitis in the veterinary literature.

Keywords: Colonic duplication cyst; intestinal duplication cyst; gastrointestinal; septic peritonitis

Accepted: 3 May 2024

Introduction

Colonic duplication cysts are a rare congenital anomaly in veterinary medicine, particularly in cats.^{1–6} Duplication cysts, which are theorized to be caused by anomalies in early embryonic development of the gastrointestinal tract, have varying morphologies, ranging from simple cysts to long tubular outpouchings, and may or may not share a blood supply and/or common opening into the true gastrointestinal tract.^{1–3} Previous reports of intestinal duplication cysts in cats have identified the cysts as an incidental finding or cause of mild gastrointestinal disease.^{1–3} Life-threatening complications secondary to intestinal cysts requiring emergency surgery have only been reported in humans^{7–10} and dogs.^{11,12} Of these cases, only one case of human intestinal duplication cysts resulted in septic peritonitis,¹⁰ and no cases of septic peritonitis have been reported in dogs. In this case report, we present a cat with septic peritonitis secondary to a ruptured non-communicating colonic duplication cyst. To our knowledge, this is the first report of a colonic duplication cyst causing secondary septic peritonitis in the veterinary literature.

Case description

A 5-month-old male castrated domestic shorthair cat weighing 3 kg (6.6 lbs) was presented to a specialty surgical center for evaluation of acute emesis over the preceding 12 h. The patient had no known past illnesses and was reportedly an otherwise healthy kitten.

On presentation, the patient was mildly hyperthermic with a temperature of 102.8°F (39.3°C). Heart rate and respiratory rate/effort were normal and no arrhythmias or murmurs were appreciated on cardiopulmonary auscultation. The only other abnormal physical examination finding was repeatable splinting upon abdominal palpation.

Small Animal Clinical Sciences, Michigan State University College of Veterinary Medicine, East Lansing, MI, USA

Corresponding author:

Maureen Spinner DVM, DACVS-SA, Small Animal Clinical Sciences, Michigan State University College of Veterinary Medicine, 736 Wilson Road, East Lansing, MI 48824, USA
Email: spinner@msu.edu



Creative Commons Non Commercial CC BY-NC: This article is distributed under the terms of the Creative Commons

Attribution-NonCommercial 4.0 License (<https://creativecommons.org/licenses/by-nc/4.0/>) which permits non-commercial use, reproduction and distribution of the work without further permission provided the original work is attributed as specified on the SAGE and Open Access pages (<https://us.sagepub.com/en-us/nam/open-access-at-sage>).

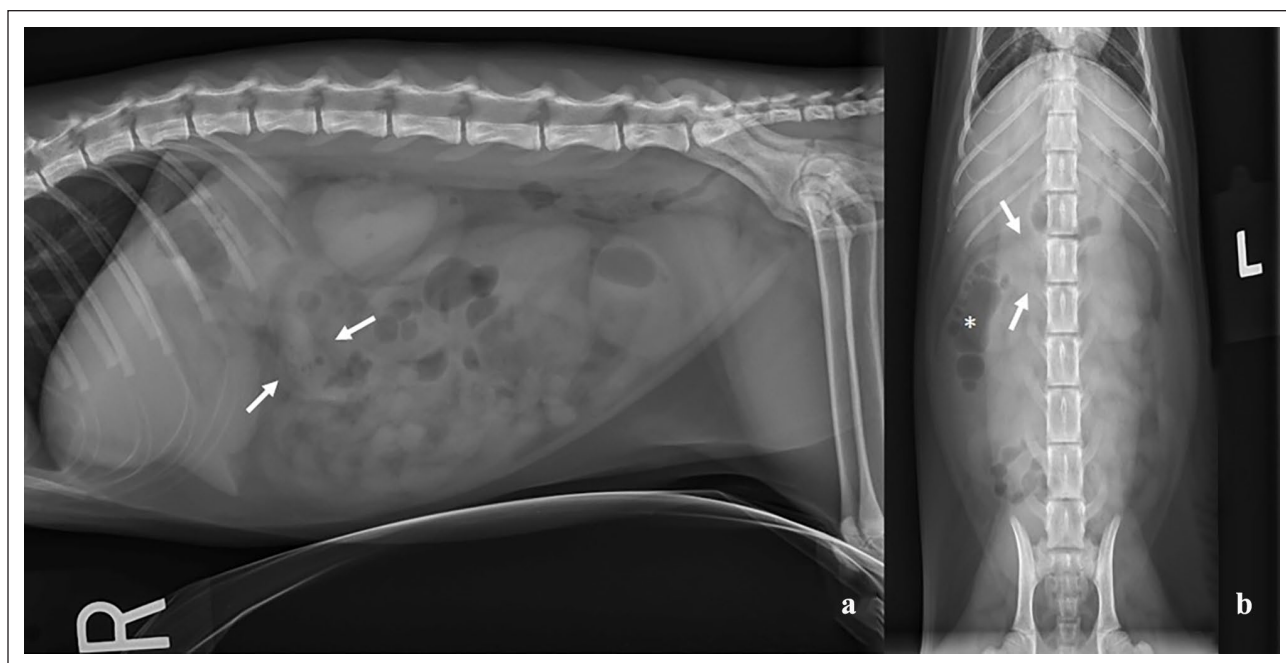


Figure 1 Abdominal radiographs with (a) right lateral and (b) ventrodorsal views of a non-radiopaque suspected foreign material present in the region of the transverse colon and superimposed with the second lumbar vertebra on ventrodorsal view (white arrows). Note the adjacent dilated intestinal loop containing a mixture of gas and fluid extending caudally from the foreign material along the right body wall on the ventrodorsal view (white asterisk)

Initial venous blood gas analysis identified no clinically significant abnormalities (Prime+ Vet; Nova) (pH 7.33 [reference interval (RI) 7.26–7.40], pCO₂ 27.5 mmHg [RI 27.2–41.4], HCO₃ 14.6 mmol/l [RI 13.9–22.8], Na 146 mmol/l [RI 148–154] and K 3.8 mmol/l [RI 3.3–4.7]). The patient was sedated using butorphanol (Torbugesic; Zoetis) (0.3 µg/kg IV) and dexmedetomidine (Dexdomitor; Zoetis) (3.3 µg/kg IV) for standard two-view abdominal radiographs that were interpreted by a boarded veterinary radiologist. A non-radiopaque structure measuring approximately 1 × 1.7 cm was visualized in the caudal abdomen at the level of the second lumbar vertebrae. The structure was interpreted as a suspected colonic foreign body with focal gas dilation in the transverse colon (Figure 1).

The patient was hospitalized for medical management and planned repeat abdominal radiographs but became increasingly nauseous and lethargic. An abdominal-focused assessment with sonography for trauma, triage and tracking (AFAST) revealed a large volume of peritoneal effusion. Abdominocentesis was performed and an in-house cytologic evaluation by an emergency clinician was consistent with a septic effusion containing intracellular cocci. A complete blood count (CBC) (Advia 2120; Siemens) found a normal hematocrit (41%, RI 33–50), clinically insignificant platelet count (130 × 10³/µl with platelet clumping [RI 168–438]), but evidence of significant inflammation, with a leukocytosis (24.19 × 10³/µl

[RI 6.3–19.6]) characterized by neutrophilia (22.25 × 10³/µl [RI 2.3–10.2]) and monocytosis (0.47 × 10³/µl [RI 0–0.4]). The patient was placed on ceftazidime (Tazicef; Pfizer) (30 mg/kg IV q4h) and clindamycin (Cleocin; Pfizer) (10 mg/kg IV q12h) in preparation for an exploratory celiotomy. The patient was premedicated with methadone (Generic; Amatheon) (0.3 mg/kg IV) and induced with alfaxalone (Alfaxan; Zoetis) (2 mg/kg IV). Intraoperatively, the patient experienced moderate hypotension that was managed with a norepinephrine (Levofedl; Pfizer) constant rate infusion (0.1 µg/kg/min) and received ceftazidime (30 mg/kg IV q90 mins).

An exploratory celiotomy was performed via a standard ventral midline incision. A mass involving the ileoceocolic junction was visualized. A rupture of the orad segment of the mass and associated ileum of approximately 1 cm was present and intestinal contents were seen leaking into the abdomen. The mass was excised and a hand-sutured end-to-end jejuncolic resection and anastomosis was routinely performed using 4-0 polydioxanone in a simple interrupted pattern. The suture line was then reinforced with a surgical sealant (PoliPhase; Avalon Medical) applied circumferentially. The remainder of the abdominal exploration was unremarkable. A 200 ml/kg sterile saline lavage was performed, aerobic and anaerobic peritoneal cultures were submitted, and a Jackson-Pratt drain (MILA International) was placed within the abdomen before

closure. The patient received a single peri-incisional dose of liposomal bupivacaine (Nocita; Elanco) 0.4 ml/kg SC and the mass was submitted for histopathological evaluation. The patient recovered uneventfully from anesthesia, with normal postoperative vital parameters (temperature 101.1°F [38.4°C], heart rate 210 beats/min, respiratory rate 28 breaths/min and mean arterial pressure 110 mmHg).

Supportive care was continued using lactated Ringer's solution (2 ml/kg/h IV), ceftazadime (30 mg/kg IV q4h), gabapentin (Neurontin; Pfizer) (12 mg/kg PO q8h) and drain production monitoring. On the second day postoperatively, the patient developed diarrhea and the Jackson-Pratt drain output increased from 19 ml/kg/day to 41 ml/kg/day over a 24 h period. Recurrent septic peritonitis, concerning for surgical site dehiscence, was diagnosed based on an in-house cytologic evaluation by emergency clinicians of fluid obtained from the bulb reservoir of the closed suction drain reservoir as opposed to abdominocentesis or by sterile collection from the drain line. Re-exploration was pursued before the discovery of the collection method and no abnormalities with the alimentary tract were identified. The anastomosis site was leak checked multiple times and all sutures were intact. The peritoneum and surrounding intestines appeared grossly normal. Repeat cultures were obtained, the previously placed closed suction drain was removed and a new drain was placed.

The patient recovered uneventfully from the second anesthetic event (temperature 101.8°F [38.8°C], heart rate 235 beats/min, respiratory rate 32 breaths/min and mean arterial pressure 130 mmHg) and standard postoperative hospital care was continued. Surgical findings prompted further discussions, which led to the discovery that the effusion sample had been obtained from the closed-suction drain bulb reservoir rather than by abdominocentesis or by sterile collection from the drain line. A postoperative venous blood gas analyses was performed and remained clinically unremarkable (pH 7.37 [RI 7.26–7.40], pCO₂ 35.0 mmHg [RI 27.2–41.4], HCO₃ 20.5 mmol/l [RI 13.9–22.8], Na 147 mmol/l [RI 148–154] and K 3.1 mmol/l [RI 3.3–4.7]). The patient's sequential Jackson-Pratt drain output continued to decrease each day until removal 7 days postoperatively from the original surgery.

Initial culture results had identified few *Escherichia coli* and moderate *Enterococcus faecium* coliforms with associated susceptibility results. The patient was started on a 2-week course of amoxicillin-clavulanate (Clavamox; Zoetis) 14.5 mg/kg PO q12h and pradofloxacin (Veraflox; Elanco) 8 mg/kg PO q24h. The second surgical culture and susceptibility results ultimately identified few *Enterococcus faecalis* and *E faecium* coliforms. No changes were made to the antibiotic regimen based on these results

and available susceptibility results. The patient was discharged 7 days postoperatively with the previously prescribed amoxicillin-clavulanate and pradofloxacin.

A histopathologic evaluation identified the resected ileocecolic junction mass as a non-communicating (containing a discrete blood supply and completely separated lumen from adjacent intestine) colonic duplication cyst with marked segmental ulceration, necrosis and fibrinosuppurative serositis.

The patient was evaluated by the primary care veterinarian 2 weeks after discharge from the hospital for incision evaluation and was reportedly doing well without complications. At the time of writing (8 months postoperatively), the owner was contacted and reported the cat to be free of clinical signs and experiencing an excellent quality of life.

Discussion

Reports of intestinal duplication cysts are uncommon in the veterinary literature. In cats, reports of both communicating and non-communicating duplication cysts involving the duodenum and, more rarely, the colon and rectum have been published within the past decade.^{1–6} Previous case reports in humans with intestinal duplication cysts that required surgical intervention were due to the development of severe secondary gastrointestinal disease, which included gastric outflow obstruction, intestinal mucosal ulceration, torsion, malignant transformation and intussusception.^{7–9} Septic peritonitis secondary to a ruptured colonic duplication cyst in a human was documented in a single case report;¹⁰ however, no reports of feline or canine colonic duplication cysts resulting in septic peritonitis exist to the best of the authors' knowledge. All known cases of intestinal or colonic duplication cysts in cats were either incidental findings surgically removed electively for histopathologic evaluation or surgically removed to manage mild non-emergent clinical signs, such as chronic inappetence, diarrhea or constipation.^{1–3} Two canine proximal gastrointestinal duplication cysts required emergency surgical intervention for suspected pyloric outflow obstruction, but not concurrent sepsis.^{11,12} Therefore, the current case of a ruptured feline colonic duplication cyst leading to septic peritonitis is the first veterinary medicine reported instance of an intestinal duplication cyst requiring emergent surgical intervention for septic peritonitis.

During hospitalization, the patient in this case report underwent a second emergency exploratory celiotomy due to concern for surgical site dehiscence. The decision to re-explore the abdomen was made on the basis of the in-house cytologic evaluation performed by the emergency clinician. As no intraoperative leakage was identified, a postoperative inquiry revealed that the reported abdominal effusion sample was actually collected from

the Jackson-Pratt drain silicone bulb reservoir rather than by abdominocentesis. Sampling from a closed drain system has been historically not advised. Drains are infrequently utilized in human plastic and orthopedic surgery, and studies evaluating their use as a diagnostic in evaluating for true surgical site infections found that the overall infection rate was only 5.6% despite 63.4% of drain fluid samples culturing positive for bacterial growth;¹³ furthermore, drain tip cultures from this population of procedures had a significant positive correlation with the presence of true surgical site infections.¹⁴ Based on these findings, we postulate that the presence of bacteria in the drain reservoir bulb was unrelated to the presence of intra-abdominal bacteria. The second postoperative culture, which was positive, was likely due to a combination of residual bacterial organisms from the original surgery and contamination via ascending coliforms growing in the closed collection system. If questions regarding the integrity of a surgical incision arises after intestinal resection and anastomosis, culture from the drain catheter tip or direct abdominocentesis would be advised. If this sampling methodology had been utilized, we postulate that the patient presented in the current case would not have undergone a second surgery.

Conclusions

To our knowledge, this is the first known case in the veterinary literature of a colonic duplication cyst leading to secondary septic peritonitis. The underlying etiology of the rupture remains unknown but expands the differential list to be considered for causes of septic peritonitis in cats. Should future cases be identified in practice, a case series retrospective analysis may prove helpful in identifying potential risk factors for septic peritonitis secondary to duplication cysts.

Conflict of interest The authors declared no potential conflicts of interest with respect to the research, authorship, and/or publication of this article.

Funding The authors received no financial support for the research, authorship, and/or publication of this article.

Ethical approval The work described in this manuscript involved the use of non-experimental (owned or unowned) animals. Established internationally recognized high standards ('best practice') of veterinary clinical care for the individual patient were always followed and/or this work involved the use of cadavers. Ethical approval from a committee was therefore not specifically required for publication in *JFMS*

Open Reports. Although not required, where ethical approval was still obtained it is stated in the manuscript.

Informed consent Informed consent (verbal or written) was obtained from the owner or legal custodian of all animal(s) described in this work (experimental or non-experimental animals, including cadavers) for all procedure(s) undertaken (prospective or retrospective studies). No animals or people are identifiable within this publication, and therefore additional informed consent for publication was not required.

References

- 1 Fruehwald C and Ellison G. **Successful surgical correction of congenital colonic duplication and anogenital cleft in a cat.** *J Am Anim Hosp Assoc* 2020; 56: 170–174.
- 2 Phipps WB, Rich AF and Rossanese M. **Asymptomatic enteric duplication cyst in a geriatric cat: case report and review of the literature.** *J Am Anim Hosp Assoc* 2021; 57: 133–138.
- 3 Agut A, Carrillo JD, Martínez M, et al. **Imaging diagnosis – radiographic, ultrasonographic, and computed tomographic characteristics of a duodenal duplication cyst in a young cat.** *Vet Radiol Ultrasound* 2018; 59: E22–E27.
- 4 Kook PH, Hagen R, Willie B, et al. **Rectal duplication cyst in a cat.** *J Feline Med Surg* 2010; 12: 978–981.
- 5 Carbonell BE, Billet JP, Vanel M, et al. **Rectal duplication in an adult cat: a novel transanal surgical approach.** *JFMS Open Rep* 2020; 6. DOI: 10.1177/2055116920916956.
- 6 Bernardé A, Forget J and Bernard F. **Multiple level enteric duplication cysts in a cat.** *Rev Vét Clin* 2014; 49: 31–35.
- 7 Al-Shaibi MA, Raniga SB, Asghar ANM, et al. **Caecal duplication cyst leading to intussusception in an adult.** *BMJ Case Rep* 2019; 12. DOI: 10.1136/bcr-2019-230567.
- 8 Ademuyiwa AO, Bode CO, Adesanya OA, et al. **Duplication cyst of ascending colon presenting as an ileal volvulus in a child: a case report and review of literature.** *Afr J Paediatr Surg* 2012; 9: 237–239.
- 9 McPherson AG, Trapnell JE and Airth GR. **Duplication of the colon.** *Br J Surg* 1969; 56: 138–142.
- 10 Rasul L, Javed N, Liaqat N, et al. **Ruptured duplication cyst of transverse colon.** *Afr J Paediatr Surg* 2021; 18: 109–110.
- 11 Mutascio L, Vilaplana Grosso F, Ramos-Vara J, et al. **Multimodality characterization of a noncommunicating congenital duodenal duplication cyst causing pyloric outflow obstruction in a young dog.** *Vet Radiol Ultrasound* 2019; 60: E10–E14.
- 12 Jack MW, Burgess D and Griffin A. **Non-communicating gastric duplication cyst in a 10-week-old Labrador Retriever puppy.** *Aust Vet J* 2016; 94: 166–170.
- 13 Reiffel AJ, Pharmer LA, Weinstein AL, et al. **A prospective analysis of the association between indwelling surgical drains and surgical site infection in plastic surgery.** *Ann Plast Surg* 2013; 71: 561–565.
- 14 Sankar B, Ray P and Rai J. **Suction drain tip culture in orthopaedic surgery: a prospective study of 214 clean operations.** *Int Orthop* 2004; 28: 311–314.