

## **Commonalities Between COVID-19 and Radiation Injury**

Authors: Rios, Carmen I., Cassatt, David R., Hollingsworth, Brynn A., Satyamitra, Merriline M., Tadesse, Yeabsera S., et al.

Source: Radiation Research, 195(1) : 1-24

Published By: Radiation Research Society

URL: <https://doi.org/10.1667/RADE-20-00188.1>

---

BioOne Complete ([complete.BioOne.org](https://complete.BioOne.org)) is a full-text database of 200 subscribed and open-access titles in the biological, ecological, and environmental sciences published by nonprofit societies, associations, museums, institutions, and presses.

Your use of this PDF, the BioOne Complete website, and all posted and associated content indicates your acceptance of BioOne's Terms of Use, available at [www.bioone.org/terms-of-use](https://www.bioone.org/terms-of-use).

Usage of BioOne Complete content is strictly limited to personal, educational, and non - commercial use. Commercial inquiries or rights and permissions requests should be directed to the individual publisher as copyright holder.

---

BioOne sees sustainable scholarly publishing as an inherently collaborative enterprise connecting authors, nonprofit publishers, academic institutions, research libraries, and research funders in the common goal of maximizing access to critical research.

## REVIEW

# Commonalities Between COVID-19 and Radiation Injury

Carmen I. Rios,<sup>1</sup> David R. Cassatt, Brynn A. Hollingsworth, Merriline M. Satyamitra, Yeabsera S. Tadesse, Lany P. Taliaferro, Thomas A. Winters and Andrea L. DiCarlo

*Radiation and Nuclear Countermeasures Program (RNCP), Division of Allergy, Immunology and Transplantation (DAIT), National Institute of Allergy and Infectious Diseases (NIAID), National Institutes of Health (NIH), Rockville, Maryland*

---

Rios, C. I., Cassatt, D. R., Hollingsworth, B. A., Satyamitra, M. M., Tadesse, Y. S., Taliaferro, L. P., Winters, T. A. and DiCarlo, A. L. Commonalities Between COVID-19 and Radiation Injury. *Radiat. Res.* **195**, 1–24 (2021).

As the multi-systemic components of COVID-19 emerge, parallel etiologies can be drawn between SARS-CoV-2 infection and radiation injuries. While some SARS-CoV-2-infected individuals present as asymptomatic, others exhibit mild symptoms that may include fever, cough, chills, and unusual symptoms like loss of taste and smell and reddening in the extremities (e.g., “COVID toes,” suggestive of microvessel damage). Still others alarm healthcare providers with extreme and rapid onset of high-risk indicators of mortality that include acute respiratory distress syndrome (ARDS), multi-organ hypercoagulation, hypoxia and cardiovascular damage. Researchers are quickly refocusing their science to address this enigmatic virus that seems to unveil itself in new ways without discrimination. As investigators begin to identify early markers of disease, identification of common threads with other pathologies may provide some clues. Interestingly, years of research in the field of radiation biology documents the complex multi-organ nature of another disease state that occurs after exposure to high doses of radiation: the acute radiation syndrome (ARS). Inflammation is a key common player in COVID-19 and ARS, and drives the multi-system damage that dramatically alters biological homeostasis. Both conditions initiate a cytokine storm, with similar pro-inflammatory molecules increased and other anti-inflammatory molecules decreased. These changes manifest in a variety of ways, with a demonstrably higher health impact in patients having underlying medical conditions. The potentially dramatic human impact of ARS has guided the science that has identified many biomarkers of radiation exposure, established medical management strategies for ARS, and led to the development of medical countermeasures for use in the event of a radiation public health emergency. These efforts can now be leveraged to help elucidate mechanisms of action of COVID-19 injuries. Furthermore, this intersection between COVID-19 and ARS may point to approaches

that could accelerate the discovery of treatments for both. © 2021 by Radiation Research Society

---

## INTRODUCTION

The world is currently in the grip of a global pandemic. As of September 10, 2020, over 50 million cases of COVID-19, the disease caused by severe acute respiratory syndrome coronavirus 2 (SARS-CoV-2), have been reported worldwide. At the forefront of directing research activities focused on combating COVID-19 is the National Institute of Allergy and Infectious Diseases (NIAID) within the U.S. National Institutes of Health (NIH). In April 2020, the NIAID published the *NIAID Strategic Plan for COVID-19 Research*<sup>2</sup> describing NIAID’s efforts to better understand SARS-CoV-2 and to accelerate the development of safe biomedical tools. The plan is a well-defined document that focuses on four research priorities: improving fundamental knowledge of SARS-CoV-2 and COVID-19; supporting the development of diagnostics and assays; characterizing and testing therapeutics; and developing safe and effective vaccines against SARS-CoV-2. A detailed research plan for each priority area is described in the document.

The novelty of the 2019 novel coronavirus disease (COVID-19) is underscored by the fact that there are no FDA-approved or licensed therapeutics specific for coronaviruses. The traditional drug development pathway for therapeutics (and diagnostic tools) can be a years-long process with milestones that require extensive resources to achieve. However, the urgency of the COVID-19 pandemic emphasizes the need for rapid development and testing of promising therapeutic and diagnostic candidates. Approaches to accelerate the development process are being explored in other areas of science where overlapping trends can be

<sup>1</sup> Address for correspondence: RNCP, DAIT, NIAID, NIH, 5601 Fishers Lane, Room 7A69, Rockville, MD 20892-9828 (20852 for express mail); email: carmen.rios@nih.gov.

<sup>2</sup> NIAID strategic plan for COVID-19 research FY2020–FY2024, April 22, 2020. (<https://bit.ly/3mFnb2e>)

investigated. Therapeutics developed for other clinical indications could potentially be repurposed to treat COVID-19; some of those possibilities are discussed in this review. Likewise, pathological features and manner of progression of other indications similar to COVID-19 could elucidate how to effectively mitigate and treat this disease. In this review, we describe observed parallels between COVID-19 and the biological effects of radiation injury that include immediate and long-term components: the acute radiation syndrome (ARS) and the delayed effects of acute radiation exposure (DEARE).

The Radiation and Nuclear Countermeasure Program (RNCP) within the NIAID is one such program in which the scientific work is relevant to the COVID-19 response. The RNCP was initiated in 2004, with the mission of supporting research to develop medical countermeasures to diagnose (biodosimetry) and treat radiation injuries leading to ARS and DEARE in the wake of a radiation public health emergency. The marked similarities between COVID-19 and radiation injuries described in this review have a major underpinning: the inflammatory response. Several products currently in development within the RNCP to treat radiation exposure operate by targeting inflammation that can lead to tissue damage. In fact, approaches developed to treat radiation-induced lung fibrosis and vascular damage merit investigating and are discussed here in the context of COVID-19.

## TARGETS

Here we highlight some of the systems and immunological areas affected by both COVID-19 and acute radiation exposure, albeit to different levels. In both cases, the result is a systemic insult that can cause damage to many parts of the body, including the vascular system, lung, heart, kidneys, liver, gut, eyes and brain. Regardless of the target organ, the hyperactivation of the immunogenic pathways are at the heart of the body's response to overcome SARS-CoV-2 and acute radiation exposure (1). Cytokines are produced by a variety of immune cells (i.e., macrophages, B lymphocytes, T lymphocytes and mast) and non-immune cells (i.e., endothelial, fibroblasts and stromal). Under normal circumstances, cytokines have a short half-life and act as local mediators within a microenvironment; therefore, circulating cytokines in the blood are below the limit of detection of most commercially available assay kits (2). This complex communication network provides a healthy immune system with the proper signals to mount a proportionate response against an infectious agent or inflammatory stimuli. In other cases, the reaction is so strong that circulating cytokine levels surge, resulting in a "cytokine storm" (also called hypercytokinemia<sup>3</sup>) or an overaction of the immune system creating a generalized

inflammatory response that can lead to systemic tissue damage. The cytokine storm is the nexus between SARS-CoV-2 infection and radiation exposure; both result in systemic inflammation that ravages the body (1, 3).

A wealth of early literature has described the cytokine storm syndrome (CSS) in COVID-19 patients (4–15). For example, in a study of 50 patients, expression levels of 14 of 48 cytokines studied were associated with disease severity and progression, with interferon (IFN)- $\gamma$ -induced protein 10 and monocyte chemotactic protein-3 noted as excellent predictors of disease progression (16). Increases in granulocyte-macrophage colony-stimulating factor (GM-CSF) and interleukin-6 (IL-6) due to T-cell overactivation were also noted (17). Another retrospective study with 3,939 patients shows both mild and severe forms of COVID-19 disease resulting in changes in circulating leukocyte subsets and cytokine secretion (8). In particular, Vaninov *et al.* noted that persistent high levels of three cytokines (CXCL10, CCL7 and IL-1 receptor antagonist) were associated with increased viral load, loss of lung function, lung injury and a fatal outcome (12). Based on these kinds of findings of elevated levels of specific cytokines, in June 2020 the FDA issued an Emergency Use Authorization (EUA) for an *in vitro* diagnostic test based on measuring the circulating IL-6 levels in serum or plasma for the management of patients with COVID-19<sup>4</sup> (discussed in more detail below). However, emerging technologies measuring "cytokine signatures" demonstrate variability across subjects and highlight the need for the development of personalized treatments based on these data.

As observed with COVID-19, cytokines are also released by many cells after radiation exposure, including endothelial cells, fibroblasts, immune cells and parenchymal cells. The interplay and early activation of inflammatory reactions involving proteins in cytokine cascade, such as fibroblast growth factor (FGF), transforming growth factor (TGF), tumor necrosis factor (TNF- $\alpha$ ), and interleukins (ILs) is thought to be responsible for DEARE. Cytokines and chemokines that attract immune cells and lead to inflammation include IL-1 $\alpha$  and IL-6. Inflammatory cells cause numerous other changes to occur, such as cell death, promotion of fibrosis and swelling of the tissue. These cytokines are involved in both early and late reactions, like the major cytokines in the response of skin cells to ionizing radiation, and include IL-1, IL-6, tumor necrosis factor (TNF)- $\alpha$ , transforming growth factor (TGF)- $\beta$ , which can be pro- or anti-inflammatory depending on the tissue and context of release, and the chemokines IL-8 and eotaxin (18). Cytokines can be broadly grouped as pro-inflammatory cytokines such as TNF- $\alpha$ , IL-1 $\alpha$  and  $\beta$ , IL-17; angiogenic/vascular endothelial growth factor (VEGF),

<sup>3</sup> NIH/National Cancer Institute. NCI Dictionaries. Cytokine storm. (<https://bit.ly/35RIp73>)

<sup>4</sup> U.S. Food and Drug Administration. Letter to Linda McCamack, Senior Regulations Manager, Roche Diagnostics. Emergency use authorization for Elecsys IL-6. June 2, 2020. (<https://bit.ly/32NzWzG>)

TNF- $\alpha$  and FGF; anti-inflammatory IL-4, IL-10 and TGF- $\beta$ ; pro-fibrotic IL-6 and TGF- $\beta$ ; immune IL-2, IL-4 and IL-7; and hematopoietic CSF1, GM-CSF, IL-3 and EPO (19). Interestingly, persistence of inflammatory cytokines, chemokines and growth factors, such as TGF- $\beta$ , IFN- $\gamma$ , ET-1, IL-4, IL-13, lead to pulmonary fibrosis (20). Notably, IL-6, which appears to be a key player in the response to SARS-CoV-2, is altered after irradiation as well; however, its role in radiation-induced lung injury is still unclear (21).

In addition to the cytokine storm, dysregulation of the renin-angiotensin system (RAS) plays a critical role in the pathogenesis of COVID-19 (22) and radiation exposure. The RAS pathway, which regulates the body's fluid regulation system, is dependent on angiotensin converting enzyme (ACE) and ACE2. ACE regulates blood pressure, water, and sodium levels as well as inflammation, proliferation and vasoconstriction. ACE2, the target receptor of SARS-CoV-2, is involved in degrading AngII to produce Ang 1-7 and then further to angiotensin 1-5, which is the effector peptide (23). ACE2 can be found in a variety of organs (e.g., heart, kidney, adipose tissue, vascular smooth muscle cells, brain tissue, testis, gastrointestinal (GI) tract, etc.). Together ACE/ACE2 promote vasodilation to reduce blood pressure and maintain homeostasis of the RAS. ACE2 is expressed throughout the body, so it is no surprise that it plays many physiological roles, which extend beyond its ability to reduce blood pressure. These include cardiac and lung protection by ACE2. A mouse study by Imai *et al.* shows that AngII, upregulated by ACE, drives severe lung failure through the AT1a receptor while ACE2 and the AT2 receptors protect against lung injury. The group showed that exogenous recombinant human ACE2 reduces acute lung failure in ACE2 knockout and wild-type mice (24, 25), and impacts GI dysregulation and diabetic complications (26). As SARS-CoV-2 (27) binds ACE2, it is possible that ACE2 receptors are downregulated, causing an imbalance in the RAS (28).

Both cytokine and RAS disequilibria may have implications in the development of lung and other organ injuries for both COVID-19 (3, 22, 27) and ionizing radiation exposure (29, 30), although the interplay is complex and not completely understood. In general, SARS-CoV-2 infection (31) and ionizing radiation exposure (31) trigger pro-inflammatory cytokines (e.g., IFN- $\alpha$ , IFN- $\gamma$ , IL-1 $\beta$ , IL-6, IL-12, IL-18, IL-33, TNF- $\alpha$ , TGF- $\beta$ , etc.). In the case of COVID-19, the lung is the most prevalent initial target and, in some cases, the injury progresses from pneumonitis (32, 33) to acute respiratory distress syndrome (ARDS). This heightened chronic inflammatory response creates a pro-fibrotic environment that yields long-term fibrosis followed by organ dysfunction. Similarly, exposure to radiation can also result in lung fibrosis (34–36) as well as injury to other organs (37–39).

The vasculature is also targeted by SARS-CoV-2, as evidenced by the prevalence of systemic thrombotic events (40), endotheliitis (endothelial inflammation) (41) and

“COVID toes” (suggesting dysfunction of microvessels in the extremities) (42, 43). The virus has been shown to directly infect endothelial cells (41), and their subsequent dysregulation likely explains the many vascular coagulopathies and thromboses that have been noted in COVID-19 patients. Recently, Zamboni (44) described COVID-19 as a vascular disease, with the endothelial cell emerging as a potent target for SARS-CoV-2, while the endothelium is called “the lynchpin” of COVID-19 pathogenesis, orchestrating the cytokine storm and damage to multiple organs (45). In severe cases, this dysfunction has led to strokes (46) and other cardiovascular involvement (47). Similarly, acute radiation exposure leads to vascular injury (48) by way of apoptosis and senescence of endothelial cells as well as via an increase in cell adhesion molecules (49) and dysregulation of coagulation homeostasis (50).

Another common target of SARS-CoV-2 and acute radiation exposure is the pyroptosis pathway or caspase-1-dependent programmed cell death of eukaryotic cells. Pyroptosis is a mechanism by which the body's innate immune system clears pathogens and promotes an adaptive immune response. Caspase-1 initiates inflammation that results in the formation of plasma-membrane pores in pathogen-infected cells, enabling water to enter, causing swelling and osmotic lysis. In addition, caspase-1 promotes cleavage of chromosomal DNA and nuclear condensation. Caspase-1 is activated by Toll-like receptors (TLRs) and NOD-like receptors (NLRs) present on immune cells, such as macrophages or epithelial cells, which sense extracellular and intracellular danger signals produced by pathogens or tissue injury. This cellular communication network results in an inflammatory cascade initiated by NF- $\kappa$ B, mitogen-activated protein kinase (MAPK)- and interferon-regulatory factor (IRF)- dependent pathways, activating IFN- $\alpha/\beta$ , TNF- $\alpha/\beta$ , IL-12, IL-6, IL-8 and pro-IL-1 $\beta$ . The pyroptosis pathway is also implicated in immune cell death (e.g., in the spleen) after acute radiation exposure (51, 52). Furthermore, the NF- $\kappa$ B/TNF- $\alpha$  signaling pathway is also activated in response to ionizing radiation, resulting in a similar cytokine cascade. In fact, a recently published study showed that pyroptosis may play a role in radiation-induced lung inflammation and fibrosis (53).

## BIOMARKERS

### *Biomarkers in Pathophysiology of COVID-19 and Radiation Injury*

There is a remarkable similarity in the pattern of biomarker response to SARS-CoV-2 infection and radiation exposure. Significant changes in hematological, chemical, inflammatory and immune biomarkers are seen in COVID-19 and in irradiated patients. Although the insult (infection or acute radiation exposure) is vastly different, the ensuing pathologies converge to multiorgan dysfunction (MOD), resulting in multiorgan failure (MOF) and mortality. Biomarkers unique



to each insult, such as smell dysfunction for COVID-19, or cytogenetic, genomic or metabolomic approaches for radiation biodosimetry are not discussed here.

### Hematology

The classical approach of hematology has emerged as a valuable tool in predicting outcome as well as stratifying and management of COVID-19 patients (54–59). For example, a retrospective analysis compared hemocyte counts (neutrophils, lymphocytes and platelets; or “NLP score”) and found a strong correlation between NLP score and COVID-19 disease progression, while another published study noted lymphocyte decrease associated with COVID-19 severity (60, 61). Furthermore, Chen *et al.* conducted a retrospective study on 548 patients and noted that the counts of lymphocytes, T-cell subsets, eosinophils and platelets decreased markedly, especially in severe/critical and fatal patients. Increased neutrophil count and neutrophil-to-lymphocyte ratio were predominant in severe/critical cases or non-survivors (61). From separate studies, it was observed that an increase in the neutrophil-to-lymphocyte ratio (NLR) is an early warning signal for severe COVID-19 (59, 62, 63). These data are further supported by findings from a published study of 75 patients from Suzhuo, China with confirmed COVID-19 infection; common COVID-19 abnormal hematological indexes on admission included hyperfibrinogenemia, lymphopenia, elevation of D-dimer, and leukopenia, which were significantly different between the mild/moderate and severe COVID-19 groups. Furthermore, the dynamic change of NLR and D-dimer level can distinguish severe COVID-19 cases from the mild/moderate (64).

Hematological data could be further refined to interrogate a single cell population (such as lymphocytes or platelets) that yielded significant correlation with COVID-19 progression and severity. A meta-analysis of 3,099 patients from 24 different studies showed that patients who did not fare well had low lymphocyte counts (mean difference of  $-361.06/\mu\text{l}$ ) compared to patients who had good outcomes (65). Other researchers have also reported lymphopenia as a key biomarker in COVID-19 patients (66–68); Terpos *et al.* (68) referred to lymphopenia as “a cardinal laboratory finding, with prognostic potential,” urging for the need for longitudinal evaluation of parameters to follow the dynamics of the disease progression. Thrombocytopenia is also commonly noted among patients hospitalized with COVID-19 and a low platelet count is associated with higher mortality (57, 69–74). It is hypothesized that SARS-CoV-2 infects both bone marrow cells and platelets via the CD13 receptor, inducing growth inhibition and apoptosis. This entry disrupts hematopoiesis, resulting in thrombocytopenia. Another cause of thrombocytopenia is attributed to lung injury due to activation, aggregation, and retention of platelets in the lung. The formation of thrombus at the site of lung injury leads to decreased platelet production and

increased consumption (75, 76). Interestingly, in most cases the platelet decreases did not reach a level where spontaneous bleeding occurred.

As seen with COVID-19 patients, radiation exposure also results in profound hematological perturbations in humans as well as irradiated animal models, characterized by granulocytopenia, lymphopenia and thrombocytopenia (77–81). Unlike COVID-19, significant decreases in neutrophils, in addition to other cytopenias, is a hallmark of ARS (82). The SEARCH (System for Evaluation and Archiving of Radiation accidents based on Case Histories) (82) database contains 824 clinical cases from 81 radiation accidents in 19 countries and allows detailed analysis of the time course of ARS, with the intention to study all medical aspects of ARS and to derive medical treatment protocols for radiation accident victims (MEDical TREATment PROTOCOLS; METREPOL) (83). The hematopoietic syndrome can be characterized by granulocyte count kinetics (84). The Radiation Emergency Medical Management (REMM)<sup>5</sup> website provides guidance on triaging radiation accident victims based on lymphocyte depletion kinetics. The kinetics of lymphocyte depletion have been shown to be directly related to the absorbed radiation dose from 0.5 to 10 Gy (85–87). Furthermore, the ratio of neutrophil to lymphocyte has been employed to determine the radiation dose exposure (88–90). Interestingly, platelet depletion alone has not been used to determine radiation dose, although thrombocytopenia correlates directly with radiation dose and platelet utilization at sites of active bleeding.

### Serum Biomarkers

Patients with moderate and severe COVID-19 showed significant increase in levels of serum amyloid A (SSA), C-reactive protein (CRP) which positively correlated to COVID-19 pneumonia (24), and serum albumin (ALB) levels ( $P < 0.05$ ) (62). Radiation also induces increases in the serum and urine proteome. CRP and serum amylase are commonly elevated after radiation exposure (91–93). In the criticality accident at Tokaimura, all three patients presented with elevated serum amylase (94). CRP levels were reported to correlate with clinical outcome in patients exposed to radiation during the Chernobyl nuclear accident (95). From a published study that identified 260 radiation-responsive proteins (96), Partridge *et al.* (97) narrowed the panel to IL-6, IL-1 $\beta$ , TNF- $\alpha$  and TGF- $\beta$  levels as being strongly correlated to irradiation, with IL-6 emerging as the best marker for COVID-19 and acute radiation exposure.

### Electrolytes

Electrolyte imbalance with reduced potassium, calcium, chloride and sodium is observed in patients with COVID-19

<sup>5</sup> U.S. Dept. of Health and Human Services. REMM/Radiation Emergency Medical Management. Guidance on diagnosis and treatment for healthcare providers. (<https://www.remm.nlm.gov/>)

(72, 76, 98). Pooled analysis of data on serum electrolytes confirms that hyponatremia, hypokalemia and hypocalcemia are associated with COVID-19 severity; however, the authors cautioned that additional information such as calcium concentrations, serum albumin levels and the patients' fluid status is necessary for accurate interpretation of laboratory findings (99). Interestingly, the authors draw a correlation between electrolyte imbalance and progression of COVID-19 disease and MOF. SARS-CoV-2 binds to its host receptor, ACE2, and reduces ACE2 expression, leading to increased angiotensin II, which can cause increased potassium excretion by the kidneys resulting in hypokalemia, while plasma angiotensin II is purported to be a mediator of ARDS and ensuing MOF seen in a significant number of COVID-19 patients (100). Another cause of electrolyte loss in COVID-19 patients is attributed to GI causes such as diarrhea and emesis (101). The U.S. Centers for Disease Control (CDC) has described a similar electrolyte imbalance, accompanied by diarrhea and emesis, due to damage and disruption of the intestine after radiation exposure (102, 103).

#### *Immune Biomarkers*

Lymphocyte counts provide a rapid snapshot of the prognosis for patients with COVID-19. Delving into the lymphocyte subsets provides a clearer understanding of the patient's immune status, with both diagnostic and prognostic value (104). In a 103-patient study, a significant decrease in T-cell populations were reported. In particular, the CD3<sup>+</sup>, CD4<sup>+</sup>, CD8<sup>+</sup> and NK cell counts dropped, with the CD4<sup>+</sup>/CD8<sup>+</sup> ratio increased in COVID-19 patients compared to healthy controls (105). In other published studies, a correlation was noted between the severity of disease and reduction in T-cell subunits (61, 66) as well as decreases in B-cell numbers (106).

Persistent changes in the immune system after radiation exposure are manifested as abnormalities in the lymphoid populations and function (107). Radiation studies have documented immediate changes in T-cell subsets (108) and B cells (109) linked to radiation dose. In particular, depletion of CD8<sup>+</sup> cells has been correlated with absorbed radiation at low doses (110). In atomic bomb (A-bomb) survivors, a decrease in CD4 helper T-cell populations, attenuated T-cell function, as well as an increase in B-cell populations, which could drive long-term inflammation. Radiation dose-dependent reduction in CD4<sup>+</sup> cell population has also been reported (111, 112). While these metrics are not used to monitor disease progression, they are indications of the continued immune dysfunction observed in patients after radiation exposure (113).

#### *Vascular Dysfunction*

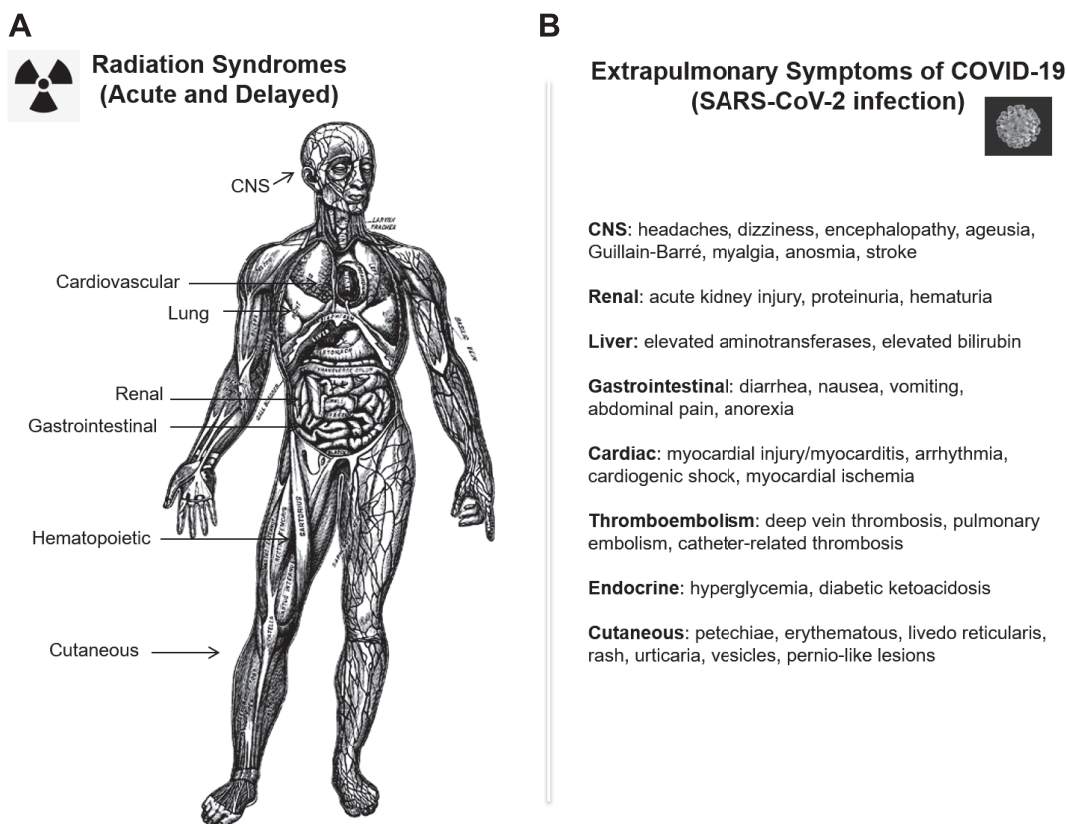
Histological analysis of COVID-19 has shown that the presence of SARS-CoV-2 within endothelial cells was associated with clusters of inflammatory cells, suggesting

that infection initiates endotheliitis throughout the entire human body, leading to systemic macro and microcirculatory dysfunction in vascular beds (44). VEGF-D was noted as an indirect procoagulant biomarker of COVID-19 progression (114) and angiopoietin-2 (a marker for endothelial activation), was associated with microvascular dysfunction (115). Vascular abnormalities such as vascular thickening, detected by thoracic computed tomography (CT), was reported to be significantly associated with COVID-19, when compared to non-COVID-19 pneumonia (59% versus 22%,  $P < 0.001$ ) (116). Ultimately, endotheliopathy converges with COVID-19-associated coagulopathies; a recently published study showed significant elevation in markers of endothelial cell and platelet activation with mortality strongly correlated to von Willebrand factor (VWF) antigen and plasma thrombomodulin (117).

Vascular dysfunction resulting from radiation exposure has also been reported. Of the 28 people who died within 98 days of the Chernobyl criticality incident, deaths were attributed to skin, GI and lung reactions, but most deaths were characterized by circulatory problems, with a high incidence of edema and focal hemorrhages (118). After the Tokaimura Nuclear Plant accident in Tokai, Japan, Akashi discussed the possible role of inflammation and hemorrhage in radiation-induced MOF. In a review of 110 cases histories of radiation accidents spanning 1945 through 2000, the authors analyzed MOF after total-body irradiation (TBI) and stated that "...symptomatology of organ system involvement could be traced not only to the pathophysiology of the rapidly turning over cell renewal systems but – of equal or more importance – to the vascular system and specifically, to the endothelial components." (119). The primary target of radiation injury to the vasculature is the endothelial cell. The acute phase of damage occurs within hours to weeks postirradiation, and is characterized by endothelial swelling, vascular permeability and edema, lymphocyte adhesion and infiltration, and apoptosis (52). Radiation-induced vascular biomarkers include inflammatory signals, endothelial activation and adhesion markers, and prothrombic markers (48, 120, 121), similar to those reported for COVID-19.

As of September 10, 2020, the FDA has authorized EUAs for more than 150 individual molecular diagnostic tests for SARS-CoV-2. As a sampling, from February 4, 2020 to June 18, 2020, a total of 85 tests received EUA authorization, which included 37 tests for detection of nucleic acids from SARS-CoV-2 and one antigen diagnostic test, with required conditions for manufacturers and authorized laboratories.<sup>6</sup> Similarly, as of mid-June 2020, the FDA had authorized more than 20 serology biomarker tests, with the caveat to "always refer to the complete instructions for use to put these estimates into the proper

<sup>6</sup> U.S. Food and Drug Administration. In vitro diagnostics EUAs. (<https://bit.ly/3mEFODt>)



**FIG. 1.** Panel A: Schematic showing the human organ systems affected by radiation exposure and comprise both acute and delayed radiation syndromes (Published and modified with permission; licensed from ClipArt ETC: <https://bit.ly/3mHcyvG>). Panel B: A representative list of extrapulmonary symptoms observed in COVID-19 (SARS-CoV-2 infection) (353). Coronavirus image published and modified, with permission, from the University of Virginia School of Medicine (<https://at.virginia.edu/32MutJv>).

context and to understand how to use and interpret these tests.” On June 2, 2020, the FDA authorized the only *in vitro* diagnostic test for the management of patients with COVID-19, which is based on measuring the circulating IL-6 levels in these patients. In stark contrast, no radiation biodosimetry test has been cleared/authorized by the FDA.

### **PATHOLOGY**

As more information becomes available, it is increasingly apparent that COVID-19 is not just a pulmonary affliction, but a multi-organ disease. Curiously, many symptoms as well as underlying pathogenesis in this multi-organ injury caused by SARS-CoV-2 are similar to the multi-organ injury caused by acute ionizing radiation exposure. In a nuclear incident, a person’s entire body may be exposed to large doses of damaging ionizing radiation, while SARS-CoV-2 can only infect cells co-expressing angiotensin-converting enzyme 2 and transmembrane serine protease 2 (TMPRSS2). The presence of these proteins on a wide variety of cell types throughout the body such as airway epithelial cells, alveolar epithelial cells, lung macrophages and vascular endothelial cells (122, 123), absorptive enterocytes of the ileum and colon (124), explains the

widespread damage caused by the infection (124). Indeed, SARS-CoV-2 RNA has been detected in sputum, nasal swabs, saliva, feces, blood, tears, urine and cerebrospinal fluid (125–128). Despite the differences in the initial cause of injury, systemic inflammation and coagulopathy, including disseminated intravascular coagulation (DIC) are hallmarks of both COVID-19 (123, 129–131) and acute radiation injury, with pyroptosis (51, 53, 131, 132) and neutrophil extracellular traps (133, 134) found in both. As noted in COVID-19 patients, hematopoietic ARS patients develop lymphopenia, thrombocytopenia and neutropenia due to bone marrow damage (135), possibly further contributing to multi-organ damage and failure. These disease processes found in both COVID-19 and acute and delayed radiation syndromes may directly cause or further exacerbate injury and pathogenesis in multiple organ systems (Fig. 1). In fact, multi-system inflammatory syndrome in children with COVID-19 has recently been described and affects a wide range of organs and systems (136).

Pulmonary disease and symptoms are the most common presentation of COVID-19 and respiratory failure is the most common cause of death in those with COVID-19 disease (98, 137), whereas lung damage in irradiated



patients is a later effect (compared to hematological and GI manifestations). Nonetheless, these injuries can also be severe and lead to death (138, 139). Pneumonitis and subsequent drop in blood oxygen levels are seen in COVID-19 patients (98, 123, 140), as well as after irradiation, which often progresses to pulmonary fibrosis (36, 139). As with lung damage seen in COVID-19 patients, fibrosis was also seen in long-term follow-up of Middle East respiratory syndrome (MERS) patients (141). An increase in local neutrophils, cytokines and other immune factors is seen in COVID-19 patients with lung damage (32, 33), and also in patients and animal models of acute radiation exposure (34–36). These factors may also contribute to pneumonitis and provide further support to the hypothesis that lung injury seen in COVID-19 patients may progress to lung fibrosis.

While pulmonary symptoms are the most common in COVID-19 patients, GI symptoms are also common. Nausea, vomiting and diarrhea are all common symptoms in both COVID-19 and irradiated patients. In one published study of 651 patients in China, it was found that 11.4% of patients experienced at least one GI symptom (142) while in another study, 5% and 3.8% of hospitalized COVID-19 patients experienced nausea/vomiting and diarrhea, respectively (143). Additionally, SARS-CoV-2 RNA is often found in stool samples of patients with and without GI symptoms (144), which is not surprising given that ACE2 is expressed throughout the intestines and co-expressed with TMPRSS2 in enterocytes in the ileum and colon (124). In addition, SARS-CoV-2 was recently found to infect enterocytes *in vitro* (145). The intestinal damage and symptoms seen in COVID-19 do not appear to be as extreme as those observed in GI-ARS, where crypt stem cells die, leading to loss of GI function and integrity, causing not only nausea, vomiting and diarrhea, but also hemorrhage, endotoxemia, bacterial infection and even death (34, 146). However, the involvement of the gut microbiota should not be overlooked in either disease process. While the effect of SARS-CoV-2 infection on the gut microbiome is not yet known, a healthy gut microbiome may have contributed to a successful, but not overly-inflammatory immune response and expedited recovery with other respiratory diseases (147). Interestingly, fecal microbiota transplants have been shown to increase survival in a lethal irradiation mouse model (148).

Another organ of concern is the heart. Though the coagulopathy seen in both COVID-19 and ARS may contribute to cardiomyopathy and circulatory failure, direct cardiac tissue remodeling is also seen in both disease processes. Cardiac ischemia, inflammation, fibrosis and wall thickening have been noted in COVID-19 patients (149, 150) and after irradiation, though dependent upon dose and time after irradiation (151, 152). SARS-CoV-2 infection and radiation both increase risk of myocardial infarction, with one study from China reporting that 7% of case fatalities had only myocardial damage and circulatory failure without respiratory failure (137). Studies of A-bomb survivors have shown that cardiovascular disease risk

increases 14% per Gy of exposure (153). The short- and long-term effects of cardiac damage from both disease processes is a concern.

Additionally, symptoms indicating damage to the central nervous system have been observed in patients with COVID-19 and those with ARS. Headache, disorientation, cognitive dysfunction, ataxia, seizures, unconsciousness, as well as other symptoms have been reported in patients who received lethal high-dose radiation (135) and in adult and juvenile COVID-19 patients (126, 154, 155). Radiation causes vascular damage and inflammation leading to hemorrhage and edema (156) and can increase risk of stroke (157). Similarly, brain damage in COVID-19 could be due to systemic inflammatory response and coagulopathy, leading to stroke and other issues (158), or may be directly due to infection of brain tissue, as SARS-CoV-2 RNA has been found in cerebrospinal fluid and in brain tissue after autopsy (159). Brain damage due to SARS-CoV-2 infection or irradiation can initiate or exacerbate injury to other organs, including respiratory or circulatory failure (159). Additionally, there is some evidence that radiation exposure may cause long-term psychological issues (160), and given the similarities between radiation-induced central nervous system inflammation and coagulopathy and that seen in COVID-19, long-term neurological and psychological effects may be forthcoming.

Several published studies have outlined the cutaneous manifestations of COVID-19. These symptoms appear at different time points of the disease progression, either at onset of disease or after hospitalization (161), and depend on the severity (mild or severe) of the infection (162–164). The most common symptoms identified in patients with mild infections are chilblain-like eruptions (i.e., COVID fingers or toes), and petechiae/purpuric rashes, while patients with severe infections experience symptoms such as acro-ischemia with finger and toe cyanosis, cutaneous bullae, dry gangrene, chickenpox-like rash and maculopapular lesions (162). Like COVID-19, cutaneous manifestations from ARS depend on the timepoint and severity of exposure often assessed using a graded scale set forth by the National Cancer Institute (165). The most common symptoms are also the least severe, i.e., acute radiation dermatitis and mild erythema, and are seen in patients exposed to low-dose radiation. These complications usually present within 90 days of radiation exposure (165). Radiation-induced telangiectasias, keratoses, ulcers, hemangiomas, splinter hemorrhages in the distal nail bed, lentiginous hyperpigmentation and severe subcutaneous fibrosis may also occur. High-dose radiation exposure leads to severe symptoms such as moist desquamation and ulceration (165). Of note, these or similar injuries may occur in the oral epithelium in both COVID-19 (166, 167), and after radiation exposure (168). In comparing cutaneous manifestations related to COVID-19 and ARS, the symptoms associated with ARS are more severe and long lasting. Delayed effects can be seen months to years postirradiation,



while lesions due to COVID-19 infection appear to heal more quickly, usually within a few days (161, 169). On the other hand, vascular complications associated with COVID-19 infection closely resemble mild radiation burns seen in patients that have been exposed to mild (non-lethal) doses of radiation. In both COVID-19 and mild radiation cutaneous injury, vascular injury may be further contributing to the skin injury, and damage to the vasculature in the upper layers of the skin may be involved (162, 163, 169).

Other symptomatic overlaps between COVID-19 and radiation exposure include: acute kidney injury (72, 170–172), whether coagulopathy-related or direct, as renal tubule cells are a potential target for SARS-CoV-2 (173); liver injury, though more severe and possibly fibrotic in radiation hepatitis (174) compared to the usually mild elevation of aspartate aminotransferase and alanine aminotransferase levels seen in 14–53% of COVID-19 patients (175); and conjunctivitis (127, 176, 177), an immediate effect of radiation with possible long-term effects including macular degeneration and cataracts (178, 179). Fertility issues have been seen in irradiated individuals, and there is concern regarding male fertility in COVID-19 patients as well, as ACE2 receptors are also expressed in the testis, and some male patients have reported scrotal discomfort. Nonetheless, SARS-CoV-2 has yet to be found in semen, and this disease may still be too new to identify fertility issues (180). High rates of androgenetic alopecia in hospitalized COVID-19 patients have been documented, leading to the hypothesis that the use of anti-androgen therapy (flutamide) may be a possible treatment for COVID-19 patients (181).

Radiation-induced coagulopathies (RIC) are part of the continuum of the irradiation sequelae (134, 182, 183), with parallels to DIC. Hemorrhage, a hallmark of DIC, was reported in 60% of the mortalities in the A-bomb-exposed population, accompanied by petechial lesions and thrombocytopenia (184), and was also observed after (184), as well as other radiation accidents (185, 186). Prevalence of prolonged clot formation times, increased levels of thrombin-antithrombin III (TAT) complex and increased circulating nucleosome/histone (cNH) levels were noted in blood from irradiated clinical samples (134). D-dimer has not been reported in any of the radiation-related coagulopathy studies, but other metrics used to predict coagulopathy for COVID-19 are similar to RIC. Though in many systems radiation damage is much more severe and chronic, overall, the similarities noted thus far between COVID-19 and ARS/DEARE may provide insight into the late effects of COVID-19, as well as shed light on possible targets for diagnostics, prognostic markers and therapeutics.

## MEDICAL COUNTERMEASURES

As noted, there are clear parallels between radiation exposure, which is known to act systemically to cause damage, and COVID-19, which has been implicated in organ damage ranging from the lung and GI tract to the

heart, brain, kidney and vasculature. In fact, the characteristics of radiation-induced pneumonitis are similar to SARS-CoV-2 interstitial pneumonia (187). Therefore, it is not surprising that there are a number of treatments for radiation exposure under development that could prove to be efficacious for COVID-19. Because it is not possible to “fight” radiation in a conventional sense, in the way that it is possible to develop approaches directly targeting a pathogen, researchers have relied instead on modifying the host response to injury, to identify therapies to address damage caused by exposure to radiation. In many cases, these approaches have worked by harnessing the body’s innate immunity, which is often dysregulated by radiation exposure. These treatments fall into several general categories, which include anti-oxidants, anti-inflammatories, antibiotics, anti-fibrotics, growth factors, cellular therapies, and products that target the vasculature or the RAS. Especially important to emphasize is the ability to repurpose these kinds of established drugs, some of which are already in clinical use, to expedite their use in patients with SARS-Cov-2 infection. These varied approaches will be considered separately below, according to their mechanisms of action.

### Growth Factors

COVID-19 is characterized by damage to the lung and vasculature, reducing blood oxygenation. In a review of the effects of erythropoietin (EPO), Ehrenreich *et al.* (188) noted that EPO acts on tissues beyond erythropoiesis; these effects could be brought to bear in fighting SARS-CoV-2 pathology. EPO is produced in the body in response to low oxygen levels, and in the short term, binds to receptors in the brain stem to improve mechanical ventilation. EPO also acts on airways and lung vasculature to reduce inflammation and promote vascularization and has been shown clinically to be neuroprotective. Although at this writing, no trials have been started, a randomized placebo-controlled trial for proof-of-concept has been proposed. EPO has also been shown to accelerate the expansion of erythroid progenitors in mouse irradiation models (189, 190). Galal *et al.* (191) described the effects of EPO beyond erythropoiesis, through the reduction of oxidative stress via upregulation of anti-inflammatory receptors. These activities point to possible treatments to reduce inflammation contributing to radiation-induced GI, lung, or kidney injury.

Leukine® (sargramostim or granulocyte-macrophage colony-stimulating factor, GM-CSF; Partner Therapeutics Inc., Lexington, MA) is one of three leukocyte growth factors approved by the U.S. FDA for treatment of ARS (192). Lang *et al.* (193) noted that, just as immune system stimulation can either help the body fight a viral infection or produce a deleterious inflammatory response, administration or inhibition of GM-CSF may be useful therapies for COVID-19. Lung macrophages depend on alveolar GM-

CSF production for their maintenance, and GM-CSF administration could provide protection against viral infection in the early stages of ARDS and promote tissue repair. At this writing, sargramostim is being proposed as a therapeutic against COVID-19 in three trials<sup>7</sup> (NCT04400929, NCT04326920, NCT04411680). As for deleterious effects, GM-CSF can exacerbate the inflammatory response, driving lung pathologies such as those resulting from COVID-19. In this case, GM-CSF inhibition could reduce expression of the pro-inflammatory cytokines IL-1, IL-6 and TNF, providing a multi-pronged approach to dampen an overstimulated immune system. Monoclonal antibody treatments targeting GM-CSF or GM-CSF receptor that are ongoing include: otilimab (NCT04376684), gimsilumab (NCT04351243), lenzilumab (NCT04351152), TJM2 (NCT04341116) and mavrilumab (NCT04397497, NCT04399980, NCT04447469). Namilumab is being used in the clinic in an expanded access program. Patients receiving treatment in these experimental protocols will need to be monitored carefully because of the role that GM-CSF plays in immunological homeostasis. In addition, it would appear that the timing of these kinds of growth factor interventions is critical to their potential efficacy.

#### *Antioxidant Approaches*

Radiation-induced damage is characterized by increases in reactive oxygen species (ROS) and oxidative stress (194–196). These increases, and the resulting inflammatory response, can damage other sensitive tissues (197–200). The antioxidant N-acetyl cysteine (NAC) has been shown to mitigate radiation-induced damage to the GI tract and improve 10- and 30-day survival in mice receiving total-abdominal irradiation (201). NAC also decreased out-of-field bone marrow damage and ROS levels, suggesting that bone marrow damage contributes to some of the radiation-induced GI injury. Because of similar patterns of tissue damage, Corry *et al.* hypothesized that COVID-19-induced damage to the lung could also be ameliorated by NAC treatment (202). This hypothesis was further supported by an earlier finding that NAC treatment of patients with acute lung injury and ARDS resulted in reduced mortality (203). Currently, there are several ongoing national clinical trials to address the possible benefit of NAC treatment in COVID-19 patients (NCT04374461, NCT04419025, NCT04370288 and NCT04279197).

Another compound under investigation for COVID-19 is the histamine H<sub>2</sub>-receptor antagonist famotidine. Typically used to treat acid reflux and heartburn, the drug is also known to have antioxidant activity (204). Although an unlikely candidate to treat viral disease, famotidine first came to the attention of researchers interested in repurposing already-licensed products (205). Generic and off-patent

drugs were of particular interest because of their safety and affordability, supported by extensive data in humans (206). In addition, *in silico* analysis suggested that the drug could be useful as a therapeutic alternative in COVID-19 (207). Clinicians have noted that hospitalized patients taking the drug for other medical indications appeared to recuperate from COVID-19 better than those who did not take the drug (208). A review of over 6,000 patient records suggested that famotidine use led to a death rate of ~14%, compared to 27% for those who had not taken famotidine. This finding was further supported by a retrospective analysis of COVID-19 patients who received the drug within 24 h of hospital admission, which showed that its use reduced the risk of intubation or death (209). One suggested mechanism of action of famotidine is a direct action on the receptor, leading to improved mast cell regulation (210). Additional, prospective clinical trials to look at the efficacy of the drug in COVID-19 patients are underway (NCT04370262, NCT04389567). A recently published article has suggested that famotidine is ineffective; however, the authors state that “We’re not challenging that famotidine might help. We’re saying that the mechanism of action is not antiviral”.<sup>8</sup> This is consistent with the primary proposed antioxidant mechanism of action.

Radiation researchers have also sought to understand the protective effects of famotidine administration, with regards to limitation of DNA damage and cellular protection. With studies performed *in vivo*, in both pre-clinical irradiation models as well as in patients undergoing radiotherapy, the potential benefits of the drug have been demonstrated. Famotidine was found to be radioprotective in mice that were administered the drug prior to irradiation, as assessed by micronuclei formation in cells of the bone marrow (211, 212). Pre-clinical work with mouse leukocytes collected from irradiated animals documented consistent outcomes, with reductions in DNA damage in animals treated with famotidine prior to irradiation (213). Famotidine also significantly reduced lymphocytopenia in prostate cancer patients who received the drug a few hours prior to undergoing radiotherapy (214). In another study, prostate cancer patients given twice-daily oral doses of famotidine during their radiotherapy led to a reduction in radiation-induced injury to the normal rectal tissue (215). These clinical findings in cancer patients were based on earlier work using peripheral blood samples taken from normal healthy volunteers (216). In those studies, blood was irradiated *ex vivo* in the presence or absence of vitamin C and famotidine. Comet assay results suggested that the presence of famotidine was protective for radiation-induced apoptosis, with an estimated dose reduction factor of 1.5. The protective effects of the drug noted above suggest the drug may have an antioxidant effect and ability to scavenge

<sup>7</sup> NIH/U.S. National Library of Medicine. ClinicalTrials.gov. (<https://clinicaltrials.gov/>)

<sup>8</sup> Saey TH. A popular heartburn medicine doesn’t work as a COVID-19 antiviral. ScienceNews 2020. (<https://bit.ly/2ZSFtDi>)

free radicals, a mechanism that would justify clinical use of the drug for COVID-19.

#### *Anti-inflammatory Approaches*

Severe COVID-19 is characterized by a cytokine storm, indicative of an overactive immune response to the infection (217). Because elevated levels of pro-inflammatory cytokines are associated with high morbidity and mortality, various approaches to modulate the inflammatory response have been proposed. Specifically, COVID-19 results in elevated levels of serum IL-6 (217). The IL-6 receptor antagonist, tocilizumab (Actemra®, Genentech, San Francisco, CA), indicated for rheumatoid arthritis, has also been proposed to ameliorate radiation-induced tissue damage, and has shown efficacy in diminishing the cytokine storm resulting from cancer immunotherapy (218). In early published clinical studies to assess the potential impact of tocilizumab treatment in COVID-19, Somers *et al.* (219) performed a single-site trial of the drug in 154 COVID-19 patients on mechanical ventilation. Treatments resulted in a lower hazard of death, although the rate of superinfections increased. Antinori *et al.* (220) noted the risk of a secondary *Candida* infection from tocilizumab treatment, and therefore suggested that the drug only be used in well-designed clinical trials. Currently, a tocilizumab treatment arm has been included as part of the University of Oxford's Randomised Evaluation of COVID-19 Therapy (RECOVERY) trial,<sup>9</sup> the results of which have not been made available at the time of this writing. In a study looking at the effect of the drug in critically ill patients, treatment led to improved oxygenation and blood counts (221). In addition, another anti-IL-6 receptor antibody, sarilumab (Kevzara®, Regeneron Pharmaceuticals Inc., Tarrytown, NY and Sanofi, Paris, France) is also under clinical consideration in more than 10 registered trials as a treatment for late-stage COVID-19 patients.

Dexamethasone is a generic corticosteroid drug, which is licensed for a broad range of indications including arthritis, allergic reactions and immune system disorders. Dexamethasone has been shown to reduce multi-organ damage, including lung injury, in rats that have been exposed to localized radiation (222). In non-human primate (NHP) models of radiation-induced lung injury, dexamethasone has been used as a component of the medical management, where it is given when there is an increase in the non-sedated respiratory rate, which suggests respiratory distress (138, 223, 224). This use of the drug is similar to its clinical use for dyspnea (225). In these NHP studies, dexamethasone treatment reduced the elevated respiratory rate, lung density, pleural effusion and pneumonitis, leading to improved outcomes. Dexamethasone treatment has also been included as an arm in the RECOVERY trial (226),

where its use has been shown to reduce COVID-19 mortality from 40.7% to 29% among patients who required invasive mechanical ventilation, but did not appear to confer a benefit to hospitalized patients who received only oxygen. These data suggest that corticosteroid treatment may only be effective if the immune system is overstimulated to the extent that it is causing significant harm. The WHO Rapid Evidence Appraisal for COVID-19 Therapies Working Group performed a meta-analysis of seven randomized trials and concluded that systemic corticosteroids reduced 28-day all-cause mortality (227). Another treatment that has been shown to improve survival in a mouse model of radiation-induced lung injury is BIO 300 (Humanetics Corp., Edina, MN), which is a nanosuspension of the soy isoflavonoid, genistein. In mice, BIO 300 administration improved survival and reduced other morbidities caused by lung irradiation (228). Although genistein has antiviral activity (229–231), it may also be useful to prevent radiation-induced lung damage. Genistein is thought to act through inactivation of NF- $\kappa$ B (232), and since NF- $\kappa$ B inhibition has been shown to reduce inflammation in a mouse model of COVID-19, it could be effective in treating lung complications caused by SARS-CoV-2 infection. Humanetics has announced initiation of a clinical trial in discharged COVID-19 patients, to determine if treatment with the oral BIO 300 product can reduce late lung fibrosis and improve quality of life in patients who are recovering from the infection (NCT04482595).

Given that the autoimmune disease, rheumatoid arthritis (RA) is caused by an overactive immune response that targets normal joint tissue, it is not surprising that approaches that have shown benefit in RA are being considered for COVID-19. For example, anakinra (Kineret®, Swedish Orphan Biovitrum AB, Stockholm, Sweden), a specific IL-1 receptor antagonist, has been proposed as a possible treatment. Similarly, anakinra has been reported to reduce vascular inflammation in a mouse model of radiation exposure (233). In that study, administration of the drug for two weeks postirradiation reduced the expression of inflammatory mediators such as pro-caspase and caspase-1. In an early case report from Italy, clinicians described a critically ill patient who was successfully treated with anakinra (234). Other studies have since followed; in fact, King *et al.* have described ten ongoing clinical trials that target hyper-inflammation. It is clear that many different dosing regimens are being tested and that most of these smaller studies (<400 patients) should be considered preliminary, but data arising from these studies could lead to larger-scale studies with more uniform treatments. The outcomes of some of these anakinra studies have been published. In the anakinra-COVID study performed in France, 25% of patients who were treated with anakinra required invasive mechanical ventilation or died, compared to 44% of historical controls from the same hospital (235). In another small retrospective cohort study from Italy, part of the COVID-19 Biobank study, anakinra-treated patients

<sup>9</sup> RECOVERY/Randomised Evaluation of COVID-19 Therapy. Oxford, UK: University of Oxford; 2020. (<https://www.recoverytrial.net/>)



showed improvement in respiratory parameters (reduced need of supplemental oxygen, improved PaO<sub>2</sub>/FiO<sub>2</sub> ratio) and reductions in the inflammatory marker, C-reactive protein.

### *Anti-fibrotic Approaches*

Lung inflammation caused by radiation can progress to fibrosis in later stages of injury, causing shortness of breath and reduced blood oxygen saturation. Drugs currently approved to treat lung fibrosis include nintedanib (OFEV®; Boehringer Ingelheim, Ingelheim am Rhein, Germany) and pirfenidone (Esbriet®; Genentech). Nintedanib is a tyrosine kinase inhibitor approved for idiopathic pulmonary fibrosis. Using a mouse model of localized irradiation, researchers demonstrated that nintedanib protected against long-term fibrosis, as detected microscopically at 39 weeks postirradiation (236). Similarly, studies showed protection in a mouse model of thoracic irradiation by pirfenidone treatment (237). In terms of COVID-19 and its progression, it was noted that patients who experienced severe ARDS often exhibit later lung fibrosis (238). Although anti-inflammatory treatments could prevent late-stage disease, it is not known if this will be the case for COVID-19. For this reason, the authors propose that anti-fibrotics, such as those described above, should be studied in clinical trials. In one clinical study (NCT04338802), patients will be randomized into a placebo-control or nintedanib treatment group, and in another, the safety and efficacy of pirfenidone will be studied in patients with SARS-CoV-2 infection (NCT04282902). Similarly, imatinib (Gleevec®; Novartis, Basel, Switzerland), licensed for chronic myeloid leukemia,<sup>10</sup> and previously shown to increase the survival time of irradiated mice by delaying lung disease, has been suggested as a COVID-19 treatment (239). Several clinical trials are planned (NCT04357613) or recruiting (NCT04394416) patients to study the drug as a possible treatment for the disease.

Pentoxifylline is another drug that could potentially be repurposed as a treatment for COVID-19. Originally licensed to treat pain in individuals suffering from intermittent claudication (peripheral arterial disease),<sup>11</sup> pentoxifylline improves blood flow, thereby increasing tissue oxygenation. It has also been shown to inhibit synthesis of pro-inflammatory cytokines, specifically TNF- $\alpha$  (240). Pentoxifylline has been shown to reduce radiation-induced fibrovascular injury in animal models (241) and in the clinic (242). Because of these anti-fibrotic (and anti-inflammatory) activities, pentoxifylline has been proposed as a possible preventative of COVID-19 complications

<sup>10</sup> Gleevec (imatinib mesylate) tablets for oral use. Prescribing information. Stein, Switzerland: Novartis Pharma Stein AG; East Hanover, NJ: Novartis Pharmaceuticals Corp.; 2008. (<https://bit.ly/3kyuqan>)

<sup>11</sup> Trental® (pentoxifylline). Reference ID: 3873773. Parsippany, NJ: Validus Pharmaceuticals LLC; 2016. (<https://bit.ly/2ZYT6Rz>)

(243) and will be tested in a clinical trial (NCT04433988). Another driver of pulmonary fibrosis, TGF- $\beta$  (244), presents a potential target for the prevention of pulmonary fibrosis in COVID-19 patients (245). For example, an anti-sense mRNA product that targets TGF- $\beta$ 2 production, OT-101 (Mateon Therapeutics, San Francisco, CA), is in phase 3 trials for several cancers, and has been proposed as a COVID-19 treatment (246). Given the probable involvement of TGF- $\beta$  in the progression of COVID-19, a preclinical, anti-TGF $\beta$  receptor 1 product, IPW5371 (Innovation Pathways, Palo Alto, CA) may also be a promising candidate to treat COVID-19-induced lung fibrosis, as it has previously been shown to reduce fibrosis and improve survival in a mouse model of radiation exposure (247).

### *RAS-Targeted Approaches*

In the early stages of the pandemic, it became clear that one method by which the SARS-CoV-2 virus gained access to the internal cellular machinery was via the ACE2 receptor, the expression of which is most prevalent on lung alveolar epithelial cells (248). This finding was similar to SARS-CoV, which also used the ACE2 receptor to gain entry into cells (249). Therefore, initial treatments considered for patients were angiotensin-converting enzyme inhibitors (ACEIs) or angiotensin II type receptor blockers (ARBs). Because many drugs, such as angiotensin-converting enzyme inhibitors (ACEIs), are generic and widely available, they represent a valuable option in repurposed drugs. Clear benefits include low cost, wealth of clinical experience, established human data and minimal side effects. During the initial stages of the COVID-19 response, it was thought that individuals currently taking hypertensive drugs could be at an increased risk of infection, and therefore, their use should be discontinued in COVID-19 patients (250, 251). In one large retrospective study of over 12,000 patients, the relationship between prior use of ACEIs and patient outcomes after infection was considered, with the finding that there was no correlation between prior hypertension medication use and COVID-19 risk (252).

In addition, it became evident that certain segments of the population were more likely to have more severe forms of disease and a propensity to develop ARDS. These individuals included those with cardiovascular disease, diabetes and hypertension, all of which have associations with dysregulated aspects of RAS (253). Still other studies suggested that these drugs should be considered as a potential treatment due to their multi-prong effects (e.g., anti-inflammatory anti-oxidant and antifibrotic) (254). Therefore, there remains a need to evaluate both angiotensin agonists and antagonists for COVID-19 (255). In one study, COVID-19 patients with hypertension were enrolled, to explore if the use of ACEI or angiotensin receptor antagonist treatments would impact the severity and progression of the infection (256). As a biomarker of

efficacy, serum levels of IL-6 and circulating T-cell counts were also evaluated. Both treatments were found to increase T cells, decrease viral load and IL-6 levels, and reduce the severity of the course of the disease. Therefore, the recommendation was made to maintain ACEI and angiotensin receptor blocker treatments in patients with COVID-19.

Similarly, the radiation community has established the role that products targeting RAS can play on the progression of radiation-induced organ injuries, primarily the lung and kidneys. Many studies have demonstrated the ability of ACEI products to address radiation-induced lung injuries. Primarily conducted in rat models of injury, ACEIs were found to increase survival and decrease lung, kidney and vascular damage (257, 258). These findings were consistent across different methods of radiation exposures, such as TBI plus bone marrow transplant (BMT), whole-thorax lung irradiation (WTLI), or partial-body irradiation (PBI) with a percentage of the bone marrow spared using shielding (259). Mitigation of lung and kidney injuries was determined through assessment of circulating markers of renal damage (e.g., blood urea nitrogen and creatinine) and CT imaging of lungs in irradiated animals. In an irradiated rat model, captopril and fosinopril both increased survival after 11 Gy (TBI with BMT) and decreased lung injury (257). Similarly, lisinopril was found to mitigate kidney (260) and lung (259) damage after high-dose PBI in adult rats and improve survival in juvenile and geriatric rats (38). Enalapril mitigated injury and improved survival in a WTLI rat model, even when initiated 35 days postirradiation (261). Captopril, administered in a TBI model, improved survival, although that benefit was diminished when coupled with skin trauma (262). Finally, ramipril mitigated radiation-induced damage to the spinal cord (263). In other preclinical models of radiation injury, angiotensin (1–7) [A(1–7)], a component of the RAS mentioned above, has also been studied for its ability to improve survival in irradiated rodents (264, 265). These peptides, which have been shown to alter activity in many cell types, accelerated recovery of the bone marrow in mice receiving TBI, and also improved the platelet nadir in the animals (264). In later studies, angiotensin peptides, even when administered days post-lethal irradiation, improved mouse survival and reduced bleeding time (265).

#### *Approaches Targeting the Vasculature*

The ability of the virus to directly infect and dysregulate endothelial cells (41) is the driving force behind vascular coagulopathies and thromboses observed in COVID-19 patients. In addition to vascular effects resulting from direct viral infection, COVID-19 patients have been found to have higher levels of VEGF as compared to healthy controls (266). Elevated VEGF could further increase vessel permeability, leading to some of the symptoms noted in patients. Furthermore, studies have implicated VEGF as a target for

therapeutic intervention in ARDS (267). At the time of this writing, several clinical trials of COVID-19 patients are being planned or are recruiting to assess the potential efficacy of bevacizumab, an anti-VEGF, long-lived, humanized monoclonal antibody, as a treatment for COVID-19-associated ARDS (NCT04275414, NCT04344782, NCT04305106). Also known as Avastin<sup>®</sup>, the mechanism of action of the drug is to bind to extracellular VEGF and prevent its interaction with its receptor on endothelial cells (268).

Radiation exposure has long been known to lead to vascular impairment, which is believed to explain the multi-organ dysfunction that it causes (121). Many promising clinical approaches that target the vasculature could have an effect on radiation-induced damage. VEGF also represents a molecule that is involved in radiation exposure, and thus, is a target for reducing the negative effects. For example, VEGF levels have been shown to be increased in mice after irradiation (269, 270), and elevated levels of the growth factor have been implicated in the development of radiation-induced necrosis of normal tissue (271). Anti-VEGF antibodies (bevacizumab) have been shown to mitigate radiation necrosis in mouse brains (272), and in rats that underwent gamma-knife radiosurgery (273), and bevacizumab has been used in the clinic for radiation injury, where it was found to reduce necrosis in nasopharyngeal carcinoma patients who received radiotherapy (274).

As observations continue to be made in COVID-19 patients, it has become apparent that DIC may be responsible for many of the complications that have been seen (275–278). This condition, which is characterized by the development and circulation of small blood clots, can lead to the blockage of small vessels. As a follow-on effect, the abnormal consumption of platelets can, in turn, lead to thrombocytopenia and hemorrhage (279). In several animal models of lethal radiation exposure, including ferrets (280) and Yucatan minipigs (281), there has been evidence of DIC, both in the early days after irradiation and at the time of death. It is believed that DIC could be a contributor to radiation-induced human mortality (50), as hemorrhage at time of death has been seen clinically in irradiated patients. A major finding in autopsies of humans who have died from radiation exposure (282), widespread bleeding in the tissues often occurs as a result of DIC. Coagulation abnormalities have also clearly emerged as a key hallmark of COVID-19 infections (283). In addition to thromboses (284), thrombocytopenia has also been noted in some patients experiencing COVID-19 infection. In a study from China involving over 1,000 patients, 36.2% were thrombocytopenic, a finding that was greater in cases that were more advanced (98). This association of low platelet count with the infection is also supported by a meta-analysis in which data from nine studies were examined, involving nearly 1,800 patients (71). Those researchers found that platelet counts were much lower in patients with severe disease and concluded that these lowered counts could indicate an increased mortality risk. It is postulated that infection with

SARS-CoV-2 leads to this dysregulated platelet state via a number of different causative pathways, including a reduction in platelet production due to loss of progenitors and growth inhibition, increased clearance due to evolution of autoantibodies, and enhanced platelet consumption due to lung injury, which leads to platelet activation and formation of microthrombi (284).

Like COVID-19, radiation exposures, especially TBI, are known to lead to a reduction in platelet levels. This thrombocytopenia has been postulated to play a major role in deaths from exposure (282). To address this manifestation of radiation injury, drugs that promote platelet production and are FDA-approved for other indications [e.g., immune thrombocytopenic purpura (ITP)] have been tested to see if they could mitigate damage and improve survival. This has included preclinical and clinical studies of drugs such as Nplate® (Amgen, Thousand Oaks, CA) (6, 285), and Promacta® (Novartis) (286, 287). Although there is a case report documenting use of Promacta to treat a COVID-19 patient who presented with ITP symptoms while hospitalized (288) and responded well to the treatment, it does not appear that these therapies have been attempted on a broader scale thus far. This may be due to the delicate balance between thrombocytopenia and thrombosis in these patients; timing of interventions is crucial to their efficacy or detriment. According to case reports, heparin has been administered as a means of countering hypercoagulation (289), and the International Society of Thrombosis and Haemostasis is now recommending use of heparin for all COVID-19 patients (290). Clearly, clinical decisions concerning the use of treatments that either enhance platelet counts or seek to reduce clotting are complex, and the use of these kinds of treatments represents an area of great interest. TP508, a 23 amino acid peptide that is a truncated form of human prothrombin, has also been shown to mitigate radiation normal tissue injury and increase survival in a mouse TBI (LD100/15) model (291). Under study in a number of other preclinical models [e.g., ischemia (292) and musculoskeletal injuries (293)], and in clinical trials to address diabetic foot ulcers (294)], TP508 has been shown to enhance tissue repair by targeting endothelial cells (292). This product is in early preclinical testing as a treatment for COVID-19<sup>12</sup> because it targets the vasculature as its primary mechanism of action and has generalized ability to mitigate tissue damage.

#### *Statins as a Common Treatment for Vascular Injury*

Statins represent another area of drug treatment overlap between radiation and COVID-19 (295, 296). In addition to an anti-inflammatory effect, statins may modify the entry of

viruses into cells, inducing autophagy of infected cells or altering activation of the coagulation cascade (297). *In silico* studies suggest that statins possess direct antiviral activity through blocking infectivity (298) and have been shown to enhance ACE2 levels (299) and protect against ARDS (300).

In clinical trials of COVID-19 patients, observed benefits were suggested to outweigh their potential risk (301). A retrospective study of patients treated with statins for other indications while hospitalized with COVID-19 showed a lower risk of mortality (302). In animal models of radiation injury, statins have demonstrated damage mitigation to normal tissues. Simvastatin, a HMG-CoA reductase inhibitor with widespread clinical use, has been shown to mitigate lung injury in a high-dose thoracic irradiation mouse model (303), and protects the GI tract, bone marrow (304) and salivary glands (305). Similarly, atorvastatin limits radiation-induced heart damage in a rat model (306) and kidney injury in mice (308).

Perhaps most significant, in terms of overlap with a primary mechanism of action involved in COVID-19, atorvastatin has been shown to induce a protective response in irradiated human umbilical vein endothelial cells (HUVECs) (308). Treatment of HUVECs with atorvastatin decreased radiation-induced cell apoptosis, thought to be driven by upregulation of thrombomodulin and protein C activation. Finally, lovastatin, when administered after high-dose irradiation in a WTLI mouse model, increased survival, reduced levels of macrophages and lymphocytes in the lung and decreased collagen (309). Activated protein C (APC) has been tested for its ability to mitigate radiation injuries (310) and has now been proposed as a therapy for the vascular dysfunction and abnormal thrombosis (e.g., DIC) observed in COVID-19 patients (311). APC's ability to downregulate inflammation and generate thrombin indicates its potential to reduce inflammation and limit ischemic injury throughout the body.

#### *Antibiotic Treatments for Radiation or SARS-CoV-2 Infection, beyond Antibacterial Properties*

Given the need to rapidly assess potential treatments, many clinicians have turned to antibiotics, which have the advantage of safety data and clinical experience. Several classes of antibiotics, which have activity against secondary bacterial infections and have anti-inflammatory and antiviral properties, have been suggested as potential treatments for COVID-19. *In silico* modeling and other predictive studies indicate efficacy of aminoglycoside compounds such as streptomycin (312); tetracyclines, such as doxycycline (313, 314) and eravacycline (312); macrolide antibiotics, such as azithromycin (315); streptogramins, such as quinupristin (316); polyether ionophoric antibiotics, such as salinomycin (317); and glycopeptides, such as teicoplanin. Teicoplanin, a drug used to treat *Staphylococcus* infections, was found to be effective against MERS and is predicted to also be

<sup>12</sup> Chrysalis BioTherapeutics receives funding from the National Institutes of Health for COVID-19 therapeutic development. Galveston, TX: Chrysalis BioTherapeutics Inc.; 2020. (<https://bit.ly/2HkvCQm>)



effective against SARS-CoV-2 (318, 319). There was hope that azithromycin, in combination with hydroxychloroquine (320), might be effective in reducing the severity of SARS-CoV-2 infections (321). The drug, commonly used to treat respiratory and other infections, is thought to strengthen interferon-mediated antiviral responses (315). Unfortunately, clinical studies did not provide evidence of efficacy of the drug (322). In contrast, some studies suggest limited benefit from the use of antibiotics, either alone or in combination (323) in both children and adults with COVID-19 (324), and other research suggests that the use of some antibiotics could actually worsen the progression of the disease (325).

As with COVID-19, the efficacy of antibiotics, outside of their normal antibacterial impact, have been observed in the mitigation of radiation normal tissue injuries. *In vitro* screening of a broad range of antimicrobial agents was conducted to determine if any of these molecules could be used as mitigators of radiation injury. In one screen that used hematopoietic progenitor cells in a clonogenic survival assay, tetracycline was identified as a significant mitigator (326). In another *in vitro* screen of mouse lymphocytes, two antibiotic classes, tetracyclines and fluoroquinolones (10 different molecules), were identified as potential radiation mitigators, which the authors attributed to being separate from their antibacterial properties. From these potential mitigators, tetracycline showed efficacy in a TBI mouse model of survival and further data mining confirmed these earlier findings (327). The predicted impact of quinolones on mitigation of radiation injuries was not surprising, given earlier studies in mice that showed ciprofloxacin, sparfloxacin and clinafloxacin could enhance colony-forming units in the bone marrow and white blood cell counts in irradiated mice (328). Similarly, a published study from 1961 showed that the presence of chlortetracycline in rodent feed decreased X-ray killing in mice (329). In more recent studies, fluoroquinolones, such as ciprofloxacin and levofloxacin, as well as doxycycline, and neomycin, were all found to increase the mean survival time in mice exposed to lethal doses of radiation. Doxycycline and neomycin also improved day-30 survival in the animals (330). In other work, ciprofloxacin, an antibiotic notable for its efficacy in treating bacterial pneumonia and other infections, was also shown to enhance survival after radiation exposure *in vivo* and *in vitro*. In studies using peripheral blood mononuclear cells, ciprofloxacin protected against radiation exposure by inhibiting p53 phosphorylation and increasing Bcl-2 production (331), and has also been shown to increase survival in a mouse model of TBI (332).

### Cellular Therapies

The development and use of cellular therapies, in both the oncology clinic (333) and as a radiation treatment (334, 335), has long been an approach of interest. In particular, mesenchymal stem (or stromal) cells (MSCs) have been

shown to mitigate the effects of radiation-induced lung injury (336, 337). Stem cells, as well as extracellular vesicles are also being considered as a means of treating injuries caused by SARS-CoV-2 (338). Specifically, MSCs derived from various sources, are under study to address lung injuries in COVID-19 patients (339). These sources include the bone marrow (340), umbilical cord (341), adipose tissue (342), peripheral blood and placenta. Early reported work indicates that the use of MSCs in patients is safe, and their use is effective in improving lung functional outcomes (343). There are more than 30 clinical trials worldwide in which these cells are being used as COVID-19 treatments (clinicaltrials.gov). In fact, several cellular therapies that are under active investigation for their development as radiation normal tissue injury mitigators are also showing promise as therapies in COVID-19 patient trials. These trials include those for placental expanded (PLX) cells<sup>13</sup> and multipotent adult progenitor cells (Multi-Stem®; Athersys® Inc., Cleveland, OH).<sup>14</sup>

### CONCLUSIONS

The majority of SARS-CoV-2 infections are asymptomatic or symptomatically mild and do not require hospitalization. However, at the time of this writing, there are over 50 million confirmed infections worldwide, with more than 9 million confirmed cases in the U.S. alone, of which hundreds of thousands have required hospitalization and over 225,000 have died. While host factors such as comorbidities, age and possibly genetics are strongly associated with the severity of disease, it is clear that the pathology of severe COVID-19 is characterized by a dysregulated inflammatory response, the so-called “cytokine storm,” along with a thrombotic response involving elevated D-dimer levels and coagulopathies ranging from small vessel thrombi to DIC. The cytokine storm is manifested through high levels of pro-inflammatory cytokines such as IL-1 $\beta$ , IL-6, IL-18, and TNF $\alpha$ . The cumulative systemic effects of the hyperinflammatory response and dysregulated thrombotic activity can lead to multi-organ failure and death. In the current absence of any effective prophylactic interventions, therapeutics capable of beneficially altering these dysregulated processes and supporting recovery are urgently needed.

A striking feature of the immune dysregulation, progression of disease and mechanisms of organ damage in COVID-19 is its similarity to the biological responses to ionizing radiation exposure at doses sufficiently large to cause ARS (>2 Gy in humans). The similarity of inflammatory responses and organ damages that are caused by COVID-

<sup>13</sup> Pluristem provides 28-day follow up for ventilator-dependent COVID-19 patients under compassionate use program in Israel and U.S. Los Angeles, CA: GlobeNewswire, Inc.; 2020. (<https://bit.ly/3cjdzVX>)

<sup>14</sup> COVID-19 and other viral induced ARDS. Cleveland, OH: Athersys®, Inc.; 2020. (<https://bit.ly/33IsQMe>)

19 and radiation offers an opportunity for possible COVID-19 interventions. There is a wealth of data (detailed above) and extensive experience from the field of radiation biology for the development of radiation mitigators that target radiation-induced dysregulation of inflammation, lung fibrosis and vascular damage that may lead to multi-organ failure and death in a fashion similar to that seen in COVID-19. Many of these agents are currently at preclinical levels of development, but several are already licensed as radiation mitigators and FDA approved for use in humans (Neupogen®, Neulasta®, Leukine®), or have demonstrated safety in human clinical trials for other indications, and are therefore well-poised for possible translation to COVID-19 indications. Finally, in perhaps the truest definition of overlap between radiation and COVID-19, is the novel (and yet “old-school”) proposal, that low-dose radiation therapy (LDRT), involving exposure of the thorax of the patient, may have efficacy in countering lung infections, including those caused by SARS-CoV-2 infection. This concept is based on studies on the use of radiation exposures in the early 1900s, before the advent of modern antibiotics, in which radiation was used to treat pneumonias resulting from bacterial or viral infections (344). This treatment proposal, however, is not without controversy. Already, numerous editorials and comments have been published (345–352) and discussion surrounding this treatment modality will undoubtedly continue. Nonetheless, LDRT is not considered to be a potential mitigator of high-dose radiation damage to the lung, and therefore this treatment generally falls outside the scope of the current review.

While medical expertise in the fields of infectious disease, pulmonology, immunology, rheumatology and hematology are critical paths forward in the search for COVID-19 therapeutic interventions, the substantial overlap in pathobiology between COVID-19 and ARS presents the possibility of readily translatable, potentially high-impact pharmacological interventions that were originally evaluated and/or developed to mitigate radiation injury in humans. By the same token, it is possible that, given the broad range of new treatment approaches that are being considered for possible efficacy in COVID-19 infections, some of these could one day be repurposed for use as radiation medical countermeasures.

## ACKNOWLEDGMENTS

### *In Memoriam*

A friend and colleague of the NIAID, Col. (ret.) and Dr. David Barillo sadly passed away due to complications from COVID 19 on August 11, 2020. David was an important mentor and voice in the community in the area of cutaneous radiation injuries (as the Medical Director of Argentum), due in part to his career devoted to the care of combat casualties, and as a lead burn surgeon. His great personality, passion for science and dedication to saving lives will be missed by all who were fortunate enough to know him.

Received: August 3, 2020; accepted: September 14, 2020; published online: October 16, 2020

## REFERENCES

1. Wadman M, Couzin-Frankel J, Kaiser J, Maticic C. A rampage through the body. *Science* 2020; 368:356–60.
2. Aziz N. Measurement of circulating cytokines and immune-activation markers by multiplex technology in the clinical setting: What are we really measuring? *For Immunopathol Dis Therap* 2015; 6:19–22.
3. Sun X, Wang T, Cai D, Hu Z, Chen J, Liao H, et al. Cytokine storm intervention in the early stages of COVID-19 pneumonia. *Cytokine Growth Factor Rev* 2020; 53:38–42.
4. Mahmudpour M, Roozbeh J, Keshavarz M, Farrokhi S, Nabipour I. COVID-19 cytokine storm: The anger of inflammation. *Cytokine* 2020; 133:155151.
5. Hu B, Huang S, Yin L. The cytokine storm and COVID-19. *J Med Virol* 2020; Epub ahead of print.
6. Wong K, Chang PY, Fielden M, Downey AM, Bunin D, Bakke J, et al. Pharmacodynamics of romiplostim alone and in combination with pegfilgrastim on acute radiation-induced thrombocytopenia and neutropenia in non-human primates. *Int J Radiat Biol* 2020; 96:155–66.
7. Ragab D, Salah Eldin H, Taeimah M, Khattab R, Salem R, The COVID-19 cytokine storm; what we know so far. *Front Immunol* 2020; 11:1446.
8. Wang J, Jiang M, Chen X, Montaner LJ. Cytokine storm and leukocyte changes in mild versus severe SARS-CoV-2 infection: Review of 3939 COVID-19 patients in China and emerging pathogenesis and therapy concepts. *J Leukoc Biol* 2020; 108:17–41.
9. England JT, Abdulla A, Biggs CM, Lee AYY, Hay KA, Hoiland RL, et al. Weathering the COVID-19 storm: Lessons from hematologic cytokine syndromes. *Blood Rev* 2020; Epub ahead of print.
10. Garg S, Garg M, Prabhakar N, Malhotra P, Agarwal R. Unraveling the mystery of Covid-19 Cytokine storm: From skin to organ systems. *Dermatol Ther* 2020; Epub ahead of print.
11. Sultan S, Sultan M. COVID-19 cytokine storm and novel truth. *Med Hypotheses* 2020; 144:109875.
12. Vaninov N. In the eye of the COVID-19 cytokine storm. *Nat Rev Immunol* 2020; 20:277.
13. Mehta P, McAuley DF, Brown M, Sanchez E, Tattersall RS, Manson JJ. COVID-19: consider cytokine storm syndromes and immunosuppression. *Lancet* 2020; 395:1033–34.
14. Ruscitti P, Berardicurti O, Iagnocco A, Giacomelli R. Cytokine storm syndrome in severe COVID-19. *Autoimmun Rev* 2020; 19:102562.
15. Jose RJ, Manuel A. COVID-19 cytokine storm: the interplay between inflammation and coagulation. *Lancet Respir Med* 2020; 8:e46–7.
16. Yang Y, Shen C, Li J, Yuan J, Wei J, Huang F, et al. Plasma IP-10 and MCP-3 levels are highly associated with disease severity and predict the progression of COVID-19. *J Allergy Clin Immunol* 2020; 146:119–127.e.4.
17. Zhou Y, Fu B, Zheng X, Wang D, Zhao C, Qi Y, et al. Aberrant pathogenic GM-CSF+ T cells and inflammatory CD14+CD16+ monocytes in severe pulmonary syndrome patients of a new coronavirus. *bioRxiv* 2020. (<https://bit.ly/2ZWVFU7>)
18. Muller K, Meineke V. Radiation-induced alterations in cytokine production by skin cells. *Exp Hematol* 2007; 35:96–104.
19. Ray K, Hudak K, Citrin D, Stick M. Chapter 39 - Biomarkers of radiation injury and response. In: Gupta RC, editor. *Biomarkers in toxicology*. Cambridge, MA: Academic Press; 2014. p. 673–87.
20. Huang Y, Zhang W, Yu F, Gao F. The cellular and molecular mechanism of radiation-induced lung injury. *Med Sci Monit* 2017; 23:3446–50.
21. Lierova A, Jelicova M, Nemcova M, Proksova M, Pejchal J,

- Zarybnicka L, et al. Cytokines and radiation-induced pulmonary injuries. *J Radiat Res* 2018; 59:709–53.
22. Busse LW, Chow JH, McCurdy MT, Khanna AK. COVID-19 and the RAAS—a potential role for angiotensin II? *Crit Care* 2020; 24:136.
  23. Santos RAS, Sampaio WO, Alzamora AC, Motta-Santos D, Alenina N, Bader M, et al. The ACE2/angiotensin-(1-7)/MAS axis of the renin-angiotensin system: focus on angiotensin-(1-7). *Physiol Rev* 2018; 98:505–53.
  24. Cheng H, Wang Y, Wang GQ. Organ-protective effect of angiotensin-converting enzyme 2 and its effect on the prognosis of COVID-19. *J Med Virol* 2020; 92:726–30.
  25. Imai Y, Kuba K, Rao S, Huan Y, Guo F, Guan B, et al. Angiotensin-converting enzyme 2 protects from severe acute lung failure. *Nature* 2005; 436:112–6.
  26. Gheblawi M, Wang K, Viveiros A, Nguyen Q, Zhong JC, Turner AJ, et al. Angiotensin-converting enzyme 2: SARS-CoV-2 receptor and regulator of the renin-angiotensin system: celebrating the 20th anniversary of the discovery of ACE2. *Circ Res* 2020; 126:1456–74.
  27. Zhang X, Li S, Niu S. ACE2 and COVID-19 and the resulting ARDS. *Postgrad Med J* 2020; 96:403–07.
  28. Wosten-van Asperen RM, Lutter R, Specht PA, Moll GN, van Woensel JB, van der Loos CM, et al. Acute respiratory distress syndrome leads to reduced ratio of ACE/ACE2 activities and is prevented by angiotensin-(1-7) or an angiotensin II receptor antagonist. *J Pathol* 2011; 225:618–27.
  29. Korystova AF, Kublik LN, Levitman MK, Samokhvalova TV, Shaposhnikova VV, Korystov YN. Ionizing radiation enhances activity of angiotensin-converting enzyme in rat aorta. *Bull Exp Biol Med* 2018; 165:216–9.
  30. Robbins ME, Diz DI. Pathogenic role of the renin-angiotensin system in modulating radiation-induced late effects. *Int J Radiat Oncol Biol Phys* 2006; 64:6–12.
  31. Coperchini F, Chiovato L, Croce L, Magri F, Rotondi M. The cytokine storm in COVID-19: An overview of the involvement of the chemokine/chemokine-receptor system. *Cytokine Growth Factor Rev* 2020; 53:25–32.
  32. Costela-Ruiz VJ, Illescas-Montes R, Puerta-Puerta JM, Ruiz C, Melguizo-Rodríguez L. SARS-CoV-2 infection: The role of cytokines in COVID-19 disease. *Cytokine Growth Factor Rev* 2020; 54:62–75.
  33. Narasaraju T, Tang BM, Herrmann M, Muller S, Chow VTK, Radic M. Neutrophilia and NETopathy as key pathologic drivers of progressive lung impairment in patients with COVID-19. *Front Pharmacol* 2020; 11:870.
  34. Williams JP, McBride WH. After the bomb drops: a new look at radiation-induced multiple organ dysfunction syndrome (MODS). *Int J Radiat Biol* 2011; 87:851–68.
  35. Hong JH, Chiang CS, Tsao CY, Lin PY, McBride WH, Wu CJ. Rapid induction of cytokine gene expression in the lung after single and fractionated doses of radiation. *Int J Radiat Biol* 1999; 75:1421–7.
  36. Johnston CJ, Williams JP, Elder A, Hernady E, Finkelstein JN. Inflammatory cell recruitment following thoracic irradiation. *Exp Lung Res* 2004; 30:369–82.
  37. MacVittie TJ, Bennett A, Booth C, Garofalo M, Tudor G, Ward A, et al. The prolonged gastrointestinal syndrome in rhesus macaques: the relationship between gastrointestinal, hematopoietic, and delayed multi-organ sequelae following acute, potentially lethal, partial-body irradiation. *Health Phys* 2012; 103:427–53.
  38. Medhora M, Gao F, Gasperetti T, Narayanan J, Khan AH, Jacobs ER, et al. Delayed effects of acute radiation exposure (Deare) in juvenile and old rats: Mitigation by lisinopril. *Health Phys* 2019; 116:529–45.
  39. Unthank JL, Miller SJ, Quickery AK, Ferguson EL, Wang M, Sampson CH, et al. Delayed effects of acute radiation exposure in a murine model of the H-ARS: Multiple-organ injury consequent to <10 Gy total body irradiation. *Health Phys* 2015; 109:511–21.
  40. Cantador E, Nunez A, Sobrino P, Espejo V, Fabia L, Vela L, et al. Incidence and consequences of systemic arterial thrombotic events in COVID-19 patients. *J Thromb Thrombolysis* 2020; 50(3):543–547.
  41. Varga Z, Flammer AJ, Steiger P, Haberecker M, Andermatt R, Zinkernagel AS, et al. Endothelial cell infection and endotheliitis in COVID-19. *Lancet* 2020; 395:1417–18.
  42. Colmenero I, Santonja C, Alonso-Riano M, Noguera-Morel L, Hernandez-Martin A, Andina D, et al. SARS-CoV-2 endothelial infection causes COVID-19 chilblains: histopathological, immunohistochemical and ultrastructural study of 7 paediatric cases. *Br J Dermatol* 2020. (<https://bit.ly/3iLnUMS>)
  43. Kanitakis J, Lesort C, Danset M, Jullien D. Chilblain-like acral lesions during the Covid-19 pandemic (“covid toes”): histologic, immunofluorescence and immunohistochemical study of 17 cases. *J Am Acad Dermatol* 2020; 83:870–5.
  44. Zamboni P. COVID-19 as a vascular disease: Lesson learned from imaging and blood biomarkers. *Diagnostics (Basel)* 2020; 10:440.
  45. Gustafson D, Raju S, Wu R, Ching C, Veitch S, Rathnakumar K, et al. Overcoming barriers: The endothelium as a linchpin of coronavirus disease 2019 pathogenesis? *Arterioscler Thromb Vasc Biol* 2020; 40:1818–29.
  46. Trejo-Gabriel-Galan JM. Stroke as a complication and prognostic factor of COVID-19. *Neurologia* 2020; 35:318–22.
  47. Bansal M. Cardiovascular disease and COVID-19. *Diabetes Metab Syndr* 2020; 14:247–50.
  48. Venkatesulu BP, Mahadevan LS, Aliru ML, Yang X, Bodd MH, Singh PK, et al. Radiation-induced endothelial vascular injury: a review of possible mechanisms. *JACC Basic Transl Sci* 2018; 3:563–72.
  49. Prabhakarparandian B, Goetz DJ, Swerlick RA, Chen X, Kiani MF. Expression and functional significance of adhesion molecules on cultured endothelial cells in response to ionizing radiation. *Microcirculation* 2001; 8:355–64.
  50. Kringsfeld GS, Kennedy AR. Is disseminated intravascular coagulation the major cause of mortality from radiation at relatively low whole body doses? *Radiat Res* 2013; 180:231–4.
  51. Stoecklein VM, Osuka A, Ishikawa S, Lederer MR, Wanke-Jellinek L, Lederer JA. Radiation exposure induces inflammatory pathway activation in immune cells. *J Immunol* 2015; 194:1178–89.
  52. Paris F, Fuks Z, Kang A, Capodiceci P, Juan G, Ehleiter D, et al. Endothelial apoptosis as the primary lesion initiating intestinal radiation damage in mice. *Science* 2001; 293:293–7.
  53. Gao J, Peng S, Shan X, Deng G, Shen L, Sun J, et al. Inhibition of AIM2 inflammasome-mediated pyroptosis by Andrographolide contributes to amelioration of radiation-induced lung inflammation and fibrosis. *Cell Death Dis* 2019; 10:957.
  54. Kermali M, Khalsa RK, Pillai K, Ismail Z, Harky A. The role of biomarkers in diagnosis of COVID-19 - A systematic review. *Life Sci* 2020; 254:117788.
  55. Ponti G, Maccaferri M, Ruini C, Tomasi A, Ozben T. Biomarkers associated with COVID-19 disease progression. *Crit Rev Clin Lab Sci* 2020; 57:389–99.
  56. Frater JL, Zini G, d’Onofrio G, Rogers HJ. COVID-19 and the clinical hematology laboratory. *Int J Lab Hematol* 2020; 42:S11–18.
  57. Henry BM, de Oliveira MHS, Benoit S, Plebani M, Lippi G. Hematologic, biochemical and immune biomarker abnormalities associated with severe illness and mortality in coronavirus disease 2019 (COVID-19): a meta-analysis. *Clin Chem Lab Med* 2020; 58:1021–8.
  58. Ferrari D, Motta A, Strollo M, Banfi G, Locatelli M. Routine



- blood tests as a potential diagnostic tool for COVID-19. *Clin Chem Lab Med* 2020; 58:1095–9.
59. Fei M, Tong F, Tao X, Wang J. Value of neutrophil-to-lymphocyte ratio in the classification diagnosis of coronavirus disease 2019. (Article in Chinese) *Zhonghua Wei Zhong Bing Ji Jiu Yi Xue* 2020; 32:554–58.
  60. Zheng Y, Zhang Y, Chi H, Chen S, Peng M, Luo L, et al. The hemocyte counts as a potential biomarker for predicting disease progression in COVID-19: a retrospective study. *Clin Chem Lab Med* 2020; 58:1106–15.
  61. Wu H, Zhu H, Yuan C, Yao C, Luo W, Shen X, et al. Clinical and immune features of hospitalized pediatric patients with coronavirus disease 2019 (COVID-19) in Wuhan, China. *JAMA Netw Open* 2020; 3:e2010895.
  62. Xia X, Wen M, Zhan S, He J, Chen W. An increased neutrophil/lymphocyte ratio is an early warning signal of severe COVID-19. (Article in Chinese). *Nan Fang Yi Ke Da Xue Xue Bao* 2020; 40:333–6.
  63. Yang AP, Liu JP, Tao WQ, Li HM. The diagnostic and predictive role of NLR, d-NLR and PLR in COVID-19 patients. *Int Immunopharmacol* 2020; 84:106504.
  64. Fu J, Kong J, Wang W, Wu M, Yao L, Wang Z, et al. The clinical implication of dynamic neutrophil to lymphocyte ratio and D-dimer in COVID-19: A retrospective study in Suzhou China. *Thromb Res* 2020; 192:3–8.
  65. Huang I, Pranata R. Lymphopenia in severe coronavirus disease-2019 (COVID-19): systematic review and meta-analysis. *J Intensive Care* 2020; 8:36.
  66. Liu J, Li S, Liu J, Liang B, Wang X, Wang H, et al. Longitudinal characteristics of lymphocyte responses and cytokine profiles in the peripheral blood of SARS-CoV-2 infected patients. *EBioMedicine* 2020; 55:102763.
  67. Hou H, Zhang B, Huang H, Luo Y, Wu S, Tang G, et al. Using IL-2R/lymphocytes for predicting the clinical progression of patients with COVID-19. *Clin Exp Immunol* 2020; 201:76–84.
  68. Terpos E, Ntanasis-Stathopoulos I, Elalamy I, Kastritis E, Sergentanis TN, Politou M, et al. Hematological findings and complications of COVID-19. *Am J Hematol* 2020; 95:834–47.
  69. Yang X, Yang Q, Wang Y, Wu Y, Xu J, Yu Y, et al. Thrombocytopenia and its association with mortality in patients with COVID-19. *J Thromb Haemost* 2020; 18:1469–72.
  70. Liu Y, Sun W, Guo Y, Chen L, Zhang L, Zhao S, et al. Association between platelet parameters and mortality in coronavirus disease 2019: Retrospective cohort study. *Platelets* 2020; 31:490–6.
  71. Lippi G, Plebani M, Henry BM. Thrombocytopenia is associated with severe coronavirus disease 2019 (COVID-19) infections: A meta-analysis. *Clin Chim Acta* 2020; 506:145–8.
  72. Huang C, Wang Y, Li X, Ren L, Zhao J, Hu Y, et al. Clinical features of patients infected with 2019 novel coronavirus in Wuhan, China. *Lancet* 2020; 395:497–506.
  73. Ahmed MZ, Khakwani M, Venkatasari I, Horgan C, Giles H, Jobanputra S, et al. Thrombocytopenia as an initial manifestation of COVID-19; case series and literature review. *Br J Haematol* 2020; 189:1057–8.
  74. Amgalan A, Othman M. Hemostatic laboratory derangements in COVID-19 with a focus on platelet count. *Platelets* 2020; 1–6.
  75. Pilaczynska-Cemel M, Gołda R, Dąbrowska A, Przybylski G. Analysis of the level of selected parameters of inflammation, circulating immune complexes, and related indicators (neutrophil/lymphocyte, platelet/lymphocyte, CRP/CIC) in patients with obstructive diseases. *Cent Eur J Immunol* 2019; 44:292–8.
  76. Ciaccio M, Agnello L. Biochemical biomarkers alterations in coronavirus disease 2019 (COVID-19). *Diagnosis (Berl)* 2020; Epub ahead of print.
  77. MacVittie TJ, Farese AM, Jackson W 3rd. The hematopoietic syndrome of the acute radiation syndrome in rhesus macaques: A systematic review of the lethal dose response relationship. *Health Phys* 2015; 109:342–66.
  78. Bilko NM, Dyagil IS, Russu IZ, Bilko DI. Circulating hematopoietic progenitor cells in patients affected by Chernobyl accident. *Exp Oncol* 2016; 38:242–4.
  79. Snell FM, Neel JV, Ishibashi K. Hematologic studies in Hiroshima and a control city two years after the atomic bombing. *Arch Intern Med* 1949; 84:569–604.
  80. LeRoy GV. The medical sequelae of the atomic bomb explosion. *JAMA* 1947; 134:1143–8.
  81. Fliedner TM. Nuclear terrorism: the role of hematology in coping with its health consequences. *Curr Opin Hematol* 2006; 13:436–44.
  82. Fliedner TM, Graessle D, Meineke V, Dorr H. Pathophysiological principles underlying the blood cell concentration responses used to assess the severity of effect after accidental whole-body radiation exposure: an essential basis for an evidence-based clinical triage. *Exp Hematol* 2007; 35:8–16.
  83. Friesecke I, Beyrer K, Wedel R, Reimers K, Fliedner TM. SEARCH: a system for evaluation and archiving of radiation accidents based on case histories. *Radiat Environ Biophys* 2000; 39:213–7.
  84. Graessle DH, Dorr H, Bennett A, Shapiro A, Farese AM, MacVittie TJ, et al. Comparing the hematopoietic syndrome time course in the NHP animal model to radiation accident cases from the database search. *Health Phys* 2015; 109:493–501.
  85. Goans RE, Holloway EC, Berger ME, Ricks RC. Early dose assessment in criticality accidents. *Health Phys* 2001; 81:446–9.
  86. Azizova TV, Osovets SV, Day RD, Druzhinina MB, Sumina MV, Pesternikova VS, et al. Predictability of acute radiation injury severity. *Health Phys* 2008; 94:255–63.
  87. Waselenko JK, MacVittie TJ, Blakely WF, Pesik N, Wiley AL, Dickerson WE, et al. Medical management of the acute radiation syndrome: recommendations of the Strategic National Stockpile Radiation Working Group. *Ann Intern Med* 2004; 140:1037–51.
  88. Graessle DH, Fliedner TM. Computer-assisted severity of effect assessment of hematopoietic cell renewal after radiation exposure based on mathematical models. *Health Phys* 2010; 98:282–9.
  89. Blakely W, Ossetrova N, Manglapus G, Salter C, Levine I, Jackson W, et al. Amylase and blood cell-count hematological radiation-injury biomarkers in a rhesus monkey radiation model—use of multiparameter and integrated biological dosimetry. *Radiat Meas* 2007; 42:1164–70.
  90. Sullivan JM, Prasanna PG, Grace MB, Wathen LK, Wallace RL, Koerner JF, et al. Assessment of biodosimetry methods for a mass-casualty radiological incident: medical response and management considerations. *Health Phys* 2013; 105:540–54.
  91. Sproull M, Kramp T, Tandle A, Shankavaram U, Camphausen K. Serum amyloid A as a biomarker for radiation exposure. *Radiat Res* 2015; 184:14–23.
  92. Ossetrova N, Sandgren D, Blakely W. C-reactive protein and serum amyloid A as early-phase and prognostic indicators of acute radiation exposure in nonhuman primate total-body irradiation model. *Radiation Meas* 2011; 46:1019–24.
  93. Prasanna PG, Blakely WF, Bertho J-M, Chute JP, Cohen EP, Goans RE, et al. Synopsis of partial-body radiation diagnostic biomarkers and medical management of radiation injury workshop. *Radiat Res* 2010; 173:245–53.
  94. Akashi M, Hiramata T, Tanosaki S, Kuroiwa N, Nakagawa K, Tsuji H, et al. Initial symptoms of acute radiation syndrome in the JCO criticality accident in Tokai-mura. *J Radiat Res* 2001; 42:S157–66.
  95. Mal'tsev V, Ivanov A, Mikhailov V, Mazurik V. The individual prognosis of the gravity and of the outcome of acute radiation disease based on immunological indexes. (Article in Russian). *Radiats Biol Radioecol* 2006; 46:152–8.
  96. Marchetti F, Coleman MA, Jones IM, Wyrobek AJ. Candidate

- protein biodosimeters of human exposure to ionizing radiation. *Int J Radiat Biol* 2006; 82:605–39.
97. Partridge MA, Chai Y, Zhou H, Hei TK. High-throughput antibody-based assays to identify and quantify radiation-responsive protein biomarkers. *Int J Radiat Biol* 2010; 86:321–8.
  98. Guan WJ, Ni ZY, Hu Y, Liang WH, Ou CQ, He JX, et al. Clinical characteristics of coronavirus disease 2019 in China. *N Engl J Med* 2020; 382:1708–20.
  99. Lippi G, South AM, Henry BM. Electrolyte imbalances in patients with severe coronavirus disease 2019 (COVID-19). *Ann Clin Biochem* 2020; 57:262–5.
  100. Kuba K, Imai Y, Rao S, Gao H, Guo F, Guan B, et al. A crucial role of angiotensin converting enzyme 2 (ACE2) in SARS coronavirus-induced lung injury. *Nat Med* 2005; 11:875–79.
  101. Pan L, Mu M, Yang P, Sun Y, Wang R, Yan J, et al. Clinical characteristics of COVID-19 patients with digestive symptoms in Hubei, China: A descriptive, cross-sectional, multicenter study. *Am J Gastroenterol* 2020; 115:766–73.
  102. Zhang K, Yin L, Zhang M, Parker MD, Binder HJ, Salzman P, et al. Radiation decreases murine small intestinal HCO<sub>3</sub><sup>-</sup> secretion. *Int J Radiat Biol* 2011; 87:878–88.
  103. Zseboek ZB, Petronyi G Jr. Effect of the protective action of Aet on sodium-water metabolism disorders in the so-called gastrointestinal radiation syndrome. (Article in German) *Strahlentherapie* 1964; 125:449–55.
  104. Ganji A, Farahani I, Khansarinejad B, Ghazavi A, Mosayebi G. Increased expression of CD8 marker on T-cells in COVID-19 patients. *Blood Cells Mol Dis* 2020; 83:102437.
  105. Jiang M, Guo Y, Luo Q, Huang Z, Zhao R, Liu S, et al. T-cell subset counts in peripheral blood can be used as discriminatory biomarkers for diagnosis and severity prediction of coronavirus disease 2019. *J Infect Dis* 2020; 222:198–202.
  106. Xu B, Fan CY, Wang AL, Zou YL, Yu YH, He C, et al. Suppressed T cell-mediated immunity in patients with COVID-19: A clinical retrospective study in Wuhan, China. *J Infect* 2020; 81:e51–60.
  107. Kusunoki Y, Hayashi T. Long-lasting alterations of the immune system by ionizing radiation exposure: Implications for disease development among atomic bomb survivors. *Int J Radiat Biol* 2008; 84:1–14.
  108. Farese AM, Hankey KG, Cohen MV, MacVittie TJ. Lymphoid and myeloid recovery in rhesus macaques following total body x-irradiation. *Health Phys* 2015; 109:414–26.
  109. Chambers KA, Harrington NP, Ross WM, Filion LG. Relative alterations in blood mononuclear cell populations reflect radiation injury in mice. *Cytometry* 1998; 31:45–52.
  110. Vokurkova D, Sinkora J, Vavrova J, Rezacova M, Knizek J, Ostereicher J. CD8<sup>+</sup> natural killer cells have a potential of a sensitive and reliable biodosimetric marker in vitro. *Physiol Res* 2006; 55:689–98.
  111. Kusunoki Y, Akiyama M, Kyoizumi S, Bloom ET, Makinodan T. Age-related alteration in the composition of immunocompetent blood cells in atomic bomb survivors. *Int J Radiat Biol* 1988; 53:189–98.
  112. Kusunoki Y, Kyoizumi S, Yamaoka M, Kasagi F, Kodama K, Seyama T. Decreased proportion of CD4 T cells in the blood of atomic bomb survivors with myocardial infarction. *Radiat Res* 1999; 152:539–43.
  113. Dainiak N. Hematologic consequences of exposure to ionizing radiation. *Exp Hematol* 2002; 30:513–28.
  114. Kong Y, Han J, Wu X, Zeng H, Liu J, Zhang H. VEGF-D: a novel biomarker for detection of COVID-19 progression. *Crit Care* 2020; 24:373.
  115. Smadja DM, Guerin CL, Chocron R, Yatim N, Boussier J, Gendron N, et al. Angiopoietin-2 as a marker of endothelial activation is a good predictor factor for intensive care unit admission of COVID-19 patients. *Angiogenesis* 2020:1–10.
  116. Qanadli SD, Beigelman-Aubry C, Rotzinger DC. Vascular changes detected with thoracic CT in coronavirus disease (COVID-19) might be significant determinants for accurate diagnosis and optimal patient management. *Am J Roentgenol* 2020; 215:W15.
  117. Goshua G, Pine AB, Meizlish ML, Chang CH, Zhang H, Bahel P, et al. Endotheliopathy in COVID-19-associated coagulopathy: evidence from a single-centre, cross-sectional study. *Lancet Haematol* 2020; 7:e575–82.
  118. United Nations Scientific Committee on the Effects of Atomic Radiation (UNSCEAR), Report to the General Assembly. Annex G: Early effects in man of high doses of radiation. New York: United Nations; 1988.
  119. Flidner TM, Dorr HD, Meineke V. Multi-organ involvement as a pathogenetic principle of the radiation syndromes: a study involving 110 case histories documented in SEARCH and classified as the bases of haematopoietic indicators of effect. *Brit J Radiol* 2005; S27:1–8.
  120. Baselet B, Sonveaux P, Baatout S, Aerts A. Pathological effects of ionizing radiation: endothelial activation and dysfunction. *Cell Mol Life Sci* 2019; 76:699–728.
  121. Satyamitra MM, DiCarlo AL, Taliaferro L. Understanding the pathophysiology and challenges of development of medical countermeasures for radiation-induced vascular/endothelial cell injuries: Report of a NIAID workshop, August 20, 2015. *Radiat Res* 2016; 186:99–111.
  122. Abobaker A, Raba AA, Alzwi A. Extrapulmonary and atypical clinical presentations of COVID-19. *J Med Virol* 2020; Epub ahead of print.
  123. Tay MZ, Poh CM, Renia L, MacAry PA, Ng LFP. The trinity of COVID-19: immunity, inflammation and intervention. *Nat Rev Immunol* 2020; 20:363–74.
  124. Zhang H, Kang Z, Gong H, Xu D, Wang J, Li Z, et al. Digestive system is a potential route of COVID-19: an analysis of single-cell coexpression pattern of key proteins in viral entry process. *Gut* 2020; 69:1010–8.
  125. Wang W, Xu Y, Gao R, Lu R, Han K, Wu G, et al. Detection of SARS-CoV-2 in different types of clinical specimens. *JAMA* 2020; 323:1843–4.
  126. Moriguchi T, Harii N, Goto J, Harada D, Sugawara H, Takamino J, et al. A first case of meningitis/encephalitis associated with SARS-Coronavirus-2. *Int J Infect Dis* 2020; 94:55–8.
  127. Karimi S, Arabi A, Shahraki T, Safi S. Detection of severe acute respiratory syndrome Coronavirus-2 in the tears of patients with coronavirus disease 2019. *Eye* 2020; 34:1220–3.
  128. Chan KH, Poon LL, Cheng VC, Guan Y, Hung IF, Kong J, et al. Detection of SARS coronavirus in patients with suspected SARS. *Emerg Infect Dis* 2004; 10:294–9.
  129. Price LC, McCabe C, Garfield B, Wort SJ. Thrombosis and COVID-19 pneumonia: the clot thickens! *Eur Respir J* 2020; 56:2001608.
  130. Giannis D, Ziogas IA, Gianni P. Coagulation disorders in coronavirus infected patients: COVID-19, SARS-CoV-1, MERS-CoV and lessons from the past. *J Clin Virol* 2020; 127:104362.
  131. Leonard-Lorant I, Delabranche X, Severac F, Helms J, Pautet C, Collange O, et al. Acute pulmonary embolism in COVID-19 patients on CT angiography and relationship to D-Dimer levels. *Radiol* 2020:201561.
  132. Cookson BT, Brennan MA. Pro-inflammatory programmed cell death. *Trends Microbiol* 2001; 9:113–4.
  133. Middleton EA, He XY, Denorme F, Campbell RA, Ng D, Salvatore SP, et al. Neutrophil extracellular traps (NETs) contribute to immunothrombosis in COVID-19 acute respiratory distress syndrome. *Blood* 2020; 136:1169–79.
  134. Kennedy AR, Maity A, Sanzari JK. A review of radiation-induced coagulopathy and new findings to support potential

- prevention strategies and treatments. *Radiat Res* 2016; 186:121–40.
135. Christensen DM, Iddins CJ, Parrillo SJ, Glassman ES, Goans RE. Management of ionizing radiation injuries and illnesses, part 4: acute radiation syndrome. *J Am Osteopath Assoc* 2014; 114:702–11.
  136. Simpson JM, Newburger JW. Multi-system inflammatory syndrome in children in association with COVID-19. *Circulation* 2020; Epub ahead of print.
  137. Ruan Q, Yang K, Wang W, Jiang L, Song J. Clinical predictors of mortality due to COVID-19 based on an analysis of data of 150 patients from Wuhan, China. *Intensive Care Med* 2020; 46:846–8, Erratum 1294–7.
  138. Garofalo M, Bennett A, Farese AM, Harper J, Ward A, Taylor-Howell C, et al. The delayed pulmonary syndrome following acute high-dose irradiation: a rhesus macaque model. *Health Phys* 2014; 106:56–72.
  139. Hanania AN, Mainwaring W, Ghebre YT, Hanania NA, Ludwig M. Radiation-induced lung injury: assessment and management. *Chest* 2019; 156:150–62.
  140. Bosmuller H, Traxler S, Bitzer M, Haberle H, Raiser W, Nann D, et al. The evolution of pulmonary pathology in fatal COVID-19 disease: an autopsy study with clinical correlation. *Virchows Arch* 2020; 477:349–57.
  141. Spagnolo P, Balestro E, Aliberti S, Coconcelli E, Biondini D, Casa GD, et al. Pulmonary fibrosis secondary to COVID-19: a call to arms? *Lancet Respir Med* 2020; 8:750–2.
  142. Jin X, Lian JS, Hu JH, Gao J, Zheng L, Zhang YM, et al. Epidemiological, clinical and virological characteristics of 74 cases of coronavirus-infected disease 2019 (COVID-19) with gastrointestinal symptoms. *Gut* 2020; 69:1002–9.
  143. Guan W-j, Ni Z-y, Hu Y, Liang W-h, Ou C-q, He J-x, et al. Clinical characteristics of coronavirus disease 2019 in China. *N Engl J Med* 2020; 382:1708–20.
  144. Chen Y, Chen L, Deng Q, Zhang G, Wu K, Ni L, et al. The presence of SARS-CoV-2 RNA in the feces of COVID-19 patients. *J Med Virol* 2020; 92:833–40.
  145. Lamers MM, Beumer J, van der Vaart J, Knoops K, Puschhof J, Breugem TI, et al. SARS-CoV-2 productively infects human gut enterocytes. *Science* 2020; 369:50–4.
  146. Somosy Z, Horvath G, Telbisz A, Rez G, Palfia Z. Morphological aspects of ionizing radiation response of small intestine. *Micron* 2002; 33:167–78.
  147. Dhar D, Mohanty A. Gut microbiota and Covid-19- possible link and implications. *Virus Res* 2020; 285:198018.
  148. Cui M, Xiao H, Li Y, Zhou L, Zhao S, Luo D, et al. Faecal microbiota transplantation protects against radiation-induced toxicity. *EMBO Mol Med* 2017; 9:448–61.
  149. Babapoor-Farrokhran S, Gill D, Walker J, Rasekhi RT, Bozorgnia B, Amanullah A. Myocardial injury and COVID-19: Possible mechanisms. *Life Sci* 2020; 253:117723.
  150. Guzik TJ, Mohiddin SA, Dimarco A, Patel V, Savvatis K, Marelli-Berg FM, et al. COVID-19 and the cardiovascular system: implications for risk assessment, diagnosis, and treatment options. *Cardiovasc Res* 2020; 116:1666–87.
  151. Leiper AD. Late effects of total body irradiation. *Arch Dis Child* 1995; 72:382–5.
  152. Bazyka OD, Belyi DO. Cardiovascular diseases and systolic function of left ventricle in clean up workers of Chernobyl accident (based on 30 years follow up). *Probl Radiac Med Radiobiol* 2017; 22:292–305.
  153. Shimizu Y, Pierce DA, Preston DL, Mabuchi K. Studies of the mortality of atomic bomb survivors. Report 12, part II. Noncancer mortality: 1950–1990. *Radiat Res* 1999; 152:374–89.
  154. Mao L, Jin H, Wang M, Hu Y, Chen S, He Q, et al. Neurologic manifestations of hospitalized patients with coronavirus disease 2019 in Wuhan, China. *JAMA Neurol* 2020; 77:683–90.
  155. Rogers JP, Chesney E, Oliver D, Pollak TA, McGuire P, Fusar-Poli P, et al. Psychiatric and neuropsychiatric presentations associated with severe coronavirus infections: a systematic review and meta-analysis with comparison to the COVID-19 pandemic. *Lancet Psychiatry* 2020; 7:611–27.
  156. Price RE, Langford LA, Jackson EF, Stephens LC, Tinkey PT, Ang KK. Radiation-induced morphologic changes in the rhesus monkey (*Macaca mulatta*) brain. *J Med Primatol* 2001; 30:81–7.
  157. Chen H, Li X, Zhang X, Xu W, Mao F, Bao M, et al. Late delayed radiation-induced cerebral Arteriopathy by high-resolution magnetic resonance imaging: a case report. *BMC Neurol* 2019; 19:232.
  158. Helms J, Kremer S, Merdji H, Clere-Jehl R, Schenck M, Kummerlen C, et al. Neurologic Features in Severe SARS-CoV-2 Infection. *N Engl J Med* 2020; 382:2268–70.
  159. Baig AM, Sanders EC. Potential neuroinvasive pathways of SARS-CoV-2: Deciphering the spectrum of neurological deficit seen in coronavirus disease-2019 (COVID-19). *J Med Virol* 2020; Epub ahead of print.
  160. Loganovsky KN, Loganovskaja TK. Schizophrenia spectrum disorders in persons exposed to ionizing radiation as a result of the Chernobyl accident. *Schizophr Bull* 2000; 26:751–73.
  161. Lopez M, Bell K, Annaswamy T, Juengst S, Ifejika N. COVID-19 Guide for the rehabilitation clinician: a review of non-pulmonary manifestations and complications. *Am J Phys Med Rehabil* 2020; 99:669–73.
  162. Wollina U, Karadag AS, Rowland-Payne C, Chiriac A, Lotti T. Cutaneous signs in COVID-19 patients: A review. *Dermatol Ther* 2020:e13549.
  163. Recalcati S. Cutaneous manifestations in COVID-19: a first perspective. *J Eur Acad Dermatol Venereol* 2020; 34:e212–3.
  164. Marzano AV, Cassano N, Genovese G, Moltrasio C, Vena GA. Cutaneous manifestations in patients with COVID-19: A preliminary review of an emerging issue. *Br J Dermatol* 2020; 183:431–42.
  165. Bray FN, Simmons BJ, Wolfson AH, Nouri K. Acute and chronic cutaneous reactions to ionizing radiation therapy. *Dermatol Ther (Heidelb)* 2016; 6:185–206.
  166. Vieira AR. Oral manifestations in coronavirus disease 2019 (COVID-19). *Oral Dis* 2020; Epub ahead of print.
  167. Martin Carreras-Presas C, Amaro Sanchez J, Lopez-Sanchez AF, Jane-Salas E, Somacarrera Perez ML. Oral vesiculobullous lesions associated with SARS-CoV-2 infection. *Oral Dis* 2020; Epub ahead of print.
  168. Maria OM, Eliopoulos N, Muanza T. Radiation-induced oral mucositis. *Front Oncol* 2017; 7:89.
  169. DiCarlo AL, Bandremer AC, Hollingsworth BA, Kasim S, Laniyonu A, Todd NF, et al. Workshop report. Cutaneous radiation injuries: models, assessment and treatments. *Radiat Res* 2020; 194(3):315–344.
  170. Chu KH, Tsang WK, Tang CS, Lam MF, Lai FM, To KF, et al. Acute renal impairment in coronavirus-associated severe acute respiratory syndrome. *Kidney Int* 2005; 67:698–705.
  171. Cogan MG, Arieff AI. Radiation nephritis and intravascular coagulation. *Clin Nephrol* 1978; 10:74–8.
  172. Peter RU, Braun-Falco O, Birioukov A, Hacker N, Kerscher M, Peterseim U, et al. Chronic cutaneous damage after accidental exposure to ionizing radiation: the Chernobyl experience. *J Am Acad Dermatol* 1994; 30:719–23.
  173. Xia S, Wu M, Chen S, Zhang T, Ye L, Liu J, et al. Long term culture of human kidney proximal tubule epithelial cells maintains lineage functions and serves as an ex vivo model for coronavirus associated kidney injury. *Virol Sin* 2020:1–10.
  174. Kim J, Jung Y. Radiation-induced liver disease: current understanding and future perspectives. *Exp Mol Med* 2017; 49:e359.
  175. Su TH, Kao JH. The clinical manifestations and management of



- COVID-19-related liver injury. *J Formos Med Assoc* 2020; 119:1016–8.
176. Hempel M, Hinkelbein W. Eye sequelae following external irradiation. *Recent Results Cancer Res* 1993; 130:231–6.
  177. Pinard CL, Mutsaers AJ, Mayer MN, Woods JP. Retrospective study and review of ocular radiation side effects following external-beam Cobalt-60 radiation therapy in 37 dogs and 12 cats. *Can Vet J* 2012; 53:1301–7.
  178. Gottlober P, Steinert M, Weiss M, Bebeshko V, Belyi D, Nadejina N, et al. The outcome of local radiation injuries: 14 years of follow-up after the Chernobyl accident. *Radiat Res* 2001; 155:409–16.
  179. Fedirko P, Babenko T, Kolosynska O, Dorichevska R, Garkava N, Grek L, et al. Morphometric parameters of retinal macular zone in reconvalescents of acute radiation sickness (in remote period). *Probl Radiac Med Radiobiol* 2018; 23:481–9.
  180. Verma S, Saksena S, Sadri-Ardekani H. ACE2 receptor expression in testes: implications in coronavirus disease 2019 pathogenesis. *Biol Reprod* 2020; 103:449–51.
  181. Wambier CG, Vano-Galvan S, McCoy J, Gomez-Zubiaur A, Herrera S, Hermosa-Gelbard A, et al. Androgenetic alopecia present in the majority of patients hospitalized with COVID-19: The “Gabrin sign”. *J Am Acad Dermatol* 2020; 83:680–2.
  182. Krantz S, Lober M. Review: hemorrhagic diathesis resulting from acute exposure to ionizing radiation. (Article in German). *Folia Haematol Int Mag Klin Morphol Blutforsch* 1977; 104:1–10.
  183. Pospisil J. Postirradiation haemorrhagic syndrome. *Acta Univ Carol Med Monogr* 1987; 99:1–187.
  184. Liebow AA, Warren S, DeCoursey E. Pathology of atomic bomb casualties. *Am J Pathol* 1949; 25:853.
  185. Valverde N, Cordeiro J, Oliveira A, Brandao Mello C. The acute radiation syndrome in the 137 Cs Brazilian accident, 1987. In: Ricks RC, Fry SA, editors. *The medical basis for radiation accident preparedness. II: Clinical experience and follow up since 1979*. New York: Elsevier North Holland Inc.; 1990. p. 89–107.
  186. Andrews GA. Criticality accidents in Vinca, Yugoslavia, and Oak Ridge, Tennessee: Comparison of radiation injuries and results of therapy. *JAMA* 1962; 179:191–7.
  187. Ippolito E, Fiore M, Greco C, D’Angelillo RM, Ramella S. COVID-19 and radiation induced pneumonitis: Overlapping clinical features of different diseases. *Radiother Oncol* 2020; 148:201–2.
  188. Ehrenreich H, Weissenborn K, Begemann M, Busch M, Vieta E, Miskowiak KW. Erythropoietin as candidate for supportive treatment of severe COVID-19. *Mol Med* 2020; 26:58.
  189. Peslak SA, Wenger J, Bemis JC, Kingsley PD, Koniski AD, McGrath KE, et al. EPO-mediated expansion of late-stage erythroid progenitors in the bone marrow initiates recovery from sublethal radiation stress. *Blood* 2012; 120:2501–11.
  190. Drouet M, Grenier N, Herodin F. Revisiting emergency anti-apoptotic cytokinotherapy: erythropoietin synergizes with stem cell factor, FLT-3 ligand, trombopoietin and interleukin-3 to rescue lethally-irradiated mice. *Eur Cytokine Netw* 2012; 23:56–63.
  191. Galal SM, Abdel-Rafei MK, Hasan HF. Cholinergic and cytoprotective signaling cascades mediate the mitigative effect of erythropoietin on acute radiation syndrome. *Can J Physiol Pharmacol* 2018; 96:442–58.
  192. Singh VK, Seed TM. An update on sargramostim for treatment of acute radiation syndrome. *Drugs Today (Barc)* 2018; 54:679–93.
  193. Lang FM, Lee KM, Teijaro JR, Becher B, Hamilton JA. GM-CSF-based treatments in COVID-19: reconciling opposing therapeutic approaches. *Nat Rev Immunol* 2020; 1–8.
  194. Aytı PK, Pathak CM, Kumar S, Kaushik G, Kaushik T, Farooque A, et al. Low dose gamma-irradiation differentially modulates antioxidant defense in liver and lungs of Balb/c mice. *Int J Radiat Biol* 2005; 81:901–10.
  195. Biaglow JE, Ayene IS, Koch CJ, Donahue J, Stamato TD, Mieyal JJ, et al. Radiation response of cells during altered protein thiol redox. *Radiat Res* 2003; 159:484–94.
  196. Hernandez-Flores G, Gómez-Contreras PC, Dominguez-Rodriguez JR, Lerma-Diaz JM, Ortiz-Lazareno PC, Cervantes-Munguia R, et al. Gamma-irradiation induced apoptosis in peritoneal macrophages by oxidative stress. Implications of antioxidants in caspase mitochondrial pathway. *Anticancer Res* 2005; 25:4091–100.
  197. Koturbash I, Rugo RE, Hendricks CA, Loree J, Thibault B, Kutanzi K, et al. Irradiation induces DNA damage and modulates epigenetic effectors in distant bystander tissue in vivo. *Oncogene* 2006; 25:4267–75.
  198. Parsons WB, Jr., Watkins CH, Pease GL, Childs DS, Jr. Changes in sternal marrow following roentgen-ray therapy to the spleen in chronic granulocytic leukemia. *Cancer* 1954; 7:179–89.
  199. Petrovic N, Perovic J, Karanovic D, Todorovic L, Petrovic V. Abscopal effects of local fractionated X-irradiation of face and jaw region. *Strahlentherapie* 1982; 158:40–2.
  200. Robin HI, AuBuchon J, Varanasi VR, Weinstein AB. The abscopal effect: demonstration in lymphomatous involvement of kidneys. *Med Pediatr Oncol* 1981; 9:473–6.
  201. Jia D, Koonce NA, Griffin RJ, Jackson C, Corry PM. Prevention and mitigation of acute death of mice after abdominal irradiation by the antioxidant N-acetyl-cysteine (NAC). *Radiat Res* 2010; 173:579–89.
  202. Corry PM, Griffin RJ. A radiation mitigator as a potential treatment for COVID-19. *Radiat Res* 2020; 193:505.
  203. Moradi M, Mojtahedzadeh M, Mandegari A, Soltan-Sharifi MS, Najafi A, Khajavi MR, et al. The role of glutathione-S-transferase polymorphisms on clinical outcome of ALI/ARDS patient treated with N-acetylcysteine. *Respir Med* 2009; 103:434–41.
  204. Ahmadi A, Ebrahimzadeh MA, Ahmad-Ashrafi S, Karami M, Mahdavi MR, Saravi SS. Hepatoprotective, antinociceptive and antioxidant activities of cimetidine, ranitidine and famotidine as histamine H2 receptor antagonists. *Fundam Clin Pharmacol* 2011; 25:72–9.
  205. Kandeel M, Abdelrahman AHM, Oh-Hashi K, Ibrahim A, Venugopala KN, Morsy MA, et al. Repurposing of FDA-approved antivirals, antibiotics, anthelmintics, antioxidants, and cell protectives against SARS-CoV-2 papain-like protease. *J Biomol Struct Dyn* 2020; 1–8.
  206. Rogosnitzky M, Berkowitz E, Jadad AR. Delivering benefits at speed through real-world repurposing of off-patent drugs: the COVID-19 pandemic as a case in point. *JMIR Public Health Surveill* 2020; 6:e19199.
  207. Ortega JT, Serrano ML, Jastrzebska B. Class A G protein-coupled receptor antagonist famotidine as a therapeutic alternative against SARS-CoV2: an in silico analysis. *Biomolecules* 2020; 10:954.
  208. Borrell B. New York clinical trial quietly tests heartburn remedy against coronavirus. *Science* 2020. (<https://bit.ly/3cgcsXg>)
  209. Freedberg DE, Conigliaro J, Wang TC, Tracey KJ, Callahan MV, Abrams JA, et al. Famotidine use is associated with improved clinical outcomes in hospitalized COVID-19 patients: a propensity score matched retrospective cohort study. *Gastroenterology* 2020; 159:1129–31.e3.
  210. Malone RW, Tisdall P, Fremont-Smith P, Liu Y, Huang XP, White KM, et al. COVID-19: famotidine, histamine, mast cells, and mechanisms. *Res Sq* 2020; Preprint. (<https://bit.ly/3iLpUEV>)
  211. Naeji A, Mozdarani H, Shabestani Monfared A, Faeghi F, Ahmadi AA, Gholami M, et al. Oral administration of vitamin C, cimetidine and famotidine on micronuclei induced by low dose radiation in mouse bone marrow cells. *J Biomed Phys Eng* 2017; 7:117–26.
  212. Zangeneh M, Mozdarani H, Mahmoudzadeh A. Potent radioprotective effects of combined regimens of famotidine and vitamin C

- against radiation-induced micronuclei in mouse bone marrow erythrocytes. *Radiat Environ Biophys* 2015; 54:175–81.
213. Mozdarani H, Nasirian B, Haeri SA. In vivo gamma-rays induced initial DNA damage and the effect of famotidine in mouse leukocytes as assayed by the alkaline comet assay. *J Radiat Res* 2007; 48:129–34.
  214. Razzaghdoust A, Mozdarani H, Mofid B, Aghamiri SM, Heidari AH. Reduction in radiation-induced lymphocytopenia by famotidine in patients undergoing radiotherapy for prostate cancer. *Prostate* 2014; 74:41–7.
  215. Razzaghdoust A, Mozdarani H, Mofid B. Famotidine as a radioprotector for rectal mucosa in prostate cancer patients treated with radiotherapy: phase I/II randomized placebo-controlled trial. *Strahlenther Onkol* 2014; 190:739–44.
  216. Mozdarani H, Ghoraeian P. Modulation of gamma-ray-induced apoptosis in human peripheral blood leukocytes by famotidine and vitamin C. *Mutat Res* 2008; 649:71–8.
  217. Ye Q, Wang B, Mao J. The pathogenesis and treatment of the ‘Cytokine Storm’ in COVID-19. *J Infect* 2020; 80:607–13.
  218. Lee DW, Gardner R, Porter DL, Louis CU, Ahmed N, Jensen M, et al. Current concepts in the diagnosis and management of cytokine release syndrome. *Blood* 2014; 124:188–95.
  219. Somers EC, Eschenauer GA, Troost JP, Golob JL, Gandhi TN, Wang L, et al. Tocilizumab for treatment of mechanically ventilated patients with COVID-19. *Clin Infect Dis* 2020:ciaa954.
  220. Antinori S, Bonazzetti C, Gubertini G, Capetti A, Pagani C, Morena V, et al. Tocilizumab for cytokine storm syndrome in COVID-19 pneumonia: an increased risk for candidemia? *Autoimmun Rev* 2020; 19:102564.
  221. Carvalho V, Turon R, Goncalves B, Ceotto V, Kurtz P, Righy C. Effects of tocilizumab in critically ill patients with COVID-19: a quasi-experimental study. medRxiv 2020. (<https://bit.ly/33MtLLF>)
  222. Geraci JP, Mariano MS, Jackson KL, Taylor DA, Still ER. Effects of dexamethasone on late radiation injury following partial-body and local organ exposures. *Radiat Res* 1992; 129:61–70.
  223. Thrall KD, Mahendra S, Jackson MK, Jackson W 3rd, Farese AM, MacVittie TJ. A comparative dose-response relationship between sexes for mortality and morbidity of radiation-induced lung injury in the rhesus macaque. *Health Phys* 2019; 116:354–65.
  224. MacVittie TJ, Farese AM, Parker GA, Jackson W 3rd. The time course of radiation-induced lung injury in a nonhuman primate model of partial-body irradiation with minimal bone marrow sparing: clinical and radiographic evidence and the effect of neupogen administration. *Health Phys* 2019; 116:366–82.
  225. Hui D, Kilgore K, Frisbee-Hume S, Park M, Tsao A, Delgado Guay M, et al. Dexamethasone for dyspnea in cancer patients: a pilot double-blind, randomized, controlled trial. *J Pain Symptom Manage* 2016; 52:8–16.e1.
  226. Horby P, Lim WS, Emberson JR, Mafham M, Bell JL, Linsell L, et al. Dexamethasone in hospitalized patients with COVID-19 - preliminary report. *N Engl J Med* 2020; Epub ahead of print.
  227. WHO Rapid Evidence Appraisal for COVID-19 Therapies Working Group, Sterne JAC, Murthy S, Diaz JV, Slutsky AS, Villar J, et al. Association between administration of systemic corticosteroids and mortality among critically ill patients with COVID-19: a meta-analysis. *JAMA* 2020; 324(13):1330–1341.
  228. Jackson IL, Zodda A, Gurung G, Pavlovic R, Kaytor MD, Kuskowski MA, et al. BIO 300, a nanosuspension of genistein, mitigates pneumonitis/fibrosis following high-dose radiation exposure in the C57L/J murine model. *Br J Pharmacol* 2017; 174:4738–50.
  229. Andres A, Donovan SM, Kuhlenschmidt MS. Soy isoflavones and virus infections. *J Nutr Biochem* 2009; 20:563–9.
  230. Kolokoltsov AA, Adhikary S, Garver J, Johnson L, Davey RA, Vela EM. Inhibition of Lassa virus and Ebola virus infection in host cells treated with the kinase inhibitors genistein and tyrphostin. *Arch Virol* 2012; 157:121–7.
  231. Vela EM, Knostman KA, Mott JM, Warren RL, Garver JN, Vela LJ, et al. Genistein, a general kinase inhibitor, as a potential antiviral for arenaviral hemorrhagic fever as described in the Pirital virus-Syrian golden hamster model. *Antiviral Res* 2010; 87:318–28.
  232. Gong L, Li Y, Nedeljkovic-Kurepa A, Sarkar FH. Inactivation of NF-kappaB by genistein is mediated via Akt signaling pathway in breast cancer cells. *Oncogene* 2003; 22:4702–9.
  233. Christersdottir T, Pirault J, Gistera A, Bergman O, Gallina AL, Baumgartner R, et al. Prevention of radiotherapy-induced arterial inflammation by interleukin-1 blockade. *Eur Heart J* 2019; 40:2495–503.
  234. Filocamo G, Mangioni D, Tagliabue P, Aliberti S, Costantino G, Minoia F, et al. Use of anakinra in severe COVID-19: a case report. *Int J Infect Dis* 2020; 96:607–9.
  235. Huet T, Beaussier H, Voisin O, Jouveshomme S, Dauriat G, Lazareth I, et al. Anakinra for severe forms of COVID-19: a cohort study. *Lancet Rheumatol* 2020; 2:e393–400.
  236. De Ruyscher D, Granton PV, Lieuwes NG, van Hoof S, Wollin L, Weynand B, et al. Nintedanib reduces radiation-induced microscopic lung fibrosis but this cannot be monitored by CT imaging: A preclinical study with a high precision image-guided irradiator. *Radiother Oncol* 2017; 124:482–7.
  237. Qin W, Liu B, Yi M, Li L, Tang Y, Wu B, et al. Antifibrotic agent pirfenidone protects against development of radiation-induced pulmonary fibrosis in a murine model. *Radiat Res* 2018; 190:396–403.
  238. George PM, Wells AU, Jenkins RG. Pulmonary fibrosis and COVID-19: the potential role for antifibrotic therapy. *Lancet Respir Med* 2020; 8:807–15.
  239. Bernal-Bello D, Jaenes-Barríos B, Morales-Ortega A, Ruiz-Giardin JM, Garcia-Bermudez V, Frutos-Perez B, et al. Imatinib might constitute a treatment option for lung involvement in COVID-19. *Autoimmun Rev* 2020; 19:102565.
  240. Zabel P, Schade FU, Schlaak M. Inhibition of endogenous TNF formation by pentoxifylline. *Immunobiology* 1993; 187:447–63.
  241. Okunieff P, Augustine E, Hicks JE, Cornelison TL, Altemus RM, Naydich BG, et al. Pentoxifylline in the treatment of radiation-induced fibrosis. *J Clin Oncol* 2004; 22:2207–13.
  242. Patel V, McGurk M. Use of pentoxifylline and tocopherol in radiation-induced fibrosis and fibroatrophy. *Br J Oral Maxillofac Surg* 2017; 55:235–41.
  243. Assimakopoulos SF, Seintis F, Marangos M. Pentoxifylline and complicated COVID-19: A pathophysiologically based treatment proposal. *Med Hypotheses* 2020; 143:109926.
  244. Yue X, Shan B, Lasky JA. TGF-beta: Titan of lung fibrogenesis. *Curr Enzym Inhib* 2010; 6:10.2174/10067.
  245. Chen W. A potential treatment of COVID-19 with TGF-beta blockade. *Int J Biol Sci* 2020; 16:1954–5.
  246. Uckun FM, Hwang L, Trieu V. Selectively targeting TGF-beta with Trabedersen/OT-101 in treatment of evolving and mild ARDS in COVID-19. *Clin Invest (Lond)* 2020; 10:167–76.
  247. Rabender C, Mezzaroma E, Mauro AG, Mullangi R, Abbate A, Anscher M, et al. IPW-5371 proves effective as a radiation countermeasure by mitigating radiation-induced late effects. *Radiat Res* 2016; 186:478–88.
  248. Ziegler CGK, Allon SJ, Nyquist SK, Mbanu IM, Miao VN, Tzouanas CN, et al. SARS-CoV-2 receptor ACE2 is an interferon-stimulated gene in human airway epithelial cells and is detected in specific cell subsets across tissues. *Cell* 2020; 181:1016–35.e19.
  249. Li W, Moore MJ, Vasileva N, Sui J, Wong SK, Berne MA, et al. Angiotensin-converting enzyme 2 is a functional receptor for the SARS coronavirus. *Nature* 2003; 426:450–4.

250. Danser AHJ, Epstein M, Batlle D. Renin-angiotensin system blockers and the COVID-19 pandemic: at present there is no evidence to abandon renin-angiotensin system blockers. *Hypertension* 2020; 75:1382–5.
251. Kuster GM, Pfister O, Burkard T, Zhou Q, Twerenbold R, Haaf P, et al. SARS-CoV2: should inhibitors of the renin-angiotensin system be withdrawn in patients with COVID-19? *Eur Heart J* 2020; 41:1801–3.
252. Reynolds HR, Adhikari S, Pulgarin C, Troxel AB, Iturrate E, Johnson SB, et al. Renin-angiotensin-aldosterone system inhibitors and risk of Covid-19. *N Engl J Med* 2020; 382:2441–8.
253. Hanff TC, Harhay MO, Brown TS, Cohen JB, Mohareb AM. Is there an association between COVID-19 mortality and the renin-angiotensin system? A call for epidemiologic investigations. *Clin Infect Dis* 2020; 71:870–4.
254. Dalan R, Bornstein SR, El-Armouche A, Rodionov RN, Markov A, Wielockx B, et al. The ACE-2 in COVID-19: foe or friend? *Horm Metab Res* 2020; 52:257–63.
255. Shete A. Urgent need for evaluating agonists of angiotensin-(1-7)/Mas receptor axis for treating patients with COVID-19. *Int J Infect Dis* 2020; 96:348–51.
256. Meng J, Xiao G, Zhang J, He X, Ou M, Bi J, et al. Renin-angiotensin system inhibitors improve the clinical outcomes of COVID-19 patients with hypertension. *Emerg Microbes Infect* 2020; 9:757–60.
257. Medhora M, Gao F, Wu Q, Molthen RC, Jacobs ER, Moulder JE, et al. Model development and use of ACE inhibitors for preclinical mitigation of radiation-induced injury to multiple organs. *Radiat Res* 2014; 182:545–55.
258. Medhora M, Gao F, Jacobs ER, Moulder JE. Radiation damage to the lung: mitigation by angiotensin-converting enzyme (ACE) inhibitors. *Respirology* 2012; 17:66–71.
259. Fish BL, Gao F, Narayanan J, Bergom C, Jacobs ER, Cohen EP, et al. Combined hydration and antibiotics with lisinopril to mitigate acute and delayed high-dose radiation injuries to multiple organs. *Health Phys* 2016; 111:410–9.
260. Mehrvar S, la Cour MF, Medhora M, Camara AKS, Ranji M. Optical metabolic imaging for assessment of radiation-induced injury to rat kidney and mitigation by lisinopril. *Ann Biomed Eng* 2019; 47:1564–74.
261. Gao F, Fish BL, Moulder JE, Jacobs ER, Medhora M. Enalapril mitigates radiation-induced pneumonitis and pulmonary fibrosis if started 35 days after whole-thorax irradiation. *Radiat Res* 2013; 180:546–52.
262. Islam A, Bolduc DL, Zhai M, Kiang JG, Swift JM. Captopril increases survival after whole-body ionizing irradiation but decreases survival when combined with skin-burn trauma in mice. *Radiat Res* 2015; 184:273–9.
263. Clausi MG, Stessin AM, Tsirka SE, Ryu S. Mitigation of radiation myelopathy and reduction of microglial infiltration by Ramipril, ACE inhibitor. *Spinal Cord* 2018; 56:733–40.
264. Rodgers KE, Xiong S, diZerega GS. Accelerated recovery from irradiation injury by angiotensin peptides. *Cancer Chemother Pharmacol* 2002; 49:403–11.
265. Rodgers KE, Espinoza T, Roda N, Meeks CJ, Hill C, Louie SG, et al. Accelerated hematopoietic recovery with angiotensin-(1-7) after total body radiation. *Int J Radiat Biol* 2012; 88:466–76.
266. Chi Y, Ge Y, Wu B, Zhang W, Wu T, Wen T, et al. Serum cytokine and chemokine profile in relation to the severity of coronavirus disease 2019 (COVID-19) in China. *J Infect Dis* 2020; 222:746–54.
267. Medford AR, Millar AB. Vascular endothelial growth factor (VEGF) in acute lung injury (ALI) and acute respiratory distress syndrome (ARDS): paradox or paradigm? *Thorax* 2006; 61:621–6.
268. Mukherji SK. Bevacizumab (Avastin). *AJNR Am J Neuroradiol* 2010; 31:235–6.
269. Makinde AY, Luo-Owen X, Rizvi A, Crapo JD, Pearlstein RD, Slater JM, et al. Effect of a metalloporphyrin antioxidant (MnTE-2-PyP) on the response of a mouse prostate cancer model to radiation. *Anticancer Res* 2009; 29:107–18.
270. Liu Y, Kudo K, Abe Y, Aoki M, Hu DL, Kijima H, et al. Hypoxia expression in radiation-induced late rectal injury. *J Radiat Res* 2008; 49:261–8.
271. Dashti SR, Spalding A, Kadner RJ, Yao T, Kumar A, Sun DA, et al. Targeted intraarterial anti-VEGF therapy for medically refractory radiation necrosis in the brain. *J Neurosurg Pediatr* 2015; 15:20–5.
272. Jiang X, Engelbach JA, Yuan L, Cates J, Gao F, Drzymala RE, et al. Anti-VEGF antibodies mitigate the development of radiation necrosis in mouse brain. *Clin Cancer Res* 2014; 20:2695–702.
273. Aslan A, Kaya ZB, Bulduk EB, Ocal O, Ucar M, Erpolat OP, et al. Prophylactic bevacizumab may mitigate radiation injury: an experimental study. *World Neurosurg* 2018; 116:e791–800.
274. Xu Y, Rong X, Hu W, Huang X, Li Y, Zheng D, et al. Bevacizumab monotherapy reduces radiation-induced brain necrosis in nasopharyngeal carcinoma patients: a randomized controlled trial. *Int J Radiat Oncol Biol Phys* 2018; 101:1087–95.
275. Lillcrap D. Disseminated intravascular coagulation in patients with 2019-nCoV pneumonia. *J Thromb Haemost* 2020; 18:786–7.
276. Kollias A, Kyriakoulis KG, Dimakakos E, Poulakou G, Stergiou GS, Syrigos K. Thromboembolic risk and anticoagulant therapy in COVID-19 patients: emerging evidence and call for action. *Br J Haematol* 2020; 189:846–7.
277. Al-Samkari H, Karp Leaf RS, Dzik WH, Carlson JC, Fogerty AE, Waheed A, et al. COVID and coagulation: bleeding and thrombotic manifestations of SARS-CoV2 infection. *Blood* 2020; 136:489–500.
278. Harenberg J, Favaloro E. COVID-19: progression of disease and intravascular coagulation - present status and future perspectives. *Clin Chem Lab Med* 2020; 58:1029–36.
279. Gando S, Levi M, Toh CH. Disseminated intravascular coagulation. *Nat Rev Dis Primers* 2016; 2:16037.
280. Krigsfeld GS, Savage AR, Billings PC, Lin L, Kennedy AR. Evidence for radiation-induced disseminated intravascular coagulation as a major cause of radiation-induced death in ferrets. *Int J Radiat Oncol Biol Phys* 2014; 88:940–6.
281. Krigsfeld GS, Shah JB, Sanzari JK, Lin L, Kennedy AR. Evidence of disseminated intravascular coagulation in a porcine model following radiation exposure. *Life Sci Space Res (Amst)* 2014; 3:1–9.
282. DiCarlo AL, Kaminski JM, Hatchett RJ, Maidment BW. Role of thrombocytopenia in radiation-induced mortality and review of therapeutic approaches targeting platelet regeneration after radiation exposure. *J Radiat Oncol* 2016; 5:19–32.
283. Han H, Yang L, Liu R, Liu F, Wu KL, Li J, et al. Prominent changes in blood coagulation of patients with SARS-CoV-2 infection. *Clin Chem Lab Med* 2020; 58:1116–20.
284. Xu P, Zhou Q, Xu J. Mechanism of thrombocytopenia in COVID-19 patients. *Ann Hematol* 2020; 99:1205–8.
285. Bunin DI, Bakke J, Green CE, Javitz HS, Fielden M, Chang PY. Romiplostim (Nplate(R)) as an effective radiation countermeasure to improve survival and platelet recovery in mice. *Int J Radiat Biol* 2020; 96:145–54.
286. Sun H, Tsai Y, Nowak I, Liesveld J, Chen Y. Eltrombopag, a thrombopoietin receptor agonist, enhances human umbilical cord blood hematopoietic stem/primitive progenitor cell expansion and promotes multi-lineage hematopoiesis. *Stem Cell Res* 2012; 9:77–86.
287. Liesveld JL, Phillips GL, 2nd, Becker M, Constine LS, Friedberg J, Andolina JR, et al. A phase 1 trial of eltrombopag in patients undergoing stem cell transplantation after total body irradiation. *Biol Blood Marrow Transplant* 2013; 19:1745–52.
288. Zulfikar AA, Lorenzo-Villalba N, Hassler P, Andres E. Immune



- thrombocytopenic purpura in a patient with COVID-19. *N Engl J Med* 2020; 382:e43.
289. Riker RR, May TL, Fraser GL, Gagnon DJ, Bandara M, Zemrak WR, et al. Heparin-induced thrombocytopenia with thrombosis in COVID-19 adult respiratory distress syndrome. *Res Pract Thromb Haemost* 2020; 4:936–41.
  290. Thachil J TN, Gando S, Falanga A, Cattaneo M, Levi M. ISTH interim guidance on recognition and management of coagulopathy in COVID-19. *J Thromb Haemost* 2020; 18:1023–6.
  291. Kantara C, Moya SM, Houchen CW, Umar S, Ullrich RL, Singh P, et al. Novel regenerative peptide TP508 mitigates radiation-induced gastrointestinal damage by activating stem cells and preserving crypt integrity. *Lab Invest* 2015; 95:1222–33.
  292. Fossum TW, Olszewska-Pazdrak B, Mertens MM, Makarski LA, Miller MW, Hein TW, et al. TP508 (Chrysalin) reverses endothelial dysfunction and increases perfusion and myocardial function in hearts with chronic ischemia. *J Cardiovasc Pharmacol Ther* 2008; 13:214–25.
  293. Ryaby JT, Sheller MR, Levine BP, Bramlet DG, Ladd AL, Carney DH. Thrombin peptide TP508 stimulates cellular events leading to angiogenesis, revascularization, and repair of dermal and musculoskeletal tissues. *J Bone Joint Surg Am* 2006; 88:S132–9.
  294. Fife C, Mader JT, Stone J, Brill L, Satterfield K, Norfleet A, et al. Thrombin peptide Chrysalin stimulates healing of diabetic foot ulcers in a placebo-controlled phase I/II study. *Wound Repair Regen* 2007; 15:23–34.
  295. Dashti-Khavidaki S, Khalili H. Considerations for statin therapy in patients with COVID-19. *Pharmacotherapy* 2020; 40:484–6.
  296. Lee KCH, Sewa DW, Phua GC. Potential role of statins in COVID-19. *Int J Infect Dis* 2020.
  297. Rodrigues-Diez RR, Tejera-Munoz A, Marquez-Exposito L, Rayego-Mateos S, Sanchez LS, Marchant V, et al. Statins: Could an old friend help the fight against COVID-19? *Br J Pharmacol* 2020; 177(21):4873–4886.
  298. Reiner Z, Hatamipour M, Banach M, Pirro M, Al-Rasadi K, Jamialahmadi T, et al. Statins and the COVID-19 main protease: in silico evidence on direct interaction. *Arch Med Sci* 2020; 16:490–6.
  299. South AM, Diz DI, Chappell MC. COVID-19, ACE2, and the cardiovascular consequences. *Am J Physiol Heart Circ Physiol* 2020; 318:H1084–90.
  300. Fedson DS, Opal SM, Rordam OM. Hiding in plain sight: an approach to treating patients with severe COVID-19 infection. *mBio* 2020; 11:e00398–20.
  301. Kow CS, Hasan SS. Use of statins in patients with COVID-19. *QJM* 2020; 113:604–5.
  302. Zhang XJ, Qin JJ, Cheng X, Shen L, Zhao YC, Yuan Y, et al. In-hospital use of statins is associated with a reduced risk of mortality among individuals with COVID-19. *Cell Metab* 2020; 32:176–87.e4.
  303. Mathew B, Huang Y, Jacobson JR, Berdyshev E, Gerhold LM, Wang T, et al. Simvastatin attenuates radiation-induced murine lung injury and dysregulated lung gene expression. *Am J Respir Cell Mol Biol* 2011; 44:415–22.
  304. Zhao X, Yang H, Jiang G, Ni M, Deng Y, Cai J, et al. Simvastatin attenuates radiation-induced tissue damage in mice. *J Radiat Res* 2014; 55:257–64.
  305. Xu L, Yang X, Chen J, Ge X, Qin Q, Zhu H, et al. Simvastatin attenuates radiation-induced salivary gland dysfunction in mice. *Drug Des Devel Ther* 2016; 10:2271–8.
  306. Zhang K, He X, Zhou Y, Gao L, Qi Z, Chen J, et al. Atorvastatin ameliorates radiation-induced cardiac fibrosis in rats. *Radiat Res* 2015; 184:611–20.
  307. Talebpour Amiri F, Hamzeh M, Naeimi RA, Ghasemi A, Hosseinimehr SJ. Radioprotective effect of atorvastatin against ionizing radiation-induced nephrotoxicity in mice. *Int J Radiat Biol* 2018; 94:106–13.
  308. Ran XZ, Ran X, Zong ZW, Liu DQ, Xiang GM, Su YP, et al. Protective effect of atorvastatin on radiation-induced vascular endothelial cell injury in vitro. *J Radiat Res* 2010; 51:527–33.
  309. Williams JP, Hernady E, Johnston CJ, Reed CM, Fenton B, Okunieff P, et al. Effect of administration of lovastatin on the development of late pulmonary effects after whole-lung irradiation in a murine model. *Radiat Res* 2004; 161:560–7.
  310. Geiger H, Pawar SA, Kerschen EJ, Nattamai KJ, Hernandez I, Liang HP, et al. Pharmacological targeting of the thrombomodulin-activated protein C pathway mitigates radiation toxicity. *Nat Med* 2012; 18:1123–9.
  311. Griffin JH, Lyden P. COVID-19 hypothesis: activated protein C for therapy of virus-induced pathologic thromboinflammation. *Res Pract Thromb Haemost* 2020; 4:506–9.
  312. Wang J. Fast identification of possible drug treatment of coronavirus disease-19 (COVID-19) through computational drug repurposing study. *J Chem Inf Model* 2020; 60:3277–86.
  313. Toma E. Doxycycline and pentoxifylline for mild and mild-to-moderate Covid-19. 2020; Preprints 2020; (<https://bit.ly/2ZYyby1>)
  314. Conforti C, Giuffrida R, Zalaudek I, Di Meo N. Doxycycline, a widely used antibiotic in dermatology with a possible anti-inflammatory action against IL-6 in COVID-19 outbreak. *Dermatol Ther* 2020; Epub ahead of print.
  315. Schogler A, Kopf BS, Edwards MR, Johnston SL, Casaulta C, Kieninger E, et al. Novel antiviral properties of azithromycin in cystic fibrosis airway epithelial cells. *Eur Respir J* 2015; 45:428–39.
  316. Pokhrel R, Chapagain P, Siltberg-Liberles J. Potential RNA-dependent RNA polymerase inhibitors as prospective therapeutics against SARS-CoV-2. *J Med Microbiol* 2020; 69:864–73.
  317. Pindiprolu S, Kumar CSP, Kumar Golla VS, Likitha P, Chandrta S, Bashae, et al. Pulmonary delivery of nanostructured lipid carriers for effective repurposing of salinomycin as an antiviral agent. *Med Hypotheses* 2020; 143:109858.
  318. Jean SS, Hsueh PR. Old and re-purposed drugs for the treatment of COVID-19. *Expert Rev Anti Infect Ther* 2020:1–5.
  319. Ceccarelli G, Alessandri F, d’Ettorre G, Borrazzo C, Spagnolello O, Oliva A, et al. Is teicoplanin a complementary treatment option for COVID-19? The question remains. *Int J Antimicrob Agents* 2020:106029.
  320. Sivapalan P, Ulrik CS, Bojesen RD, Lapperre TS, Eklof JV, Hakansson KEJ, et al. Proactive prophylaxis with azithromycin and hydroxychloroquine in hospitalised patients with COVID-19 (ProPAC-COVID): a structured summary of a study protocol for a randomised controlled trial. *Trials* 2020; 21:513.
  321. Damle B, Vourvahis M, Wang E, Leaney J, Corrigan B. Clinical pharmacology perspectives on the antiviral activity of azithromycin and use in COVID-19. *Clin Pharmacol Ther* 2020; 108:201–11.
  322. Gbinigie K, Frie K. Should azithromycin be used to treat COVID-19? A rapid review. *BJGP Open* 2020; 4:bjgpopen20X101094.
  323. Du Y, Tu L, Zhu P, Mu M, Wang R, Yang P, et al. Clinical features of 85 fatal cases of COVID-19 from Wuhan: a retrospective observational study. *Am J Respir Crit Care Med* 2020; 201:1372–9.
  324. Naseer MS, Chand R, Coppola S, Abreo A, Sharma M, Singh N. Post-transplant de-novo renal phospholipidosis in a kidney transplant recipient: Fabry disease or something else? *Clin Nephrol Case Stud* 2020; 8:46–8.
  325. Asaduzzaman M, Zaman F, Rousham E. Antibiotic consumption may be linked to exaggeration of COVID-19. *Med Hypotheses* 2020; 143:109913.
  326. Epperly MW, Franicola D, Shields D, Rwigema JC, Stone B,

- Zhang X, et al. Screening of antimicrobial agents for in vitro radiation protection and mitigation capacity, including those used in supportive care regimens for bone marrow transplant recipients. *In Vivo* 2010; 24:9–19.
327. Kim K, Damoiseaux R, Norris AJ, Rivina L, Bradley K, Jung ME, et al. High throughput screening of small molecule libraries for modifiers of radiation responses. *Int J Radiat Biol* 2011; 87:839–45.
328. Shalit I, Kletter Y, Weiss K, Gruss T, Fabian I. Enhanced hematopoiesis in sublethally irradiated mice treated with various quinolones. *Eur J Haematol* 1997; 58:92–8.
329. Linkenheimer WH, Berger H. The effect of continuous antibiotic feeding on x-irradiation mortality in mice. *Proc Soc Exp Biol Med* 1961; 108:676–80.
330. Plett PA, Sampson CH, Chua HL, Joshi M, Booth C, Gough A, et al. Establishing a murine model of the hematopoietic syndrome of the acute radiation syndrome. *Health Phys* 2012; 103:343–55.
331. Kiang JG, Garrison BR, Smith JT, Fukumoto R. Ciprofloxacin as a potential radio-sensitizer to tumor cells and a radio-protectant for normal cells: differential effects on gamma-H2AX formation, p53 phosphorylation, Bcl-2 production, and cell death. *Mol Cell Biochem* 2014; 393:133–43.
332. Kiang JG, Fukumoto R. Ciprofloxacin increases survival after ionizing irradiation combined injury: gamma-H2AX formation, cytokine/chemokine, and red blood cells. *Health Phys* 2014; 106:720–6.
333. A phase-II trial of fractionated total body radiation in bone marrow transplantation for acute leukemia. UCLA Bone Marrow Transplant Team. *Transplant Proc* 1979; 11:205–7.
334. Fukumoto R. Mesenchymal stem cell therapy for acute radiation syndrome. *Mil Med Res* 2016; 3:17.
335. DiCarlo AL, Tamarat R, Rios CI, Benderitter M, Czarniecki CW, Allio TC, et al. Cellular therapies for treatment of radiation injury: report from a NIH/NIAID and IRSN workshop. *Radiat Res* 2017; 188:e54–75.
336. Xu T, Zhang Y, Chang P, Gong S, Shao L, Dong L. Mesenchymal stem cell-based therapy for radiation-induced lung injury. *Stem Cell Res Ther* 2018; 9:18.
337. Klein D, Steens J, Wiesemann A, Schulz F, Kaschani F, Rock K, et al. Mesenchymal stem cell therapy protects lungs from radiation-induced endothelial cell loss by restoring superoxide dismutase 1 expression. *Antioxid Redox Signal* 2017; 26:563–82.
338. Chrzanowski W, Kim SY, McClements L. Can stem cells beat COVID-19: advancing stem cells and extracellular vesicles toward mainstream medicine for lung injuries associated with SARS-CoV-2 infections. *Front Bioeng Biotechnol* 2020; 8:554.
339. Golchin A, Seyedjafari E, Ardashirylajimi A. Mesenchymal stem cell therapy for COVID-19: present or future. *Stem Cell Rev Rep* 2020; 16:427–33.
340. Sengupta V, Sengupta S, Lazo A, Woods P, Nolan A, Bremer N. Exosomes derived from bone marrow mesenchymal stem cells as treatment for severe COVID-19. *Stem Cells Dev* 2020; 29:747–54.
341. Atluri S, Manchikanti L, Hirsch JA. Expanded umbilical cord mesenchymal stem cells (UC-MSCs) as a therapeutic strategy in managing critically ill COVID-19 patients: the case for compassionate use. *Pain Physician* 2020; 23:E71–83.
342. Rogers CJ, Harman RJ, Bunnell BA, Schreiber MA, Xiang C, Wang FS, et al. Rationale for the clinical use of adipose-derived mesenchymal stem cells for COVID-19 patients. *J Transl Med* 2020; 18:203.
343. Leng Z, Zhu R, Hou W, Feng Y, Yang Y, Han Q, et al. Transplantation of ACE2(–) mesenchymal stem cells improves the outcome of patients with COVID-19 pneumonia. *Aging Dis* 2020; 11:216–28.
344. Calabrese EJ, Dhawan G. How radiotherapy was historically used to treat pneumonia: could it be useful today? *Yale J Biol Med* 2013; 86:555–70.
345. Trott KR, Zschaek S, Beck M. Radiation therapy for COVID-19 pneumopathy. *Radiother Oncol* 2020; 147:210–11.
346. Rodel F, Arenas M, Ott OJ, Fournier C, Georgakilas AG, Tapio S, et al. Low-dose radiation therapy for COVID-19 pneumopathy: what is the evidence? *Strahlenther Onkol* 2020; 196:679–82.
347. Montero A, Arenas M, Algara M. Low-dose radiation therapy: could it be a game-changer for COVID-19? *Clin Transl Oncol* 2020; Epub ahead of print.
348. Kirsch DG, Diehn M, Cucinotta FA, Weichselbaum R. Response letter: Radiation therapy for COVID-19 pneumopathy. *Radiother Oncol* 2020; 149:238–9.
349. Kirkby C, Mackenzie M. Is low dose radiation therapy a potential treatment for COVID-19 pneumonia? *Radiother Oncol* 2020; 147:221.
350. Kefayat A, Ghahremani F. Low dose radiation therapy for COVID-19 pneumonia: A double-edged sword. *Radiother Oncol* 2020; 147:224–5.
351. Lazzari G, Silvano G. RILI model and the Covid-19 pneumonia: The radiation oncologist point of view. *Radiother Oncol* 2020; 147:222–3.
352. Schae D, McBride WH. Flying by the seat of our pants: is low dose radiation therapy for COVID-19 an option? *Int J Radiat Biol* 2020; 96(10):1219–1223.
353. Gupta A, Madhavan MV, Sehgal K, Nair N, Mahajan S, Sehrawat TS, et al. Extrapulmonary manifestations of COVID-19. *Nat Med* 2020; 26:1017–32.