



## **Medical Response to Radiological Accidents in Latin America and International Assistance**

Authors: Reyes, Eduardo Herrera, Baciú, Florian, Benderitter, Marc, Lataillade, Jean Jacques, Bey, Eric, et al.

Source: Radiation Research, 185(4) : 359-365

Published By: Radiation Research Society

URL: <https://doi.org/10.1667/RR14292.1>

---

BioOne Complete ([complete.BioOne.org](https://complete.BioOne.org)) is a full-text database of 200 subscribed and open-access titles in the biological, ecological, and environmental sciences published by nonprofit societies, associations, museums, institutions, and presses.

Your use of this PDF, the BioOne Complete website, and all posted and associated content indicates your acceptance of BioOne's Terms of Use, available at [www.bioone.org/terms-of-use](http://www.bioone.org/terms-of-use).

Usage of BioOne Complete content is strictly limited to personal, educational, and non - commercial use. Commercial inquiries or rights and permissions requests should be directed to the individual publisher as copyright holder.

---

BioOne sees sustainable scholarly publishing as an inherently collaborative enterprise connecting authors, nonprofit publishers, academic institutions, research libraries, and research funders in the common goal of maximizing access to critical research.

## Medical Response to Radiological Accidents in Latin America and International Assistance

Eduardo Herrera Reyes,<sup>a,1</sup> Florian Baciú,<sup>a</sup> Marc Benderitter,<sup>b</sup> Jean Jacques Lataillade,<sup>c</sup> Eric Bey,<sup>d</sup> Francois Tromprier<sup>b</sup> and Radia Tamarat<sup>b</sup>

<sup>a</sup> Incident and Emergency Centre, International Atomic Energy Agency (IAEA), Vienna International Centre, 1400 Vienna, Austria;

<sup>b</sup> Institute of Radioprotection and Nuclear Safety (IRSN), Fontenay-aux-Roses Cedex 92262, France; <sup>c</sup> Research Department and Cell Therapy Unit, Military Blood Transfusion Centre (CTSA), Clamart 92141, France; and <sup>d</sup> Department of Plastic Surgery, Military Hospital of Percy, Clamart Cedex 92141, France

---

**Herrera Reyes, E., Baciú, F., Benderitter, M., Lataillade, J. J., Bey, E., Tromprier, F. and Tamarat, R. Medical Response to Radiological Accidents in Latin America and International Assistance. *Radiat. Res.* **185**, 359–365 (2016).**

**This article provides an overview of four radiological accidents in Latin America, and includes a history of the events, the clinical manifestations and health consequences for the exposed individuals, the medical response based on preclinical studies and the role of the International Atomic Energy Agency (IAEA) in coordinating medical response assistance.** © 2016 by Radiation Research Society

---

### NUCLEAR AND RADIOLOGICAL EMERGENCIES

An emergency is a nonroutine situation that necessitates prompt action, primarily to mitigate a hazard or limit the adverse consequences for human health and safety, quality of life, property and the environment. It includes situations for which prompt action is warranted to mitigate the effects of a perceived hazard. A nuclear or radiological emergency involves hazards due to radiation exposure or due to the energy resulting from a nuclear chain reaction or from the decay of the products of a chain reaction (1).

From 1945 to 2005, there were 565 significant nuclear or radiological emergencies reported worldwide, in which 3,000 individuals were exposed and 169 fatalities occurred (2, 3). From 2000 to 2010, 130 individuals were exposed and 14 fatalities occurred in North America, South America, Africa, Asia and Europe. In Latin America alone, there were 46 radiological accidents from 1962 to 2014, primarily associated with industrial activities (35%), irradiators (27%) and clinical sources (12%) (3). Since 1980, the number of

reported overexposures in the medical sector has increased (4).

The low frequency of radiological accidents, the paucity of information available on the subject to students at medical schools and the nonspecific clinical manifestations, especially at earlier stages, are some of the common factors that contribute to the late identification and delayed diagnosis of affected individuals in nuclear or radiological emergencies (5). Some of the typical clinical manifestations are listed in Table 1 (6).

This review provides an overview of some of the medical experiences and lessons learned from radiological accidents that occurred in Latin America.

### THE RADIOLOGICAL ACCIDENT IN YANANGO

On February 20, 1999, a radiological accident occurred in Yanango, Peru. A worker on a hydroelectric construction site picked up, with his right hand, an unshielded radioactive sealed source of iridium-192 (<sup>192</sup>Ir) used for industrial radiography. At the time of the accident, the activity of the source was 1.37 TBq. The worker then kept the radioactive source in the right back pocket of his trousers for at least 3 h (7).

The preliminary dose assessment concluded a high-absorbed dose to the right inferior limb and other organs. This included: “skin at 1 cm of contact to the radioactive source (9,966 Gy); soft tissues among 2–7 cm of contact (from 2,508 to 191 Gy), femur (143 Gy); femoral artery (143 Gy); gonads (23 Gy); bladder and rectum (18 Gy)”.

This accident resulted in severe health consequences for the patient during the following months. He developed necrosis of tissues including skin, subcutaneous tissues, muscles, blood vessels, proximal epiphysis and diaphysis of the right femur, exposure of sciatic nerve and severe lesions in gonads and rectum (Fig. 1). The therapeutic strategy applied at that time consisted of medical interventions after the appearance of clinical manifestations. In this case,

<sup>1</sup> Address for correspondence: Incident and Emergency Centre, International Atomic Energy Agency (IAEA), Vienna International Centre, P.O. Box 100, 1400 Vienna, Austria; email: E.D.Herrera-Reyes@iaea.org.

**TABLE 1**  
**Radiation-Induced Clinical Manifestations**

Abdominal cramps or pain	Diarrhea	Headache	Onycholysis
Anorexia	Erythema	Hypotension	Sensation or itching
Blistering	Fatigue syndrome	Infection	Swelling and edema
Blood loss	Fever	Lymphocyte changes	Thrombocyte changes
Cognitive deficit	Granulocyte changes	Nausea	Ulcers/necrosis
Desquamation	Hair loss	Neurological deficit	Vomiting

several surgeries were performed to remove the necrotic tissues (7).

Approximately one month after the accident, the Peruvian authorities requested the provision of specialized medical assistance from the IAEA by invoking the Convention on Assistance in the Case of a Nuclear Accident or Radiological Emergency (Convention on Assistance) (8). An IAEA Assistance Mission under the terms of the Convention on Assistance was deployed to Lima, Peru. The objectives of the mission were to: examine and evaluate the patient's condition; review the methodology of the dosimetry calculations and evaluation; determine the results of the patient's examination with respect to the estimated doses; discuss whether surgery was required and, if so, what type; review the expected course of treatment for the patient as well as issues related to future medical care; review the possible causes of the accident; and provide further recommendations (7).

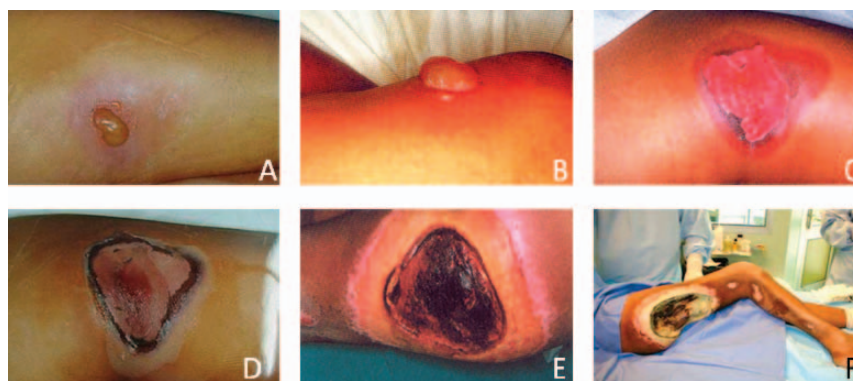
Due to the severity of the patient's condition, he was transferred to the Percy Military Hospital (HIA Percy, Clamart Cedex, France) on day 100 after the accident based on the conclusions of the Assistance Mission. On post-accident day 171, given the critical condition of the patient, the extensive necrosis in the right limb, intense pain, multiple infections and ankyloses of the right hip and knee, the decision was made to perform a radical surgical procedure, which consisted of a wide exeresis of the internal rectus and the major and minor gluteus, followed by a disarticulation of the right hip. Afterwards, the patient

completed treatment in Peru due to the evolution of his medical condition (Fig. 2).

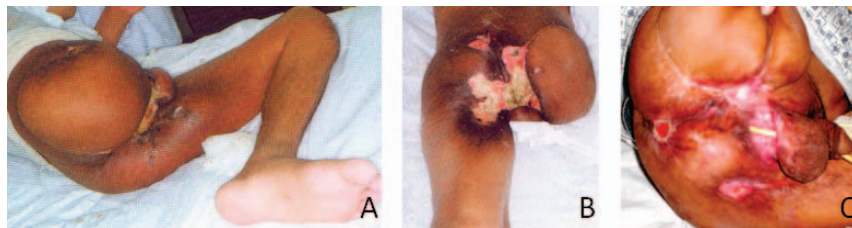
The clinical evolution of the patient and the health consequences after the accident prompted the need for stronger consideration of preclinical and clinical studies for the development of new therapeutic approaches. Some of these approaches were developed by the Institute of Radioprotection and Nuclear Safety (IRSN, Fontenay-aux-Roses Cedex, France) in collaboration with HIA Percy, and involved the design of an innovative therapeutic protocol using early surgery guided by local dose assessment, combined with the administration of mesenchymal stem cell (MSC) therapy (9, 10).

#### DEVELOPMENT OF PRECLINICAL STUDIES AFTER THE YANANGO ACCIDENT

At the end of the 1990s, after the radiological accident in Yanango, scientists began exploring the possible use of MSCs taken from bone marrow to treat radiation-induced skin lesions. Adult stem cells are responsible for the maintenance and homeostasis of their tissue or organ of origin throughout life. They share a number of properties, including self renewal, multipotent yet lineage-restricted differentiation and extensive paracrine activity. Therefore, the therapeutic use of stem cells presents interesting possibilities for promoting tissue regeneration after radiation-induced injury. Hematopoietic stem cells harvested from bone marrow have been used for decades to



**FIG. 1.** Yanango accident, 1999 (3), evolution of the patient. In the upper row: day 3 after the accident, blistering lesion surrounded with large inflammatory halo on the mid-upper line of the rear surface of the right thigh (panel A); day 4, blister size 4 cm × 1.5 cm × 1 cm (panel B); day 9, extended ulcer surrounded by a large dusky inflammatory area in the rear surface of the right thigh (panel C). In the lower row, panel D: day 23. Panel E: day 72, very large necrotic lesion extended in the upper third of the right thigh. The depth of the defect was significant. The bottom was covered by a crust and infected. Panel F: day 101, extended necrosis and loss of tissues at the right limb (photo courtesy of the IRSN-HIA Percy).



**FIG. 2.** Yanango accident, 1999 (3). Panels A and B: Photographs taken 240 days after surgery. Panel C: Photograph taken 13 years after the accident, medical follow-up in 2012. (photo credits: Dr. Oscar Barriga) (3).

reconstitute hematopoietic system and immune function in patients. Similarly, MSCs constitute a promising tool for cell therapies, because they are easily accessible and isolated from various sources, e.g., bone marrow, fat and umbilical cord, they show robust *in vitro* expansion to clinical scale and they allow cryopreservation with minimal loss of stem cell characteristics (11). MSCs have been evaluated for regenerative medicine applications, either through direct differentiation into cartilage, bone and fat, or indirectly through protein or cytokine secretion and immune suppression. Building on the good clinical safety record established by several studies of systemic MSC transplantation, preclinical studies demonstrated the beneficial effect of human MSCs (hMSCs) on the healing of radiation-induced musculocutaneous lesions in a mouse model (12). The preclinical data have not only shown that the transplanted hMSCs were found in the injured area but also that the pathophysiological consequences of radiation exposure were reduced (12). The severity of the skin lesions was limited, and the healing process was hastened in hMSC-treated animals compared to controls. The observed positive effects of hMSC therapy on skin repair were mainly due to their paracrine effect. Similarly, recent studies demonstrated the beneficial role of bone marrow administration in remodeling processes and the repair of radiation-induced vascular damage in the acute and late phases. It was shown that bone marrow injection in irradiated skin lesions does not heighten the inflammatory response to radiation represented by the endothelial activation visualized by videomicroscopy (Fig. 3). Finally, the preclinical results allowed the translation of basic knowledge on MSC biology into the design of clinical therapies, supporting the treatment of local radiation-induced injuries. At the preclinical stage, a new therapeutic strategy had been proven effective: the

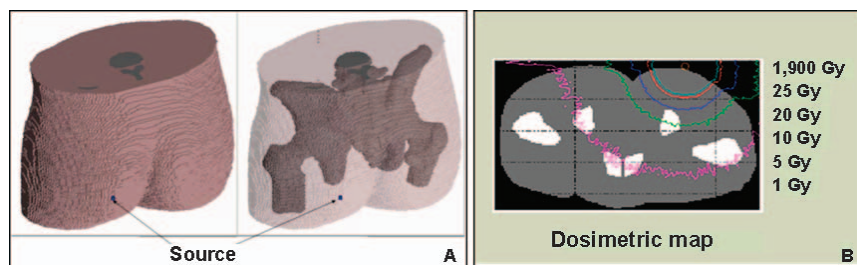
combination of surgery at the early postirradiation stage, guided by dose assessment and the injection of MSCs.

### THE RADIOLOGICAL ACCIDENT IN NUEVA ALDEA AND THE TREATMENT APPLICATION BASED ON PRECLINICAL STUDY RESULTS

A radiological accident occurred on December 15, 2005 at a cellulose plant in Nueva Aldea, Chile. A scaffolding worker found a sealed radioactive  $^{192}\text{Ir}$  source from an industrial radiography procedure performed the previous day. The worker held the source in his hands for several minutes and thereafter kept it in his left back trouser pocket. Two coworkers were also exposed. The activity of the source was 3.33 TBq at the time of the accident (13, 14). The local and whole-body absorbed dose estimates are shown in Table 2 (13). The medical evaluation of the patient concluded that whole-body and severe local exposure of the left lower limb had occurred. The clinical manifestations, comprised of erythema, edema, blisters, moist epidermidis and ulceration, were observed in the irradiated area. The skin lesions were accompanied by intense pain, which was only partially alleviated by morphine. The clinical manifestations were similar to those of the patient from Yanango.

On Sunday, December 18, 2005, the IAEA's Incident and Emergency Centre (IEC) received a request for assistance from the Chilean authorities under the Convention on Assistance (8). On the same day, an IAEA Assistance Mission was sent to Santiago, Chile, arriving on Monday December 19, 2005.

The objectives of the IAEA Assistance Mission, conducted from December 19–21, 2005, were to assist the



**FIG. 3.** Nueva Aldea accident, 2005. Panel A: The 3D view of the voxel phantom (external envelope and skeleton) and of the source using SABRINA software. Panel B: Dose distribution on the skin surface and in the underlying tissues of the buttock obtained using the personalized voxel phantom (illustration courtesy of the IRSN) (3).

**TABLE 2**  
**Preliminary Dose Estimates for the Worker in Nueva Aldea Accident**

Basis of estimate	Whole-body dose (Gy)	Local dose to left buttock (Gy) <sup>a</sup>
Clinical manifestation	1–2	-
Chromosome aberrations	1.3	-
Physical dose reconstruction	1.3–1.5	1,600

<sup>a</sup> Dose at the surface with a steep decrease with depth.

Chilean authorities in the following: 1. Ensuring that the radiation source involved in the accident was in a safe and secure condition; 2. Evaluating the doses incurred by the affected patients by, among other things, analyzing the history of exposure and the medical status of the patients; 3. Evaluating the treatment given to the affected workers; 4. Performing a medical prognosis and advising on necessary further treatment; and 5. Identifying issues for which the IAEA could coordinate assistance to minimize the consequences of the accident (13).

On day 15 after the accident, following the request from the Chilean authorities and in line with the recommendation of the IAEA Assistance Mission, the IEC coordinated the transfer of the patient to HIA Percy in France.

Autologous total bone marrow cells were obtained from the unexposed iliac crest. Based on the dose reconstruction mapping, a wide surgical resection, including a proportion of healthy tissues, was performed on the buttock on day 21 after the accident. All tissues exposed to a dose over 20 Gy situated between the center of the lesion and the 20 Gy isodose line were excised and then covered with a cryopreserved allograft (15). Two local MSC administrations were performed to accelerate the rate of wound healing (Fig. 4).

The first skin lesions appeared on the fingers of the left hand rapidly after the accident (Fig. 5). It was decided that a combined treatment of skin grafting and autologous MSC injections would be applied.

No adverse reactions to the autologous MSC administration (buttock and hand) were observed. Remarkably, the day after the first MSC injections, pain disappeared and the active clinical evolution of the lesion was halted. The size of the wound progressively decreased, following a centripetal process of healing. The patient returned to Chile on day 141 after the accident, with 98% of the buttock lesion covered.

Important factors in the Nueva Aldea accident were the early recognition of the event and a clear description of the circumstances. These consequently facilitated an early

diagnosis of those workers involved and the ability to treat them with the new therapeutic approach, which consisted of surgery guided by dosimetry (in tissues), performed early after exposure and the use of MSCs for the first time (Fig. 6) (13).

During medical follow-up of the patient, months after the accident, lesions appeared on the fourth and fifth fingers of his left hand, as well as osteoradionecrosis of the last phalanx of the left thumb. In 2013, a medical evaluation determined that the patient was in a good condition and presented normal function of the lower limb, with no restrictions in common activities.

#### OTHER RADIOLOGICAL ACCIDENTS IN THE REGION AND INTERNATIONAL ASSISTANCE IN THE COORDINATION OF MEDICAL RESPONSE

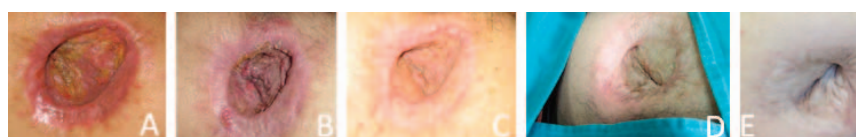In 2012 and 2014, two radiological accidents occurred in Peru, which resulted from the inadequate manipulation of radioactive sources and the lack of safety procedures during nondestructive tests in industrial radiography. The exposed individuals incurred severe health consequences.

On January 9, 2012, the IEC received information concerning an overexposure from a radioactive source used in industrial radiography. After the IAEA's offer of aid on January 20, 2012, the IEC received a request for assistance from the Peruvian authorities for medical advice and further medical follow-up. A second request for assistance was received on February, 1, 2012 for specialized medical support for the individual most severely exposed in the accident.

An assistance action plan was organized by the IEC, and an IAEA Assistance Mission to Peru was conducted with the following objectives: 1. Assess the medical condition of those most exposed; 2. Assess the radiological impact in terms of local and whole-body doses of the most exposed persons; 3. Provide medical advice and medical treatment to those individuals; 4. Provide support in dose reconstruction based on the most probable scenario of exposure; and 5. Recommend further actions.

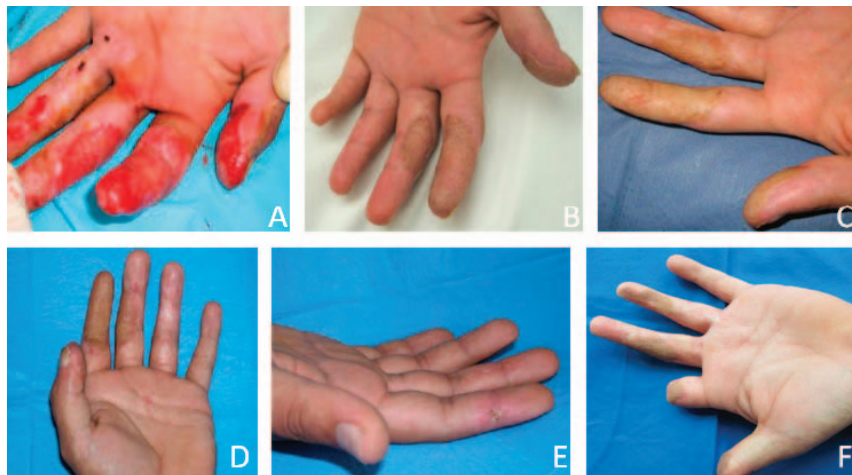
The medical treatment was successfully coordinated by the IAEA with the French authorities and delivered by French physicians at the HIA Percy in cooperation with the IRSN.

In May 2013, the IEC received a third request for assistance from the Peruvian authorities for medical



**FIG. 4.** Nueva Aldea accident 2005–2013. Clinical evolution of the necrotic buttock after MSC therapy. Day 109 (panel A), day 162 (panel B) and day 204 (panel C) after the accident (photos courtesy of HIA Percy, Military Blood Transfusion Centre and IRSN). July 2008 (panel D) and September 2013 (panel E) (photo credit: Dr. Eduardo Herrera Reyes).





**FIG. 5.** Nueva Aldea accident 2005–2013, clinical evolution of the left hand of the worker. Panels A–C: Before the treatment, January 2006 (panel A); after MSC treatment (panels B and C) in 2006. Panels D–F: Medical follow-up, October 2008 (panels D and E) and September 2013 (panel F).

treatment of the same patient. The patient had developed recurrences of cutaneous radiation syndrome on his hands.

The treatment in 2013 was successfully performed for the first time in Latin America and coordinated by an IAEA Assistance Mission, with the participation of French medical experts from the IRSN and HIA Percy, IEC staff and Chilean physicians in Santiago.

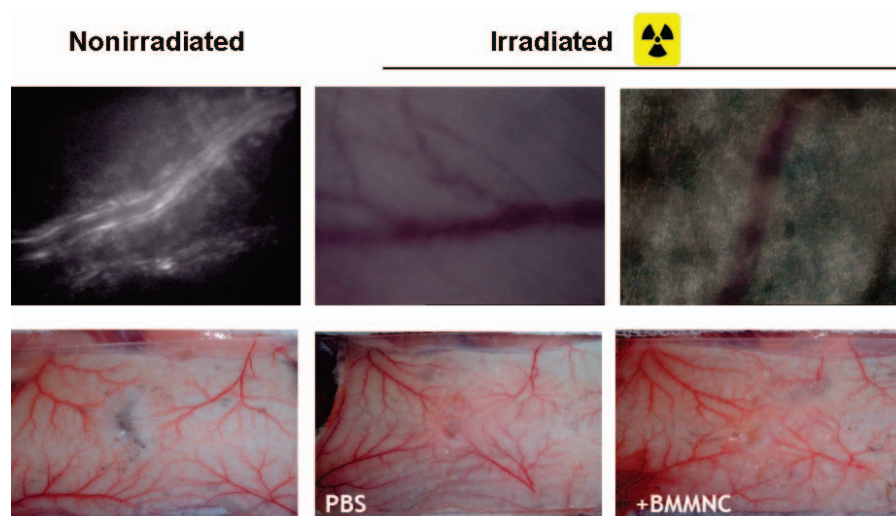
Another industrial radiography accident occurred in Peru in 2014. The medical response was coordinated by the IEC, which organized an IAEA Assistance Mission to Peru and, at a later stage, to Brazil. The medical treatment was performed in Brazil by Brazilian physicians with assistance from French experts. A physical dosimetry reconstruction was performed by the IRSN in France. And a biodosimetry analysis was performed by the Autoridad Regulatoria Nuclear (ARN) in Argentina. This was the second time that this protocol had been successfully applied in Latin America. Over 30

professionals from nine institutions in four countries were coordinated by the IAEA to provide the medical response to this patient. Currently, both patients (from the 2012 and the 2014 cases) are under medical follow-up in Peru.

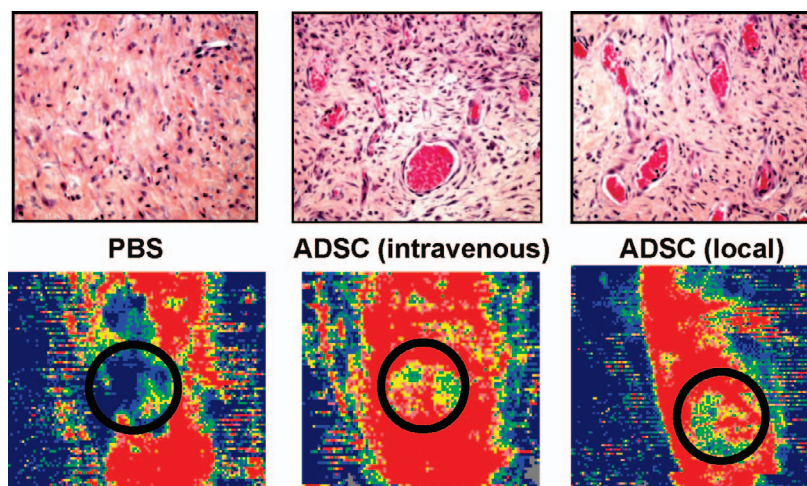
#### THE ROLE OF THE IAEA IN NUCLEAR OR RADIOLOGICAL EMERGENCIES

The IEC acts as the global hub for preparedness and response in the event of emergencies related to nuclear and radiological safety or security, as well as threats or events that are of interest to the media, by coordinating the international emergency preparedness and response assistance (3).

The IAEA assumes its role in emergency preparedness and response to nuclear or radiological emergencies in accordance with the Convention on Early Notification of a



**FIG. 6.** Representative images of intravital videomicroscopy of leukocyte-endothelium interactions in the dorsal skin vessels under the punch 60 days after bone marrow administration.



**FIG. 7.** Representative photomicrographs of vascular density in irradiated tissue measured by H&E staining and skin perfusion evaluated by imaging laser Doppler in mice treated with or without intravenous or local ADSCs 7 days postirradiation.

Nuclear Accident (16) and the Convention on Assistance (8), as well as the IAEA's Statute (17), its safety standards, relevant decisions of the policy-making organizations, interagency agreements and best international practices.

As part of the IAEA's strategy for supporting the practical implementation of the Convention on Assistance, the IEC manages the IAEA Response and Assistance Network (RANET). RANET is intended to strengthen the worldwide capability to provide assistance and advice and/or to coordinate the provision of assistance as specified within the framework of the Convention on Assistance, in the event of nuclear accidents and radiological emergencies, or in case of other nuclear or radiological incidents (18).

There are a few medical centers in the world with sufficient experience to provide treatment to individuals with radiation-induced injuries. Some of these centers are part of RANET and have been involved in the provision of assistance in response to past radiological accidents.

#### FUTURE PERSPECTIVES OF MSC THERAPY AND PRECLINICAL STUDIES

During the past two decades, the IRSN and the Burn Treatment Centre of HIA Percy have demonstrated the clinical benefit of MSC therapy in the treatment of more than ten patients with local radiation-induced injuries from overexposure in radiological accidents (9, 10). All of these clinical applications were supported by basic research performed in different preclinical studies using rodents and mini pigs.

Several strategies to improve the therapeutic potential of cell therapies in local radiation-induced injuries are under consideration. These include preclinical studies using endothelial cell progenitors (EPCs) on mice that have shown to accelerate the wound healing process in irradiated conditions by stimulating angiogenesis and restoring skin quality. In addition, to circumvent the problems of insufficient cell

number and low efficiency of incorporation, two distinct strategies have been proposed: 1. The use of EPCs activated by ephrine-B2 and -B4 to increase their numbers at the site of lesion; and 2. The co-administration of EPCs and smooth-muscle progenitor cells to promote the formation of mature, more functional vessels as treatment for radiation-induced skin injury (19). Experimental data have demonstrated that using a combined strategy is more efficient than a single approach. Unfortunately, these new approaches have limitations, such as the need for significant volumes of blood (about 20 liters) to obtain a clinical dose of cellular therapy product.

Recently, the plasticity of adipose-derived stem cells (ADSCs) has raised new hopes in the field of regenerative medicine. Moreover, the clinical application of adipocyte cells in delayed wound healing may offer a new therapeutic approach due to their mode of isolation by liposuction (a less invasive technique than bone marrow aspiration) and larger quantities of starting material. The beneficial effects of ADSCs may be the result of several cellular mechanisms: ADSC differentiation toward keratinocyte, cell fusion, paracrine effects and pro-angiogenic potential (20). Interestingly, it has also been shown that GFP-ADSCs incorporated into vessels, and differentiated into CD31-expressing endothelial cells, lead to increased blood perfusion and vessel density (Fig. 7). These findings confirm the potential value of ADSCs for further use in the treatment of radiation-induced cutaneous lesions.

Future developments in stem cell therapy applications to treat radiological skin lesions will include exosomes, which are secreted by a variety of cell types including MSCs, and are involved in cell-to-cell communication through the release of their proteins and nucleic acid to target cells. Exosomes have been identified as the main active component of the paracrine arsenal released by stem cells, and it has been shown that they could substitute for, and recapitulate, the beneficial effects of their producing cells. Such exosome therapeutics hold new promise in regener-

ative medicine, notably by alleviating a number of safety concerns and limitations associated with the transplantation of viable replicating stem cells. Accordingly, preliminary results from a collaborative preclinical study indicate that injection of hMSC-derived exosomes results in a similarly beneficial effect as MSC injection in a radiological skin injury mouse model.<sup>2</sup>

On the basis of clinical observations during patient follow-up, a new strategy for optimizing treatment will consist of targeting the injured tissue by using tissue-specific stem cells (e.g., muscle and bone).

All of these important preclinical studies need further confirmation in larger animal experiments before clinical trials can be conducted, to validate their therapeutic benefits. Whatever the type of cell used, several technical and practical challenges must be overcome to achieve the ideal conditions for a cell therapy that is both effective in the long term and easily applicable. The successful transplantation of stem cells and subsequent reduction in radiation-induced complications has paved the way for further development of completely new strategies in treating local radiation-induced injuries.

### CONCLUSION

Individuals involved in radiological accidents have suffered severe health consequences from exposure. In the past 15 years, significant progress in the treatment of patients with local radiation-induced injuries has been made. The introduction of new techniques, as applied by the IRSN and HIA Percy Burn Treatment Centre, which are based on preclinical studies and a multidisciplinary medical approach, has improved the prognosis and quality of life for these patients.

The effective coordination of international assistance by the IAEA in the medical response to radiological emergencies, and the continued efforts to improve the sharing of knowledge among medical professionals in different countries, have been fundamental in the treatment of patients with local radiation-induced injuries.

### ACKNOWLEDGMENTS

The information contained in this article was presented at CONTREC (Conference on Normal Tissue Radiation Effects and Countermeasures), May 6–9, 2015, at Winthrop Rockefeller Institute in Morrilton, Arkansas. Our thanks go to all of the organizers for this conference and especially to Professor Martin Hauer-Jensen.

Received: October 19, 2015; accepted: November 16, 2015; published online: March 28, 2016

### REFERENCES

1. Safety glossary: terminology used in nuclear safety and radiation protection. Vienna: International Atomic Energy Agency; 2007.

2. Berger ME, Christensen DM, Lowry PC, Jones OW, Wiley AL. Medical management of radiation injuries. *Occupational Med* 2006; 56:162–72.
3. Medical preparedness and response for a nuclear or radiological emergency. Training materials. Vienna: International Atomic Energy Agency; 2014. ([bit.ly/1WSIZ7t](http://bit.ly/1WSIZ7t))
4. Coeytaux K, Bey E, Christensen D, Glassman ES, Murdock B, Doucet C. Reported radiation overexposure accidents worldwide, 1980–2013: A systematic review. *PLoS One* 2015; 10:e0118709.
5. Lessons learned from the response to radiation emergencies (1945–2010). Vienna: International Atomic Energy Agency; 2012. ([bit.ly/1RARy4g](http://bit.ly/1RARy4g))
6. Medical management of radiation accidents: manual of the acute radiation syndrome (Flidner TM, Friesecke I, Beyrer K. eds.). London: The British Institute of Radiology; 2001. ([bit.ly/1oaMnP3](http://bit.ly/1oaMnP3))
7. The radiological accident in Yanango. Vienna: International Atomic Energy Agency; 2000. (<http://bit.ly/20VzCns>)
8. Convention on assistance in the case of a nuclear accident or radiological emergency. Information Circular INFCIRC/336. Vienna: International Atomic Energy Agency; 1986. ([bit.ly/1oJpS3F](http://bit.ly/1oJpS3F))
9. Bey E, Prat M, Duhamel P, Benderitter M, Brachet M, Tromprier F, et al. Emerging therapy for improving wound repair of severe radiation burns using local bone marrow-derived stem cell administrations. *Wound Repair Regen* 2010; 18:50–8.
10. Benderitter M, Gourmelon P, Bey E, Chapel A, Clairand I, Prat M, et al. New emerging concepts in the medical management of local radiation injury. *Health Phys* 2010; 98:851–7.
11. Tamarat R, Lataillade JJ, Bey E, Gourmelon P, Benderitter M. Stem cell therapy: from bench to bedside. *Radiat Prot Dosimetry* 2012; 151:633–9.
12. François S, Mouiseddine M, Mathieu N, Semont A, Monti P, Dudoignon N, et al. Human mesenchymal stem cells favour healing of the cutaneous radiation syndrome in a xenogenic transplant model. *Ann Hematol* 2007; 86:1–8.
13. The radiological accident in Nueva Aldea. Vienna: International Atomic Energy Agency; 2005. ([bit.ly/1Rg5cXW](http://bit.ly/1Rg5cXW))
14. Nuclear safety review for the year 2005. GC(50)/INF/2. Vienna: International Atomic Energy Agency; 2005. ([bit.ly/1ncADdN](http://bit.ly/1ncADdN))
15. Lataillade JJ, Doucet C, Bey E, Carsin H, Huet C, Clairand I, et al. New approach to radiation burn treatment by dosimetry-guided surgery combined with autologous mesenchymal stem cell therapy. *Regen Med* 2007; 2:785–94.
16. Convention on Early notification of a nuclear accident. IAEA Information Circular INFCIRC/335. Vienna: International Atomic Energy Agency; 1986. ([bit.ly/1LqXMEE](http://bit.ly/1LqXMEE))
17. The Statute of the IAEA. As amended up to 23 February 1989. Vienna: International Atomic Energy Agency; 1989.
18. IAEA Response and assistance network. IAEA EPR-RANET 2013. Vienna: International Atomic Energy Agency; 2013. ([bit.ly/1XVRyyC](http://bit.ly/1XVRyyC))
19. Foubert P, Squiban C, Holler V, Buard V, Dean C, Levy BI, et al. Strategies to enhance the efficiency of endothelial progenitor cell therapy by ephrin B2 pretreatment and coadministration with smooth muscle progenitor cells on vascular function during the wound-healing process in irradiated or nonirradiated condition. *Cell Transplant* 2015; 24:1343–61.
20. Ebrahimian TG, Pouzoulet F, Squiban C, Buard V, André M, Cousin B, et al. Cell therapy based on adipose tissue-derived stromal cells promotes physiological and pathological wound healing. *Arterioscler Thromb Vasc Biol* 2009; 29:503–10.

<sup>2</sup> Unpublished results.