

## **SUBCUTANEOUS MYCOTIC INFECTION OF A WHITE-TAILED DEER 1**

Author: SALKIN, IRA F.

Source: Journal of Wildlife Diseases, 10(1) : 34-38

Published By: Wildlife Disease Association

URL: <https://doi.org/10.7589/0090-3558-10.1.34>

---

BioOne Complete ([complete.BioOne.org](https://complete.BioOne.org)) is a full-text database of 200 subscribed and open-access titles in the biological, ecological, and environmental sciences published by nonprofit societies, associations, museums, institutions, and presses.

Your use of this PDF, the BioOne Complete website, and all posted and associated content indicates your acceptance of BioOne's Terms of Use, available at [www.bioone.org/terms-of-use](https://www.bioone.org/terms-of-use).

Usage of BioOne Complete content is strictly limited to personal, educational, and non - commercial use. Commercial inquiries or rights and permissions requests should be directed to the individual publisher as copyright holder.

---

BioOne sees sustainable scholarly publishing as an inherently collaborative enterprise connecting authors, nonprofit publishers, academic institutions, research libraries, and research funders in the common goal of maximizing access to critical research.

## SUBCUTANEOUS MYCOTIC INFECTION OF A WHITE-TAILED DEER<sup>□</sup>

IRA F. SALKIN, Division of Laboratories and Research, New York State Department of Health, Albany, New York 12201, U.S.A.

WARD B. STONE, Division of Fish and Wildlife, New York State Department of Environmental Conservation, Delmar, New York 12201, U.S.A.

**Abstract:** Microscopic examination of scales from lesions on the ear of a white-tailed deer (*Odocoileus virginianus*) revealed the presence of fungal structures, gross appearance of which was consistent with the morphology of a dematiaceous mold. Nutrient agar cultures inoculated with such scales yielded *Alternaria alternata*. No other fungus was seen or isolated. Hyphalike elements were also noted in thin sections of the connective tissue of the ear. These data indicate a subcutaneous infection initiated by *Alternaria*.

### INTRODUCTION

The saprophytic mold *Alternaria* has occasionally been reported associated with skin diseases in animals. Hörter<sup>4</sup> observed the mycelia and macroconidia of *Alternaria* in scales from eczematous lesions on five piglets. Král and Schwartzman<sup>6</sup> isolated *Alternaria* from lesions of cocker and springer spaniels affected with a localized form of seborrhea. The present report documents the isolation of *Alternaria alternata* from a subcutaneous infection in the ear of a white-tailed deer (*Odocoileus virginianus*).

### CASE REPORT

#### History

A 2.5-year-old male white-tailed deer was shot by a hunter in Cayuga County, New York, in November, 1972. Noting that the animal was unusually emaciated, the hunter requested an examination by a state wildlife technician. The technician, observing scales and hair loss on the ears, submitted the animal for fur-

ther study to the Wildlife Pathology Section of the New York State Department of Environmental Conservation.

#### Gross Examination

The buck was large-framed (53.6 Kg dressed weight), with heavy scaling on the ears and alopecia. The lateral portion of the right maxilla, associated teeth, and a large section of the palatine process had been shot away the previous year. The wound had created an opening through the hard palate into the nasal cavity, the right side of which was packed with rotting vegetation. Fragments of lead were recovered from the healed fractured maxilla and the right bulla tympanica. Since the deer had been field-dressed, gross studies of the internal organs could not be made.

#### Histopathology

Epidermal hypertrophy as well as congestion and lymphocytic infiltration in the underlying dermis was observed in hematoxylin-and-eosin-stained sections of

□ This study was supported in part by a contribution of federal aid in Fish and Wildlife Restoration to the junior author, Project W-35-R, Job IV-1.

the scaled lesions on the ears. Hyphalike elements were observed within the stratum corneum. A detailed examination of methenamine-silver-stained sections revealed fungoid structures throughout the connective tissue of the ear (Fig. 1). As a result of these findings a portion of an ear was submitted to the Laboratories for Mycology of the New York State Department of Health for further analysis.

#### Mycological Studies

Microscopic examination of epidermal scales aseptically scraped from the ear revealed septated, branched hyphae (Fig. 2) and germinating conidia (Fig. 3) consistent with the gross morphology of a dematiaceous mold. Additional scrapings were inoculated on Mycosel medium and Sabouraud dextrose agar fortified with penicillin and streptomycin (SDA+). The fungal colonies which developed in all SDA+ cultures and half of the Mycosel cultures were identified

as *Alternaria alternata*. No growth was found on the remaining Mycosel medium.

#### Experimental Inoculation

Two healthy yearling white-tailed deer obtained from the experimental farm of the Department of Health were immobilized with the muscle relaxant succinylcholine chloride. An area of 3 cm<sup>2</sup> on the inner surface of one ear of each animal was scraped with a blunt scalpel to remove adhering debris, washed twice with 70% ethyl alcohol, and lightly scarified with a scalpel. A portion of one of the *Alternaria* cultures obtained from the original scaled lesions was then applied to the scarified area. Two weeks after scarification, heavy scaling was observed in the treated ear of one yearling. Microscopic examination of scales removed from both the inoculation point and an area approximately 5 cm from the site revealed dematiaceous

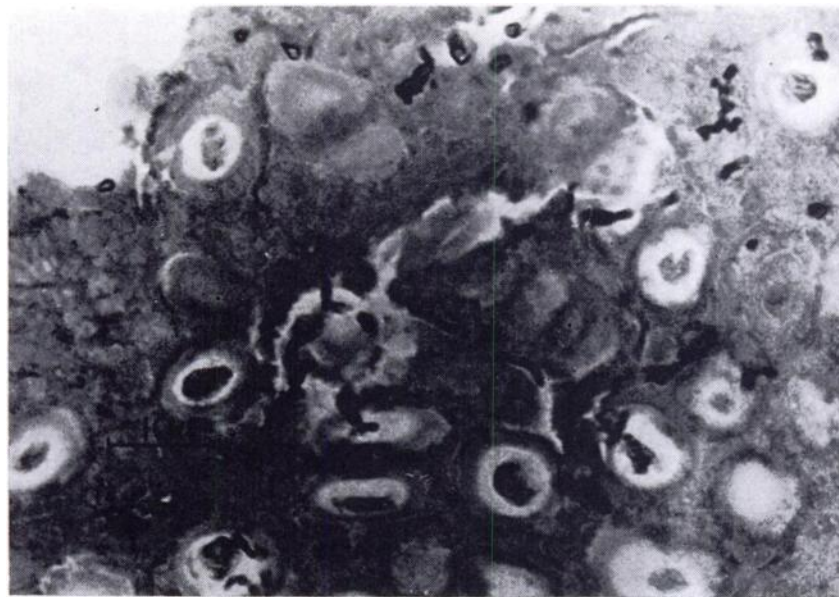


FIGURE 1. Numerous hyphalike elements penetrating the connective tissue of the ear. Gomori's methenamine-silver stain.

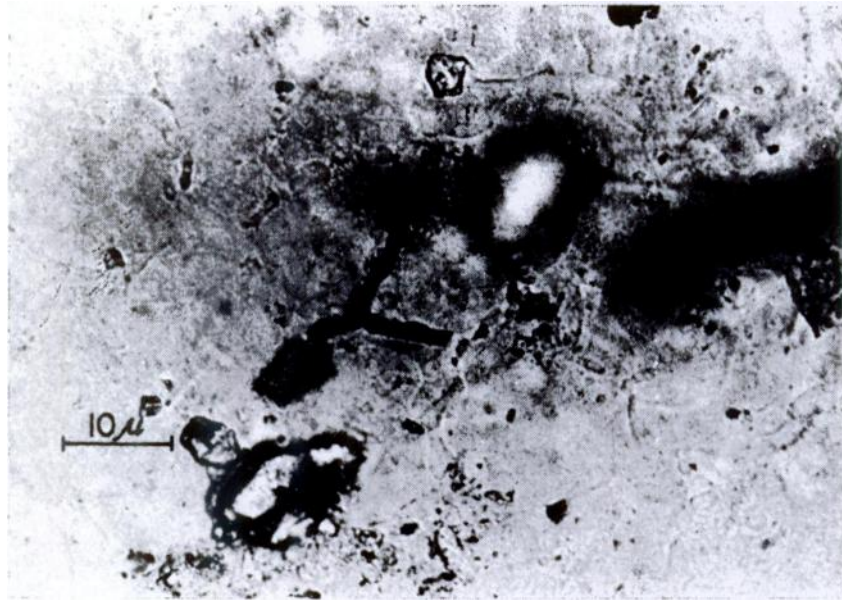


FIGURE 2. Branched hyphal filaments on epidermal scales as observed on direct mount in 10% KOH.

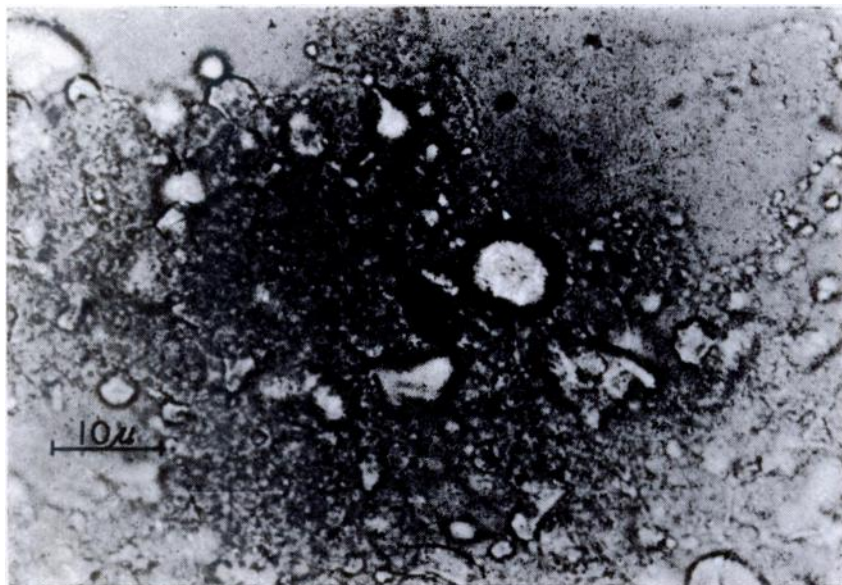


FIGURE 3. Germinating conidium on epidermal scales as observed on direct mount in 10% KOH.

hyphae. SDA+ cultures inoculated with this material yielded *A. alternata*. Four weeks after scarification, scaling was still evident; dematiaceous hyphae were again observed in the scales, and *A. alternata* was isolated in SDA+ cultures. However, no fungal structures were revealed by microscopic examination of methenamine-silver-stained sections of tissue removed from the inoculation site 4 weeks after scarification. No scaling or other physical changes were observed with the second yearling.

#### DISCUSSION

Three aspects of the data presented in this report indicate an *Alternaria* infection: (1) The characteristics of the fungal elements seen on direct mount were compatible with *Alternaria*. (2) Cultures of the scales yielded *Alternaria*, which on microscopic examination proved to be *A. alternata*. (3) No other fungus was observed or isolated. Further, sections of the ear revealed that a fungus had penetrated and developed through the keratinized epidermis into the connective tissue.

*Alternaria* has been shown to be an important causal factor in such allergic responses of man as atopic dermatitis,<sup>8</sup> asthma,<sup>9</sup> and pneumonitis.<sup>10</sup> In addition, as an opportunistic agent it has been found in several cases of keratomycosis.<sup>7</sup> Previous animal studies (noted above) have shown a relationship between *Alternaria* and superficial skin diseases. The

present report apparently constitutes the first instance in which *Alternaria* has been implicated as a causative agent in a subcutaneous infection in either man or animals.

It is widely assumed that mycotic infections caused by normally saprophytic molds such as *Alternaria* represent opportunistic invasions. These infections are usually precipitated by the debilitation of the host through prolonged antibiotic therapy,<sup>2</sup> trauma,<sup>1</sup> diabetes mellitus,<sup>6</sup> or other factors.<sup>5</sup> In the present case, the severe wound inflicted during the previous hunting season probably contributed to the animal's debilitated condition, directly through massive damage to the maxilla and palatine structures and/or indirectly in creating feeding difficulties. With the deer in a weakened state, spores from saprophytic fungi developing on the rotting vegetation in the nasal cavity could have initiated an opportunistic infection.

The experimental inoculation of the two yearlings provided ambiguous results. The heavy scaling on the ear of one yearling and the presence of hyphae within those scales would indicate a mycotic infection. However, no fungal structures were observed in thin sections prepared from tissue removed from the inoculation site. While no definite conclusion can be drawn from such results as to the pathogenicity of this *Alternaria* isolate, they suggest that the fungus is not usually zoopathogenic but rather represents an opportunistic invader of a compromised host.

#### LITERATURE CITED

- BRIDGES, C. H. and C. W. EMMONS. 1961. A phycomycosis of horses caused by *Hyphomyces destruens*. J. Amer. Vet. Med. Assoc. 138: 579-589.
- HESSLER, J. R., J. C. WOODARD, R. J. BEATTIE and A. F. MORELAND. 1967. Mucormycosis in a Rhesus monkey. J. Amer. Vet. Med. Assoc. 151: 909-913.
- HOPKINS, J. G., R. W. BENHAM and B. M. KESTEN. 1930. Asthma due to a fungus: *Alternaria*. J. Amer. Med. Assoc. 94: 6-10.
- HORTER, R. 1962. Fungal flora of pigs with or without skin diseases. Dtsch. tierärztl. Wschr. 69: 717-719.
- KALINER, A. S. and W. R. BEISEL. 1969. Opportunistic infection: a review. Amer. J. Med. Sci. 258: 431-456.

6. KRAL, F. and R. M. SCHWARTMAN (eds.). 1964. *Veterinary and Comparative Dermatology*. J. B. Lippincott Co., Philadelphia, 444 pp.
7. LOCATCHER-KHORAZO, D., B. C. SEEGAL, A. G. DeVOE and M. SILVA-HUTNER. 1972. Fungal infections of the eye. pp. 208-240. In: Locatcher-Khorazo, D., and Seegal, B. C. (eds.). *Microbiology of the Eye*. C. V. Mosby Co., St. Louis.
8. MARTIN, J. E., D. J. KROE, R. E. BOSTROM, D. J. JOHNSON and R. A. WHITNEY, Jr. 1969. Rhino-orbital phycomycosis in a Rhesus monkey (*Macaca mulatta*). *J. Amer. Vet. Med. Assoc.* 155: 1253-1257.
9. RAJKA, G. 1963. Studies in hypersensitivity to molds and staphylococci and in prurigo besnier (atopic dermatitis). *Acta Derm. Venereol.* 43 (suppl. 54): 9-139.
10. SCHLUETER, D. P., J. N. FINK and G. T. HENSLEY. 1972. Wood-pulp workers' disease: a hypersensitivity pneumonitis caused by *Alternaria*. *Ann. Int. Med.* 77: 907-914.

Received for publication 27 July 1973

---