

INFECTIOUS PODODERMATITIS IN A PRONGHORN ANTELOPE IN ALBERTA

Authors: CHALMERS, GORDON A., and BARRETT, MORLEY W.

Source: Journal of Wildlife Diseases, 10(1) : 60-62

Published By: Wildlife Disease Association

URL: <https://doi.org/10.7589/0090-3558-10.1.60>

BioOne Complete (complete.BioOne.org) is a full-text database of 200 subscribed and open-access titles in the biological, ecological, and environmental sciences published by nonprofit societies, associations, museums, institutions, and presses.

Your use of this PDF, the BioOne Complete website, and all posted and associated content indicates your acceptance of BioOne's Terms of Use, available at www.bioone.org/terms-of-use.

Usage of BioOne Complete content is strictly limited to personal, educational, and non - commercial use. Commercial inquiries or rights and permissions requests should be directed to the individual publisher as copyright holder.

BioOne sees sustainable scholarly publishing as an inherently collaborative enterprise connecting authors, nonprofit publishers, academic institutions, research libraries, and research funders in the common goal of maximizing access to critical research.

INFECTIOUS PODODERMATITIS IN A PRONGHORN ANTELOPE IN ALBERTA

GORDON A. CHALMERS, Alberta Department of Agriculture, Veterinary Services Division, Lethbridge, Alberta, Canada

MORLEY W. BARRETT, Alberta Department of Lands and Forests, Fish and Wildlife Division, Lethbridge, Alberta, Canada

Abstract: Infectious pododermatitis (footrot) presumably caused by *Spherophorus necrophorus* occurred in the left front limb of a mature free-ranging female pronghorn antelope (*Antilocapra americana* Ord) in southeastern Alberta. Marked swelling of the coronary band, phalanges and metacarpus, with fistulous tracts above the hoof were observed. Tenacious, pale green pus was present in the periarticular tissues but did not involve articular surfaces. The causative organism was grown in pure culture on bovine blood agar, incubated anaerobically at 37 C. This is the first published account of footrot in pronghorns.

INTRODUCTION

There have been several descriptions of the syndromes caused by *Spherophorus necrophorus* in North American big game animals, a summary of which has been provided by Rosen.² Species affected have included mule deer (*Odocoileus hemionus*), elk (*Cervus canadensis*), white-tailed deer (*O. virginianus*), Columbian black-tailed deer (*O. hemionus columbianus*), moose (*Alces alces*), caribou (*Rangifer caribou*) and bighorn sheep (*Ovis canadensis*).² This paper describes a case of pododermatitis indicative of *S. necrophorus* infection in a mature, free-ranging, female pronghorn antelope (*Antilocapra americana* Ord), a species in which this infection has not been documented previously.

HISTORY AND NECROPSY FINDINGS

This severely debilitated animal, one of a herd of twelve, was observed in a grain stubble field in southeastern Alberta in late February, 1973. She was limping markedly on her left front leg and was unable to travel with the remainder of the herd when they moved from the

area in early March. Her activities had become extremely limited and consequently on March 6, after approximately 10 days of observation, she was shot. A field necropsy revealed that she carried twin fetuses and had depleted internal fat reserves. The only identifiable materials in the rumen were grain stubble and a small number of grain heads; rumen analyses of other Alberta pronghorns at this time of year revealed primarily forbes and grasses which are the preferred spring forage. The front limbs were removed and taken to the laboratory for more detailed examination.

The left forelimb revealed much swelling of the subcutaneous tissues of the coronary band, phalanges, and distal half of the metacarpus (Fig. 1). Fistulous tracts were evident immediately above the hoof on the lateral aspect of the limb and in the interdigital space. Reflection of the skin revealed voluminous, thick, tenacious pale green pus (Fig. 2) which was confined to the periarticular tissues. Flexor tendons and ligaments were involved in the inflammatory process which was being confined in some areas by advanced fibrosis.

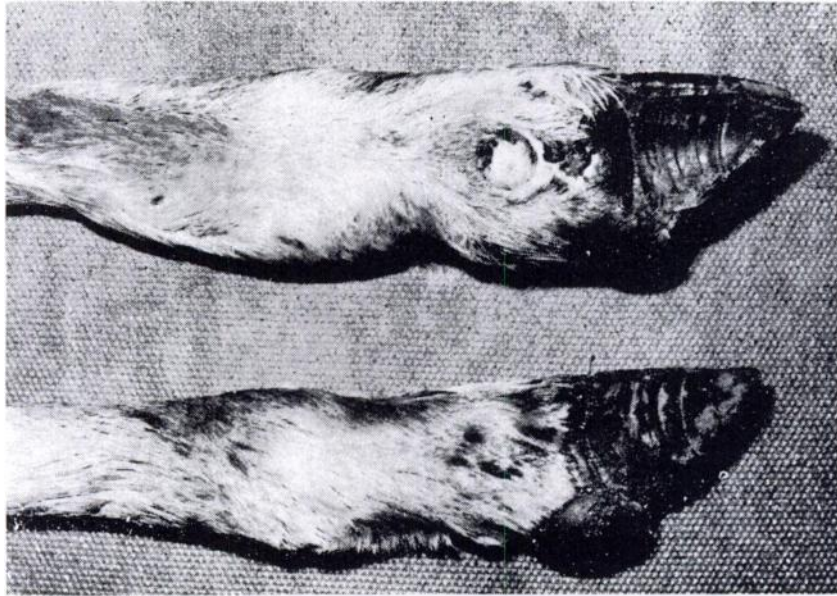


FIGURE 1. Upper limb—marked swelling of the coronary band, phalanges and lower metacarpus. Note the fistulous tracts. Normal limb is below.

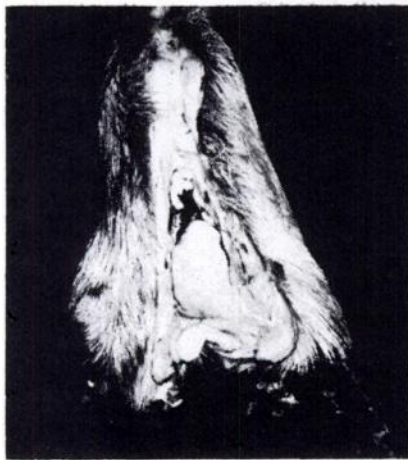


FIGURE 2. Thick, pale green pus exuding from incision in affected limb.

Pus aspirated from the lesions was inoculated onto bovine blood agar and MacConkey's agar media and incubated aerobically, anaerobically and in an atmosphere of 10% CO_2 at 37 C. Growth within 48 hours occurred only on the anaerobically incubated blood agar medium and consisted of many small, round, smooth yellow-white non-hemolytic colonies. Gram and methylene blue stained smears of these colonies, as well as pus from the lesions, revealed numerous uniformly short, beaded Gram-negative rods. Repeated attempts to subculture this organism under anaerobic conditions and to induce growth in various sugars were unsuccessful. On the basis of its morphology and fastidious cultural characteristics, in combination with the location and purulent nature of the reaction, the agent was presumptively identified as *S. necrophorus*.

DISCUSSION

The pathogenesis of footrot in domestic and wild ungulates is incompletely understood. In some cases, however, it is believed that the infective organisms gain entrance to the subcutaneous tissues through abrasions.^{1,2} Pronghorn antelope are occasionally observed limping during the winter when the abrasive action of crusted snow lacerates the anterior surface of the lower limbs. Al-

though such lesions could provide a portal of entry they have never been associated directly with footrot in pronghorns. Moreover, the snowfall in southern Alberta during the winter of 1972-1973 was minimal, suggesting that some other traumatic mechanism was the basis for the infection. The pedal drainage lesions may have been the sites of the initial trauma which introduced *S. necrophorus* to the tissues.

Acknowledgements

The assistance of E. Bruns and A. Farrants of the Alberta Fish and Wildlife Division, with the field necropsy, is appreciated. We also thank J. Wood of the Alberta Veterinary Services Division for his help in bacteriology.

LITERATURE CITED

1. BLOOD, D. C. and J. A. HENDERSON. 1968. *Veterinary Medicine*. Third Ed. Bailliere, Tindall and Cassell, London. pp 419-422.
2. ROSEN, M. N. 1970. Necrobacillosis. In *Infectious Diseases of Wild Mammals*. John W. Davis, Lars H. Karstad and Daniel O. Trainer, Editors. Iowa State University Press, Ames. pp 286-292.

Received for publication 5 September 1973
